

## **ULTRASTRUCTURE OF THE CYST AND LIFE CYCLE OF SARCOCYSTIS SP. FROM WILD SHEEP (OVIS MUSIMON)**

Authors: Nigro, M., Mancianti, F., Rossetti, P., and Poli, A.

Source: Journal of Wildlife Diseases, 27(2) : 217-224

Published By: Wildlife Disease Association

URL: <https://doi.org/10.7589/0090-3558-27.2.217>

---

BioOne Complete ([complete.BioOne.org](https://complete.BioOne.org)) is a full-text database of 200 subscribed and open-access titles in the biological, ecological, and environmental sciences published by nonprofit societies, associations, museums, institutions, and presses.

Your use of this PDF, the BioOne Complete website, and all posted and associated content indicates your acceptance of BioOne's Terms of Use, available at [www.bioone.org/terms-of-use](https://www.bioone.org/terms-of-use).

Usage of BioOne Complete content is strictly limited to personal, educational, and non - commercial use. Commercial inquiries or rights and permissions requests should be directed to the individual publisher as copyright holder.

---

BioOne sees sustainable scholarly publishing as an inherently collaborative enterprise connecting authors, nonprofit publishers, academic institutions, research libraries, and research funders in the common goal of maximizing access to critical research.

## ULTRASTRUCTURE OF THE CYST AND LIFE CYCLE OF *SARCOCYSTIS* SP. FROM WILD SHEEP (*OVIS MUSIMON*)

M. Nigro,<sup>1</sup> F. Mancianti,<sup>2</sup> P. Rossetti,<sup>2</sup> and A. Poli<sup>2</sup>

<sup>1</sup> Dipartimento di Biomedicina Sperimentale, Infettiva e Pubblica, Sez. Biologia e Genetica, Università di Pisa, 56100 Pisa, Italy

<sup>2</sup> Dipartimento di Patologia Animale, Profilassi ed Igiene degli Alimenti, Facoltà di Medicina Veterinaria, Università di Pisa, 56124 Pisa, Italy

**ABSTRACT:** *Sarcocystis* sp. (Eimeriina: Sarcocystidae) is described as a heteroxenous coccidian with domestic dogs as an experimental definitive host and wild sheep (*Ovis musimon*) as natural intermediate hosts. Mature sarcocysts of this *Sarcocystis* sp. were examined by transmission electron microscopy. Sarcocysts in various muscle tissues were microscopic, had a thin primary cyst wall and septa and measured  $81.0 \times 30.5 \mu\text{m}$ . The cysts were located within muscle cells and were limited by a primary cyst wall (PCW). The cyst surface was highly folded forming densely packed projections. Between the PCW projections the surface of the cyst was marked with pit-like invaginations. The ground substance of the cyst formed a layer at the periphery of the cyst, filled the projections and formed septa which divided the cyst into compartments. Sarcocysts contained numerous bradyzoites that were  $15.2 \times 3 \mu\text{m}$  and few metrocytes  $11.5 \times 3.5 \mu\text{m}$ . Twelve days after ingesting *Sarcocystis* sp.-infected wild sheep meat, four dogs began passing sporocysts in their feces: two domestic cats did not pass oocysts or sporocysts after ingesting meat from the same animals. Sporocysts measured  $14.8 \times 9.9 \mu\text{m}$ .

**Key words:** *Sarcocystis* sp., Wild sheep, *Ovis musimon*, ultrastructure, dog, cat, experimental infection.

### INTRODUCTION

Sarcocystosis is a widespread protozoan infection in wild and domestic herbivores. The parasite has a two-host life cycle with the sexual stage occurring in carnivorous animal which become infected by ingesting infected meat. Sporocysts, shed in the feces are ingested by intermediate host, usually herbivores, in which the schizogonic stage occurs (Tadros and Laarman, 1982). The final life cycle stage in the intermediate host is usually located within striated muscle cells and is termed sarcocyst when mature, containing bradyzoites and a few metrocytes.

*Sarcocystis* sp. has been described primarily on the morphology of mature cyst (cysts containing mainly bradyzoites). Size, shape, and cyst wall ultrastructure of sarcocysts are important in the identification and differentiation of *Sarcocystis* sp., as also are life cycle studies (Mehlhorn et al., 1976; Speer and Dubey, 1981; Levine, 1986).

There are numerous detailed investigations on *Sarcocystis* spp. from domestic sheep and goats (O'Donoghue et al., 1986;

Mehlhorn et al., 1975; Mehlhorn and Scholtyssek, 1973; Heydorn and Unterholzner, 1983; Ashford, 1977; Unterholzner, 1983); however, there are few such studies from wild species. In the present paper the ultrastructure of *Sarcocystis* sp. from the wild sheep *Ovis musimon* is described and compared with *Sarcocystis* spp. from related hosts. The role of the dog and cat in the life cycle of this parasite also is investigated.

### MATERIALS AND METHODS

Six adult wild sheep (*O. musimon*) from the Miemo hunting protected Area (Pisa, Italy;  $43^{\circ}28'N$ ,  $10^{\circ}40'E$ ) were examined grossly and microscopically for *Sarcocystis* sp. infection. For light microscopy, 1 cm<sup>3</sup> samples of the tongue, heart and diaphragm muscles, were removed from each wild sheep during necropsy, fixed in 10% buffered formalin solution (pH 7.4), and embedded in paraffin. Five  $\mu\text{m}$  sections were stained with hematoxylin and eosin or periodic acid Schiff (PAS). For electron microscopy, about 1 mm<sup>3</sup> pieces of heart, tongue and diaphragm muscles were collected from each wild sheep, fixed in 2.5% glutaraldehyde in 0.1 M cacodylate buffer solution for 2 hr, rinsed in 0.1 M cacodylate buffer, postfixed for 2 hr in 1% (w/v) OsO<sub>4</sub> in the same buffer for 1 hr at 4 C,

partially dehydrated in ethanol, and prestained in 1% (w/v) uranyl acetate and 1% (w/v) phosphotungstic acid in 70% (v/v) ethanol at 4 C per 12 hr. They were further dehydrated in a graded series of ethanol and in three changes in propylene oxide, and embedded in epon-araldite mixture. One  $\mu\text{m}$  thick and ultrathin sections were cut using a LKB Ultratome III (Broma, Sweden) with glass or diamond knives. Thick sections were stained with toluidine blue. Ultrathin sections were stained with uranyl acetate and lead citrate and examined in a Siemens Elmiskop 101 (Siemens, Berlin, Federal Republic of Germany) transmission electron microscope.

Muscle tissues from each wild sheep were also examined for *Sarcocystis* sp. bradyzoites by pepsin digestion technique.

To determine whether or not domestic dogs or cats could serve as definitive hosts of this *Sarcocystis* sp., samples of heart from infected wild sheep were fed to four dogs and two cats. Six dogs were obtained from the Medical Clinic (School of Veterinary Medicine, University of Pisa, Pisa, Italy) where they had been fed dry dog food (Laika, International Food, Rivolta d'Adda, Italy). Four cats were raised on canned milk (Parmalat, Parma, Italy) and canned cat food (Wiskas, effen Inc. and Cia, Madrid, Spain) until 6-wk-old.

Feces were examined for several days before the beginning of the experiment and all dogs and cats were found free from *Sarcocystis* spp. infection (Dubey, 1980).

Dogs were 5-wk-old and cats 6-wk-old at the beginning of the experiment. Four dogs and two cats, housed individually, were each fed 150 g of heart, tongue and diaphragmatic muscles from naturally infected wild sheep. Two dogs and two cats were used as controls. Feces were collected and examined daily for sporocysts of *Sarcocystis* sp. as described by Dubey (1980).

Dogs were killed at 15, 30, 40, and 60 days post-infection and cats at 30 and 40 days. Control dogs and cats were killed at 30 days after the beginning of the experiment.

The mucosa and submucosa of the small intestine of each animal fed infected wild sheep meat, were removed by scraping with a glass slide and then homogenized in 20 volumes of water to release sporocysts from the host tissue. Sporocysts were collected and stored in a balanced salt solution at 4 C as described by Speer and Dubey (1982).

Representative specimens (histological slides and formalin fixed tissues) of *Sarcocystis* sp. from this study are deposited in the U.S. National Parasite Collection (Animal Parasitology Institute, U.S.D.A., Building 1180 Barc-East, Belts-

ville, Maryland 20705, USA; Accession Number 81865).

## RESULTS

Using pepsin digestion, *Sarcocystis* sp. infection was diagnosed in all six wild sheep examined. Banana shaped bradyzoites were 13.3 to 19.2  $\mu\text{m}$  ( $\bar{x}$  = 15.2  $\mu\text{m}$ , SD = 1.8  $\mu\text{m}$ ,  $n$  = 21) long and 2.8 to 4.1  $\mu\text{m}$  ( $\bar{x}$  = 3.0  $\mu\text{m}$ , SD = 0.3  $\mu\text{m}$ ,  $n$  = 21) wide. Merozoites were 11.0 to 11.9  $\mu\text{m}$  ( $\bar{x}$  = 11.5, SD = 0.2  $\mu\text{m}$ ,  $n$  = 8) by 3.5  $\mu\text{m}$  (SD = 0,  $n$  = 8).

All the sarcocysts were microscopic, measuring  $81.02 \pm 5.27 \mu\text{m}$  ( $n$  = 18) in length and  $30.50 \pm 2.40 \mu\text{m}$  ( $n$  = 18) in width. Sarcocysts had a thin walls (Fig. 1), were located within muscle cells, and were surrounded by altered host cell organelles (i.e., pycnotic cell nuclei, disoriented myofibrils and degenerating mitochondria) (Fig. 2). Sarcocysts from heart, tongue and diaphragm were similar. The primary cyst wall (PCW) consisted of a unit membrane (the parasitophorous vacuolar membrane) which was lined, on the inside, by an osmiophilic dense layer (Figs. 3, 5). The primary cyst wall measured 9 to 10 nm; there was no secondary cyst wall. The PCW was folded along its entire surface (Figs. 2, 3, 4). When the sarcocyst is sectioned longitudinally, the PCW outfoldings appeared as flexic digitations (60 to 180 nm thick and 0.8 to 1.5  $\mu\text{m}$  long) (Fig. 3). These projections were wider at the base and their tip was often bifurcated (Fig. 3). The bifurcated tips were adjacent to the mitochondria and myofibrils of the host cell (Figs. 3, 4). In transversely sectioned sarcocysts the cyst walls were different morphologically. They were 4 to 5 times wider than those in longitudinal cyst sections (0.3 to 0.6  $\mu\text{m}$ ) thus assuming a palisade-like arrangement (Figs. 2, 3). However, due to their flexibility shape, only rarely did the section cut a single projection entirely from the base to the tip (Figs. 2, 4). In some micrographs a few dense plaques were present in the PCW of the apex of projections (Fig. 4). The zone of

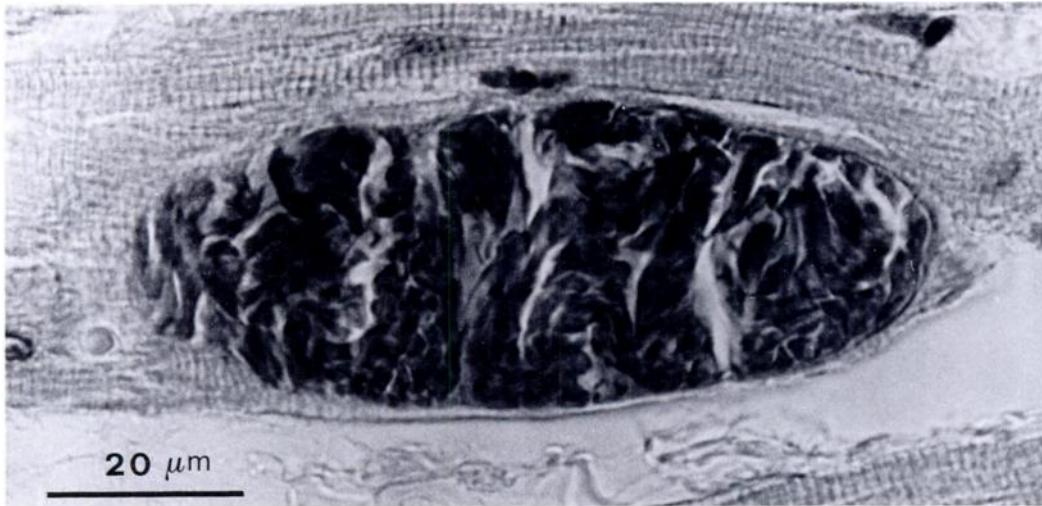


FIGURE 1. Light micrograph of a sarcocyst within a cardiac muscle cell of *Ovis musimon*.

PCW projections had a total thickness ranging from 1.14 to 2.27  $\mu\text{m}$ . In the narrow spaces between the projections, the cyst membrane formed numerous pit-like invaginations (Figs. 4, 5). The invaginations were 54 to 61 nm deep and 32 to 40 nm wide, and appeared in tangential sections as lucent spots (Fig. 5). The invaginated regions of the cyst membrane were not reinforced by the osmiophilic material. The cyst ground substance occupied the immediate interior of the primary cyst wall, filling the core of the outfoldings and forming a layer 0.3 to 0.4  $\mu\text{m}$  thick beneath the projection bases (Figs. 2, 3, 4). The ground substance also extended into septa which divided the interior of the cyst into compartments that contained densely packed cystozoites (Fig. 2). Bradyzoites had all morphological features which are characteristic of the Sarcocystidae such as a posteriorly located nucleus, amylopectin granules, rhoptries, micronemes, mitochondria with tubular cristae, a well-developed conoid and a great number of free ribosomes (Fig. 2). Metrocytes, which were located only at the periphery of the cyst, had an ovoid shape, a large nucleus and a less electron-dense cytoplasm due to a moderate number of ribosomes.

Of the four dogs that ingested *Sarco-*

*cystis* sp.-infected wild sheep meat, three shed sporocysts in their feces beginning at 12 days after ingestion, and one shed sporocysts in its feces at 13 days. Dogs killed at 15 and 30 days post infection were positive for the presence of sporocysts in the small intestine. The other two experimentally-infected dogs shed sporocysts continually for 34 days. The two control dogs did not shed sporocysts, and sporocysts were not found in the feces or the small intestine of the cats fed infected tissues.

*Sarcocystis* sp. sporocysts contained four sporozoites and a granular residuum (Fig. 6). Sporocysts were 13.0 to 15.2  $\mu\text{m}$  ( $\bar{x}$  = 14.9  $\mu\text{m}$ , SD = 0.6  $\mu\text{m}$ ,  $n$  = 30) in length and 8.7 to 10.9  $\mu\text{m}$  ( $\bar{x}$  = 9.9  $\mu\text{m}$ , SD = 0.7  $\mu\text{m}$ ,  $n$  = 30) in width, with a central or terminal cluster of residual granules 7.8  $\mu\text{m}$  in diameter.

## DISCUSSION

In the present study only a single type of sarcocyst was found in various muscle tissues of *O. musimon*. Moreover, all the cysts studied appeared to be in the same developmental stage. The structure of the sarcocyst was typical for *Sarcocystis* sp. in that they have a primary cyst wall, beneath which was a granular layer of ground

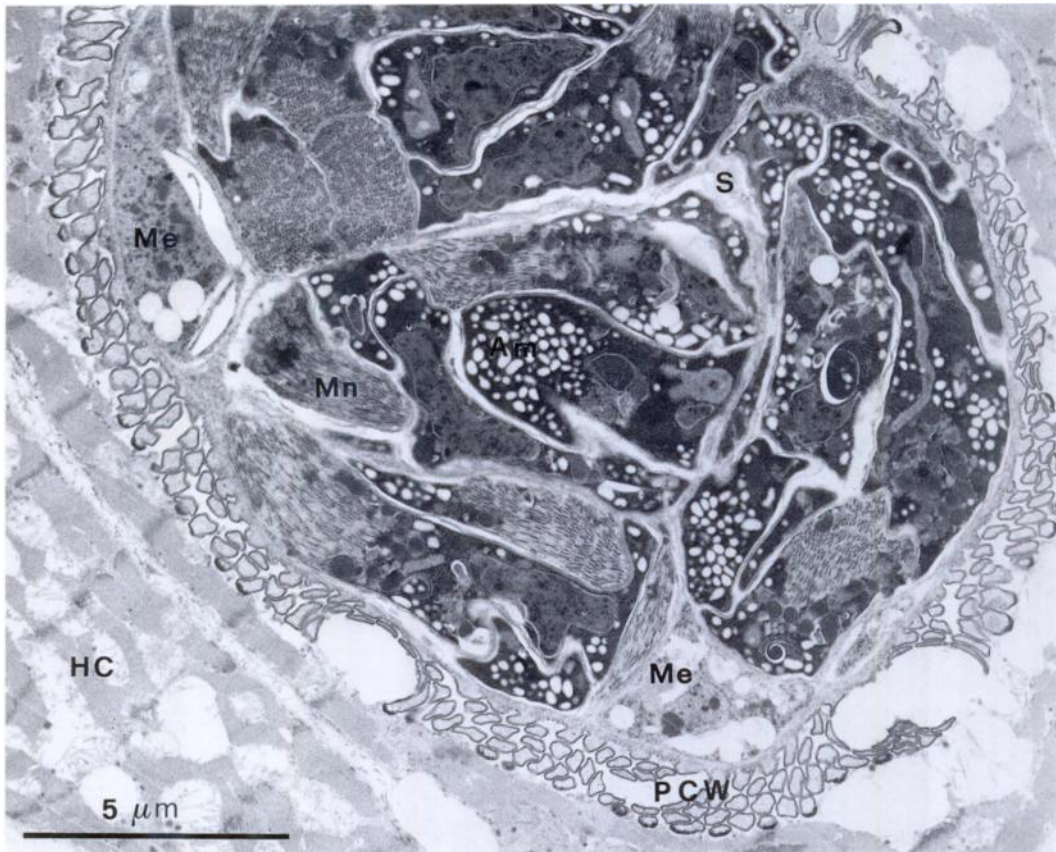


FIGURE 2. Transmission electron micrograph of a transversally sectioned sarcocyst from *Ovis musimon* showing groups of bradyzoites separated by thin septa (S) of ground substance and the palisade-like projections of the primary cyst wall (PCW). Hc, host cell; Me, Merozoite; Mn, Micronemes; A, Amylopectin granules.

substance which was continuous with septa that traversed the sarcocyst completely.

Projections of the primary cyst wall were highly asymmetrical in structure; they were variously flattened in the direction of the major axis of the cyst and wider in that of the minor axis. Most projections were flexible and their distal ends were expanded in a sucker-like structure. The sucker-like tips of the projections were in contact with the host cell myofibrils and mitochondria. Flattened PCW projections also have been described in *Sarcocystis* sp. from fallow deer (Poli et al., 1988) and in *S. greuneri* from reindeer (Gjerde, 1986) and the dense plaques present in the apex of projections of the primary cyst wall resembled the disk-shaped plaques described by Speer and Dubey (1986) in *S. hemionilatrantis*.

Great attention in planning the sectioning procedure must be taken when describing the structure of the cyst wall. Differences in the shape and spatial arrangement of projections could, in fact, merely be due to a different section plane.

Twelve days after ingesting *Sarcocystis* sp.-infected wild sheep meat, dogs began to pass sporocysts in their feces. Moreover, 15 and 30 days post-infection the small intestine of infected dogs contained numerous sporocysts of *Sarcocystis* sp. Because two dogs were killed at 40 and 60 days post-infection we could determine the length of patency. Like most *Sarcocystis* sp. studied (Fayer, 1977; Speer and Dubey, 1982) we have found a relatively long patent period (34 days).

Domestic cats, which also ingested the



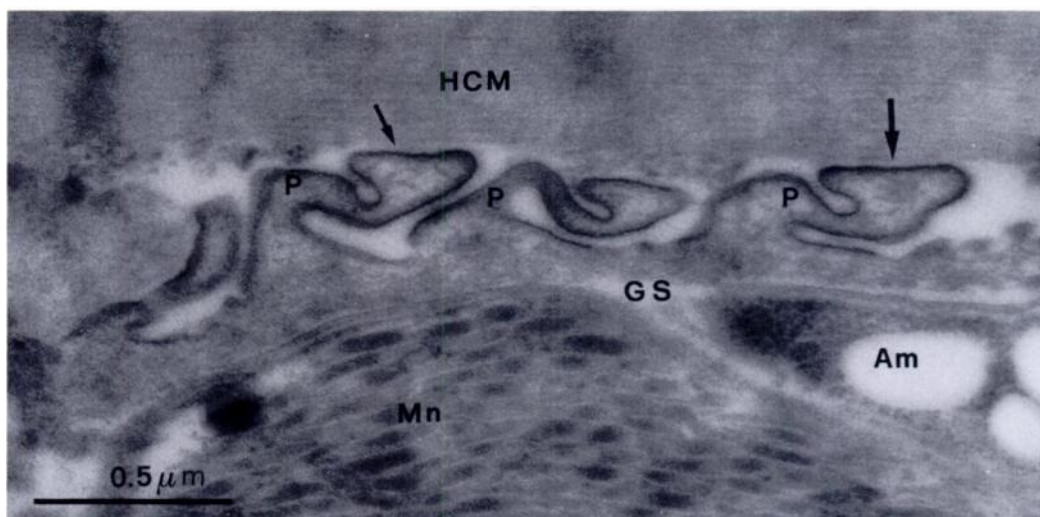


FIGURE 3. Transmission electron micrograph of the peripheral portion of a longitudinally sectioned sarcocyst from *Ovis musimon*; note the primary cyst wall projection (P) which appear narrowed and characterized by sucker-like ends (arrows). HCM, host cell myofibrils; MN, micronemes; Am, amylopectin; Gs, ground substance.

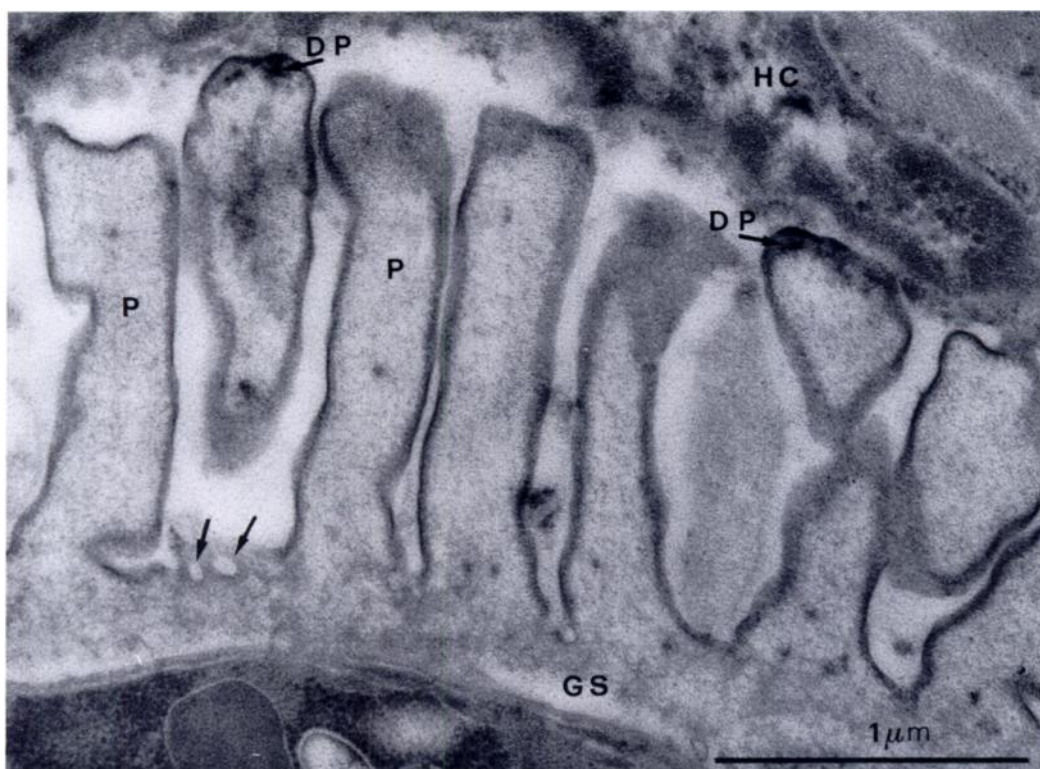


FIGURE 4. Transmission electron micrograph of peripheral portion of a transversally sectioned sarcocyst from *Ovis musimon*; note the palisade-like appearing of the primary cyst wall projections (P) and the presence of pit-like invagination into the cyst surface between projections (arrows); dense plaques (DP) are also visible at the tip of projections. Hc, host cell, Gs, ground substance.

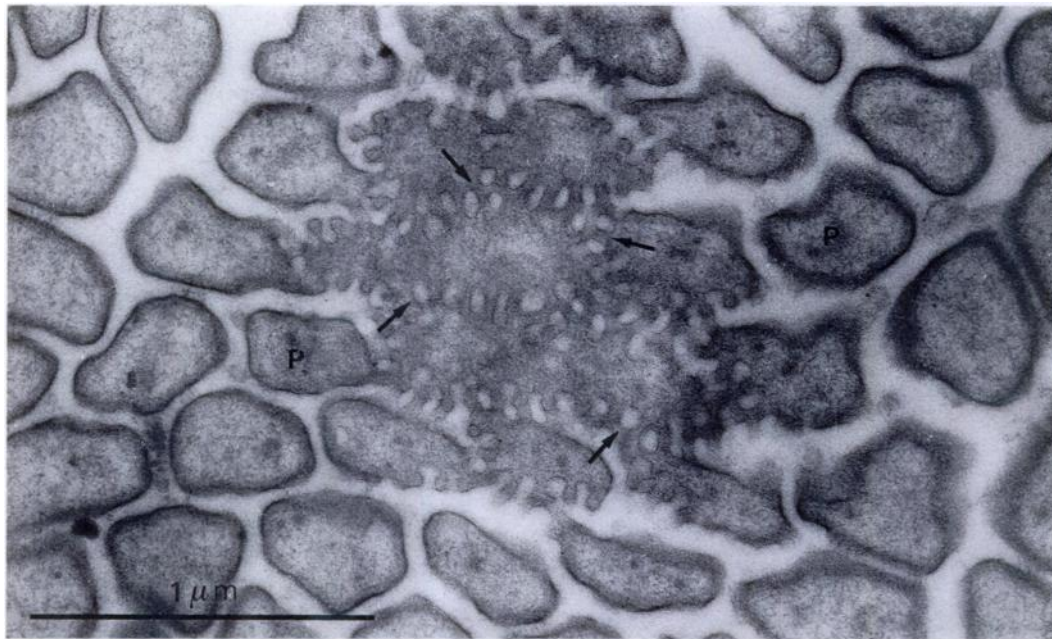


FIGURE 5. Transmission electron micrograph of a section tangential to the sarcocyst from *Ovis musimon* tapering end showing the pit-like invagination (arrows) that in tangential section of the cyst surface appear as lucid spots. P, projection.

infected wild sheep meat did not pass any sporocysts in their feces and did not have any sporocysts or oocysts in their intestinal tract. These experimental infections indicated that the dog, but not the cat, is the definitive host of *Sarcocystis* sp. from *O. musimon*.

The sarcocyst of *Sarcocystis* sp. from *O. musimon* was similar to those of *S. tenella*

(=*S. ovis*) from domestic sheep (Mehlhorn et al., 1975), of *S. capracanis* from goat (O'Donoghue et al., 1986), *Sarcocystis* sp. from chamois (*Rupicapra rupicapra*) (Cornaglia et al., 1980), and *S. ferois* from bighorn sheep (*Ovis canadensis*) (Dubey, 1983). All these *Sarcocystis* sp. were microscopic, had palisade-like projections and underwent gametogony in the Canidae (Levine and Tadros, 1980; Levine, 1986). In *S. tenella* and *S. capracanis* the cyst wall protrusions reach a length of 2 to 3  $\mu$ m and 2.0 to 3.5  $\mu$ m, respectively (O'Donoghue et al., 1986). Also in *Sarcocystis* sp. from *R. rupicapra* the cyst wall protrusions reach a length of 2 to 3  $\mu$ m (Cornaglia et al., 1980), while in sarcocyst from *O. musimon* and *O. canadensis* they are shorter and reach a length of 0.7 to 1.5  $\mu$ m and 1.1 to 1.6  $\mu$ m, respectively (Dubey, 1983). This difference could account for the fact that, in being light microscopy observations, sarcocysts from wild sheep and bighorn sheep did not exhibit thick and striated walls. The structure of sarcocyst wall from *O. musimon* is different also from

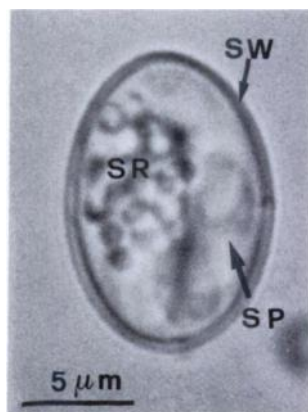

FIGURE 6. Photomicrograph of a sporocyst of *Sarcocystis* sp. from *Ovis musimon*; note sporozoites (SP), sporocyst residuum (SR), and sporocyst wall (SW).

that of sarcocysts in bighorn sheep. The sarcocyst of the bighorn sheep had mushroomlike evaginations and lacks the palisade-like arrangement of projections that *Sarcocystis* sp. from *O. musimon* had in transversally sectioned sarcocysts.

Traditionally the systematics of *Sarcocystis* spp. has been heavily based on structural differences regarding the primary cyst wall and secondarily upon cross-infection experiments. There are two possible explanations for the structural similarities that *Sarcocystis* spp. from systematically related intermediate hosts share. They (1) belong to a common species with poor specificity or (2) they represent different species which are highly specific for each intermediate host. There is contradicting evidence regarding this question. Unterholzner (1983) reported that a sheep inoculated with sporocysts of *S. capracanis* and *S. hircicanis* did not become infected with these parasites; moreover goats inoculated with sporocysts from *S. tenella* (= *S. ovis*) did not become infected. Other transmission experiments also have demonstrated that *S. ovis* and *S. capracanis* are two separate species (Aryeetey et al., 1980) notwithstanding their ultrastructural and genetic similarities (O'Donoghue et al., 1986). However, accurate life cycle studies with cross-transmission experiments are needed to confirm whether *Sarcocystis* sp. from *O. musimon* is as specific for the intermediate host as has been demonstrated for *S. capracanis* and *S. tenella* and whether or not it can be considered a separate species.

#### ACKNOWLEDGMENTS

This research was financed by a grant from Consiglio Nazionale delle Ricerche (Italy) and Amministrazione Provinciale, Pisa (Italy).

#### LITERATURE CITED

- ARYEETAY, M., H. MEHLHORN, AND A. O. HEYDORN. 1980. Electron microscopic studies on the development of *Sarcocystis capracanis* in experimentally infected goats. *Zentralblatt für Bakteriologie und Hygiene. I. Abstract Originale A* 247: 543–556.
- ASHFORD, R. W. 1977. The fox, *Vulpes vulpes*, as a final host for *Sarcocystis* of sheep. *Annals of Tropical Medicine and Parasitology* 71: 29–34.
- CORNAGLIA, E., F. GUARDA, AND M. E. MISCIATTELLI. 1980. Ricerca, frequenza, diagnosi, morfologia istopatologica ed ultrastrutturale della Sarcosporidiosi cardiaca nei camosci e stambecchi. *Annali di Facoltà Medicina Veterinaria Torino* 27: 279–296.
- DUBEY, J. P. 1980. Coyote as a final host for *Sarcocystis* species of goats, sheep, cattle elk, bison, and moose in Montana. *American Journal of Veterinary Record* 41: 1227–1229.
- . 1983. *Sarcocystis ferovis* sp. n. from the bighorn sheep (*Ovis canadensis*) and coyote (*Canis latrans*). *Proceedings of the Helminthological Society of Washington* 50: 153–158.
- FAYER, R. 1977. Production of *Sarcocystis cruzi* sporocysts by dogs fed experimentally infected and naturally infected beef. *The Journal of Parasitology* 63: 1072–1075.
- GJERDE, B. 1986. Scanning electron microscopy of the sarcocysts of six species of *Sarcocystis* from reindeer (*Rangifer tarandus tarandus*). *Acta Pathologica et Microbiologica Scandinavica Sect. B* 94: 309–317.
- HEYDORN, A. O., AND J. UNTERHOLZNER. 1983. Zur Entwicklung von *Sarcocystis hircicanis* n. sp. *Ber. Münch. Tierärztliche Wochenschrift* 96: 275–282.
- LEVINE, N. D. 1986. The taxonomy of *Sarcocystis* (Protozoa, Apicomplexa) species. *The Journal of Parasitology* 72: 372–382.
- , AND W. TADROS. 1980. Named species and hosts of *Sarcocystis* (Protozoa: Apicomplexa: Sarcocystidae). *Systematic Parasitology* 2: 41–59.
- MEHLHORN, H., W. J. HARTLEY, AND A. O. HEYDORN. 1976. A comparative ultrastructural study of the cyst wall of 13 *Sarcocystis* species. *Protistologica* 12: 451–467.
- , A. O. HEYDORN, AND R. GESTRICH. 1975. Licht- und elektronenmikroskopische Untersuchungen an Cysten von *Sarcocystis ovis* Heydorn et al., 1975 in der Muskulatur von Schafen. *Zeitschrift für Parasitenkunde* 48: 83–93.
- , AND E. SCHOLTYSECK. 1973. Elektronenmikroskopische Untersuchungen an Cystenstadien von *Sarcocystis tenella* aus der Oesophagus-Muskulatur des Schafen. *Zeitschrift für Parasitenkunde* 41: 291–310.
- O'DONOGHUE, P. J., M. ADAMS, B. R. DIXON, G. E. FORD, AND P. R. BAVERSTOCK. 1986. Morphological and biochemical correlates in the characterization of *Sarcocystis* spp. *Journal of Protozoology* 33: 114–121.
- POLI, A., F. MANCIANTI, A. MARCONCINI, M. NIGRO, AND R. COLAGRECO. 1988. Prevalence, ultrastructure of the cyst wall and infectivity for the dog and cat of *Sarcocystis* sp. from fallow deer



- (*Cervus dama*). Journal of Wildlife Diseases 24: 97-104.
- SPEER, C. A., AND J. P. DUBEY. 1981. An ultrastructural study of first- and second-generation merogony in the coccidian *Sarcocystis tenella*. Journal of Protozoology 28: 424-431.
- , AND ———. 1982. *Sarcocystis wapiti* sp. nov. from the North American wapiti (*Cervus elaphus*). Canadian Journal of Zoology 60: 881-888.
- , AND ———. 1986. An unusual structure in the primary cyst wall of *Sarcocystis hemionti-latrantis*. Journal of Protozoology 33: 130-132.
- TADROS, W., AND J. J. LAARMAN. 1982. Current concepts on the biology, evolution and taxonomy of tissue cyst forming eimeriid coccidia. Advances in Parasitology 20: 293-468.
- UNTERHOLZNER, J. 1983. Zur Entwicklung einer neuen vom Hund übertragenen Sarkosporidienart (*Sarcocystis* sp. (Z)) der Ziege. Veterinary Medicine Dissertation. Freien Universität Berlin, Federal Republic of Germany, 64 pp.

Received for publication 10 April 1990.