

INFLAMMATORY CELL STIMULATION AND WOUND HEALING IN SPHAERIDIOTREMA GLOBULUS EXPERIMENTALLY INFECTED MALLARD DUCKS (ANAS PLATYRHYNCHOS)

Authors: Mucha, K. Head, and Huffman, Jane E.

Source: Journal of Wildlife Diseases, 27(3) : 428-434

Published By: Wildlife Disease Association

URL: <https://doi.org/10.7589/0090-3558-27.3.428>

BioOne Complete (complete.BioOne.org) is a full-text database of 200 subscribed and open-access titles in the biological, ecological, and environmental sciences published by nonprofit societies, associations, museums, institutions, and presses.

Your use of this PDF, the BioOne Complete website, and all posted and associated content indicates your acceptance of BioOne's Terms of Use, available at www.bioone.org/terms-of-use.

Usage of BioOne Complete content is strictly limited to personal, educational, and non - commercial use. Commercial inquiries or rights and permissions requests should be directed to the individual publisher as copyright holder.

BioOne sees sustainable scholarly publishing as an inherently collaborative enterprise connecting authors, nonprofit publishers, academic institutions, research libraries, and research funders in the common goal of maximizing access to critical research.

INFLAMMATORY CELL STIMULATION AND WOUND HEALING IN *SPHAERIDIOTREMA GLOBULUS* EXPERIMENTALLY INFECTED MALLARD DUCKS (*ANAS PLATYRHYNCHOS*)

K. Head Mucha¹ and Jane E. Huffman^{1,2}

¹ Department of Biological Sciences, East Stroudsburg University,
East Stroudsburg, Pennsylvania 18301, USA

² Author to whom correspondence and reprint requests should be sent

ABSTRACT: Thirty laboratory-reared mallard ducks (*Anas platyrhynchos*) were experimentally infected with *Sphaeridiotrema globulus*. Host cell-mediated immunity and wound healing in *S. globulus* infected ducks were evaluated by gross and histological examination. Establishment, location, and life span of *S. globulus* differed from previous reports of sphaeridiotremiasis in both naturally and experimentally infected waterfowl. No worms were recovered from the ceca, and worm migration occurred anterior to the ileo-cecal valve with greater dispersion (less worm crowding) at higher rates of infectivity. Parasite death and host lesion resolution were evident at days 8 to 10 postinfection (PI) in ducks fed a moderate dose (200 metacercariae, group A) with a 5% mean parasite recovery rate. Host death occurred at days 3 to 6 in ducks fed a high dose (550 metacercariae, group B) with a 16% mean parasite recovery rate. Mast cells increased significantly ($P < 0.005$) in group A ducks from days 4 to 10 PI. Eosinophil proliferation was greater in group B than in group A on day 4 PI, but comparatively fewer eosinophils were identifiable in group B ducks on day 6 PI.

Key words: *Sphaeridiotrema globulus*, trematode, mallard duck, *Anas platyrhynchos*, mast cell, eosinophil, wound healing, experimental infections.

INTRODUCTION

Sphaeridiotrema globulus is a pathogenic digenetic trematode (family Psilostomatidae) inhabiting the small intestine of waterfowl. This helminth is enzootic among mute swans (*Cygnus olor*) at Lake Musconetcong, New Jersey (USA) (Roscoe and Huffman, 1982), and has been the suspect etiologic agent in a fatal enteritis of several species of waterfowl in North America (Price, 1934; Cornwell and Cowan, 1963; Trainer and Fischer, 1963; Speckmann et al., 1972; Roscoe and Huffman, 1983; Hoeve and Scott, 1988), Europe (Francalanci and Manfredini, 1969; Testi, 1962), and Australia (Campbell and Jackson, 1977). Susceptible waterfowl die 3 to 8 days postinfection after ingesting a lethal dose of *S. globulus* metacercarial cysts from intermediate snail hosts (Huffman and Roscoe, 1989). Clinical and gastrointestinal pathologies have been reported; anorexia, bloody pericloacal discharge, ballooning of the ileum and jejunum presenting hemorrhagic, necrotic

extensive mucosa epithelial desquamation, vascular congestion and death (Price, 1934; Speckmann et al., 1972; Huffman et al., 1984; Huffman and Roscoe, 1989).

The objectives of this study were to (1) describe the pathogenesis of sphaeridiotremiasis in mallard ducks by evaluating gross and serial histopathology, (2) investigate the frequency of mast cells and eosinophils in *S. globulus* experimentally infected mallard duck intestinal tissue, and (3) evaluate the role of mast cells and eosinophils as effector cells in avian host immunology, or as potentiators of hemorrhagic enteritis in host immunopathology.

MATERIALS AND METHODS

Wild mallard ducks eggs were collected from March through April, 1989. Eggs were incubated and hatched at the New Jersey Fish, Game and Wildlife facility in Rockport (New Jersey 07840, USA). Ducklings were provided food (Country Egg Producer, Agway, Inc., Syracuse, New York, 13221, USA) and water ad libitum. Ducks (12-wk-old) were divided into three groups, A, B, and C. Groups A and B were fed 200 and 550 metacercarial cysts, respectively. Metacercarial cysts suspended in water were ad-

were obtained from naturally infected *Goniobasis virginica* snails from Lake Musconetcong (Netcong, New Jersey; USA 40°45'N, 74°42'W) (Huffman and Roscoe, 1989). Group C were controls and were not infected.

Twenty ducks comprised group A. Four birds were killed by cervical dislocation at 2 day intervals, from days 2 to 10 postinfection (PI). The worm location was recorded in cm anterior to the ileo-cecal valve and reported as a percentage of individual duck intestinal length. The number of parasites recovered were recorded for each duck. Tissue samples of each ulcerated region from 10 ducks were fixed immediately in 10% buffered neutral formalin for 24 hr, then dehydrated in graded alcohols, cleared in xylene, embedded in Paraplast, and sectioned at 6 μ m.

Ten ducks comprised group B. Two birds were killed by cervical dislocation and necropsied at each 2 day interval from day 2 to 6 PI, or necropsied immediately if the animal succumbed to the infection. Two ducks from group C were killed by cervical dislocation and uninfected tissue samples were processed as previously described.

Infected tissue sections were stained in Giemsa and Pollack's Trichrome solution using Toren's mast cell stain (Toren, 1963). Giemsa staining time was modified for avian tissue from 75 min to 25 min. Trichrome staining time also was modified from 10 to 15 sec to 5 to 8 sec.

Cells (mast cells, globule leukocytes, and eosinophils) were counted per 10 villus/crypt units (Miller and Jarrett, 1971), adjacent to parasites attached to intestinal tissue and at 20 VCU- and 40 VCU-increments from the parasites. A total of 50 VCU's from five separate segments of intestine were counted per necropsied duck. Histological serial counts were taken from 10 group A ducks killed at 2 day intervals (days 2 to 10 PI), and 8 group B ducks (days 2 to 6), or upon immediate necropsy if a duck succumbed to the infection.

Logarithmic (to base 10) transformation of cell counts ($x + 1$) was performed. This transformation tends to be variance stabilizing and to normalize such data (Handlinger and Rothwell, 1981). Cell counts were presented as geometric means (anti-log of mean log of data). Intensity variation was reported as standard error.

RESULTS

Data from day 2 PI ducks were not included from group A (four ducks) or B (four ducks) in the infectivity results. Worms were difficult to observe and had

not yet aggregated into clusters and did not produce visible lesions. Parasites recovered after day 2 PI were found in clusters usually adjacent to one another. Lesions containing one parasite were uncommon.

Sixty-three percent of the ducks in group A were infected (10 of 16) with a range of 0 to 43 helminths. Mean parasite recovery rate was $5.0 \pm 3.7\%$ (160 of 3,200). All group B ducks were infected, with a range of 67 to 121 helminths. Mean parasite recovery rate was $16.0 \pm 6.4\%$ (696 of 4,400).

The prevalence of infection decreased in group A ducks from 75% (three of four) at day 4 PI, to 50% (two of four) at day 8 PI, to 25% (one of four) at day 10 PI. The mean parasite intensity of four ducks from each 2 day necropsy on days 4 to 10 PI, decreased from 22.5 ± 13.5 individuals, to 11.3 ± 5.5 , 3.75 ± 3 and 2.8 ± 3.2 individuals at days 4, 6, 8 and 10 PI, respectively. Lesion site resolution was evident after day 8 and 10 PI.

Parasites recovered from group A ducks were located 18.7 to 36.8% distance anterior to the ileo-cecal valve. Parasites recovered from group B were located 14.1–56.1% distance anterior to the ileo-cecal valve. In the high dose group (B), parasites migrated anterior to the ileo-cecal valve with less crowding per 2.5% distance interval. The area chart shown in Figure 1 depicts comparative worm frequencies and locations in % distance of group A and B parasites recovered.

Clinically, *S. globulus* experimentally infected mallard ducks presented similar signs and symptoms as found in naturally infected waterfowl. Six to 12 hr prior to death, a pericloacal bloody discharge, unsteady gait, and wing droop were characteristic signs of high dose (group B) ducks. Four group B ducks died from the infection on day 5 to 6 PI. One duck died on day 3 PI with 121 parasites recovered at necropsy. A single group B duck survived 6 days PI, although it was ataxic and near death. The minimum lethal number

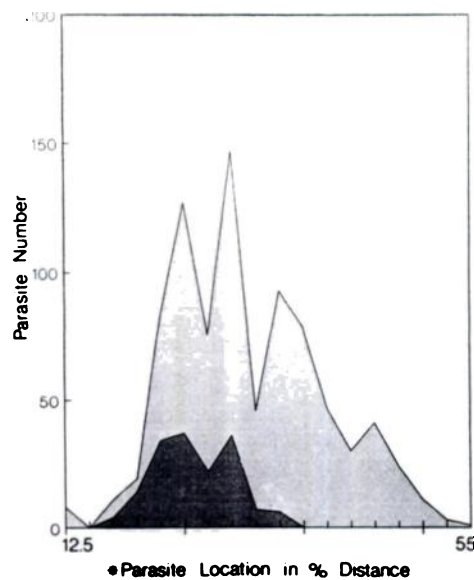


FIGURE 1. Comparative parasite frequencies and locations of parasites recovered from group A and B *S. globulus* infected mallard ducks. Parasite location is anterior to the ileo-cecal valve, ▨ group A, ▢ group B.

of *S. globulus* worms recovered at necropsy in group B ducks was 67.

Gross inspection of both group A and B revealed an elevated, yellowish-white plaque at sites of worm attachment and ulceration. The lesions varied in diameter, depending on the number of parasites present in the ulcer. Histopathological examination showed the lesions were composed of fibrin, mucin, desquamated mucosal epithelial cells, and inflammatory cells.

The histological lesions were grouped into three categories; early lesion, advanced lesion, and resolved lesion. The early lesion consisted of a focal necrosis with a heterophil infiltration. An aggregation of fibrin and polymorphonuclear cells splayed out from a necrotic focus forming a raised lesion site. The early lesion was evident by day 4 PI in both group A and group B ducks.

The advanced lesion was present by days 4 to 6 PI. Blood vessel congestion, and a marked heterophilic infiltration accompanied the ulceration. Frequently, the par-

asites penetrated the muscularis, resulting in vessel congestion and hemorrhage.

Resolution of the lesion occurred in moderate dose (group A) ducks by days 8 to 10 PI. Scar tissue composed of fibroblasts, polymorphonuclear leucocytes, fibrin, and collagen, formed over the damaged villi and dead worms, walling off the parasites from surrounding tissues. A normal mucosal architecture was generated in group A ducks by 8 to 10 days PI.

Group A mast cell frequency increased from day 4 PI through day 10 PI ($P < 0.05$) using Duncan's Multiple Range Test compared to (SAS Institute, Inc., 1987) group C control values for uninfected mallard ducks. Mast cell frequency remained elevated after day 6 PI through day 10 PI, during the period of lesion resolution and wound healing. Uninfected control ducks had a geometric mean ($x + 1$) of 1.90 ± 0.33 mast cells/10 VCU's, with a total of 9 mast cells/100 VCU's. Group A ducks had a geometric mean range of 3.9 ± 0.84 to 10.5 ± 2.7 mast cells per 10 VCU's, from days 2 to 10 PI, respectively, with a total mast cell number range of 29 to 95 mast cells per 100 VCU's.

Group B ducks had no significant ($P < 0.278$) difference in variance of mast cell geometric means per 10 VCU's on days 3, 4, 5 and 6 PI using geometric linear model (GLM) analysis of variance ANOVA (SAS Institute, Inc., 1987) compared to uninfected control ducks. No mast cell stimulation was observed. Group B ducks had a geometric mean range of 1.2 ± 0.2 to 2.0 ± 0.4 mast cells per 10 VCU's, with a total mast cell number range of 1 to 10 mast cells/50 to 100 VCU's from days 2 to 6 PI.

Table 1 compares mast cell counts between groups A and B, at days 2, 4, and 6 PI, using GLM ANOVA (SAS Institute, Inc., 1987). There is a significant difference ($P < 0.05$) in variance of group A and B mast cell geometric means on days 2, 4, and 6 PI. Group A mast cell geometric means increase every 2 days PI, and group B mast cell geometric means decrease every 2 days PI.

TABLE 1. Comparison of geometric mean mast cell counts/10 villus/crypt units (VCU's) between group A and B 2-day necropsy intervals postinfection (PI), in *S. globulus* infected mallard ducks.

Day PI	Number of ducks	Geometric mean cell count/VCU's		
		Group A	Group B	P-value*
2	4	3.9	1.5	<0.05
4	3	6.9	1.4	<0.05
6	4	8.1	1.2	<0.05

* GLM ANOVA (SAS Institute, Inc., 1987).

Eosinophil geometric mean cell counts in group A showed a significant increase at day 6, 8, and 10 PI ($P < 0.05$) using Duncan's Multiple Range Test (SAS Institute, Inc., 1987), compared to group C control mallard ducks. The eosinophil geometric mean cell count was 2.6 ± 0.4 in control ducks/10 VCU's. Group A geometric means ranged from 2.2 ± 0.3 to 329.3 ± 67.4 eosinophils/10 VCU's, from days 2 to 10 PI, with a total eosinophil cell number range of 12 to 3,283 eosinophils per 100 VCU's. Eosinophils were stimulated markedly at sites of worm attachment. Eosinophil stimulation and localization was greatest at day 6 PI and remained elevated through day 10 PI, during the period of lesion resolution and wound healing.

Group B ducks had a significant ($P < 0.0001$) difference in variance of eosinophil geometric means/10 VCU's on days 3, 4, 5 and 6 PI using GLM ANOVA (SAS Institute, Inc., 1987) compared to group C control ducks. Eosinophil geometric means ranged from 3.3 ± 0.6 to 146.2 ± 38.9 eosinophils/10 VCU's from days 2 to 6 PI,

with a total eosinophil cell number range of 23 to 1,452/50 or 100 VCU's.

Table 2 is a comparison of eosinophil cell counts between group A and B, on days 2, 4, and 6 PI. There is a significant difference in variances ($P < 0.0001$) between group A and B eosinophil geometric means on days 2, 4, and 6 PI using GLM ANOVA (SAS Institute, Inc., 1987). Group B showed a marked stimulation on eosinophil frequency at day 4, PI, compared to group A. At day 6 PI, group A showed the greatest increase in eosinophils, compared to group B. Group B eosinophil stimulation occurred earlier than group A, but the intensity of eosinophil stimulation was greater in group A by day 6 PI.

Figure 2 compares group A duck mast cells, eosinophils and mean parasite burdens from each 2-day interval PI. After day 4 PI, mean worm numbers recovered decreased through day 10 PI, and mast cell means remained elevated. After day 6 PI, worm means dropped markedly, and eosinophil mean cell counts increased significantly ($P < 0.05$), remaining elevated through day 10 PI.

Figure 3 compares group B duck mast cells, eosinophils and mean worm burdens from days 2 to 6 PI. Eosinophil mean cell count variances differed significantly ($P < 0.0001$). The mean parasite burden did not decrease.

DISCUSSION

The establishment and location of *S. globulus* in experimentally infected mallard ducks differed from previous reports of sphaeridiotremiasis in both naturally and

TABLE 2. Comparison of geometric mean eosinophil cell counts/10 villus/crypt units (VCU's) \pm SE between group A and B 2-day necropsy intervals postinfection (PI), in *S. globulus* infected mallard ducks.

Day PI	Number of ducks	Geometric mean cell count/10 VCU's		
		Group A	Group B	P-value*
2	4	2.2	3.3	†
4	3	4.3 ± 0.7	91.6 ± 19.6	<0.0001
6	4	329.3 ± 67.4	121.3 ± 33.1	<0.0001

* GLM ANOVA (SAS Institute, Inc., 1987).

† Not significant ($P < 0.05$).

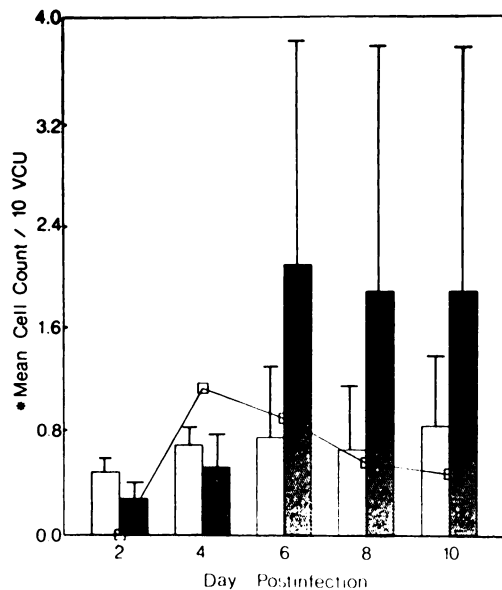


FIGURE 2. Comparison of mast cells (□), eosinophils (■), and mean parasite intensity (◻), in group A *S. globulus* infected ducks ($n = 10$) from day 2 to 10 postinfection (PI), \pm SE. *Log 10 data transformation ($x + 1$).

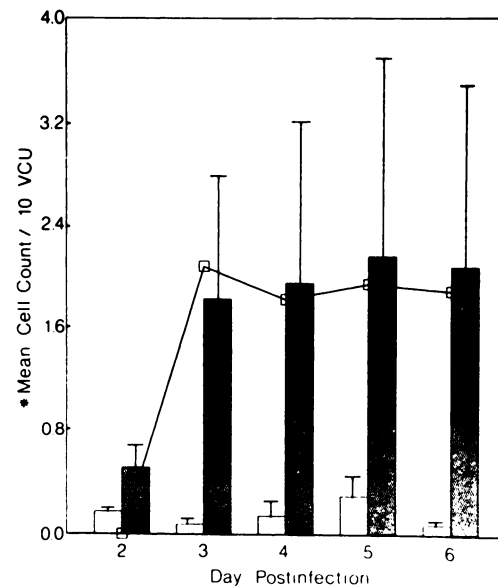


FIGURE 3. Comparison of mast cells (□), eosinophils (■), and mean parasite intensity (◻), in group B *S. globulus* infected ducks ($n = 8$) from day 2 to 6 postinfection (PI), \pm SE. *Log 10 data transformation ($x + 1$).

experimentally infected waterfowl. Macy and Ford (1964), Macy et al. (1968), and Trainer and Fischer (1963), recovered *S. globulus* from the cecum and small intestine of various species of waterfowl.

Sphaeridiotrema globulus in our experimentally infected ducks had a 10 day life span. A 16 day life span has been previously reported (Berntzen and Macy, 1969).

Parasite recovery and pathogenicity of *S. globulus* in experimentally infected ducks also differ from the results of Macy et al. (1968). They reported a mean parasite recovery of 24.8 to 29.5% at day 5 PI, regardless of the numbers of cysts fed (500 to 2,000 cysts per duck). In this study, group A ducks (fed 200 cysts each) had a mean parasite recovery of $8.4 \pm 6.6\%$ at day 4 to 6 PI (134 parasites recovered from eight ducks fed 1,600 cysts). Group B ducks (fed 550 cysts each) had a $16.0 \pm 2.8\%$ mean recovery at day 5 PI (353 parasites recovered from four ducks, fed 2,200 cysts). The minimum lethal dose fell within the range 43 to 66 worms.

The immune response of moderate dose

(group A) ducks in this study was capable of killing, and isolating, the parasite from surrounding intestinal tissue by day 8 to 10 PI. The response may be both humoral and cell-mediated.

Mast cells increased significantly in group A ducks from days 2 to 10 PI, and peaked on day 10 PI. Mast cell hyperplasia coincided with lesion resolution (day 8 to 10 PI) in low dose group A ducks. Similar results correlating expulsion kinetics and intestinal mastocytosis have been reported in *Nippostrongylus brasiliensis* infected mice (Stadnyk et al., 1990) and rats (Miller and Jarrett, 1971; MacDonald et al., 1980). Mast cells decreased in group B ducks on day 3 and 6 PI. A decrease in the histological identification of mucosal mast cells may be an indicator of mast cell activity. Metachromatic granules are not identifiable under light microscopy after degranulation, and may be difficult to recognize in immature mast cells. Woodbury et al. (1984) characterized rat mast cell protease II (RMCP II) in mucosal mast cells using immunochemical techniques. They noted

that when high levels of RMCP II were detectable, few mast cells were observable using histological technique. The cell mediated immune (CMI) response of high dose (group B) ducks may have functioned at a greater intensity in fewer days than CMI in moderate dose (group A) ducks. Fewer group A mast cells may have been degranulating during proliferation with moderate *S. globulus* intensities, compared to group B.

Eosinophils are usually detectable during degranulation due to staining of the nucleus and cytoplasm, although degranulating eosinophils can be confused in appearance with heterophils. Eosinophil granules are not as easily damaged during fixation and staining as mucosal mast cell granules. Eosinophil proliferation was significant on day 4, 6, and 10 PI in group A ducks. High numbers of eosinophils localized only at sites of parasite attachment.

The comparatively fewer numbers of histologically identifiable eosinophils in group B after day 4 PI may indicate an increase in eosinophil degranulation. The short time period (3 to 6 days) of intense eosinophil stimulation in group B ducks may not have been sufficient for eosinophil differentiation and migration from the bone marrow and peripheral blood to sites of infection. This may suggest that the requirement for greater total numbers of eosinophils exceeded rates of eosinophil production during the short period of disease in high dose infections.

Mast cells and eosinophils in both group A and B ducks was significantly affected by *S. globulus* infections. Mast cell proliferation continued throughout the course of infection (10 days PI) in group A ducks. Eosinophil numbers increased at the critical period of disease (day 6 PI), and decreased through day 10 PI.

If the decline in histologically identifiable mast cells and eosinophils after day 5 to 6 PI in both group A and B was due to degranulation, then it is likely that inflammatory mediators secreted from these cells

caused parasite destruction and concomitant pathology in infected host tissue.

ACKNOWLEDGMENTS

This work was supported by a Faculty Development Research Grant from East Stroudsburg University and by the Pennsylvania Academy of Sciences. We gratefully thank Edward Washuta for statistical assistance and C. Dean Miller for typing the manuscript.

LITERATURE CITED

- BERNTZEN, A. K., AND R. W. MACY. 1969. In vitro cultivation of the digenetic trematode *Sphaeridiotrema globulus* (Rudolphi) from the metacercarial stage to egg production. *The Journal of Parasitology* 55: 136-139.
- CAMPBELL, N. J., AND C. A. W. JACKSON. 1977. The occurrence of the intestinal fluke *Sphaeridiotrema globulus* in domestic ducks in New South Wales. *Australian Veterinary Journal* 53: 29-31.
- CORNWELL, G. W., AND A. B. COWAN. 1963. Helminth populations in the canvasback *Aythya valisineria* and host-parasite interrelationships. *Transactions of the North American Wildlife Resource Conference* 28: 173-199.
- FRANCALANCI, G., AND L. MANFREDINI. 1969. La distomatosi intestinale dei volatili domestici da *Sphaeridiotrema globulus* (Rudolphi, 1814). *Clinica Veterinaria Milano* 92: 308-314.
- HANDLINGER, J. H., AND T. L. W. ROTHWELL. 1981. Studies of the responses of basophil and eosinophil leucocytes and mast cells to the nematode *Trichostrongylus colubriformis*: Comparison of cell populations in parasite resistant and susceptible guinea pigs. *International Journal for Parasitology* 11: 67-70.
- HOEVE, J., AND M. E. SCOTT. 1988. Ecological studies on *Cyathocotyle bushiensis* (Digenea) and *Sphaeridiotrema globulus* (Digenea), possible pathogens of dabbling ducks in southern Quebec. *Journal of Wildlife Diseases* 24: 407-421.
- HUFFMAN, J. E., B. FRIED, D. E. ROSCOE, AND A. CALI. 1984. Comparative pathologic features and development of *Sphaeridiotrema globulus* (Trematoda) infections in the mute swan and domestic chicken and chicken chorioallantois. *American Journal of Veterinary Research* 45: 387-391.
- , AND D. E. ROSCOE. 1989. Experimental infections of waterfowl with *Sphaeridiotrema globulus* (Digenea). *Journal of Wildlife Diseases* 25: 143-146.
- MACDONALD, T. T., M. MURRAY, AND A. FERGUSON. 1980. *Nippostrongylus brasiliensis*: Mast cell kinetics at small intestinal sites in infected rats. *Experimental Parasitology* 49: 9-14.
- MACY, R. W., AND J. R. FORD. 1964. The psilostome

- trematode *Sphaeridiotrema globulus* (Rudolphi) in Oregon. The Journal of Parasitology 50: 93.
- MACY, R. W., A. K. BERNTZEN, AND M. BENZ. 1968. In vitro excystation of *Sphaeridiotrema globulus* metacercariae, structure of cyst, and the relationship to host specificity. The Journal of Parasitology 54: 28-38.
- MILLER, H. R. P., AND W. H. F. JARRETT. 1971. Immune reactions in mucous membranes. I. Intestinal mast cell response during helminth expulsion in the rat. Immunology 20: 277-288.
- PRICE, E. W. 1934. Losses among wild ducks due to infestation with *Sphaeridiotrema globulus* (Rudolphi) (Trematoda: Psilostomidae). Proceedings of the Helminthological Society of Washington 1: 31-34.
- ROSCOE, D. E., AND J. E. HUFFMAN. 1982. Trematode (*Sphaeridiotrema globulus*)-induced ulcerative hemorrhagic enteritis in wild mute swans (*Cygnus olor*). Avian Diseases 26: 214-224.
- and ———. 1983. A lethal *Sphaeridiotrema globulus* infection of a whistling swan. Journal of Wildlife Diseases 19: 370-371.
- SAS INSTITUTE, INC. 1987. SAS/STAT guide for personal computers, version 6 edition. SAS Institute Inc., Cary, North Carolina, 1028 pp.
- SPECKMANN, G., A. ROBERTSON, AND W. A. WEBSTER. 1972. *Sphaeridiotrema* flukes, the cause of ulcerative enteritis in a cygnet (*Cygnus olor*). Journal of Wildlife Diseases 8: 1-2.
- STADNYK, A. W., P. J. MCELROY, J. GAULDIE, AND A. D. BEFUS. 1990. Characterization of *Nippostrongylus brasiliensis* infection in different strains of mice. The Journal of Parasitology 76: 377-382.
- TESTI, F. 1962. *Sphaeridiotrema globulus* (Rudolphi, 1814) Odhner, 1913, in *Antra domestica*. Nuova Veterinari 38: 149-153.
- TOREN, D. A. 1963. Toren's method for mast cells. Stain Technology 38: 249-250.
- TRAINER, D. O., AND G. W. FISCHER. 1963. Fatal trematodiasis of coots. The Journal of Wildlife Management 27: 483-486.
- WOODBURY, R. G., H. R. P. MILLER, J. F. HUNTLEY, G. F. NEWLANDS, A. C. PALLISER, AND D. WAKELIN. 1984. Mucosal mast cells are functionally active during spontaneous expulsion of intestinal nematode infections in rats. Nature 312: 450-452.

Received for publication 2 August 1990.