

## **Squamous Cell Carcinoma in a Free-ranging Bighorn Sheep (*Ovis canadensis californiana*)**

Authors: Foreyt, William J., Hullinger, Gordon A., and Leathers, Charles W.

Source: Journal of Wildlife Diseases, 27(3) : 518-520

Published By: Wildlife Disease Association

URL: <https://doi.org/10.7589/0090-3558-27.3.518>

---

BioOne Complete ([complete.BioOne.org](https://complete.BioOne.org)) is a full-text database of 200 subscribed and open-access titles in the biological, ecological, and environmental sciences published by nonprofit societies, associations, museums, institutions, and presses.

Your use of this PDF, the BioOne Complete website, and all posted and associated content indicates your acceptance of BioOne's Terms of Use, available at [www.bioone.org/terms-of-use](https://www.bioone.org/terms-of-use).

Usage of BioOne Complete content is strictly limited to personal, educational, and non - commercial use. Commercial inquiries or rights and permissions requests should be directed to the individual publisher as copyright holder.

---

BioOne sees sustainable scholarly publishing as an inherently collaborative enterprise connecting authors, nonprofit publishers, academic institutions, research libraries, and research funders in the common goal of maximizing access to critical research.

## Squamous Cell Carcinoma in a Free-ranging Bighorn Sheep (*Ovis canadensis californiana*)

William J. Foreyt, Gordon A. Hullinger, and Charles W. Leathers, Department of Veterinary Microbiology and Pathology, Washington State University, Pullman, Washington 99164, USA

**ABSTRACT:** An oral squamous cell carcinoma which invaded maxillary bones with metastasis to the right retropharyngeal lymph node was diagnosed in a free-ranging California bighorn sheep (*Ovis canadensis californiana*) from Washington. Much of the maxillae had been replaced with tumor and reactive tissue, and many teeth were missing or loose. The tumor was predominantly confined to the shape of the maxillary bones and was unusual because it was bilaterally symmetrical.

**Key words:** Squamous cell carcinoma, neoplasia, tumor, histopathology, bighorn sheep, *Ovis canadensis californiana*, case report.

In January 1990, a free-ranging California bighorn sheep (*Ovis canadensis californiana*) was observed to be depressed and weak on a rural road near Loomis, Washington (USA; 48°50'N, 117°15'W). Three days later, it died and was submitted the same day to the Washington Animal Disease Diagnostic Laboratory (Pullman, Washington 99164, USA).

At necropsy, the adult female sheep weighed 37.3 kg and was emaciated. There was a fluctuant subcutaneous swelling over the right metatarsus immediately distal to the hock. The swelling was filled with greenish, caseated material that extended into many pockets. The upper right dental arcade retained only 1 molar which was freely moveable. Only the first premolar was missing from the upper left dental arcade, and the other teeth were loose. Next to these teeth, the gingiva was eroded and ulcerated, and a 1 to 2 cm diameter socket contained a small amount of impacted ingesta. Adjacent tissue was reddened and covered with a thin layer of granulation tissue, and the overlying maxillae were markedly bilaterally thickened and softened. Most of the maxillary bones were replaced by soft tissue. On cut surface, the maxillae contained many chalky

white foci and occasional tracts and pockets of thick white exudate. The mandibles appeared normal. The right retropharyngeal lymph node was greatly enlarged and contained many white miliary foci similar to those in the maxillae.

Internally, body fat was scant or serous. Two cysticerci morphologically compatible with *Taenia hydatigena* were attached to the mesentery in the pelvic region, and cestodes were in the small intestine. Internal tissues were grossly normal.

Histologically, all sections of the oral lesions were similar, characterized by multiple nests and cords of neoplastic epithelial cells which invaded from ulcerated oral mucosa of the hard palate, through the maxillary bones to intact nasal epithelium. Islands of tumor cells were centrally necrotic and often separated by thick bands of fibrous tissue mixed with inflammatory cellular debris (Fig. 1). Tumor cells were large, polygonal and pleomorphic. Nuclei were sometimes multiple, round to oval, stippled to vesiculated, varied greatly in size and often contained multiple prominent nucleoli. Mitotic figures were rarely seen, but were often atypical. Cytoplasm varied from eosinophilic and vacuolated to hyalinized, brightly eosinophilic, and keratinized. Prominent intercellular bridges were identified in some areas. Tumor cells were adjacent to ulcerated oral epithelium and located between poorly mineralized spicules of bone. Over 75% of the maxillary bones had been obliterated by neoplastic cells or replaced by fibrous tissue. Neutrophils were located predominantly next to ulcerated oral mucosa.

In the right retropharyngeal lymph node, normal nodal architecture was effaced by cords and islands of malignant

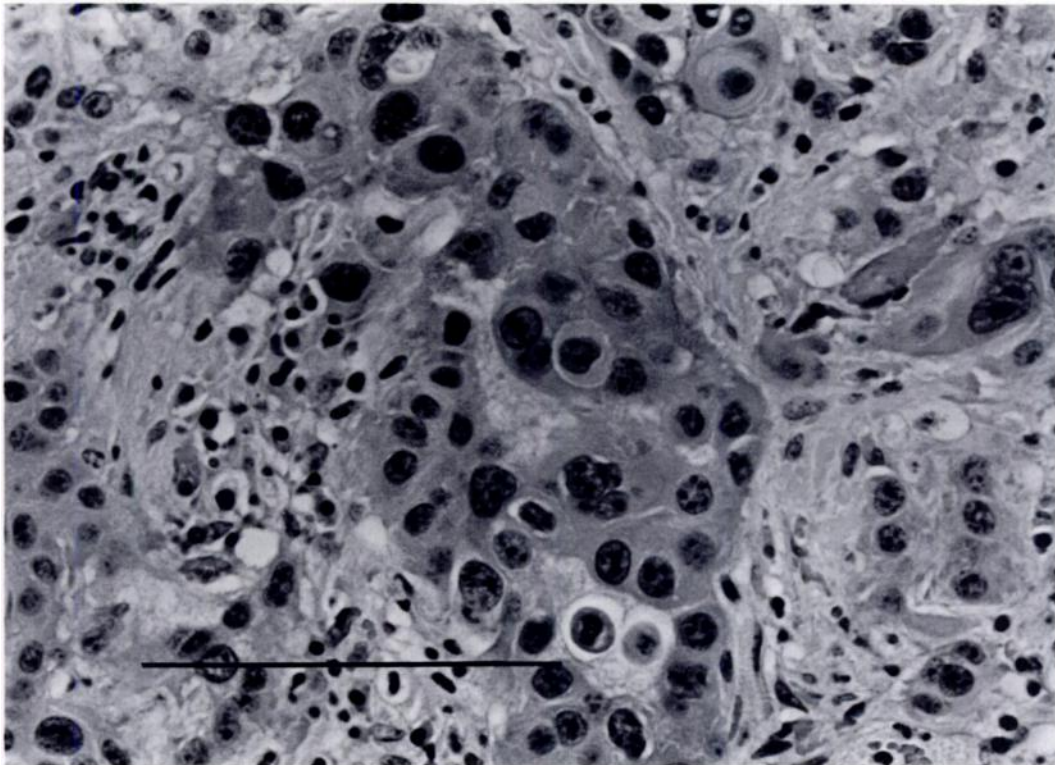


FIGURE 1. Photomicrograph of oral squamous cell carcinoma from a bighorn sheep. Note central island of large tumor cells, surrounded by inflammatory cellular debris. H&E. Bar = 100  $\mu$ m.

epithelial cells morphologically similar to those described previously. Occasional aggregates of lymphoid tissue remained at the margins of the node. The capsule was thickened and many capsular vessels contained tumor emboli.

Hepatic cords contained prominent accumulations of pale amphophilic amorphous material that stained positively for amyloid with Congo red. These deposits were in all portions of hepatic lobules, especially periportally. Renal glomeruli and interstitium also contained accumulations of amyloid. Cardiac and skeletal muscle contained occasional basophilic multinucleate cysts of *Sarcocystis* sp. which were approximately 40  $\times$  80  $\mu$ m, without associated inflammation. Lung, thyroid and mandible were histologically normal.

The destructive mass involving maxillary bones was histologically confirmed as a squamous cell carcinoma with metastasis

to a regional lymph node. A representative paraffin-embedded block of the tumor was deposited in the Registry of Comparative Pathology (Armed Forces Institute of Pathology, Washington, D.C. 20306, USA; Accession Number 2267195). Much of the maxillae had been replaced with tumor cells and reactive fibrous tissue. This tumor was unusual in being bilaterally symmetrical, as well as eroding bone and causing loosening and loss of teeth. Oral epithelium is the likely source of the primary tumor because deep ulcerations were present at the cranial aspects of the right and left upper dental arcades. The neoplasm was well differentiated and remained predominantly confined to the shape of the maxillary bone, without extension through nasal epithelium. Hepatic and renal amyloidosis was considered secondary to chronic inflammation associated with the destructive tumor. Emaciation of the sheep likely re-

sulted from an inability to forage due to the extensive oral lesions.

Few neoplasms have been reported in bighorn sheep. These include adenomas of the pituitary and adrenal glands, and an adenocarcinoma in a bighorn  $\times$  mouflon sheep (*Ovis musimon*), but details of these were not reported (Williams, 1982). Malignant neoplasms have been reported in a variety of wild and domestic ungulates (Cotchin, 1960; Head, 1976; Effron et al., 1977; Ensley et al., 1980; Montali, 1980; Cosgrove et al., 1981; Williams, 1982; Hubbard et al., 1983; Sundberg and McDonald, 1984), but to our knowledge, this is the first squamous cell carcinoma reported in a free-ranging bighorn sheep.

We thank Gordon LaVoy and Jerry King, Washington Department of Wildlife, for assistance in this case.

#### LITERATURE CITED

- COSGROVE, G. E., L. C. SATTERFIELD, AND V. F. NETTLES. 1981. Neoplasia. In *Diseases and parasites of white-tailed deer*, W. R. Davidson, F. R. Hayes, V. A. Nettles, and F. E. Kellog (eds.). Miscellaneous Publication Number 7, Tall Timbers Research Station, Tallahassee, Florida, pp. 62-71.
- COTCHIN, E. 1960. Tumours of farm animals: A survey of tumours examined at the Royal Veterinary College, London, during 1950-1960. *Veterinary Record* 72: 816-822.
- EFFRON, M., L. GRINER, AND K. BENIRSCHKE. 1977. Nature and rate of neoplasia found in captive wild animal, birds, and reptiles at necropsy. *Journal of the National Cancer Institute* 59: 185-194.
- ENSLEY, P. K., D. L. JANSSEN, AND M. P. ANDERSON. 1980. Squamous cell carcinoma in an Indochina sika deer. *Journal of the American Veterinary Medical Association* 177: 932.
- HEAD, K. W. 1976. Tumours of the upper alimentary tract. *Bulletin of the World Health Organization* 53: 145-166.
- HUBBARD, G. B., R. E. SCHMIDT, AND K. C. FLETCHER. 1983. Neoplasia in zoo animals. *Journal of Zoo Animal Medicine* 14: 33-40.
- MONTALI, R. J. 1980. An overview of tumors in zoo animals. In *The comparative pathology of zoo animals*, R. J. Montali and G. Migaki (eds.). Smithsonian Institution Press, Washington, D.C., pp. 531-547.
- SUNDBERG, J. P., AND S. E. McDONALD. 1984. Squamous cell carcinoma of the cervix in a black-buck. *Journal of the American Veterinary Medical Association* 185: 1445-1446.
- WILLIAMS, E. S. 1982. Neoplasias. In *Diseases of wildlife in Wyoming*, 2nd ed., E. T. Thorne, N. Kingston, W. R. Jolley, and R. C. Bergstrom (eds.). Wyoming Fish and Game Department, Cheyenne, Wyoming, pp. 261-269.

*Received for publication 30 July 1990.*