

## **DESCRIPTIVE EPIZOOTIOLOGICAL STUDY OF EUROPEAN BROWN HARE SYNDROME IN SWEDEN**

Authors: Gavier-Widén, Dolores, and Mörner, Torsten

Source: Journal of Wildlife Diseases, 29(1) : 15-20

Published By: Wildlife Disease Association

URL: <https://doi.org/10.7589/0090-3558-29.1.15>

---

BioOne Complete ([complete.BioOne.org](https://complete.BioOne.org)) is a full-text database of 200 subscribed and open-access titles in the biological, ecological, and environmental sciences published by nonprofit societies, associations, museums, institutions, and presses.

Your use of this PDF, the BioOne Complete website, and all posted and associated content indicates your acceptance of BioOne's Terms of Use, available at [www.bioone.org/terms-of-use](https://www.bioone.org/terms-of-use).

Usage of BioOne Complete content is strictly limited to personal, educational, and non - commercial use. Commercial inquiries or rights and permissions requests should be directed to the individual publisher as copyright holder.

---

BioOne sees sustainable scholarly publishing as an inherently collaborative enterprise connecting authors, nonprofit publishers, academic institutions, research libraries, and research funders in the common goal of maximizing access to critical research.

## DESCRIPTIVE EPIZOOTIOLOGICAL STUDY OF EUROPEAN BROWN HARE SYNDROME IN SWEDEN

Dolores Gavier-Widén and Torsten Mörner

Department of Wildlife Diseases, The National Veterinary Institute, Box 7073, S-75007 Uppsala, Sweden

**ABSTRACT:** A study on descriptive epizootiology of the viral necrotising hepatitis of hares, European brown hare syndrome (EBHS) was conducted in Sweden. Two thousand eight hundred eighteen hares were necropsied between 1980 and 1989. European brown hare syndrome was diagnosed histologically in 234 (14%) of 1644 European brown hares (*Lepus europaeus*) and 26 (3%) of 958 varying hares (*Lepus timidus*). Most cases occurred in October, November, and December. In 1980, the first cases were recorded on the island Gotland and in 1981 EBHS occurred on the mainland in the south of Sweden. In the following years it spread northward up to the Nordic limit (*Limes norrlandicus*), which marks the transition of climate, topography, fauna and flora, between central Sweden and Norrland. By 1989 EBHS was restricted to the southern terrain, overlapping the distribution of the population of European brown hares, and it occurred in 23.2% of the hares received for post-mortem examination at the National Veterinary Institute of Sweden.

**Key words:** European brown hare syndrome, necrotising hepatitis, rabbit viral hemorrhagic disease, hare, rabbit, *Lepus europaeus*, *Lepus timidus*.

### INTRODUCTION

The European brown hare syndrome (EBHS) was first observed in Sweden in the early 1980's as a new disease characterized by severe liver damage of unknown cause. In the following years extensive research was carried out to identify the cause of the disease. Pesticides, mycotoxins, selenium levels and new sorts of rape (*Brassica napus*) with low glucosinolate content (called "double zero varieties") were investigated; no conclusive relation between any of these and EBHS was found. Bacteriological, parasitological and virological investigations failed to identify a specific cause of the disease. In 1989, Lavazza and Vecchi (1989) found viral particles in the liver of European brown hares that had died of EBHS, by negative staining immune electron microscopy. Interestingly, these particles were morphologically similar to the virus of "X disease of rabbits" or rabbit viral hemorrhagic disease (RVHD), a disease described in China (Xu and Chen, 1989) and which recently emerged in Europe. Subsequently, the virus first observed by Lavazza was consistently found in the liver of hares that had died of EBHS in the different countries (Chasey and Duff, 1990; Eskens and Volmer, 1989; Gavier-Widén and Mörner,

1991; Morisse et al., 1990). Furthermore, Eskens and Volmer (1989) in Germany; and Gavier-Widén and Mörner (1991) in Sweden reproduced the disease in hares by inoculation with liver homogenates from hares with EBHS. The causative virus of EBHS is a small (30 to 35 nm) icosahedral, non-enveloped and hemagglutinating virus (Gavier-Widén and Mörner, 1991). The clinical and pathological manifestations of EBHS and RVHD are remarkably similar. There is no evidence of natural cross-infection between hares and rabbits; however, there are two reports of experimental successful cross-infection (Modugno and Nasti, 1990; Morisse et al., 1990). The relatedness of the viruses has not yet been completely elucidated, although a partial antigenic relationship has been found (Capucci et al., 1991). No studies have been reported on the genomes of the viruses. The classification of the EBHS and RVHD viruses has been controversial. All attempts to make them grow in tissue culture have been unsuccessful, making the study of the viral properties more difficult. Most European workers have concluded that the RVHD virus is a calicivirus, (Capucci et al., 1990; Ohlinger et al., 1990) while American researchers have classified it as a parvovirus (Gregg and House, 1989).

TABLE 1. Age and sex distribution of 275 hares with European brown hare syndrome.

Sex	Age			Totals
	Adult	Subadult	Young	
Female	100 (36.3%)*	42 (15.3%)	0 (0%)	142 (51.6%)
Male	94 (34.2%)	39 (14.2%)	0 (0%)	133 (48.4%)
Totals	194 (70.5%)	81 (29.5%)	0 (0%)	275 (100%)

\*Number and percent of the total for each category.

The liver lesions of EBHS are very characteristic and their histological identification provide a reliable diagnosis. Viral antigen is consistently detected in these cases. In one study, EBHS antigen was found in the liver of all the hares with typical EBHS lesions (Gavier-Widén, 1992). The EBHS virus also can be seen by negative staining electron microscopy in many hares having typical EBHS liver lesions (Poli et al., 1991). Periportal hepatocytic coagulation necrosis with foci of hepatocellular lysis, acidophilic bodies, granular accumulation of calcium in the hepatocytes and a scanty inflammatory infiltrate are changes observed in hares that die of EBHS (Gavier and Mörner, 1989; Gustafsson et al., 1989). Other pathological changes include lung edema, congestion of tracheal mucosa and organs, and occasional petechia, probably related to shock and terminal disseminated intravascular coagulation. Confirmatory diagnostic techniques involve detection of virus in organ homogenates by hemagglutination, negative staining electron microscopy and enzyme-linked immunosorbent assay (ELISA), using rabbit anti-RVHD hyperimmune serum as a catcher and as a tracer or using a mixture of monoclonal antibodies (Capucci et al., 1991). In the recent years, increasing awareness of EBHS led the way to investigation and reporting in many countries. European brown hare syndrome has, to date, been reported in Sweden (Gavier and Mörner, 1989; Gustafsson et al., 1989), Denmark (Henriksen et al., 1989), Belgium (Okerman et al., 1989), Italy (Marcato et al., 1989), Yugoslavia (Sostaric et al., 1991), Great Britain

(Chasey and Duff, 1990), Germany (Es-kens and Volmer, 1989) and France (Morrisse, 1988). European brown hare syndrome today is widely recognized as the cause of death of an apparently large number of free-living and farm-raised hares in Europe. However, the epizootiological aspects of the disease are poorly understood. Our objective was to provide information about host susceptibility, and the temporal and geographic distribution of EBHS in free-living hares in Sweden.

#### MATERIALS AND METHODS

We evaluated 1,644 European brown hares (*Lepus europaeus* Pallas), 958 varying hares (*Lepus timidus* Linné) and 216 hares with species not determined (*Lepus* spp.) received for post-mortem examination from Sweden at The National Veterinary Institute, Uppsala, Sweden, from the 1 January 1980 to 31 December 1989. During necropsy, samples of liver from each hare were fixed in 10% neutral buffered formalin. The tissues were trimmed and processed by routine paraffin technique, and were cut at 4  $\mu$ m. All sections were stained with hematoxylin and eosin and in some cases additional sections were stained using the von Kossa method (Luna, 1968). The diagnosis of EBHS was based on characteristic histological lesions in the liver. The distribution of the EBHS cases were evaluated by sex, age, species, body weight, geographical location, temporal distribution and seasonality. The hares were classified in three age groups. Hares with fully developed gonads were considered adults, hares with gonads not fully developed, subadults (approximately 3 wk to 6 mo) and hares whose stomachs contained milk, young (up to 3 wk).

#### RESULTS

A total of 275 cases were identified as EBHS. Overall, the proportion of EBHS cases for the 10 years of the study, was

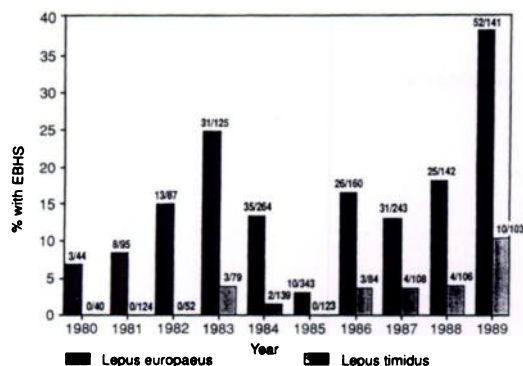


FIGURE 1. Proportion of the examined European brown hares (*Lepus europaeus*) and varying hares (*Lepus timidus*) with European brown hare syndrome per year. Numbers on the bars: number of EBHS cases/number of hares examined.

substantially higher in European brown hares than in varying hares. We diagnosed EBHS in 234 (14%) of 1,644 European brown hares, in 26 (2.7%) of 958 varying hares, and in 15 (6.9%) of 216 unidentified hares.

No cases of EBHS occurred in young hares (Table 1). There was no significant difference ( $P > 0.05$ ) in the proportion of cases in males and females. European brown hare syndrome occurred in a considerably higher proportion of the European brown hares than of the varying hares examined. Considering each year separately, during 1980, 1981 and 1982, EBHS was detected only in European brown hares (Fig 1). In 1983, EBHS was detected for the first time in varying hares and was diagnosed in 3.8% of the total number of the varying hares examined that year. Few cases occurred in varying hares every year until 1989, when they composed 9.7% of the cases.

For European brown hares with EBHS, the median body weight was 3,470 g, and ranged from 1,920 g to 4,460 g. For varying hares the median value was 3,120 g, ranging from 2,220 to 4,000 g. For comparison, the median body weight of 220 apparently healthy, free-ranging adult European brown hares shot in three areas of Sweden for a health monitoring study

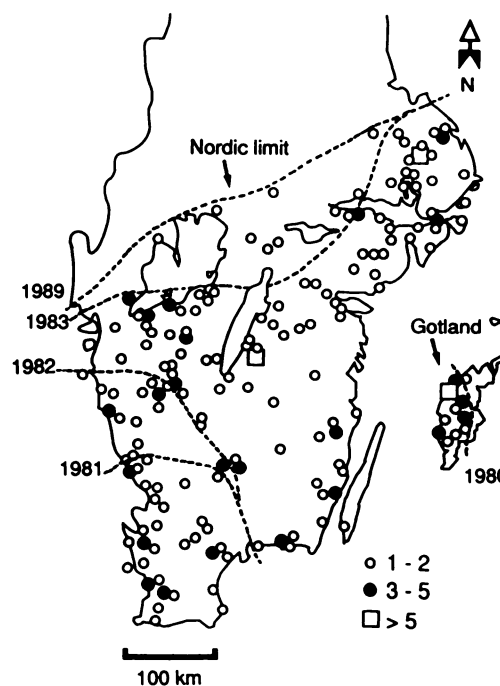


FIGURE 2. Location of 275 cases of European brown hare syndrome in southern Sweden from 1980 to 1989. *Lepus europaeus* bagged (□), *Lepus timidus* bagged (○), % of hares examined that had EBHS (■).

was 4,000 g, with a range of 2,000 to 5,600 g (Mörner, unpubl. data).

All cases of EBHS occurred in the southernmost third of Sweden, between the latitudes 60°20'N and 55°15'N (Fig. 2). The distribution of EBHS overlapped the distribution of the population of European brown hares and part of that of varying hares (Björvall and Ullström, 1985).

There was no apparent correlation between hunting success as an index of hare populations and the occurrence of EBHS (Swedish Sportmans Association, 1991) (Fig. 3). European brown hare syndrome occurred throughout the year but was most frequent during October, November and December (Fig. 4).

## DISCUSSION

It is difficult to speculate on how and where EBHS originated. It is not known if EBHS occurred in Sweden before 1980. In the fall of 1986, EBHS was responsible

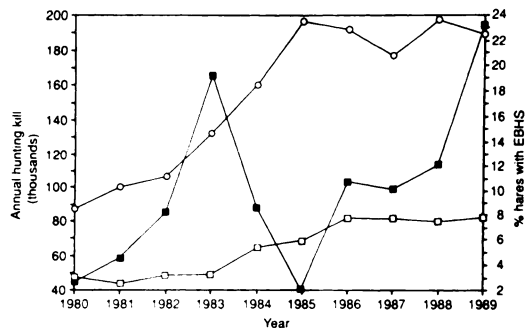


FIGURE 3. Annual hunting kill for European brown hares (*Lepus europaeus*) and varying hares (*Lepus timidus*) in Sweden and percentage of hares with EBHS of the total number of hares examined at the National Veterinary Institute (Sweden) annually, 1980 to 1989.

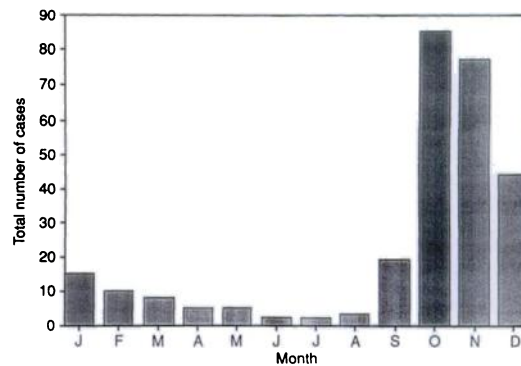


FIGURE 4. Seasonal distribution of 275 cases of European brown hare syndrome diagnosed at the National Veterinary Institute (Sweden) from 1980 to 1989.

for the death of a large number of hares in central Europe (Eskens et al., 1987; Poli et al., 1991). Currently (1992) the disease has been recognized and reported in most European countries. In Sweden, the first three recognized cases occurred on the island Gotland (56°54' to 58°00'N, 18°05' to 19°20'E) in 1980. In 1981 EBHS occurred on the mainland in the south of Sweden. In the following years EBHS extended northward to the geographical and climatic border called the Nordic limit (*Limes norrlandicus*), which marks the transition of climate, topography fauna and flora, between central Sweden and Norrland (Fig. 2). European brown hare syndrome is, to this date, confined to the south of this limit. The distribution of EBHS may be limited by the reservoir host species that inhabits only the southern terrain. European brown hare syndrome does not seem to occur in areas where European brown hares are absent, such as northern Sweden, Finland and Norway. Perhaps EBHS was originally a disease of European brown hares that extended to the population of varying hares. Perhaps European brown hares with chronic forms of EBHS continue shedding virus for long periods, acting as long term carriers and reservoirs, whereas varying hares are more susceptible and die more acutely. The higher frequency of EBHS in brown hares than in varying

hares may be explained if the disease were endemic in the population of brown hares and the occurrence of EBHS in varying hares was only accidental. The two species of hares occur in different habitats. European brown hares are grazers and live predominantly in agricultural fields while varying hares are browsers and inhabit forests. Therefore the contact between the two species is very limited, and occurs mostly at the margins of forest areas. The proportion of varying hares affected by EBHS in southern Sweden increased in 1989 to 9.7% and in 1990 to 13.8% (Gavier-Widén, unpubl.). The reasons are not clear; however, it might signify that the virus is adapting to the varying hare. Since EBHS is an infectious disease, cases should be more common in years when hares are abundant. However, there was a peak of cases of EBHS in 1983 and very few cases in 1985 (Fig. 3). At the same time the annual hunting kill increased during those years, reflecting more dense hare populations. Thus, factors other than population density, such as climate, may influence the occurrence of EBHS. In 1985, the winter was particularly severe, the large amounts of snow may have reduced the spread of EBHS-virus by reducing contact between hares.

In our study, EBHS occurred only in adult and subadult hares, and was most

common in adult hares. No cases were found in young hares. Passive maternal immunological protection may account for the lack of cases in very young hares. We have found hemagglutination inhibition antibodies against EBHS in recently born hares in endemic areas (Gavier-Widén and Mörner, 1991). However, it is not known how long the passive protection lasts. The body weight distribution of hares with EBHS appeared to have lower values than those for normal hares, indicating that the disease may cause weight loss. Alternatively, the lower weight of EBHS-affected hares may reflect higher susceptibility of stressed animals (from poor nutrition, pesticides or chronic diseases) to infection with EBHS virus.

The high occurrence of EBHS in October, November and December, may be related to the high hare density at this time of the year. A comparable pattern is seen in other infectious diseases of hares in Sweden, such as tularemia, in which a concentration of cases occurs between August and November and the seasonality is attributed to mosquito transmission (Mörner et al., 1988). No studies have been made on possible vector transmission of EBHS. Other factors that may contribute to the seasonality of EBHS are the presence of high number of susceptible young hares that have lost the passive maternal protection; the concentration of hares in marginal areas for grazing following the harvest of agricultural crops; and the fact that dead hares are more likely to be found at this time of the year, when the hunters are out in the fields and forests.

Despite the high density of the population of both wild rabbits and hares co-existing on the island of Gotland, no wild rabbits were found with liver damage resembling EBHS until 1990, when RVHD was introduced, indicating that natural infection of wild rabbits with EBHS virus does not occur. The reason why the first cases of both EBHS and RVHD were recognized on the same island, is not clear. There is no natural movement of hares and

wild rabbits between mainland and the island Gotland. Perhaps migrating birds introduced the virus onto Gotland, as was reported for myxomatosis in Sweden (Borg and Bakos, 1963). Even though the importation of rabbits from countries with RVHD was prohibited, an illegal introduction of an infected rabbit can not be excluded.

The effect of EBHS on the size of the population of hares is difficult to evaluate. Mortality and morbidity rates, or total population numbers could not be estimated in this study. Disease prevalence rates based on serosurveys have not yet been investigated. However, the most common disease causing death in free living hares is currently EBHS. In spite of this, the number of hares shot in Sweden in the last few years has increased, indicating that presently EBHS is probably not causing drastic reduction in the population of hares.

#### LITERATURE CITED

- BJÄRVALL, A., AND S. ULLSTRÖM. 1985. Däggdjur. Alla Europas arter. Wahlström och Widstrand, Stockholm, Sweden, pp. 1–240.
- BORG, K., AND K. BAKOS. 1963. Dissemination of myxomatosis by birds. *Nordisk Veterinärmedicin* 15: 159–166.
- CAPUCCI, L., M. T. SCICLUNA, A. LAVAZZA, AND E. BROCCHI. 1990. Purification and characterization of the causative agent of viral hemorrhagic disease of rabbit. *Selezione Veterinaria* 31: 301–312.
- , ———, AND ———. 1991. Diagnosis of viral hemorrhagic disease of rabbits and the European brown hare syndrome. *Revue Scientifique et Technique O.I.E.* 10: 347–370.
- CHASEY, D., AND P. DUFF. 1990. European brown hare syndrome and associated virus particles in the UK. *The Veterinary Record* 126: 623–624.
- ESKENS, U., AND K. VOLMER. 1989. Investigations on the etiology of liver dystrophy in brown hare (*Lepus europaeus* Pallas). *Deutsche Tierärztliche Wochenschrift* 96: 433–472.
- , H. KLIMA, J. NILZ, AND D. WIEGAND. 1987. Liver dystrophy in hares. Pathological and epidemiological research of frequently occurring deaths of hares in Central Hesse. *Tierärztliche Praxis* 15: 229–235.
- GAVIER, D., AND T. MÖRNER. 1989. The European brown hare syndrome in Sweden. In *Proceedings 31. Internationalen Symposiums über die Er-*

- krakungen der Zoo- und Wildtiere. Dortmund, Federal Republic of Germany, pp. 261–264.
- GAVIER-WIDÉN, D. 1992. Epidemiology, pathology and pathogenesis of two related viral hepatitis of leporids. Dissertation Abstracts International (in press).
- , AND T. MÖRNER. 1991. Epidemiology and diagnosis of European brown hare syndrome in Scandinavian countries: a review. *Revue Scientifique et Technique O.I.E.* 10: 453–458.
- GREGG, D. A., AND C. HOUSE. 1989. Necrotic hepatitis of rabbits in Mexico: A parvovirus. *The Veterinary Record* 125: 603–604.
- GUSTAFSSON, K., T. SVENSSON, AND A. UGGLA. 1989. Studies on an idiopathic syndrome in the brown hare (*Lepus europaeus* P.) and mountain hare (*Lepus timidus* L.) in Sweden, with special reference to hepatic lesions. *Journal of Veterinary Medicine A* 36: 631–637.
- HENRIKSEN, P., D. GAVIER, AND F. ELLING. 1989. Acute necrotising hepatitis in Danish farmed hares. *The Veterinary Record* 125: 486–487.
- LAVAZZA A., AND G. VECCHI. 1989. Osservazioni su alcuni episodi di mortalità nelle lepri. Evidenziazione al microscopio elettronico di una particella virale. Nota preliminare. *Selezione Veterinaria* 30: 461–467.
- LUNA, L. G. (editor). 1968. Manual of histologic staining methods of the Armed Forces Institute of Pathology, 3rd ed. McGraw Hill Company, New York, New York, 258 pp.
- MARCATO, P. S., C. BENAZZI, M. GALEOTTI, AND L. SALDA DELLA. 1989. Infective necrotic hepatitis of leporids. *Rivista di Coniglicultura* 26: 41–50.
- MODUGNO, G. D., AND R. NASTI. 1990. Viral hemorrhagic disease of rabbits in Apulia, experimental infection of rabbits and hares. *Rivista di Coniglicultura* 27: 25–32.
- MORISSE, J. P. 1988. Hemorrhagic septicemia syndrome in rabbits: First observations in France. *Le Point Vétérinaire* 20: 79–83.
- , J. P. PICAULT, E. BOILLETOT, AND M. MORIN. 1990. Etiological relationship between the European brown hare syndrome (EBHS) and the viral hemorrhagic disease in rabbits (VHD). *Revue Médecine Vétérinaire* 141: 463–467.
- MÖRNER, T., G. SANDSTRÖM, R. MATTSSON, AND P. NILSSON. 1988. Infections with *Francisella tularensis* biovar *palaeartica* in hares (*Lepus timidus*, *Lepus europaeus*) from Sweden. *Journal of Wildlife Diseases* 24: 422–433.
- OHLINGER, V. F., B. HAAS, G. MEYERS, F. WEILNAD, AND H. J. THIEL. 1990. Identification and characterization of the virus causing rabbit hemorrhagic disease. *Journal of Virology* 64: 3331–3336.
- OKERMAN, L., P. VAN DE KERCKHOVE, S. OSAER, L. DEVRIESE, AND E. UYTTEBROEK. 1989. European brown hare syndrome in captive hares (*Lepus capensis*) in Belgium. *Vlaams Diergeneeskundig Tijdschrift* 58: 44–46.
- POLI, A., M. NIGRO, D. GALLAZZI, G. SIRONI, A. LAVAZZA, AND D. GELMETTI. 1991. Acute hepatitis in the European brown hare (*Lepus europaeus*) in Italy. *Journal of Wildlife Diseases* 27: 621–629.
- SOSTARIC, B., Z. LIPEJ, AND R. FUCHS. 1991. The disappearance of free living hares in Croatia: 1. European brown hare syndrome. *Veterinarski Arhiv* 61: 133–150.
- SWEDISH SPORTSMANS ASSOCIATION. 1991. Report annual bag for Swedish game. Svenska Jägareförbundet, Box 1, S-16321 Spånga, Sweden, 130 pp.
- XU, Z. J., AND W. X. CHEN. 1989. Viral hemorrhagic disease in rabbits: A review. *Veterinary Research Communications* 13: 205–212.

Received for publication 18 June 1991.