

Syndactylism and Brachygnathia in a White-tailed Deer

Author: Rollor, Edward A.

Source: Journal of Wildlife Diseases, 29(4) : 618-619

Published By: Wildlife Disease Association

URL: <https://doi.org/10.7589/0090-3558-29.4.618>

BioOne Complete (complete.BioOne.org) is a full-text database of 200 subscribed and open-access titles in the biological, ecological, and environmental sciences published by nonprofit societies, associations, museums, institutions, and presses.

Your use of this PDF, the BioOne Complete website, and all posted and associated content indicates your acceptance of BioOne's Terms of Use, available at www.bioone.org/terms-of-use.

Usage of BioOne Complete content is strictly limited to personal, educational, and non - commercial use. Commercial inquiries or rights and permissions requests should be directed to the individual publisher as copyright holder.

BioOne sees sustainable scholarly publishing as an inherently collaborative enterprise connecting authors, nonprofit publishers, academic institutions, research libraries, and research funders in the common goal of maximizing access to critical research.

Syndactylism and Brachygnathia in a White-tailed Deer

Edward A. Rollor, III, Southeastern Cooperative Wildlife Disease Study, College of Veterinary Medicine, The University of Georgia, Athens, Georgia 30602, USA

ABSTRACT: A white-tailed deer (*Odocoileus virginianus*) fawn was presented to the Southeastern Cooperative Wildlife Disease Study for examination of brachygnathia and syndactylous front feet. The hoof keratin of digits 3 and 4 was completely fused and typical sole integument covered the palmar surface between the primary digits. Based on a radiographic examination, there was fusion of the epiphyses of the first phalanges of digits 3 and 4 in both feet. In

the right foot the proximal metaphyses of the first phalanges of digits 3 and 4 were fused.

Key words: *Odocoileus virginianus*, white-tailed deer, brachygnathia, syndactylism.

On 6 June 1979 a 12-day-old (Haugen and Speake, 1958), female, white-tailed deer (*Odocoileus virginianus*) with syndactylous front feet and brachygnathia was

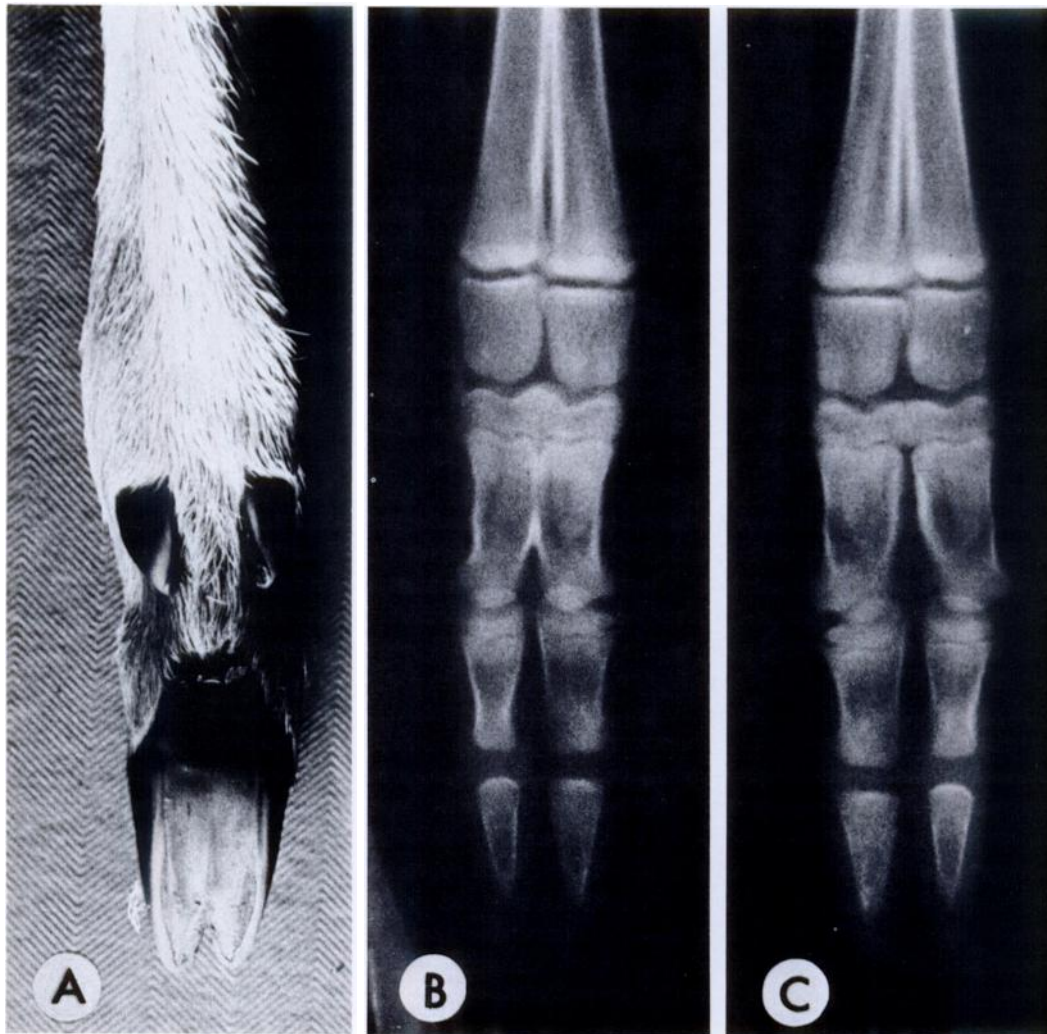


FIGURE 1. Syndactylous front feet of a female white-tailed deer fawn. A) Palmar view of right foot. B) Dorsopalmar radiograph of right foot. C) Dorsopalmar radiograph of left foot.

submitted to the Southeastern Cooperative Wildlife Disease Study, Athens, Georgia (USA), for examination. The fawn was found in Wayne County, Georgia (31°40'N, 81°50'W). The deer was in good condition and did not exhibit difficulties in walking or eating. The incisors of the lower jaw met the upper jaw approximately 1 cm behind the normal point of contact. The hoof keratin of both front feet was completely fused at the interdigital clefts of the primary digits (digits 3 and 4). The palmar surface of the fused primary digits was covered with typical sole integument (Fig. 1A). Based on a radiographic examination of the right front foot, there was a fusion of the epiphyses and the proximal metaphyses of the first phalanges of digits 3 and 4 (Fig. 1B). The left front foot did not have a fusion of the metaphyses of the first phalanges, but did have a fusion of the epiphyses of the first phalanges (Fig. 1C).

Three cases of syndactylous feet in roe deer (*Capreolus capreolus*) (Szabo, 1965, as cited by Saperstein et al., 1978) and one case in a South American deer (*Odocoileus virginianus peruvianus*) (Lonnberg, 1930, as cited by Harris, 1975) have been reported. Syndactylism has not been reported previously in North American cervids.

Brachygnathism has been reported in mule deer (*O. hemionus*) (Robinette and Aldous, 1955; Short, 1964) and white-tailed deer (Johnson, 1935; Ryel, 1963; Scanlon, 1973; Wobeser and Runge, 1973; Barrett and Chalmers, 1975; Smits and Bubenik, 1990). Reports of limb deformities other than syndactylism accompanied by brachygnathia have been arthrogryposis (Barrett and Chalmers, 1975), limb rotation (Scanlon, 1973; Wobeser and Runge, 1973), and osteopetrosis (Smits and Bubenik, 1990). Smits and Bubenik (1990) suggested that inferior brachygnathia may be a phenotypic marker for the lesions of osteopetrosis and should be considered in populations where inbreeding occurs.

This study was supported by an appro-

priation from the Congress of the United States to the Southeastern Cooperative Wildlife Disease Study, College of Veterinary Medicine, The University of Georgia, Athens, Georgia. Funds were administered and research coordinated under the Federal Aid to Wildlife Restoration Act (50 Stat. 917) through Contract Number 14-16-0004-99-916, Fish and Wildlife Service, U.S. Department of the Interior. The author is grateful to Dr. Royce E. Roberts, Dr. Lynn E. Hayes, and Dr. Gail L. Mahnke for their interpretations of the radiographs.

LITERATURE CITED

- BARRETT, M. W., AND G. A. CHALMERS. 1975. Congenital anomalies in a neonatal white-tailed deer in Alberta. *Journal of Wildlife Diseases* 11: 497-501.
- HARRIS, S. 1975. Syndactyly in the red fox, *Vulpes vulpes*. *Journal of Zoology* 176: 282-287.
- HAUGEN, A. O., AND D. W. SPEAKE. 1958. Determining age of young fawn white-tailed deer. *The Journal of Wildlife Management* 22: 319-321.
- JOHNSON, C. E. 1935. Abnormal mandible in white-tailed deer. *Journal of Mammalogy* 16: 69-70.
- ROBINETTE, W. L., AND C. M. ALDOUS. 1955. "Parrot Mouth" in Rocky Mountain mule deer. *Journal of Mammalogy* 36: 308-310.
- RYEL, L. A. 1963. The occurrence of certain anomalies in Michigan white-tailed deer. *Journal of Mammalogy* 44: 79-98.
- SAPERSTEIN, G., H. W. LEIPOLD, S. M. KRUCKENBERG, AND N. A. MUCKENHIRN. 1978. Congenital defects of wild and zoo mammals. *Institute of Laboratory Animal Research News* 20: 2-23.
- SCANLON, P. F. 1973. Abnormalities of mandibles and of limbs in white-tailed deer from Virginia. *Proceedings of the Southeastern Association of Game and Fish Commissioners* 27: 301-302.
- SHORT, H. L. 1964. Notes and comments on mandibular malformations in deer. *Journal of Mammalogy* 45: 319-321.
- SMITS, B., AND G. A. BUBENIK. 1990. Congenital osteopetrosis in white-tailed deer (*Odocoileus virginianus*). *Journal of Wildlife Diseases* 26: 567-571.
- WOBESER, G., AND W. RUNGE. 1973. Multiple anomalies in a white-tailed deer fetus. *Journal of Wildlife Diseases* 9: 356-358.

Received for publication 7 January 1991.