

DEGENERATIVE LEUKOENCEPHALOPATHY AND MYELOPATHY IN DASYURIDS

Authors: Holz, Peter H., and Little, Peter B.

Source: Journal of Wildlife Diseases, 31(4) : 509-513

Published By: Wildlife Disease Association

URL: <https://doi.org/10.7589/0090-3558-31.4.509>

BioOne Complete (complete.BioOne.org) is a full-text database of 200 subscribed and open-access titles in the biological, ecological, and environmental sciences published by nonprofit societies, associations, museums, institutions, and presses.

Your use of this PDF, the BioOne Complete website, and all posted and associated content indicates your acceptance of BioOne's Terms of Use, available at www.bioone.org/terms-of-use.

Usage of BioOne Complete content is strictly limited to personal, educational, and non - commercial use. Commercial inquiries or rights and permissions requests should be directed to the individual publisher as copyright holder.

BioOne sees sustainable scholarly publishing as an inherently collaborative enterprise connecting authors, nonprofit publishers, academic institutions, research libraries, and research funders in the common goal of maximizing access to critical research.

DEGENERATIVE LEUKOENCEPHALOPATHY AND MYELOPATHY IN DASYURIDS

Peter H. Holz^{1,2,3} and Peter B. Little¹

¹ Department of Pathology, Ontario Veterinary College, University of Guelph, Guelph, Ontario, Canada N1G 2W1

² Metropolitan Toronto Zoo, P.O. Box 280, West Hill, Ontario, Canada M1E 4R5

³ Healesville Sanctuary, P.O. Box 248, Healesville, Victoria 3777, Australia

ABSTRACT: From June 1985 to November 1992 eight eastern quolls (*Dasyurus viverrinus*) and six Tasmanian devils (*Sarcophilus harristii*), held at institutions in Australia and Canada, developed progressive blindness and posterior paresis progressing to paralysis. All were aged individuals. At necropsy white matter tracts, particularly in the spinal cord, optic tracts, and cerebellum, contained evidence of severe axon degeneration with vacuolation and macrophage infiltration. The surrounding tissue had evidence of gliosis. The etiology of the condition is unknown but may be a form of age-related degeneration.

Key words: Axonopathy, age, *Dasyurus viverrinus*, eastern quoll, *Sarcophilus harristii*, Tasmanian devil, marsupial.

INTRODUCTION

The dasyurids are a group of carnivorous marsupials, ranging in size from the diminutive flat-skulled marsupial mouse (*Planigale tenuirostris*) to the two largest members, the eastern quoll (*Dasyurus viverrinus*) and the Tasmanian devil (*Sarcophilus harristii*) (Nowak and Paradiso, 1983).

Maximum longevity of the eastern quoll in the wild is approximately 2 yr, whereas the Tasmanian devil can live for up to 4 yr (Obendorf, 1993). However, in captivity individuals tend to live much longer; a maximum of 6 yr has been recorded for the eastern quoll and 8 yr for the Tasmanian devil (Nowak and Paradiso, 1983). As a consequence, age-related diseases are being recognized with increasing frequency. These include intervertebral disc disease and neoplasia, the latter occurring with unusual frequency in this group of animals (Attwood and Woolley, 1973; Griner, 1979).

We present the first known report of a degenerative neurological disease in eastern quolls and Tasmanian devils.

MATERIALS AND METHODS

Individuals in this study originated from three zoological institutions in Australia: Healesville Sanctuary, Healesville, Victoria (37°40'S,

145°30'E); Taronga Park Zoo, Sydney, New South Wales (33°48'S, 151°20'E); Tasmanian Wildlife Park, Mole Creek, Tasmania (41°25'S, 147°10'E); and from a zoo in Canada: Metropolitan Toronto Zoo, Toronto, Ontario (43°30'N, 79°30'W). Six of the eastern quolls (Q1 through Q6), three males and three females, were part of the animal collection at Healesville Sanctuary and developed symptoms between June 1985 and January 1987. Three of these quolls were wild caught as adults and their ages were unknown. However, at the time of death all had been in the collection for at least 4 yr. The youngest quoll of known age to be affected was 42-mo-old at the time of onset. The quolls were housed in two buildings. One was an enclosed structure within the nocturnal house, designed for public display, and the other was an off-exhibit pen enclosed by wire but with access to the outside. Quolls frequently were moved between the two areas. Their diet consisted of chickens, mice, rats, hard boiled eggs, dog chow, and a multivitamin supplement.

Tissues from quolls Q7 and Q8 were submitted from Taronga Park Zoo. They were affected in April 1987 and June 1989 respectively, and represented a geriatric male and a geriatric female of unknown ages.

All quolls affected with the neurological condition were euthanized by intravenous administration of an overdose of pentobarbitone sodium (Lethobarb, 325 mg/ml, Virbac Pty. Ltd., Peakhurst, New South Wales, Australia). Complete necropsies were performed, and samples were taken of brain, spinal cord for Q8 only, lung, liver, kidney, spleen, pancreas, adrenal, and any grossly detected masses; spinal cord was sampled for Q8 only. Tissues were fixed in 10% neutral buffered formalin, embedded in paraf-

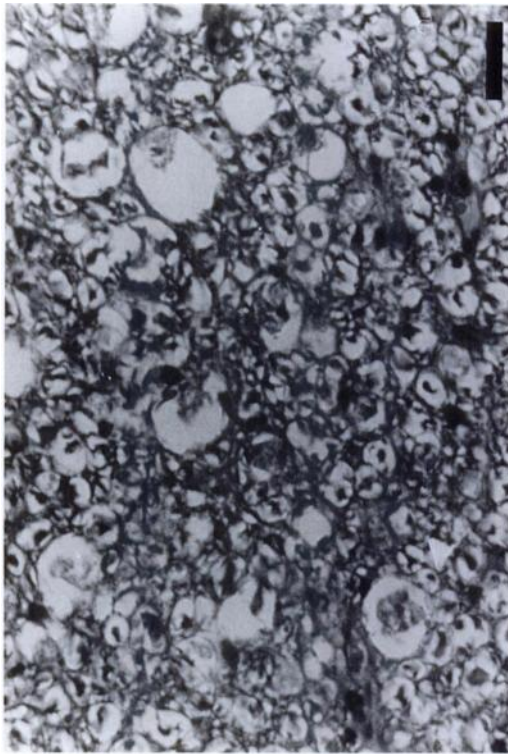


FIGURE 1. Spinal cord of a Tasmanian devil. Note vacuoles containing axonal debris and macrophages. H&E. Bar = 15 μ m.

fin, cut in 6 μ m sections, and stained with hematoxylin and eosin (Allen, 1992).

Possible exposure of the quolls at Healesville Sanctuary to dieldrin was investigated. Rat livers, chicken livers, and sawdust on the floor of the exhibit were assayed by gas liquid chromatography with electron capture detection (Varium 3400, Mulgrave, Victoria, Australia) by the State Chemistry Laboratory (East Melbourne, Victoria, Australia).

Five Tasmanian devils (TD1 through TD5), three males and two females, were housed indoors at the Metropolitan Toronto Zoo, either on exhibit or in a holding area. Their diet consisted of rats, chickens, mice, horsetails, a vitamin supplement and a carnivore mixture formulated by the zoo. Affected Tasmanian devils were seen from June 1985 until November 1992, minimum age of onset of symptoms was 50 mo. All devils were euthanized by intravenous administration of an overdose of T61 (Hoechst Canada Inc., Regina, Saskatoon, Canada). Central nervous system tissue was not available for histological examination from one Tasmanian devil (TD2).

The sixth Tasmanian devil (TD6) was a male,

51-mo-old, submitted from the Tasmanian Wildlife Park in October 1992.

Tissues, including brain, spinal cord, lung, liver, spleen, heart, adrenal, kidney, and any grossly detected masses, from affected devils were treated as described for the quolls.

RESULTS

All affected quolls had similar clinical signs and the disease progressed along the same course. The initial symptoms included a decrease in menace response and an apparent lack of awareness of humans being present in their vicinity. This was accompanied by a swaying gait in the hindquarters which progressed gradually, over a period of several months, to paresis and eventually total hindquarter paralysis. Simultaneously, the quolls became blind and anorexic leading to emaciation and the decision to euthanize the animals.

The Tasmanian devils had clinical signs similar to those observed in the quolls. However, anorexia was not observed and all devils were in good condition prior to euthanasia.

On histological examination, lesions were similar in both groups of marsupials. Spinal cord was available for examination in only one of the quolls (Q8). In the Tasmanian devils, and this particular quoll, the cords contained a severe diffuse axonopathy. Marked vacuolation was visible in the dorsal, lateral, and ventral funiculi of the white matter of the spinal cord. These lesions were detected throughout the cord extending from the cervical to the lumbar areas, and did not differ appreciably in their severity.

Some of the vacuoles were empty but others contained wispy eosinophilic debris, swollen axons, and macrophages (Fig. 1). Some macrophage nuclei appeared dark and pyknotic. The surrounding white matter contained a markedly increased number of swollen astrocytes.

Both groups of animals also had white matter lesions in the brain. However, these tended to be more severe in the quolls than in the Tasmanian devils, based on subjec-

tive evaluation of the degree of vacuolation per unit of white matter. The lesions were qualitatively similar to those observed in the spinal cord. Marked vacuolation was visible, particularly in the optic tracts, but also in the cerebellum and, to a lesser extent, in the thalamus, medulla, and telencephalon. Vacuoles contained axonal debris and macrophages. Many of the macrophages appeared large and foamy. Astrocytes were numerous and large, many with copious cytoplasm, indicative of a chronic disease process. There was no histological evidence of nerve cell necrosis. Peripheral nerves were not examined, but there was no gross evidence of muscle wasting.

One Tasmanian devil (TD3) and two eastern quolls (Q3 and Q7) had evidence of vascular siderocalcinosis within the cerebellum.

Dieldrin analysis was negative for the rat livers and sawdust. A level of 0.01 mg/kg was found for the chicken livers.

As all affected individuals were considered old, other lesions also were present. Using histological appearance of the tissue as the basis for diagnosis, one quoll (Q6) had evidence of interstitial pneumonia. Large numbers of macrophages were visible throughout alveolar septa. Two other individuals had squamous cell carcinomas, one at the base of an ear (Q2) and the other adjacent to the cloaca (Q3). Quoll 8 appeared to have a basal cell tumor at the base of an ear. Lesions compatible with a mammary and uterine adenocarcinoma were found in Q7. The central nervous system lesions were complicated in Q1 by the presence of a granulomatous encephalomyelitis. Cysts containing organisms with a histological appearance compatible with *Toxoplasma gondii* zoites were found in the brain, along with perivascular lymphocytic infiltrates. Due to the confounding nature of the lesion this quoll is not included in the study. No evidence of toxoplasmosis was detected histologically in the other quolls.

The quoll (Q6) with the pneumonic le-

sion also had a calcified, fragmented intervertebral disc at the junction of the sixth and seventh lumbar vertebrae. Disc lesions were observed in five of the affected Tasmanian devils. One Tasmanian devil (TD1) had evidence of disc protrusion at the level of the fourth, fifth, and sixth cervical vertebrae. In another case (TD2) the fourth, fifth, and sixth lumbar discs were calcified and a tumor was found which appeared to be histologically compatible with an endometrial adenocarcinoma. A third Tasmanian devil (TD4) had a calcified disc at the level of the twelfth and thirteenth thoracic vertebrae and a fragmented and degenerate disc at the thoracolumbar junction. The fourth Tasmanian devil (TD5) had a protruding disc between the fourth and fifth thoracic vertebrae as well as a scrotal squamous cell carcinoma and an adrenal carcinoma, as indicated by their histological appearance. The final Tasmanian devil (TD6) had prolapsed intervertebral discs from the fourth cervical to the first lumbar vertebrae.

DISCUSSION

We describe degenerative lesions of the central nervous system of eastern quolls and Tasmanian devils. The marsupial brain and spinal cord essentially has the same structure as that of eutherian mammals. The only major difference is the absence of a corpus callosum in marsupials (Barbour, 1977). Consequently the location of the lesions can be extrapolated from eutherian anatomy. The lesions in these dasyurids appeared most severe within the optic tract, cerebellum and, when available for histological examination, spinal cord. This pattern of distribution coincided with the observed clinical signs of hind-quarter paresis and paralysis and apparent blindness.

The etiology of this condition remains unknown. In view of the advanced age of individuals affected, and the fact that no young animals with the disease have been identified, it may represent an age-related degeneration of the central nervous sys-

tem, similar to that described for aging rats (van Steenis and Kroes, 1971; Burek et al., 1976; Burek, 1978). Lesions between the two groups were very similar, although the dasyurids lacked any peripheral nerve lesions or the muscle atrophy observed in the rats. Senile plaques also were absent.

Other authors mention a lumbar polyradiculopathy found in a number of domestic and exotic species (Anderson and King, 1988; Anderson et al., 1989; Anderson et al., 1993). Histologically, these lesions were similar to those found in the dasyurids, but were confined to the lumbar area of the spinal cord and were incidental findings discovered at necropsy. Tissues from clinically healthy dasyurids have not been examined to determine if these lesions can also exist as incidental findings.

One possible alternative etiology is a dietary deficiency. Increased supplementation with thiamine failed to produce any improvements or prevent further cases. However, other dietary supplements were not tried and may be indicated for future cases.

Dieldrin intoxication is unlikely. A minimum of 0.4 mg/kg is required to cause clinical signs in dogs (Gilmour and Synge, 1987). In the samples assayed the chemical was either not detected or found at concentrations too low (0.01 mg/kg) to cause clinical signs. Organophosphates, heavy metals, acrylamide and hexandione can cause similar lesions (Jubb and Huxtable, 1993). Although analyses for these toxins were not performed, it seems unlikely that all the affected individuals were exposed to them in sufficient concentrations to produce neurological disease. Plants of the genera *Stypandra* and *Helichrysum* have produced similar lesions (Everist, 1981), but none of the animals had a known history of exposure.

Interpretation of the results was complicated by the presence of intervertebral disc disease in several of the individuals. However, because of the extensive nature of the condition, involving all sections of the spinal cord as well as areas of the brain,

we rule this out as the primary cause. However, the disc lesions may have exacerbated spinal cord pathology which already was present.

Marsupials are highly susceptible to infections with *Toxoplasma gondii* (Finnie, 1988) and, although one individual may have had a *Toxoplasma* sp. encephalitis, none of the other individuals had any histological evidence of infection.

The cerebellar vascular siderocalcinosis observed in three individuals is an aging phenomenon which has been described in humans, rats, a Senegal bushbaby (*Galago senegalensis*), and a Western lowland gorilla (*Gorilla gorilla*) (Schmidt and Hubbard, 1987; Yanai et al., 1993). It is not associated with any clinical signs and involves mineralization of blood vessel walls.

In conclusion, we describe a condition found in old eastern quolls and Tasmanian devils which is manifested clinically by blindness and ataxia of the hindquarters. There is no treatment known and an exact etiology has not been ascertained. However, in view of the advanced age of affected individuals and the geographically widespread nature of the cases, an age-related degeneration is the likely cause.

The condition has been described only for captive individuals. However, it is likely that the syndrome also is present in the wild population without yet being recognized. As only old individuals that are beyond reproductive age are affected, the condition is unlikely to have a great impact on the population as a whole.

ACKNOWLEDGMENTS

We acknowledge the support of the keeping staff of Healesville Sanctuary and the Metropolitan Toronto Zoo, and the financial support provided by the Zoological Society of Metropolitan Toronto. We thank S. Barlow, W. Hartley, and D. L. Obendorf for providing histological material for examination. The assistance of I. K. Barker also is greatly appreciated.

LITERATURE CITED

- ALLEN, T. C. 1992. Hematoxylin and eosin. In *Laboratory methods in histotechnology*, E. B. Prophet, B. Mills, J. B. Arrington, and L. H. Sobin (eds.).

- American Registry of Pathology, Washington, D.C., pp. 53–58.
- ANDERSON, W. K., AND K. M. KING. 1988. Subclinical lumbar polyradiculopathy in multiple aged mammalian species. *Cornell Veterinarian* 78: 185–189.
- , K. F. CUMMINGS, H. STEINBERG, A. DELAHUNTA, AND K. M. KING. 1989. Subclinical lumbar polyradiculopathy in aged domestic, laboratory and exotic mammalian species. A light and selected electronmicroscopic study. *Cornell Veterinarian* 79: 339–344.
- , ———, ———, ———, AND ———. 1993. Subclinical lumbar polyradiculopathy, polyneuritis and ganglionitis in aged wild and exotic mammals. *Journal of Comparative Pathology* 109: 89–91.
- ATTWOOD, H. D., AND P. A. WOOLLEY. 1973. Spontaneous malignant neoplasms in dasyurid marsupials. *Journal of Comparative Pathology* 83: 569–581.
- BARBOUR, R. A. 1977. Anatomy of marsupials. In *The biology of marsupials*, B. Stonehouse and D. Gilmore (eds.). Macmillan Press Ltd., London, United Kingdom, pp. 237–272.
- BUREK, J. D. 1978. Pathology of aging rats. CRC Press, Boca Raton, Florida, pp. 139–159, 191–197.
- , A. J. VAN DER KOEGL, AND C. F. HOLLANDER. 1976. Degenerative myelopathy in three strains of aging rats. *Veterinary Pathology* 13: 321–331.
- EVERIST, S. L. 1981. Poisonous plants of Australia, 2nd ed. Angus and Robertson Publishers, Sydney, Australia, pp. 507–511.
- FINNIE, E. P. 1988. Diseases and injuries of other Australian mammals. In *Australian wildlife. Proceedings* 104, Post Graduate Committee in Veterinary Science, University of Sydney, Sydney, Australia, pp. 91–93.
- GILMOUR, K. S., AND B. SYNGE. 1987. Brain changes in a dog poisoned by the insecticide dieldrin. *Journal of Comparative Pathology* 97: 273–279.
- GRINER, A. 1979. Neoplasms in Tasmanian devils (*Sarcophilus harristi*). *Journal of the National Cancer Institute* 62: 589–592.
- JUBB, K. V. F., AND C. R. HUXTABLE. 1993. The nervous system. In *Pathology of domestic animals*, 4th ed., Vol. 1, K. V. F. Jubb, P. C. Kennedy, and N. Palmer (eds.). Academic Press Inc., San Diego, California, pp. 267–439.
- NOWAK, R. M., AND J. L. PARADISO. 1983. Walker's mammals of the world, 4th ed., Vol. 1. Johns Hopkins University Press, Baltimore, Maryland, pp. 36–39.
- OBENDORF, D. L. 1993. Diseases of dasyurid marsupials. In *The biology and management of Australasian carnivorous marsupials*, M. Roberts, J. Carnio, G. Crawshaw, and M. Hutchins (eds.). Metropolitan Toronto Zoo, Toronto, Canada, pp. 39–46.
- SCHMIDT, R. E., AND G. B. HUBBARD. 1987. Central nervous system. In *Atlas of zoo animal pathology*, Vol. 1. CRC Press, Boca Raton, Florida, pp. 173–180.
- VAN STEENIS, G., AND R. KROES. 1971. Changes in the nervous system and musculature of old rats. *Veterinary Pathology* 8: 320–332.
- YANAI, T., T. MASEGI, K. UEDA, J. MANABE, M. TERANISHI, M. TAKAOKA, N. MATSUNUMA, K. FUKUDA, AND N. GOTO. 1993. Spontaneous globoid mineralization in the cerebellum of rats. *Journal of Comparative Pathology* 109: 447–451.

Received for publication 11 January 1995.