



## **Prevalence of Hepatic Helminths and Associated Pathology in Impala (*Aepyceros melampus*) in Swaziland**

Authors: Gallivan, G. J., Barker, I. K., Culverwell, J., and Girdwood, R.

Source: Journal of Wildlife Diseases, 32(1) : 137-141

Published By: Wildlife Disease Association

URL: <https://doi.org/10.7589/0090-3558-32.1.137>

---

BioOne Complete ([complete.BioOne.org](https://complete.BioOne.org)) is a full-text database of 200 subscribed and open-access titles in the biological, ecological, and environmental sciences published by nonprofit societies, associations, museums, institutions, and presses.

Your use of this PDF, the BioOne Complete website, and all posted and associated content indicates your acceptance of BioOne's Terms of Use, available at [www.bioone.org/terms-of-use](https://www.bioone.org/terms-of-use).

Usage of BioOne Complete content is strictly limited to personal, educational, and non - commercial use. Commercial inquiries or rights and permissions requests should be directed to the individual publisher as copyright holder.

---

BioOne sees sustainable scholarly publishing as an inherently collaborative enterprise connecting authors, nonprofit publishers, academic institutions, research libraries, and research funders in the common goal of maximizing access to critical research.

## Prevalence of Hepatic Helminths and Associated Pathology in Impala (*Aepyceros melampus*) in Swaziland

G. J. Gallivan,<sup>1</sup> I. K. Barker,<sup>2,5</sup> J. Culverwell,<sup>3</sup> and R. Girdwood,<sup>4,1</sup> Department of Biology, University of Swaziland, Private Bag Kwaluseni, Swaziland; <sup>2</sup> Department of Pathology, Ontario Veterinary College, University of Guelph, Guelph, Ontario, Canada. N1G 2W1; <sup>3</sup> Mbuluzi Nature Reserve, Tambankulu Estates, Private Bag Mhlume, Swaziland; <sup>4</sup> Mlawula Nature Reserve, Private Bag Simunye, Swaziland; <sup>5</sup> Corresponding author for reprints

**ABSTRACT:** The livers of impala (*Aepyceros melampus*) collected in the Mlawula-Mbuluzi-Simunye Nature Reserve and Protected Area complex in northeastern Swaziland from October 1985 to September 1986 were infected with three species of helminths: a nematode (*Cooperioides hepaticae*), a cestode (*Stilesia hepatica*), and a trematode (*Fasciola gigantica*). *Cooperioides hepaticae* caused a severe cholangitis. Lambs were infected at 1.5 to 2 mo of age, and the prevalence increased to 100% by 5 mo of age. The prevalence was 82% in yearlings and 44% in adults, with the highest prevalence and intensity of infection at the end of the dry season. *Stilesia hepatica* was found primarily in adults. Heavy infections caused a thickening and distension of the main bile ducts, but no changes were evident in the liver parenchyma. *Fasciola gigantica*, found only in one adult male, caused a thickening and distension of main bile duct. There was no apparent association between the helminth infections and body condition.

**Key words:** Impala, *Aepyceros melampus*, *Cooperioides hepaticae*, *Stilesia hepatica*, *Fasciola gigantica*, prevalence, body condition.

Impala (*Aepyceros melampus*) are commonly infected with the hepatic helminths *Cooperioides hepaticae* (Nematoda: Trichostrongyloidea) and *Stilesia hepatica* (Cestoda: Cyclophyllidae) (Round, 1968). The reported prevalence of *C. hepaticae*, which causes a chronic cholangitis with marked hyperplasia of the bile duct epithelium (Pletcher et al., 1988), ranges from 77 to 91% (Young and Wagener, 1968; Anderson, 1983). In the northern Transvaal of South Africa the highest intensity of infection was from July to November (Horak, 1978), but there didn't appear to be a seasonal pattern in Natal (Anderson, 1983). Anderson (1983) reported that the intensity of infection was highest in lambs, while Pletcher et al. (1988) reported that it was highest in yearlings.

While *C. hepaticae* infects only impala, *S. hepatica* infects other wild and domestic ruminants (Round, 1968). The prevalence in impala ranges from 0 to 15% (Horak, 1978; Anderson, 1983). Muger (1969) described hyperplasia and cystic dilatation of the bile ducts in *S. hepatica* infections in impala, but he appears to have confused these lesions with those caused by *C. hepaticae* (Pletcher et al., 1988). *Stilesia hepatica* is more prevalent in adult impala (Sachs et al., 1969), but there is no information on the seasonal pattern in prevalence.

In the present paper we report the patterns of prevalence and lesions associated with hepatic helminthosis in impala in the Mlawula-Mbuluzi-Simunye Nature Reserve and Protected Area complex in northeastern Swaziland (26°12'S, 32°00'E). The study area has been described by Gallivan et al. (1989, 1995).

From October 1985 to September 1986, 191 impala were collected by shooting, with monthly sample sizes ranging from six to 24 animals. The impala were necropsied within 2 hr of shooting for the determination of body condition (Gallivan et al., 1995) and parasite status. At that time the liver was removed and any gross lesions were recorded. The main bile ducts and gall bladder were dissected, and the liver parenchyma was sectioned at approximately 1-cm intervals and the cut surfaces examined. Samples of helminths were collected and the intensity of infestation of nematodes was estimated as light (1 to 25), moderate (26 to 100) or heavy (>100). Nematodes were preserved in 70% alcohol with 5% glycerin, and cestodes and trematodes were preserved in 70% alcohol with

TABLE 1. Prevalence (%) of hepatic helminths by age class in impala in the Mlawula-Mbuluzi-Simunye Nature Reserve and Protected Area complex in Swaziland from October 1985 to September 1986.

	Lambs (1–12 mo)	Yearlings (13–24 mo)	Adults (>24 mo)
Sample size	53	34	104
<i>Cooperioides hepaticae</i>	74	82	44
<i>Stilesia hepatica</i>	0	3	18
<i>Fasciola gigantica</i>	0	0	1

3% acetic acid. The helminths were cleared using standard procedures (Drury and Wallington, 1967) and identified using the keys of Gibbons (1978) and Reinecke (1983). Liver samples for microscopic examination were preserved in 10% neutral buffered formalin, embedded in paraffin, sectioned at 6  $\mu$ m, and stained with hematoxylin and eosin. The relationships between parasite prevalence and age, sex and season were analyzed using contingency tables (Fleiss, 1981). The relationships between parasite prevalence and the body condition indices: visual body condition, packed cell volume, kidney fat index and marrow dry weight (Gallivan et al., 1995), were analyzed using general linear models (PROC GLM) (SAS Institute Inc., 1985) with parasite presence and season as the independent variables.

Three species of helminths, *C. hepaticae*, *S. hepatica* and *Fasciola gigantica* were collected from the livers (Table 1). Representative samples of *C. hepaticae* and *S. hepatica* are deposited in the Canadian Museum of Nature Invertebrate Collection, Ottawa, Ontario (Accession numbers CMNPA1995-0125 and CMNPA-1995-0126).

Lambs (1 to 12 mo of age) were infected with *C. hepaticae* in January at 1.5 to 2 mo of age, and the prevalence was 100% by 5 mo of age (Fig. 1). The prevalence in yearlings (13 to 24 mo of age) was lowest during the summer and autumn (January to May), and highest in the late winter and spring (July to November) ( $P < 0.1$ ). The intensity of infection was

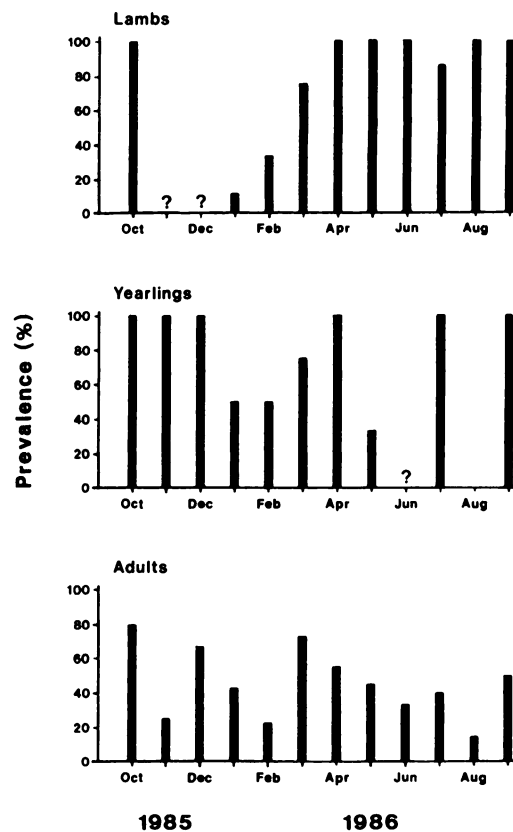


FIGURE 1. Prevalence of *Cooperioides hepaticae* by month in the three age classes of impala in the Mlawula-Mbuluzi-Simunye Nature Reserve and Protected Area complex in northeastern Swaziland from October 1985 to September 1986. "?" indicates that no impala of that age class were collected.

highest in the late winter and early spring, and decreased markedly after the spring rains in November. In adults the prevalence was highest in March and April, and in October ( $P = 0.025$ ). However, the intensity of infection was low in March and April, and high in October. There were no significant differences in the prevalence of *C. hepaticae* between the sexes in any age class ( $P > 0.2$ ).

*Cooperioides hepaticae* caused a severe cholangitis with a marked thickening of the bile ducts. In lambs in January there was active periductal fibroplasia with local infiltration of eosinophils, plasma cells, globule leucocytes, and lymphocytes which often formed focal lymphoid aggregates.

Adult parasites were associated with segmental ulceration of the epithelium and a fibrinous exudate containing neutrophils and eosinophils. Epithelial hyperplasia with the formation of papillae was present in some ducts. The inflammatory infiltrate and mild periportal fibrosis extended into the terminal portal triads. In lambs in February, well-organized fibrous tissue surrounded prominent bile ducts which contained adult nematodes and eggs, and there was extensive development of the papillae which were thickened by infiltrating eosinophils and lymphocytes. There was squamous metaplasia and ulceration of the epithelium adjacent to adult worms and eggs. Eggs embedded in epithelioid giant cells caused focal granulomas in the periportal parenchyma. This pattern was evident until June in impala of all ages with an active infection. In September the bile ducts contained necrotic debris surrounded by a loosely organized fibrous tissue containing macrophages, giant cells and lymphoid follicles.

In October many impala had dilated, obstructed bile ducts forming nodules which projected above the hepatic surface, but were also found deep in the liver parenchyma. These nodules contained adult nematodes, and there were often large numbers of nematodes in the gall bladder, which was dilated and filled with mucoid bile. Microscopically the nodules were similar to the bile ducts seen from February to June. In November and December the nodules were confined primarily to the main bile ducts. The nodules formed abscesses which resolved slowly. In March the abscesses in many adults and yearlings contained green caseous, gritty material, but no parasites. However, there were light infections in ducts away from the abscesses. From May to August adult impala in which there was no apparent infection often had fibrosis and epithelial hyperplasia of the smaller bile ducts, but with little inflammatory infiltrate.

The lesions associated with *C. hepaticae* infection were similar to those described

by Pletcher et al. (1988). The nodules described by previous authors (Young and Wagener, 1968; Mugeru, 1969; Pletcher et al., 1988) were only present in October when there was a high intensity of infection, and appeared to result from obstruction of the bile ducts by parasites and/or necrotic debris.

Patent infections of *C. hepaticae* in lambs at 1.5 to 2 mo of age indicate that infection can occur early in life as the prepatent period is approximately 21 days (Anderson, 1992). The high prevalence and intensity of infection in animals from 5 to 14 mo of age is consistent with other reports (Sachs et al., 1969; Pletcher et al., 1988). Although Anderson (1983) reported that the intensity was highest in lambs, their mean body weight suggests that they were >6 mo of age.

The lower prevalence and intensity of infection in adult impala suggests that they develop at least a partial immunity (Pletcher et al., 1988). However, adults were often heavily infected, indicating that other factors may also regulate infection.

The apparent seasonal pattern in the prevalence and intensity of *C. hepaticae* infection may be related to seasonal changes in spatial distribution of the impala. *Cooperioides hepaticae* has a direct life cycle, and development from eggs to third-stage larvae (L<sub>3</sub>) requires 12 to 16 days, with L<sub>3</sub> larvae capable of surviving up to a month in water (Anderson, 1992). There was no rainfall in the Mlawula-Mbuluzi-Simunye complex from May to October 1985, and in October the impala, which were in poor condition (Gallivan et al., 1995), were concentrated near permanent water sources. After the spring rains the impala moved into areas with seasonal water sources, moving back to the permanent water sources at the end of the summer when the females formed large breeding herds (G. J. Gallivan, unpubl.). Water is the most likely route of transmission as impala are predominately browsers during the winter (Dunham, 1980) and require free water, particularly in the hot,

dry conditions in early spring (Klein and Fairall, 1986). Thus, the potential for transmission is highest at this time.

*Stilesia hepatica* was a parasite of adult impala as reported by Sachs et al. (1969). The prevalence did not differ seasonally, nor between the sexes. It caused a thickening and distension of the main bile ducts, but no changes were evident in the liver parenchyma and smaller bile ducts. This differs from the description of Mugergera (1969); however, the parasites in his photomicrographs are *Cooperioides* spp., not *Stilesia* spp. as reported in his figure captions.

The yearling infected with *S. hepatica* was heavily infected with *C. hepaticae*, and eight of the 19 adults infected with *S. hepatica* were infected with *C. hepaticae* at a low intensity of infection. Sachs et al. (1969) suggested that *C. hepaticae* and *S. hepatica* were associated, but there was no association in the present study ( $\kappa$  (K) = -0.02;  $P > 0.8$ ). The lesions in animals with concurrent infections resembled those in animals with *C. hepaticae* only, but no nodules were observed.

*Fasciola gigantica* was only collected from one old adult male impala which was also infected with *S. hepatica*. There were plaques around the trematodes and the main bile duct was thickened by hyperplasia of the mucosal glands and peribiliary fibrosis infiltrated with eosinophils and lymphocytes. Black pigment was present in Kupffer cells throughout the liver parenchyma.

*Fasciola gigantica* is a common parasite of cattle throughout much of Africa, but does not appear to be a natural parasite of impala. Previous records (Horak, 1978; Jooste, 1987) are from impala which grazed with cattle and an introduced impala herd. The areas we sampled had been cattle ranches prior to their designation as nature reserves.

When the seasonal changes in body condition (Gallivan et al., 1995) were controlled, there was no association between *C. hepaticae* or *S. hepatica* prevalence and

the body condition of impala ( $P > 0.1$ ). The highest prevalence and intensity of *C. hepaticae* infection was in October, at the end of the dry season when the impala were in poor condition due to a restricted food supply. Both crowding and decreased resistance secondary to poor nutrition may have contributed to the parasite burdens. Anderson (1983) reported that impala heavily infected with helminths were in poor condition, but also suggested that the poor condition was secondary to the high stocking rates and overgrazing, factors which would contribute to the helminth burdens. Thus, although *C. hepaticae* and *S. hepatica* are common parasites of impala they do not appear to be of major significance to the health of the animal under normal conditions. However, they may be an added burden in periods of environmental stress, and may result in significant economic losses due to the condemnation of livers in game ranching or culling programs (Young and Wagener, 1968; Sachs et al., 1969).

Funding for this study was provided by the Research and Publication Committee of the University of Swaziland and logistical support was provided by the Swaziland National Trust Commission, Tumbankulu Estates and Simunye Sugar Estate. The assistance of K. Braun, J. Kunene, G. Dlamini and T. Lapidos in the collections was greatly appreciated. Dr. R. M. R. Alves of Onderstepoort Research Institute kindly identified the *Fasciola gigantica* and some specimens of *Cooperioides hepaticae*.

#### LITERATURE CITED

- ANDERSON, I. G. 1983. The prevalence of helminths in impala *Aepyceros melampus* (Lichtenstein 1812) under game ranching conditions. South African Journal of Wildlife Research 13: 55-70.
- . 1992. Observations on the life-cycles and larval morphogenesis of, and transmission experiments with *Cooperioides hamiltoni* and *Cooperioides hepaticae* (Nematoda: Trichostrongyloidea) parasitic in impala, *Aepyceros melampus*. South African Journal of Zoology 27: 81-88.
- DRURY, R. A. B., AND E. A. WALLINGTON. 1967.

- Carleton's histological technique, 4th ed. Oxford University Press, London, England, 432 pp.
- DUNHAM, K. M. 1980. The diet of impala (*Aepyceros melampus*) in the Sengwa Wildlife Research Area, Rhodesia. *Journal of Zoology*, London 192: 41–57.
- FLEISS, J. L. 1981. Statistical methods for rates and proportions, 2nd ed. John Wiley & Sons, New York, New York, 322 pp.
- GALLIVAN, G. J., I. K. BARKER, R. M. R. ALVES, J. CULVERWELL, AND R. GIRDWOOD. 1989. Observations on the lungworm, *Pneumostrongylus calcaratus*, in impala (*Aepyceros melampus*) from Swaziland. *Journal of Wildlife Diseases* 25: 76–82.
- , J. CULVERWELL, AND R. GIRDWOOD. 1995. Body condition indices of impala (*Aepyceros melampus*): Effect of age, season, sex and management. *South African Journal of Wildlife Research* 25: 23–31.
- GIBBONS, L. M. 1978. Revision of the genus *Cooperioides* Daubney, 1933 (Nematoda: Trichostrongylidae). *Journal of Helminthology* 52: 311–322.
- HORAK, I. G. 1978. Parasites of domestic and wild animals in South Africa. X. Helminths of impala. Onderstepoort *Journal of Veterinary Research* 45: 221–228.
- JOOSTE, R. 1987. Internal parasites of wild-life in Zimbabwe: Impala, *Aepyceros melampus* (Lichtenstein, 1812). *Zimbabwe Veterinary Journal* 18: 44–55.
- KLEIN, D. R., AND N. FAIRALL. 1986. Comparative foraging behaviour and associated energetics of impala and blesbok. *Journal of Applied Ecology* 23: 489–502.
- MUGERA, G. M. 1969. Lesions caused by *Cooperioides hepatica* and *Stilesia hepatica* in the liver of Kenya impala. *Bulletin of Epizootic Diseases of Africa* 17: 311–316.
- PLETCHER, J. M., I. G. HORAK, V. DE VOS, AND J. BOOMKER. 1988. Hepatic lesions associated with *Cooperioides hepaticae* (Nematoda: Trichostrongyloidea) infection of impala (*Aepyceros melampus*) of the Kruger National Park. *Journal of Wildlife Diseases* 24: 650–655.
- REINECKE, R. K. 1983. *Veterinary helminthology*. Butterworths, Durban, South Africa, 392 pp.
- ROUND, M. C. 1968. Checklist of the helminth parasites of African mammals of the orders Carnivora, Tubulidentata, Proboscidea, Hyracoidea, Artiodactyla and Perissodactyla. Technical Communication No. 38, Commonwealth Bureau of Helminthology (St. Albans). Commonwealth Agricultural Bureau, Farnham Royal, Bucks, England, 252 pp.
- SACHS, R., R. R. HOFMANN, AND A. O. SORHEIM. 1969. *Stilesia* infestation in East African antelopes. *The Veterinary Record* 84: 233–234.
- SAS INSTITUTE INC. 1985. SAS user's guide, version 5: Statistics. SAS Institute Inc., Cary, North Carolina, 956 pp.
- YOUNG, E. AND L. J. J. WAGENER. 1968. The impala as a source of food and by-products. Data on production potential, parasites and pathology of free-living impala of the Kruger National Park. *Journal of the South African Veterinary Medical Association* 39: 81–86.

Received for publication 23 November 1994.