

TOXICOLOGIC EVALUATION OF A HIGH-SELENIUM HAY DIET IN CAPTIVE PRONGHORN ANTELOPE (ANTILOCAPRA AMERICANA)

Authors: Raisbeck, M. F., O'Toole, D., Schamber, R. A., Belden, E. L., and Robinson, L. J.

Source: Journal of Wildlife Diseases, 32(1) : 9-16

Published By: Wildlife Disease Association

URL: <https://doi.org/10.7589/0090-3558-32.1.9>

BioOne Complete (complete.BioOne.org) is a full-text database of 200 subscribed and open-access titles in the biological, ecological, and environmental sciences published by nonprofit societies, associations, museums, institutions, and presses.

Your use of this PDF, the BioOne Complete website, and all posted and associated content indicates your acceptance of BioOne's Terms of Use, available at www.bioone.org/terms-of-use.

Usage of BioOne Complete content is strictly limited to personal, educational, and non - commercial use. Commercial inquiries or rights and permissions requests should be directed to the individual publisher as copyright holder.

BioOne sees sustainable scholarly publishing as an inherently collaborative enterprise connecting authors, nonprofit publishers, academic institutions, research libraries, and research funders in the common goal of maximizing access to critical research.

TOXICOLOGIC EVALUATION OF A HIGH-SELENIUM HAY DIET IN CAPTIVE PRONGHORN ANTELOPE (*ANTILOCAPRA AMERICANA*)

M. F. Raisbeck,^{1,3} D. O'Toole,¹ R. A. Schamber,¹ E. L. Belden,¹ and L. J. Robinson²

¹ Department of Veterinary Sciences, University of Wyoming, 1174 Snowy Range Road, Laramie, Wyoming 82070, USA

² Wyoming Game and Fish Department, Sybille Wildlife Research and Wildlife Conservation Unit Bosler Route Box 8101, Wheatland, Wyoming, 82201

³ Author for reprints

ABSTRACT: Five captive-raised pronghorn antelope (*Antilocapra americana*) were fed an alfalfa-grass hay diet containing 15 ppm total dietary selenium (Se) for 164 days. Four additional captive-raised pronghorns fed a similar diet containing approximately 0.3 ppm total dietary Se served as controls. None of the pronghorns had clinical signs attributable to the high Se hay. Plasma Se increased more rapidly than blood Se concentrations, from baseline concentrations (<0.15 g/ml) to >0.40 g/ml within the first 50 days on the high selenium diet, but thereafter declined to approximately 0.30 μ g/ml. Mean primary antibody response to hen egg albumin was less in pronghorn on Se hay. No significant gross or histological lesions attributable to selenosis were found, nor was there any evidence of dystrophic hoof growth. The greatest Se tissue concentrations were found in liver and kidney (5.67 to 10.4 μ g/g and 2.36 to 3.14 μ g/g, respectively) from experimental animals; liver and kidney from the controls contained considerably less (≤ 0.52 μ g/g and ≤ 0.61 μ g/g, respectively). Exposure of pronghorns for more than 5 mo to a diet containing 15 ppm Se caused significant increases in plasma, liver and kidney Se concentrations, in the absence of clinical disease or pathologic lesions due to selenosis. Based on these results, we propose that pronghorns are less susceptible to selenosis than previously reported and that diagnostic criteria for the disease should be modified.

Key words: Selenium, *Antilocapra americana*, pronghorn antelope, selenosis, diagnosis, alkali disease.

INTRODUCTION

Selenium (Se) is a common constituent of many geologic formations and their derivative soils in the Great Plains of the United States and Canada (Mayland and James, 1988). Under specific conditions it is accumulated and stored from such soils by vegetation, resulting in a potential toxic hazard to herbivorous livestock and wildlife (Mayland et al., 1991). Chronic selenosis causes various clinicopathological syndromes, of which the best characterized is alkali disease of horses (*Equus caballus*), cattle (*Bos taurus*), and swine (*Sus scrofa*) (Moxon, 1937). Alkali disease is manifested clinically by abnormal growth and cracking of hooves, and loss of hair from the tail switch (Yager and Scott, 1993). Selenium-induced digital lesions are associated with histological changes such as hyperplasia and dyskeratosis of digital epithelium, and abnormally confi-

gured tubular horn (O'Toole and Raisbeck, 1995).

There is little information about the susceptibility to selenosis of game species native to seleniferous areas of North America (Beath, 1982; Ohlendorf, 1989). There are anecdotal reports of elevated tissue Se concentrations in native herbivores with abnormal hooves (Williams, 1982). There are, however, little background data and no controlled studies to compare with diagnostic data. The native range of pronghorn antelope (*Antilocapra americana*) includes potentially seleniferous areas that are presently mined for coal, such as the Powder River Basin of Wyoming (USA). During mining and reclamation, reduced Se in mine waste materials (spoil and overburden) may become oxidized to more plant-available forms (Whanger, 1989). The natural diet of pronghorns includes Se-accumulating plants such as saltbush (*Atriplex* spp.), and there are anecdotal re-

ports of selenosis in pronghorns in these areas (Post, 1958, 1959). Considerable uncertainty remains, however, about the critical thresholds in reclaimed soil and vegetation necessary to ultimately cause adverse effects in native wildlife. Our objectives were to determine if native vegetation naturally containing 15 ppm Se was toxic to pronghorns and to describe any lesions associated with such intoxication.

MATERIALS AND METHODS

Nine healthy male pronghorn antelope aged 6 mo to 8 yr were obtained from the Colorado (USA) Division of Wildlife Foothills Wildlife Research Facility and maintained in outdoor pens at the Sybille Wildlife Research and Conservation Unit of the Wyoming Game and Fish Department (41°46'N, 105°19'W) between October 1993 and late May 1994. Animals either were born to captive pronghorn in the Colorado facility (nos. 1 to 4, 6 to 9) (Wild et al., 1994) or raised as a wild-caught perinatal fawn (no. 5); the origin of one animal, an 8-yr-old castrated male (no. 9) was unknown. Each pen was provided with a heated waterer (<50 ppb Se), free-choice white salt and a three-sided shed for shelter. After acclimation to a ground (about 1 cm) grass hay-alfalfa diet (basal diet; 0.3 to 0.5 ppm dry matter Se) for 1 mo, animals were ranked by weight and, from that ranking, randomly assigned to either a control (nos. 1 to 4) or a experimental group (nos. 5 to 9). These groups then were subdivided by age (fawns and adults) between four pens, and fed by pen. Experimental animals were fed a diet of native grass hay naturally high in Se (23 to 25 ppm dry matter Se) ground 60:40 with alfalfa (0.3 to 0.5 ppm dry matter Se). The Se concentration of the ground mixture was analyzed after each batch was ground and varied between 14 and 16 ppm dry matter. Controls remained on the basal ration. From late January (49 days on treatment) until the experiment was terminated, each animal also was given 200 g of a corn-oats-barley mix or alfalfa pellets (0.3 to 0.5 ppm dry matter) per day.

Each animal was inspected daily for evidence of illness. Blood was drawn into evacuated containers every 28 days by jugular venipuncture for Se analysis (trace element grade tubes), clinical chemistry (clot and heparin tubes), complete blood count (ethylenediaminetetraacetic acid (EDTA) tube) and antibody analysis (clot tube). Samples for Se and antibody analysis were frozen -20 C until analyzed. Blood

counts were performed within 24 hr and clinical chemistries within 8 hr of collection on fresh blood and serum.

After 164 days on high Se hay (December 1993 to May 1994), each pronghorn was killed by electrocution after being anesthetized with an overdose (1,000 mg) of xylazine (Rompun, Haver Scientific, Shawnee, Kansas, USA). Gross lesions found at necropsy were noted. The weight of each carcass and, following trimming of excess fat and connective tissue, the weights of the following were recorded: liver, kidneys, testes, spleen, pancreas, brain, adrenals, thyroids, pituitary, heart, left and right ventricular free walls, and septal myocardium. The following tissues from each animal were stored in 10% neutral buffered formalin for light microscopic evaluation: salivary gland, tongue, esophagus, reticulum, rumen, omasum, abomasum, small bowel (three levels), cecum, colon, liver, gall bladder, pancreas, lung (anterior, middle and posterior lobes of the left lung), heart (right and left ventricles at the papillary muscles, and interventricular septum), thoracic aorta, kidneys, bladder, adrenals, thyroids, pituitary, thymus, spleen, mesenteric and hepatic lymph nodes, testicle, bone marrow (femur), skin (three sites: tail, right lateral thorax, and dorsal midline cervical area), brain, spinal cord, seven skeletal muscles (*biceps brachii*, *extensor carpi radialis*, *vastus lateralis*, *biceps femoris*, *tibialis cranialis*, *longissimus lumborum* and *psoas major*;) and four peripheral nerves (ulnar, median, ischiatic and fibular nerves). Hooves were collected from six animals (three controls and three experimentals). Eyes were trimmed of extraocular tissue, fixed in Zenker's-acetic acid (Luna, 1985), and cut in a vertical midsagittal plane through the optic papilla. Following fixation in formalin, the following 11 levels of each brain and seven transverse and longitudinal levels of spinal cord, including spinal nerve roots, were prepared for histology with hematoxylin-eosin and Von Kossa stains (Luna, 1985): mid-sagittal level of cerebellum and septotemporal level of hippocampus; coronal levels of frontal, parietal and occipital cortex, basal ganglia, thalamus; midbrain; medulla oblongata at middle-posterior cerebellar peduncles, obex and near the junction with the first cervical spinal cord segment (C1); and spinal cord at C3, C6, third thoracic segment (T3), T7, T12, first lumbar segment (L1) and L4. Samples of the left mandible of animal no. 4, and of medulla oblongata at the obex (animal nos. 3, 6, 7, 8) were decalcified in a solution of EDTA and HCl (Decal-F, Baxter Scientific, McGaw Park, Illinois, USA). Following fixation, hooves were cut initially on an electrical band saw and three sites were sampled with razor strips for histol-

ogy: through the junction of periople with coronary hoof at right angles to the periople; through the junction of coronary with laminar hoof perpendicular to laminae; and through distal laminar hoof (Dyce et al., 1987). Histological preparations of hoof included dermis, epithelium, stratum lamellatum, stratum medium and stratum tectorium.

Sterile swab samples were taken of all grossly abnormal tissues and cultured on 5% sheep blood agar plates (Acumedia, Baltimore, Maryland, USA) at 37 C for 24 hr. Individual colonies were isolated on similar plates (Breed et al., 1964) and identified by the technique of Breed et al., (1964).

Samples of brain, liver, kidney, hoof, skeletal muscle (*biceps brachii*) and myocardium (apex of the left ventricle) were collected and frozen (−20 C) for Se analysis. Feedstuffs, water and tissues for Se analysis were digested with HNO₃ and MgNO₃ (Poole et al., 1977), reduced with concentrated HCl and reacted with diamiononaphthalene in the presence of urea to produce the piazoselenol derivative (Helrich, 1990); this then was quantified with a Shimadzu 535 fluorescence detector (Shimadzu Instrument Corp, Tokyo, Japan). Each analysis included a high and low control sample (Bovine Liver and Dried Milk, National Institute of Standards and Technology, Gaithersburg, Maryland, USA), and a duplicate sample fortified with selenium, each value was required to be within 20% of the target before the analysis was accepted. Selenium tissue concentrations were calculated on a wet weight basis. Clinical chemistries (blood urea nitrogen (BUN), serum albumin, globulin, protein, alkaline phosphatase (AP), glucose, creatinine, alanine aminotransferase (ALT), aspartate aminotransferase (AST), creatine kinase (CK) and total bilirubin) were analyzed on an clinical biochemistry unit (IDEXX 8008, IDEXX Corp., Westbrook, Maine, USA). Alpha-hydroxybutyrate dehydrogenase activity (HBDH) in serum was evaluated manually with a commercial kit (DG120-K, Sigma Chemical Co., St. Louis, Missouri, USA). Whole blood glutathione peroxidase (GPx) was assayed manually by the method of Agergaard and Jensen (1982).

On day 28 each pronghorn was given a single subcutaneous injection (2 ml) of hen egg albumin (OVA; Sigma A5503) 20 mg/ml in potassium alum adjuvant (Proom, 1943). An indirect enzyme linked immunosorbant assay (ELISA) developed in our laboratories (Schamber, 1994) was used to measure OVA-specific antibody in serum collected at the subsequent three bleedings.

Data were analyzed by the SAS General Linear Models procedure, using diet and time on

diet as independent variables, and treatment group means compared by the method of least squares means (SAS Institute, Cary, North Carolina, USA). Prior to analysis, all data were evaluated for normality. Organ weights were expressed as a ratio to brain weight prior to analysis. Differences between group means were considered statistically significant at $P < 0.05$.

RESULTS

With the exception of one control pronghorn (no. 4) which developed a severe peritonitis unrelated to the experiment and was euthanized on day 25, none of the pronghorns had any clinical signs of illness. In particular, there were no hair or hoof lesions, signs of impaired vision, or convulsions. There were no significant differences between treatment groups in the red blood count, hematocrit, hemoglobin, white blood count, differential leukocyte counts, nor most serum chemistries (BUN, albumin, protein, AP, glucose, creatinine, ALT, AST, total bilirubin, HBDH). Creatine kinase activity decreased from a high of approximately 400 IU/l during acclimation period to less than 100 IU/l in both groups (data not shown).

Although the pronghorns initially ate the ground hay quite readily, food consumption declined in both experimental animals and controls after approximately 1 mo. As this coincided with the coldest part of winter, after day 49 the ration was supplemented daily with 200 g of mixed grain (0.25 ppm dry matter Se) or alfalfa pellets (0.3 ppm dry matter Se) per head, for the remainder of the experiment. Energy supplementation increased hay consumption in both groups and brought controls back up to expected intake, but experimental animals consumed less than controls for the remainder of the experiment. Estimated total Se consumed by fawns and adults during the 164 day experiment was 1.57 gm/animal and 2.07 gm/animal, respectively.

Blood and plasma Se and GPx increased significantly in pronghorns fed high Se hay (Fig. 1). Plasma Se increased quickly to

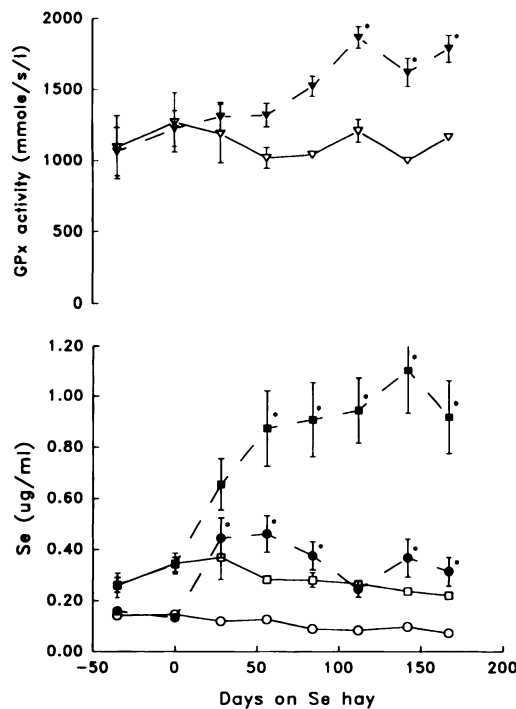


FIGURE 1. Indicators of selenium (Se) status in blood of pronghorns fed 15 ppm dry matter Se hay and control pronghorn fed 0.3 ppm dry matter hay. Filled elements represent experimental animals, open elements, controls. Plasma Se concentration is indicated by circles, blood Se concentrations by squares, glutathione peroxidase (GPx) activity by triangles. Blood concentration data previously were reported in Raisbeck et al. (1995). All values are presented as mean \pm standard error, but in some instances the standard error was too small to depict. * denotes significantly ($P < 0.05$) greater than value on day 0.

approximately 0.4 $\mu\text{g}/\text{ml}$ at 28 days. Glutathione peroxidase activity also was slower to respond to the high Se diet than plasma Se. Heart, liver, and skeletal muscle Se concentrations were significantly greater in experimental animals than controls (Table 1). Although brain Se concentrations were greater in experimental animals than controls, the difference was not statistically significant. Mean primary antibody responses to OVA were significantly smaller in the Se groups than controls on days 56, 84, and 112 (Fig. 2).

At necropsy, all pronghorn were in fair body condition. Although organ weight ratios did not differ significantly between groups (data not shown), gross lesions were found in two animals. Animal no. 5 (an experimental fawn) had a hard 3 cm diameter swelling in the ramus of the left mandible that contained yellow purulent fluid and surrounded the root of a check tooth; *Actinomyces pyogenes* was isolated in pure culture. Animal no. 9 (an experimental adult) had three 30 to 65 mm abscesses in the right lung that involved anterior and middle pulmonary lobes; a mixture of *Pasteurella haemolytica* and an alpha hemolytic *Streptococcus* spp. was isolated.

Histologically, animal no. 5 had chronic localized bacterial periodontitis-osteomyelitis around the root of a molar tooth. Animal no. 9 had chronic exudative bronchiolitis with fibrosis. The four adult pronghorn (nos. 3, 7, 9) had unilateral or

TABLE 1. Tissue selenium (Se) concentration (mean \pm standard error; $\mu\text{g}/\text{g}$ wet weight) in pronghorns fed high and adequate Se diets (November, 1993 to May, 1994).

Tissue	Control ($\mu\text{g}/\text{g}$ wet weight)	Experimental ($\mu\text{g}/\text{g}$ wet weight)
Skeletal muscle (<i>biceps brachii</i>)	0.21 \pm 0.056 ^a	1.13 \pm 0.108 ^b
Brain	0.14 \pm 0.009	0.73 \pm 0.126
Heart	0.20 \pm 0.252	1.41 \pm 0.126 ^b
Kidney	0.67 \pm 0.091	2.72 \pm 0.149 ^b
Liver	0.50 \pm 0.014	8.76 \pm 0.914 ^b

^a Mean \pm standard error.

^b Significantly ($P < 0.05$) greater than concentration in corresponding tissue from controls.

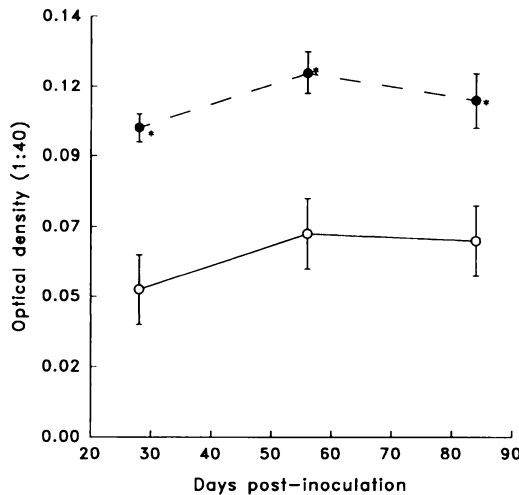


FIGURE 2. Primary antibody response in pronghorns to hen egg albumin (OVA). Filled elements are for experimental animals, open elements for controls. Each point represents the mean \pm standard error optical density of OVA specific antibody in serum diluted 1:40 with buffer. Pronghorn were inoculated with OVA after 28 days on high or adequate Se hay; therefore, values on abscissa represent 56, 84 and 112 days on hay. * denotes significantly ($P < 0.05$) greater than controls on same date.

bilateral irregularly oval, laminated concretions (25 to 350 μ m diameter) in the neuropil of the dorsal vagal nucleus, that were surrounded by a mild hyperplastic microglial reaction. One of these four animals also had mineralized concretions in the tunica adventitia of an arteriole in the dorsal vagal nucleus. Seven animals (nos. 2, 3, 5, 7, 8), including two controls, had widely scattered degenerating axons in white matter of all columns of the spinal cords. This change was found in cervical, thoracic and lumbar levels and, although mild, was more extensive in the four adults. The two oldest animals in the study (nos. 8 and 9) had mild colloidal or colloidal-hyperplastic goiter; however only pronghorn no. 8 had a thyroid:brain ratio notably larger (0.081) than the group mean \pm SE (0.053 \pm 0.020). Two animals (nos. 2 and 3) had widely scattered large (up to 900 μ m) thyroid follicles and animal no. 6 had an epithelial-lined thyroidal cyst.

DISCUSSION

A diet of native grass and alfalfa hay, naturally containing 15 ppm dry matter Se, did not induce clinically recognizable disease (with the possible exception of decreased weight gain in fawns), clinicopathologic changes, nor post-mortem lesions when fed to pronghorn for 164 days. Selenium concentrations in tissues from experimental animals were greater than previously believed to be characteristic of selenosis in wild ungulates, 1 μ g/ml blood or 5 ppm, dry weight for liver (Williams, 1982). Based on these results, we believe that either pronghorns may tolerate higher dietary Se than other species, or that Se tissue concentrations are not definitive for diagnosis of selenosis, especially after chronic, low level exposure.

Plasma Se concentration responded to the high Se diet more quickly than did blood Se concentration (Raisbeck et al., 1995) or GPx (Fig. 1). Plasma Se also was more labile than the other measures of Se status, decreasing significantly from its initial peak concentration at 112 days. Thus plasma Se concentrations are an unreliable indication of long term Se exposure; blood or tissue Se concentrations are preferable. Blood glutathione peroxidase is most commonly used as an measure of Se deficiency (Ullrey, 1987); however, there are limited data from our laboratory and others (D. Harnar, pers. comm.) that GPx actually may decline in cattle and horses during overt selenosis. The fact that GPx remained elevated in this experiment is further support for the idea that the pronghorn were not injured by the high Se diet. Elevated CK activity early in the experiment was attributed to sample-collecting stress as it occurred in both experimental animals and controls and declined as the animals became accustomed to being handled.

Conversely, significantly less primary antibody response to OVA was noted in pronghorns on high Se hay. The difference in OVA-specific antibody between groups

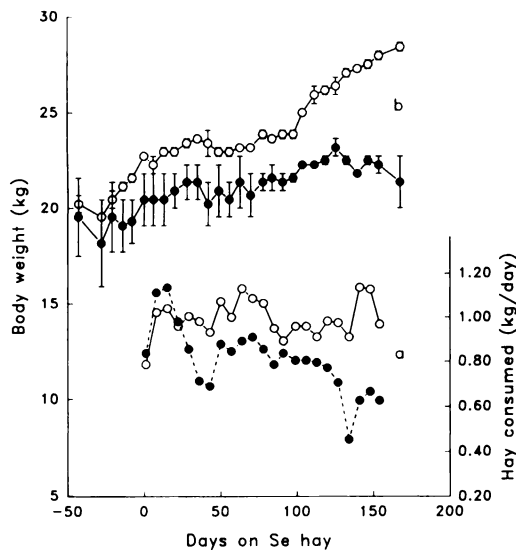


FIGURE 3. Feed consumption (a) and body weight (b) gain of fawns fed high selenium (Se) hay. Filled elements indicate experimental animals, open elements indicate controls. Note consistent trend to smaller hay consumption in the experimental group.

was consistent over time, but there was no difference in total globulin concentration between groups. Thus, we propose a direct effect by Se on antigen processing, presentation or subsequent lymphocyte interactions. The relevance of this observation is uncertain. The most severe potential consequence of such a deficit would be increased susceptibility to disease under field conditions; however, it remains to be seen if the deficit seen in this study is of sufficient magnitude to result in such an increase in susceptibility.

As reported previously (Raisbeck et al., 1995), fawns on Se hay gained less during the experiment than did controls (Fig. 3). This was attributed to an abscessed molar in one fawn in the experimental group, and to feed aversion to the Se hay. In our experience, aversion to high Se diets is a common pitfall in chronic Se feeding studies in mammals (O'Toole and Raisbeck, 1995) and also is reported in waterfowl (Heinz and Sanderson, 1990).

Various lesions were found in both controls and experimental animals; all were interpreted as incidental findings. Dystroph-

ic growth of hooves is a reliable index of selenosis in cattle, horses and pigs, and in cattle there is histological evidence of concurrent hyperplasia and parakeratosis in epithelium in the hoof at dosages which caused no overt damage (O'Toole and Raisbeck, 1995). No such gross or microscopic lesions developed in pronghorns. Topographically localized mineralization was present in the dorsal vagal nucleus of four adult pronghorns, including one control animal. Calcification occurs in brains of adult cynomolgus monkeys (*Macaca fascicularis*) and as an age-related change in humans, mice (*Mus domestica*), and cattle (Esiri and Oppenheimer, 1989; Yanai et al., 1994), and is most commonly found in the basal ganglia. We are not aware of any reports in other species of mineralization in dorsal vagal nucleus, but conclude it is an age-related incidental lesion that is subclinical and unrelated to Se in the diet. Two pronghorns had abscesses in the jaw or lung. Periodontitis is a sporadic disease that has been seen in other captive pronghorns in the Sybille facility and elsewhere (Griner, 1983) that may be due to artificial diets (E. S. Williams, pers. comm.). The two oldest pronghorns in the study, both experimental animals, had histological evidence of mild goiter. There is no association to our knowledge of selenosis with goiter, and this may be an age- or diet-related change. Mild axonal degeneration was found in spinal cord white matter in seven of the nine pronghorns; the cause of this lesion was not established and there was no clinical evidence of neurological deficits due to these mild changes.

The absence of overt disease is evidence that pronghorns tolerate relatively high (15 ppm dry matter) dietary Se concentrations without obvious adverse effects, and that the suggested diagnostic cut-off of 5 ppm (dry weight) in tissues should be modified to include other criteria. The decreased primary antibody response to OVA in these animals may be evidence that chronic selenosis resulted in subclinical immune impairment. Further studies are needed to

determine if the latter effect is sufficient to cause increased disease under field conditions.

ACKNOWLEDGMENTS

We thank Roger Siemion, Debbie Sanchez, and Val Welch for technical support, and Dr. E. S. Williams for valuable comments on the manuscript. The study was supported by the Abandoned Coal Mine Land Research Program, the University of Wyoming's Agricultural Experiment Station and the Pharmaceutical Manufacturer's Association.

LITERATURE CITED

- AGERGAARD, N., AND P. T. JENSEN. 1982. Procedure for blood glutathione peroxidase determination in cattle and swine. *Acta Veterinaria Scandinavica* 23: 515–527.
- BEATH, O. A. 1982. The story of selenium in Wyoming. *Agricultural Experiment Station Bulletin* No. 744, University of Wyoming, Laramie, Wyoming, pp. 27–28.
- BREED, R. S., E. G. D. MURRAY, AND N. R. SMITH. 1964. *Bergey's manual of determinative bacteriology*, Williams and Wilkins, Baltimore, Maryland, pp. 29–1033.
- DYCE, K. M., W. O. SACK, AND C. J. G. WENSING. 1987. *Textbook of veterinary anatomy*. W.B. Saunders Company, Philadelphia, Pennsylvania, pp. 707–710.
- ESIRI, M. M., AND D. R. OPPENHEIMER. 1989. Metabolic diseases of the nervous system. In: *Diagnostic neuropathology. A practical manual*. Blackwell Scientific Publications, Oxford, England, pp. 303–304.
- GRINER, L. A. 1983. Family Antilocapridae. In *Pathology of zoo animals*. Zoological Society of San Diego, San Diego, California, p. 512.
- HEINZ, G. H., AND C. J. SANDERSON. 1990. Avoidance of selenium-treated food by mallards. *Environmental Toxicology and Chemistry* 9: 1155–1158.
- HELDRICH, K. 1990. Selenium in food. Fluorometric method. In *Official methods of analysis of the AOAC. Agricultural chemicals; contaminants; drugs*, 15th ed., Vol. 1. Association of Official Analytical Chemists, Inc., Arlington, Virginia, pp. 269–270.
- LUNA, L. G. 1985. *Armed Forces Institute of Pathology manual of histologic staining methods*, 3rd ed., McGraw-Hill, New York, New York, pp. 4–33.
- MAYLAND, H. F., AND L. F. JAMES. 1988. Ecological aspects of selenosis on rangelands. In: *The ecology and economic impact of poisonous plants on livestock production*. Westview Press, Boulder, Colorado, pp. 275–293.
- , L. P. GOUGH, AND K. C. STEWART. 1991. Selenium mobility in soils and its absorption, translocation and metabolism in plants. U.S. Geological Survey Circular 1064, U.S. Government Printing Office, Washington, D.C., pp. 57–64.
- MOXON, A. L. 1937. Alkali disease or selenium poisoning. *Bulletin* No. 311, South Dakota Agricultural Experiment Station, Brookings, South Dakota, pp. 1–91.
- O'TOOLE, D., AND M. RAISBECK. 1995. Pathology of experimentally-induced chronic selenosis ("alkali disease") in yearling cattle. *Journal of Veterinary Diagnostic Investigation* 7: 364–373.
- OHLENDORF, H. M. 1989. Bioaccumulation and effects of selenium in wildlife. In *Selenium in agriculture and the environment*. Soil Science Society of America Special Publication No. 23, American Society of Agronomy and Soil Science Society of America, Madison, Wisconsin, pp. 314–338.
- POOLE, C. F., N. J. EVANS, AND D. G. WIBBERLEY. 1977. Determination of Se in biological samples by gas-liquid chromatography with electron capture detection. *Journal of Chromatography* 136: 73–83.
- POST, G. 1958. Diagnosis in mammals and birds. Pittman-Robertson Job Completion Report, Project FW-3-R-5, Work Plan No. 1, Job No. 1W. Wyoming Game and Fish Commission, Cheyenne, Wyoming, pp. 5–13.
- . 1959. Diagnosis of diseases in mammals and birds. Pittman-Robertson Job Completion Report, Project FW-3-R-7, Work Plan No. 1, Job No. 1W. Wyoming Game and Fish Commission, Cheyenne, Wyoming, pp. 1–22.
- PROOM, H. 1943. The preparation of precipitating sera for the identification of animal species. *Journal of Pathogenic Bacteriology* 55: 419–426.
- RAISBECK M. F., D. T. O'TOOLE, D. A. SANCHEZ, R. L. SIMIEON, AND J. W. WAGGONER. 1995. Re-evaluation of selenium toxicity in grazing mammals. *Proceedings of the American Society for Surface Mining and Reclamation, American Society for Surface Mining and Reclamation*, Princeton, West Virginia, pp. 372–384.
- SCHAMBER, R. 1994. Selenium immunotoxicity. M.S. Thesis. University of Wyoming, Laramie, Wyoming, p. 168.
- ULLREY D. E. 1987. Biochemical and physiological indicators of selenium status in animals. *Journal Animal Science* 65: 1712–1726.
- WHANGER, P. D. 1989. Selenocompounds in plants and their effects in animals. In *Toxicants of plant origin*, Vol. 3. Proteins and amino acids, P.R. Cheeke (ed.). CRC Press, Inc., Boca Raton, Florida, pp. 141–167.
- WILD, M. A., M. W. MILLER, D. L. BAKER, N. T. HOBBS, R. B. GILL, AND B. J. MAYNARD. 1994. Comparing growth rates of dam- and hand-raised

- bighorn sheep, pronghorn, and elk neonates. *The Journal of Wildlife Management* 58: 340–347.
- WILLIAMS, E. S. 1982. Plant intoxication. *In* Diseases of wildlife in Wyoming, 2nd ed., E. T. Thorne, N. Kingston, W. R. Jolley, and R. C. Bergstrom (eds.). Wyoming Game and Fish Department, Cheyenne, Wyoming, pp. 280–288.
- YAGER, J. A., AND D. W. SCOTT. 1993. The skin and appendages. *In* Pathology of domestic animals, 4th ed., K. V. F. Jubb, P. C. Kennedy, and N. Palmer (eds.). Academic Press, Inc., San Diego, California, pp. 587–589.
- YANAI T., T. MASEGI, K. UEDA, J. MANABE, M. TERANISHI, M. TAKAOKA, N. MATSUNUMA, K. FUKUDA, N. GOTTO, AND K. FUJIWARA. 1994. Vascular mineralization in the monkey brain. *Veterinary Pathology* 31: 546–552.

Received for publication 19 January 1995.