

## **PREVALENCE AND HISTOPATHOLOGY OF SHELL DISEASE IN TURTLES FROM LAKE BLACKSHEAR, GEORGIA**

Authors: Lovich, Jeffrey E., Gotte, Steve W., Ernst, Carl H., Harshbarger, John C., Laemmerzahl, Arndt F., et al.

Source: Journal of Wildlife Diseases, 32(2) : 259-265

Published By: Wildlife Disease Association

URL: <https://doi.org/10.7589/0090-3558-32.2.259>

---

BioOne Complete ([complete.BioOne.org](https://complete.BioOne.org)) is a full-text database of 200 subscribed and open-access titles in the biological, ecological, and environmental sciences published by nonprofit societies, associations, museums, institutions, and presses.

Your use of this PDF, the BioOne Complete website, and all posted and associated content indicates your acceptance of BioOne's Terms of Use, available at [www.bioone.org/terms-of-use](https://www.bioone.org/terms-of-use).

Usage of BioOne Complete content is strictly limited to personal, educational, and non - commercial use. Commercial inquiries or rights and permissions requests should be directed to the individual publisher as copyright holder.

---

BioOne sees sustainable scholarly publishing as an inherently collaborative enterprise connecting authors, nonprofit publishers, academic institutions, research libraries, and research funders in the common goal of maximizing access to critical research.

## PREVALENCE AND HISTOPATHOLOGY OF SHELL DISEASE IN TURTLES FROM LAKE BLACKSHEAR, GEORGIA

Jeffrey E. Lovich,<sup>1,5</sup> Steve W. Gotte,<sup>2</sup> Carl H. Ernst,<sup>3</sup> John C. Harshbarger,<sup>4</sup> Arndt F. Laemmerzahl,<sup>3</sup> and J. Whitfield Gibbons<sup>1</sup>

<sup>1</sup> Savannah River Ecology Laboratory, Drawer E, Aiken, South Carolina 29802 USA

<sup>2</sup> National Biological Service, Biological Survey Project, National Museum of Natural History, Washington, D.C. 20560 USA

<sup>3</sup> George Mason University, Department of Biology, 4400 University Drive, Fairfax, Virginia 22030 USA

<sup>4</sup> Registry of Tumors in Lower Animals, Department of Pathology, Ross 520,

George Washington University Medical Center, 2300 I Street, N.W., Washington, D.C. 20037 USA

<sup>5</sup> Present Address: National Biological Service, Midcontinent Ecological Science Center, Palm Springs Field Station, 63500 Garnet Avenue, P.O. Box 2000, North Palm Springs, California 92258-2000 USA

**ABSTRACT:** Turtles in Lake Blackshear, Crisp County, Georgia (USA) were evaluated for shell disease during intensive trapping efforts on 8 and 9 May 1990. The disease was most prevalent in *Pseudemys concinna* (74%) and *Trachemys scripta* (35%). The degree of necrosis on the carapace was significantly positively correlated with the degree of necrosis on the plastron in *T. scripta* ( $r_s = 0.50$ ), but not in *P. concinna* ( $r_s = 0.06$ ). Female *T. scripta* with lesions were significantly larger than females without lesions. Lesions were not detected on six other species of turtles. Some areas contained multinucleate osteoclasts that were destroying bone. No tumors were detected in soft tissue samples.

**Key words:** Turtle, *Trachemys scripta*, *Pseudemys concinna*, shell disease, osteitis.

### INTRODUCTION

There is widespread recognition that turtle populations around the world are declining (Ernst and Barbour, 1989). Disease is one potential factor of global decline, and some turtle populations are purportedly experiencing catastrophic declines due to disease-induced mortality (Jacobson, 1994). Turtles facing disease threats occupy a diversity of habitats and belong to several families. For example, some populations of green sea turtles (*Chelonia mydas*), particularly in the Hawaiian Islands (USA) and the Caribbean, contain individuals debilitated by fibropapillomas. These growths can impair vision, locomotion, and feeding ability. Fibropapillomatosis is considered to be a significant worldwide epizootic infecting up to 92% of some *C. mydas* populations (Herbst, 1994; Williams et al., 1994). Desert tortoise (*Gopherus* [= *Xerobates*] *agassizii*) populations in California, Nevada, Arizona, and Utah (USA) have been diagnosed with chronic upper respiratory tract disease (URTD). In one California population, 43% of the tortoises sampled had outward signs of the disease (Jacobson

et al., 1991). Large numbers of adult tortoises died in some California populations during a relatively short period of time, presumably because of URTD (Jacobson, 1993). Recently a new malady, shell disease, has been reported in desert tortoises on the Chuckwalla Bench in California (Jacobson et al., 1994). Disease reportedly presents a significant threat to the recovery of the federally threatened desert tortoise, including those on the Chuckwalla Bench (U.S. Fish and Wildlife Service, 1993). Finally, a disease causing emaciation and lesions on the plastron is suspected as a cause of major population declines of the flattened musk turtle (*Stenotherus depressus*), another federally threatened species (Dodd, 1988).

Since 1978 faculty and students of the University of Georgia, Savannah River Ecology Laboratory have periodically visited Lake Blackshear in Crisp County, Georgia (USA) (31°58'N, 83°54'W), to collect and mark turtles. On each visit we noticed that many river cooters (*Pseudemys concinna*) and yellow-bellied slider turtles (*Trachemys scripta*) had some degree of shell necrosis. The disease was character-

ized by deep excavating lesions on the plastron and elevated nodular lesions on the carapace. In addition, dead turtles frequently were found along the margin of the impoundment. Other than a brief note of the disease by Beltz (1993), there are no published papers documenting the occurrence and histopathology of this disease. Our objectives were to describe the prevalence of shell disease in turtles occupying the lake, evaluate the incidence of shell disease in relation to species and body size, and provide a histological description of shell disease.

#### MATERIALS AND METHODS

Turtles were collected in the Gum Creek embayment of Lake Blackshear, Crisp County, Georgia from 8 to 9 May 1990. Lake Blackshear is a 3,450-hectare impoundment on the Flint River. Most turtles were captured in baited hoop traps, but some were collected with dipnets or by hand. Data taken for each specimen included species, sex, and plastron length. The presence, degree, and location (carapace or plastron) of shell disease also was noted. The degree of shell disease was scored visually using the following system: 0 = no necrosis, 1 = necrotic involvement of 1 to 33% of the shell surface, 2 = necrotic involvement of 34 to 66% of the shell surface, and 3 = necrotic involvement of 67 to 100% of the shell surface. Live turtles were marked for future identification and released. Data were also taken from the shells of dead turtles found along the lake.

Voucher specimens of turtles were deposited in the U.S. National Museum (USNM), Smithsonian Institution, Washington, D.C., and the Vertebrate Museum of the Savannah River Ecology Laboratory (SREL), Aiken, South Carolina (USA); *Graptemys barbouri*: SREL 3077; *Kinosternon subrubrum*: USNM 306799-800, 306861; *Pseudemys concinna*: SREL 3356; USNM 306814-22, 306830, 306848-52; *Trachemys scripta*: SREL 3357, USNM 306823-29, 306831, 306856-57; *Sternotherus minor*: 306801; and *Sternotherus odoratus*: 306802-13, 306862-66.

Histological examinations of shell lesions were conducted by examining blocks of necrotic shell tissue fixed in 10% formalin. Ten blocks of shell tissue were examined from three specimens (*Trachemys scripta* USNM 306823 and 306824, *Pseudemys concinna* USNM 306817). Samples were taken from the raised lesions on the carapace and excavating lesions on the plastron. The blocks of tissue were re-

moved with a saw, decalcified, trimmed, embedded in paraffin, sectioned at 4  $\mu$ m, and stained by hematoxylin and eosin. Microscope slides were deposited in the Registry of Tumors in Lower Animals (RTLA), Department of Pathology, George Washington University Medical Center, Washington, D.C.: *Pseudemys concinna*: RTLA 5187; *Trachemys scripta*: RTLA 5185-86. Liver samples were taken from three specimens (*T. scripta*, USNM 306817; *P. concinna*, 306823 and 306824) and spleen, kidney, pancreas, ovary and gut were taken from one or two other specimens. Statistical techniques followed Zar (1984). An analysis of variance was used to compare means, Spearman's correlation coefficient was used to measure the degree of association between disease rank and disease location on the shell. To examine the incidence of shell lesions relative to the various turtle species a  $2 \times 3$  contingency table analysis was conducted. Specimens were classified into two rows based on the presence or absence of shell lesions. The three columns contained data for *T. scripta*, *P. concinna*, or all other species combined. The category "other" constituted a guild of highly aquatic carnivorous turtle species. Statistical significance was set at  $\alpha \leq 0.05$ .

#### RESULTS

We examined 112 turtles representing eight species. Diseased turtles had deep excavating lesions or raised, often nodular, lesions on the shell (Fig. 1). The effect of the lesions on the inner surface of the plastron was severe in some specimens (Fig. 2). The incidence of shell lesions was highest in *Pseudemys concinna* with 17 (74%) of 23 specimens possessing carapace or plastron lesions or both. *Trachemys scripta* had the next highest frequency of lesions with 22 (35%) of 63 specimens affected. Lesions were observed more frequently on the plastron than on the carapace in both *T. scripta* and *P. concinna*. Ten (45%) of 22 affected *T. scripta* had lesions on the carapace and 19 (86%) had plastron lesions. In affected *P. concinna*, 10 (59%) of 17 specimens had carapace lesions and all possessed plastron lesions (Table 1). Not all specimens with carapace lesions had plastron lesions or vice versa, but the degree of carapace necrosis in *T. scripta* was positively correlated with the degree of plastron necrosis (Spearman's

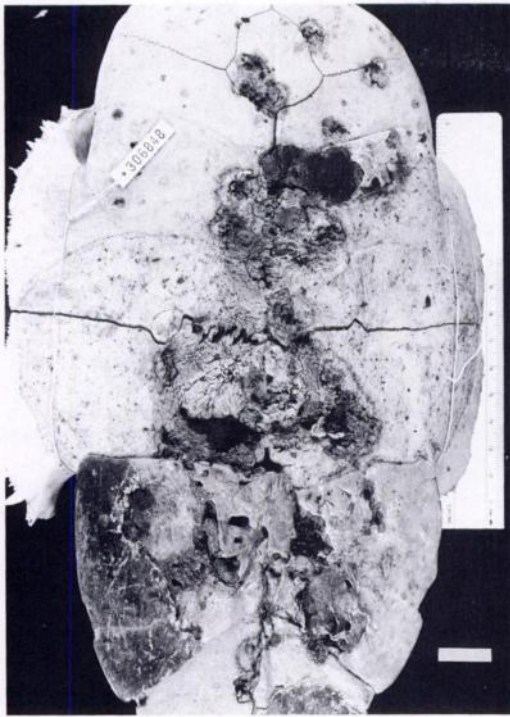


FIGURE 1. Shell disease lesions on the plastron of a *Pseudemys concinna* from Lake Blackshear, Georgia. The scutes have been removed to show the underlying bone. Bar = 20 mm.

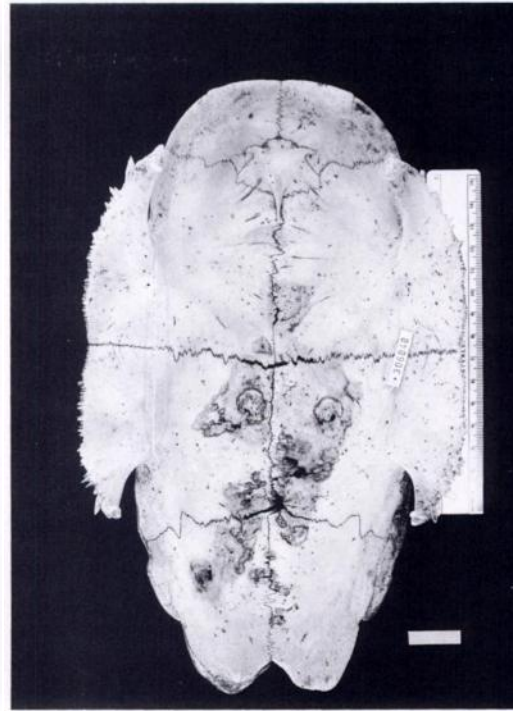


FIGURE 2. Interior view of the plastron of a *Pseudemys concinna* from Lake Blackshear, Georgia, showing lesions caused by shell disease (same specimen as in Fig. 1). Bar = 20 mm.

rank correlation,  $r_s = 0.50$ ,  $n = 50$ ,  $P = 0.0005$ ). Such was not the case for *P. concinna* ( $r_s = 0.06$ ,  $n = 20$ ,  $P = 0.78$ ). The mean ( $\pm$ SD) plastron length of male *T. scripta* without lesions ( $147 \text{ mm} \pm 19 \text{ mm}$ ,  $n = 18$ ) was not significantly different (ANOVA;  $df = 2, 23$ ;  $F = 0.488$ ;  $P = 0.62$ ) from those with lesions ( $148 \text{ mm} \pm 23 \text{ mm}$ ,  $n = 8$ ). The difference approached significance in female *T. scripta* (ANOVA;  $df = 3, 20$ ;  $F = 3.02$ ;  $P = 0.054$ ) since the mean plastron length of those without lesions ( $150 \text{ mm} \pm 25 \text{ mm}$ ,  $n = 12$ ) was less than that of females with lesions ( $193 \text{ mm} \pm 25.0 \text{ mm}$ ,  $n = 12$ ). Since such a small number of *P. concinna* were collected that did not possess lesions ( $n = 6$ ), statistical interpretation of the affected proportions of each sex was precluded.

None of the other species examined showed any signs of lesions, but our sample sizes were small (*Trionyx spiniferus*,  $n$

$= 1$ ; *Chelydra serpentina*,  $n = 2$ ; *Kinosternon subrubrum*,  $n = 3$ ; *Macrolemys temminckii*,  $n = 2$ ; *Sternotherus minor*,  $n = 3$ ; *Sternotherus odoratus*  $n = 15$ ). On previous collecting trips several individuals of *Graptemys barbouri* were examined. Although none possessed lesions, all had signs of damaged and sloughing shell scutes. Based on a  $2 \times 3$  contingency table

TABLE 1. The location on the shell and approximate percentage (surface area) of shell disease on affected turtles collected at Lake Blackshear, Georgia, May 1990. Numerals represent the sample size for each combination of shell location and damage class.

Percent damage	<i>Trachemys scripta</i> ( $n = 22$ )		<i>Pseudemys concinna</i> ( $n = 17$ )	
	Carapace	Plastron	Carapace	Plastron
1–33%	6	11	7	3
36–66%	4	6	3	9
67–100%	0	2	0	5

TABLE 2. Plastron length (mm) for turtles collected in Lake Blackshear, Georgia, May 1990. Means  $\pm$  SD are followed by sample sizes in parentheses.

Species/sex	Lesions absent	Lesions present
<i>Pseudemys concinna</i>		
Males	167 (1)	200 $\pm$ 12 (7)
Females	265 $\pm$ 21 (2)	262 $\pm$ 33 (10)
<i>Trachemys scripta</i>		
Males	147 $\pm$ 19 (18)	148 $\pm$ 23 (8)
Females	150 $\pm$ 25 (12)	193 $\pm$ 25 (12)

analysis, the incidence of lesions was not independent of species ( $G = 18.05$ ,  $df = 2$ ,  $P = 0.002$ ); thus *T. scripta* and *P. concinna* were far more likely to have shell lesions than all the other species combined.

Normally the carapace and plastron are made up of cancellous bone plates several millimeters thick covered by skin. The skin consists of a heavily keratinized stratified squamous epidermis of approximately five-cell layers and a thin, well-collagenized fibrous dermis. Histologically, elevated lesions of the carapace consisted of fibrous scar tissue continuous with the dermis and extending between and among trabeculae of bone that had not been absorbed and removed by osteoclasts. Intervening involuted epidermal pits, in cross section resembled epidermoid cysts, contained layers of keratin, bacteria, fragments of bone, pus, and debris. Osteoblasts lined a few trabeculae in an attempt to lay down new bone. Other areas contained multinucleate osteoclasts that were destroying bone (Fig. 3).

Lacunae being etched larger by osteoclasts contained a spectrum of white blood cells although not all white blood cell types were present in every location. Eosinophils, containing large, round, orange-pink cytoplasmic inclusions, were prominent. Herterophils, large cells with smaller, darker, more nearly rod-shaped cytoplasmic inclusions were observed in some locations. Monocytes were rarely seen but lymphocytes were widespread. Some la-

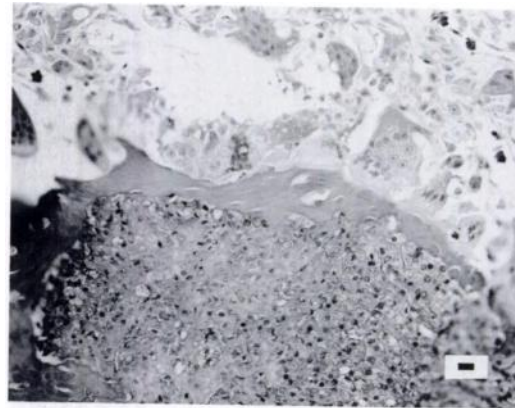


FIGURE 3. *Pseudemys concinna* (RTLA 5187) from Lake Blackshear, Georgia. Multinucleate osteoclasts (top) are absorbing and removing bone, thus enlarging lacunae. Inflammatory cells and debris (pus) fill some of the enlarged lacunal spaces (bottom). H&E. Bar = 10  $\mu$ m.

cunae also contained fibrocytes and melanophores in addition to the leukocytes.

The excavating lesions on the plastron (Fig. 4) usually were filled by a similar fibrosis (Fig. 5) with septic debris-filled epidermoid cysts but, in contrast to the carapace, the friable bone and debris often

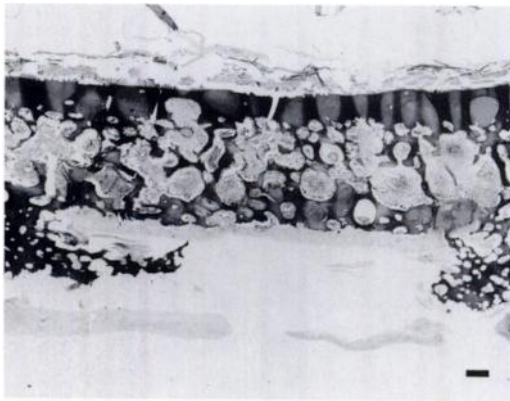


FIGURE 4. *Pseudemys concinna* (RTLA 5187) from Lake Blackshear, Georgia. Outer portion of plastron (bottom) has been excavated leaving a furrow bordered on either side by necrotic bone. Inner portion of plastron (top) has enlarged lacunae containing osteoclasts as well as inflammatory cells probably in response to infection agents. Soft tissue (top) is skeletal muscle. Soft tissue (bottom) is fibrous tissue attempting to form a scar. H&E. Bar = 300  $\mu$ m.






FIGURE 5. *Pseudemys concinna* (RTLA 5187) from Lake Blackshear, Georgia. Fibrous scar (bottom) replaces eroded shell (plastron). The scar is bordered by a layer of keratinized epidermis. The empty hole in the scar bordered by epidermis is an epidermal cyst: a cross section of a pit in the epidermis. To the lower right is another epidermal cyst filled with keratin. H&E. Bar = 300  $\mu$ m.

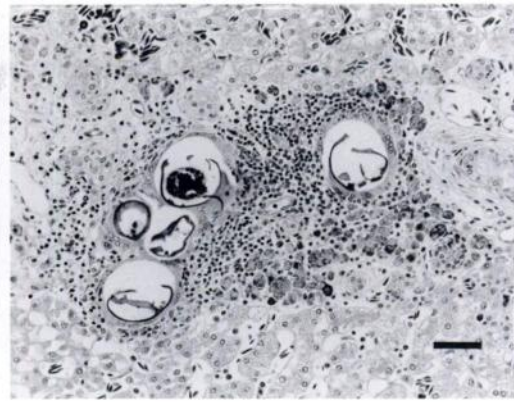


FIGURE 6. *Pseudemys concinna* (RTLA 5187) from Lake Blackshear, Georgia. A cluster of five spirorchid trematode eggs lodged in blood vessels of the liver have elicited an inflammatory host response consisting of epithelioid macrophages, lymphocytes and melanomacrophages. H&E. Bar = 50  $\mu$ m.

sloughed off leaving a crater rather than an elevated lesion.

The spleen of USNM 306823 and the liver of USNM 306817 and 306824 contained focal chronic inflammatory reactions (granulomas) in response to trematode eggs (Fig. 6). The bile ducts had a heavily fibrous cuff. No tumors were detected in the three specimens.

#### DISCUSSION

Biologists have known about shell deformities on turtles in Lake Blackshear for over 20 yr (Beltz, 1993). Based on our sample, shell disease appeared restricted to *P. concinna* and *T. scripta*. Damaged and sloughing scutes were observed in several specimens of *Graptemys barbouri* that are not typical of this species elsewhere in its range (Sanderson and Lovich, 1988), but no severe shell disease was observed as seen in *P. concinna* and *T. scripta*. Both *P. concinna* and *T. scripta* spend many hours of the day engaged in aerial basking (Ernst et al., 1994). In addition, both species are omnivorous with *P. concinna* tending to be more herbivorous (Ernst et al., 1994). With the exception of

*Graptemys barbouri*, none of the other turtle species in Lake Blackshear were observed basking as much as *P. concinna* and *T. scripta*. In fact, most are highly aquatic and tend to be carnivorous bottom-walkers (Berry and Shine, 1980). Because of dichotomy in disease incidence between guilds of semi-aquatic omnivorous turtles and highly aquatic carnivorous turtles, we propose that ecological differences are related to the etiology of shell disease.

Lesions on the shell of affected turtles appeared to be caused by a reactive fibrosis of the dermis which was continuous with an abnormal intertrabecular fibrosis within the bone itself. Islands of outwardly migrating bone probably were being created by the pits and fibrosis. On the carapace the material was piling up while on the plastron the material appeared friable enough to be sloughed off during movement over the substrate, leaving an ulcerated area of dehydrated bone. There was little evidence of new bone formation, but greater evidence of bone destruction by osteoclasts as well as inflammatory cells. The disease may have been caused by bacterial invasion of the keratin layer, leading to reactive dermal fibrosis extending into the bone, involuting epidermal pits, ulcer-

ation and inflammation, and excavation of the bone. The increase in fibrous tissue may have been part of the reactive reparative process. Clinically the diseased turtles appeared to be suffering from chronic shell dermatitis and osteitis with shell plate sloughing.

Shell disease also has been observed in a free-ranging population of desert tortoises (*Gopherus agassizii*) in southern California (Jacobson et al., 1994). The disease, termed cutaneous dyskeratosis, affects the shell and thickened forelimb scutes. Affected areas were gray-white and occasionally orange and had a roughened flaky appearance. Interestingly, the authors also observed that the plastron was more severely affected than other areas of the integument.

The trematode eggs that caused the granulomas observed in the liver and spleen of some specimens may have been shed by cardiovascular trematodes (Spirorchidae) which are common in some turtles. Wolke et al. (1982) described the pathologic response by loggerhead sea turtles (*Caretta caretta*) to some of these blood flukes and cited pertinent references. The heavily fibrous cuff observed in bile ducts is similar to that which we have seen in some fish from polluted areas, but reference turtle specimens from unaffected areas were not available for comparison.

Toxic or immunosuppressive chemicals may be predisposing factors in shell disease of turtles at Lake Blackshear. Differential effects among species may be a consequence of dietary habits, increased exposure to ultraviolet radiation, or other ecological and behavioral factors that are interactive. Jacobson et al. (1994) noted that cutaneous dyskeratosis in desert tortoises was suggestive of either a deficiency disease or toxicosis, although the exact cause of the disease could not be determined. Further study will be required to verify the role of these factors in the incidence of shell disease in turtles.

## ACKNOWLEDGMENTS

The following individuals assisted in the collection of turtles: Tony Mills, Trip Lamb, Laurie Vitt, Tony Tucker, Steve Sekscienski, Stanley Kemp, and Laura Elliot. Earlier versions of the manuscript benefitted from comments offered by Hal Avery and John McQuown. Research and manuscript preparation were supported by contract number DE-AC09-76SROO-819 between the United States Department of Energy and the University of Georgia, Savannah River Ecology Laboratory. Histopathology was supported by NIH Contract NOI-CP-15641 to the Smithsonian Institution and subcontract 95-59-MT-00004 from the Smithsonian Institution to the George Washington University Medical Center for the operation of the Registry of Tumors in Lower Animals.

## LITERATURE CITED

- BELTZ, E. 1993. Herpet-pourri. Bulletin of the Chicago Herpetological Society 28: 11-13.
- BERRY, J. F., AND R. SHINE. 1980. Sexual size dimorphism and sexual selection in turtles (Order Testudines). Oecologia 44: 185-191.
- DODD, C. K. 1988. Disease and population declines in the flattened musk turtle *Sternotherus depressus*. American Midland Naturalist 119: 394-401.
- ERNST, C. H., AND R. W. BARBOUR. 1989. Turtles of the world. Smithsonian Institution Press, Washington, D.C., 313 pp.
- , J. E. LOVICH, AND R. W. BARBOUR. 1994. Turtles of the United States and Canada. Smithsonian Institution Press, Washington, D.C., 578 pp.
- HERBST, L. H. 1994. Fibropapillomatosis of marine turtles. Annual Review of Fish Disease 4: 389-425.
- JACOBSON, E. R. 1993. Implications of infectious diseases for captive propagation and introduction programs of threatened/endangered reptiles. Journal of Zoo and Wildlife Medicine 24: 245-255.
- . 1994. Causes of mortality and disease in tortoises: A review. Journal of Zoo and Wildlife Medicine 25: 2-17.
- , J. M. GASKIN, M. B. BROWN, R. K. HARRIS, C. H. GARDINER, J. L. LAPOINTE, H. P. ADAMS, AND C. REGGIARDO. 1991. Chronic upper respiratory tract disease of free-ranging desert tortoises (*Xerobates agassizii*). Journal of Wildlife Diseases 27: 296-316.
- , T. J. WRONSKI, J. SCHUMACHER, C. REGGIARDO, AND K. H. BERRY. 1994. Cutaneous dyskeratosis in free-ranging desert tortoises, *Gopherus agassizii*, in the Colorado Desert of southern California. Journal of Zoo and Wildlife Medicine 25: 68-81.

- SANDERSON, R. A., AND J. E. LOVICH. 1988. *Graptemys barbouri*. Catalogue of American Amphibians and Reptiles 421.1–421.2.
- U.S. FISH AND WILDLIFE SERVICE. 1993. Draft recovery plan for the desert tortoise (Mojave population). U.S. Fish and Wildlife Service, Portland, Oregon, 170 pp.
- WILLIAMS, E. H., JR., L. BUNKLEY-WILLIAMS, E. C. PETERS, B. PINTO-RODRÍGUEZ, R. MATOS-MORALES, A. A. MIGNUCCI-GIANNONI, K. V. HALL, J. V. RUEDA-ALMONACID, J. SYBESMA, I. BONNELLY DE CALVENTI, AND R. H. BOULON. 1994. An epizootic of cutaneous fibropapillomas in green turtles *Chelonia mydas* of the Caribbean: Part of a panzootic? *Journal of Aquatic Animal Health* 6: 70–78.
- WOLKE, R. E., D. R. BROOKS, AND A. GEORGE. 1982. Spirochidiasis in loggerhead sea turtles (*Caretta caretta*): Pathology. *Journal of Wildlife Diseases* 18: 175–185.
- ZAR, J. H. 1984. Biostatistical analysis. Prentice-Hall, Inc. Englewood Cliffs, New Jersey, 718 pp.

*Received for publication 17 May 1995.*