

A CASE OF SPONDYLOSIS DEFORMANS IN THE DEFLESHED SKELETON OF A WILD COYOTE AND ITS SIGNIFICANCE TO OSTEOPATHOLOGIC INTERPRETATION

Author: Duckler, Geordie L.

Source: Journal of Wildlife Diseases, 33(2) : 211-219

Published By: Wildlife Disease Association

URL: <https://doi.org/10.7589/0090-3558-33.2.211>

BioOne Complete (complete.BioOne.org) is a full-text database of 200 subscribed and open-access titles in the biological, ecological, and environmental sciences published by nonprofit societies, associations, museums, institutions, and presses.

Your use of this PDF, the BioOne Complete website, and all posted and associated content indicates your acceptance of BioOne's Terms of Use, available at www.bioone.org/terms-of-use.

Usage of BioOne Complete content is strictly limited to personal, educational, and non - commercial use. Commercial inquiries or rights and permissions requests should be directed to the individual publisher as copyright holder.

BioOne sees sustainable scholarly publishing as an inherently collaborative enterprise connecting authors, nonprofit publishers, academic institutions, research libraries, and research funders in the common goal of maximizing access to critical research.

A CASE OF SPONDYLOSIS DEFORMANS IN THE DEFLESHED SKELETON OF A WILD COYOTE AND ITS SIGNIFICANCE TO OSTEOPATHOLOGIC INTERPRETATION

Geordie L. Duckler

Department of Biology, University of California, Los Angeles, 405 Hilgard Avenue,
Los Angeles, California 90024, USA

ABSTRACT: The skeleton of a wild coyote (*Canis latrans*), collected in Alturas, California (USA), in 1940 and reported to have died of a blowfly infection, was analyzed. The axial components, primarily a series of fused and deformed vertebrae, had classic osteological indications of spondylosis deformans, a trauma-induced disorder. Severe crippling due to a crushing-type strain was identified as the primary pathological condition to which the coyote succumbed, with death hastened by vertebral degeneration and the complicating infection.

Key words: Spondylosis deformans, coyote, *Canis latrans*, osteopathological.

INTRODUCTION

In this paper I describe vertebral deformations in a canid skeleton recognizable as having comprised a severely debilitating and ultimately fatal stress for the individual during its life. I used visual and radiographic cues from skeletal elements to establish a more precise diagnosis of the particular infirmity to which the animal had probably been subjected before death. Certain life stresses can be identified from bone even without the opportunity to examine the living animal. This study forms part of a larger paleontological project aimed at diagnosing stress in samples of isolated fossil elements for which no life history information is known. The osteologist's capability in assessing the health of individuals solely from preserved skeletal tissues—paramount in constructing health surveys of extinct species—is argued for here.

The recovered remains of a modern wild animal such as the North American coyote (*Canis latrans*) provide an excellent template on which to model a paleopathological analysis. On the one hand, long-term captive or domestic animals tend to manifest health conditions which are unusual with respect to the animal's natural physiological development (Wallach and Boever, 1983). On the other hand, too little is known about the morphology and anatomy of most exotics to support a sat-

isfactory skeletal analysis. The coyote is phylogenetically and anatomically close enough to the domestic dog that veterinary information on the latter's skeletal deformities may be useful in comparison. Finally, the axial skeleton in general is remarkably sensitive to life history insults, and vertebral deformations are in particular a relatively fruitful area in which to look for osteopathological signals (Barnes, 1994).

MATERIALS AND METHODS

The skull and skeleton of a wild-living North American male coyote (USNM 265986) obtained from the United States National Museum, was examined for gross anatomical defects. The skeleton had been collected on 15 August 1940, in Alturas, California (USA) (41°29'N, 120°32'W), by F. B. McNulty, under the auspices of a United States Biological Survey. The specimen's collection tag included a single remark: "Died of maggot infection—screw-worm?".

The axial skeleton was represented by the skull; 13 pairs of ribs and associated sternebral elements, including the xiphoid process and manubrium; all vertebrae, apart from six middle thoracic vertebrae (T5 through T10); and an undeterminable number of distal coccygeal elements.

With respect to the appendicular skeleton, all elements were present apart from a few sesamoids and distal phalangeal elements. No baculum was present.

All elements were inspected with hand lens and microscope, with particular attention paid to the vertebral column. In addition, the spec-




FIGURE 1. Whole view, cranial portion of vertebral column in USNM 265986 (anterior to right).

imen was scanned using computed tomography (C-T) and then compared against the skeleton of another male coyote of the same subspecies (UCLA 15470), obtained from the Dickey Collection at the University of California, Los Angeles, California. The comparative specimen had been collected on 21 March 1929, from the Sacramento Valley in Mohave County, Arizona (USA) (34°52'N, 114°09'W), by W. Gasto, again as part of a United States Biological Survey. The comparative specimen appeared osteologically normal.

Anatomic, veterinary and radiologic reference atlases were consulted, including Miller (1964) on anatomy of the dog; Schmidt and Hubbard (1987) on wild animal pathologies; Edeiken (1981) and Carlson (1967) on animal radiography; and Forrester and Brown (1987) on radiography of joint diseases.

RESULTS

In overall gross aspect, the appendicular skeleton was unremarkable. The axial portion presented a picture of severe and tortuous osteophytic deformity.

In the skull, the braincase had a slightly reduced left occipital condyle. The vertebral column itself had been prepared as two separated sections, consisting of a cranial and a caudal component. In the cranial section, composed of all elements between the atlas and the fifth thoracic vertebrae, all segments were defective (Fig. 1). The atlas had a reduced dorsal arch, compressed wings constricting the left transverse and the right intervertebral fo-

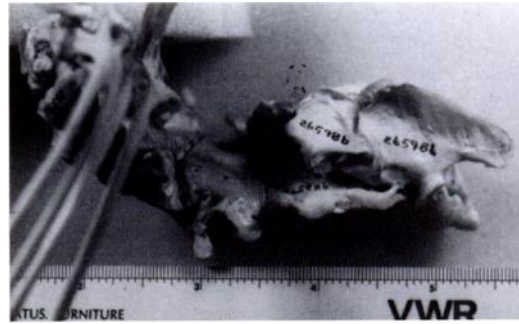


FIGURE 2. Detail on axis, third, fourth and fifth vertebrae, lateral aspect (anterior to right); scale in cm.

ramina, and a left alar notch covered by osteophytic deposits on its ventral surface.

The axis had a solid bony bond with the third through fifth cervical vertebrae (C3 through C5), with only the transverse processes distinct (Fig. 2). Articular surface plates were observable on C6 and C7, although the transverse processes had consolidated into a mass of undifferentiated osteophytic material with what had once been the first through fourth thoracic vertebrae (T1 through T4). While the fovea of the right transverse processes of T1 through T4 maintained connections with their associated ribs, processes on the left had deformed and lost distinction in articular surface structure. Two separate fusions of spinous processes had taken place, of T1 with T2, and of T3 with T4 (Fig. 3). The region between C3 and T4 was also bent ventrally in the longitudinal plane. As noted, T5 through T10 were missing.

In the caudal component of the column (Fig. 4), T11 was laterally twisted and T12 and T13 had a dorsal overlap of spinous and accessory processes along with tightly bonded ventral surfaces. The twelfth thoracic vertebrae did not possess articulating ribs, although fovea were identifiable. The vertebral foramen was exposed dorsally on both T11 and T12 in the mid-sagittal plane, the neural arches having bifurcated (Fig. 5). The edges of the resultant notch were smooth and rounded.

The articular surfaces on the left side of

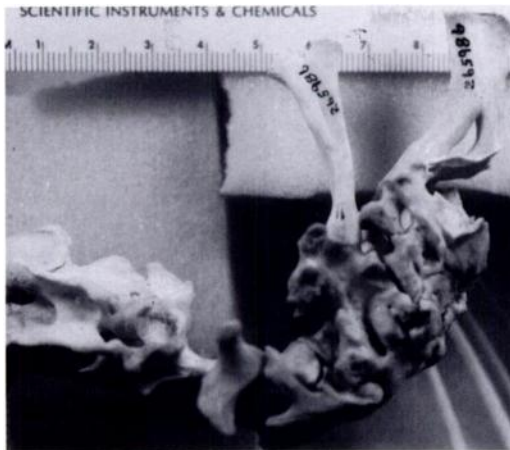


FIGURE 3. Detail on spinous processes of first through fourth thoracic vertebrae, lateral aspect (anterior to left).

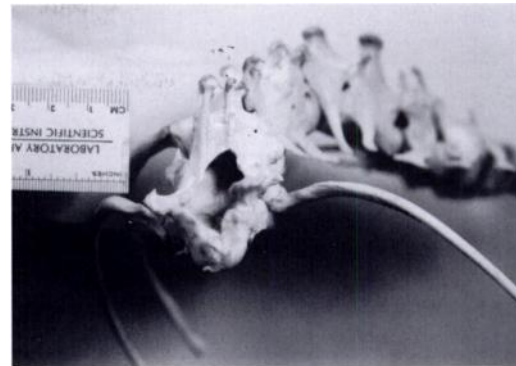

FIGURE 5. Detail in opening of vertebral foramen in eleventh and twelfth thoracic vertebrae (cranial view).

the first two lumbar vertebrae were completely fused, while the spinous processes of the first three lumbar vertebrae (L1 through L3) were bent so as to abut the adjoining left mamillary processes. The first lumbar vertebra's left caudal articular process had extended caudally to articulate with L3's left mamillary, bypassing L2's dorsal surface (Fig. 6). The third and fourth lumbar vertebrae had fused into a single bony mass, as had L6 and L7. The dorsal surface of the right caudal border of L5 interfered with the dorsal surface of the entire cranial border of L6 in the manner of interlocking puzzle pieces (Fig. 7). The seventh lumbar had no spinous process

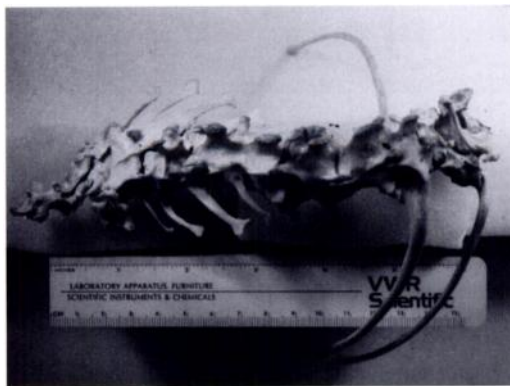


FIGURE 4. Whole view, caudal portion of vertebral column (anterior to right).

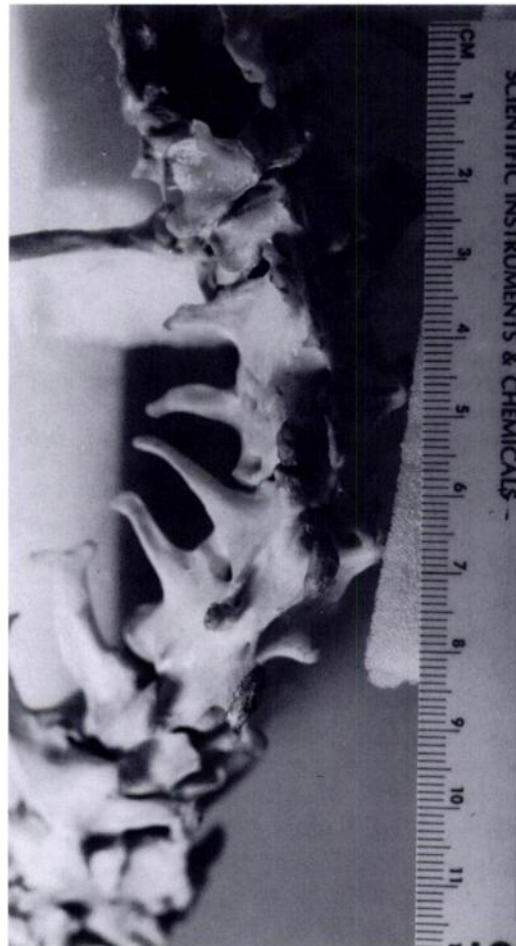

FIGURE 6. Detail on first three lumbar vertebrae, dorsal aspect (anterior to left).



FIGURE 7. Detail on fifth and sixth lumbar vertebrae, dorsal aspect (anterior to top).

and appeared laterally flared and dorso-ventrally flattened. The ventral surfaces of L6 and L7 overlapped considerably with each other and with part of L5, again forming an indistinct osteophytic mass (Fig. 8).

Only the cranial wings were distinct on the sacrum. As with the terminal thoracics, the dorsal surface had opened, exposing the vertebral foramen by a river-like infolding which continued onto the surfaces of the first several coccygeal vertebrae (Fig. 9). The few coccygeal vertebrae present formed a final indistinguishable mass.

Overall, under the C-T scans, I observed massive misalignment and disruption of the vertebral canal at all articulations. The internal architecture appeared generally malformed. In all vertebrae, ventral and lateral osteophytic material

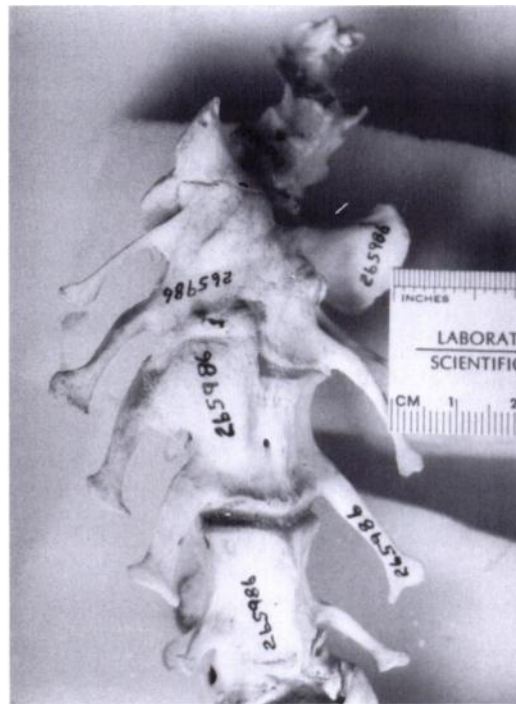


FIGURE 8. Detail on fifth and sixth lumbar vertebrae, ventral aspect.

buildup created internal osseous bridges, uniting and frequently obliterating anatomical features of each successive vertebral body.

DISCUSSION

Spondylosis deformans is the technical designation for any stiffening or fixation

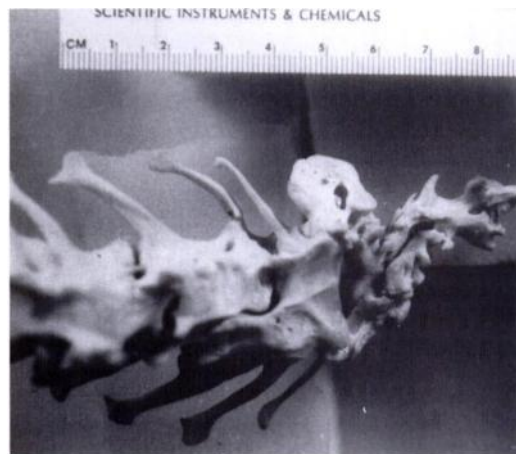


FIGURE 9. Detail on sacrum and caudal vertebrae, dorsal aspect (anterior to left).

(ankylosis) of a series of vertebral bodies in the animal skeleton. The distinction between deformans and other forms of spondylosis was first introduced by Schmorl and Junghanns (1959). As a distinct vertebral disorder, deformans is characterized primarily by the presence of osteophytes on the bodies at the intervertebral spaces (Morgan et al., 1967), as well as by degeneration of the intervertebral disks themselves (Smith, 1968). In severe cases, new bone formation occurs between each vertebral body to such an extent that adjoining elements become bridged or fused tightly together (Hultgren et al., 1987). Osteogenesis also occurs in later stages of the disorder, and where new bone formation progresses sufficiently so as to encroach on contiguous structures, entire regions of vertebral joints may become mechanically inoperable in consequence (Smith, 1968). Extensive regions of bone proliferation can become smooth after covering sites which were formerly separate and adjacent, and present a texture comparable to a mold (Schmorl and Junghanns, 1959). Spondylosis deformans, described predominantly in humans, has also been observed in the vertebrae of bulls, pigs and dogs, but is rare in most other mammals (Hultgren et al., 1987). In older dogs, particularly, a mild form of the condition is frequently encountered; that is, where one or two osteophytes have developed marginal to a single vertebral body (Langeland and Lingaas, 1995). Clinical significance attaches to the disorder only after several vertebrae have become involved (Wheeler and Sharp, 1994).

Because degeneration of the intervertebral disk is the primary factor in the pathogenesis of spondylosis deformans (Ruge, 1977), consequential changes such as compression tend to progressively impair column efficiency; the normal buffer properties of the vertebrae are lost, increasing the chances of further damage with each new spinal pressure (Smith, 1968). Secondary collapse of the vertebral nuclei escalates the damage, placing great-

er shearing, rotational, and tractional stresses on associated ligaments and joints (Wilkinson, 1967). Much of the epaxial musculature and connective tissue overlaying the affected region thereby undergo pathological changes, resulting in derangement of nerve roots and of the spinal cord itself; spinal cord lesions also often appear (Wilkinson, 1967). Muscular atrophy results in advanced cases and interference with spinal innervations may reach a stage where the damage to postural responses, muscular reflexes and limb orientation is irreversible (Brain and Wilkinson, 1967).

Symptoms can manifest anywhere from less than 3 wk after the first primary change to more than 3 yr later (Smith, 1968). The condition is most common and severe at those areas where movement is greatest (Smith, 1968). Severely stricken individuals are restrained in functional movement of the spinal cord, and eventually die of immobility-related causes (Seawright and English, 1964).

Clinical diagnosis of spondylosis deformans in humans is almost always made upon investigation of neurological abnormalities caused by compressed nerve roots (Smith, 1968). The diagnosis is confirmed by radiography, myelography and laboratory tests. In most non-human cases, behavioral clues prompt identification (Hultgren et al., 1987), although veterinarians commonly rely upon osteological information obtained in necropsy (Seawright et al., 1967). Based on a review of the veterinary and zooarchaeological literature, I found no evidence that the condition has been diagnosed in a defleshed animal skeleton.

In the specimen described here, the fusion and distortion rampant in the cervical and thoracic groups, the exposure of the vertebral foramen, the osteophyte formation between vertebral bodies at their margins, and the smoothed-over appearance to the vertebral borders were all consistent with previously described spondylosis deformans effects (Wilkinson, 1967; Schmorl and Junghanns, 1959). The extensive col-

lapsing of post-atlantal cervical vertebrae also appeared quite characteristic (Wilkinson, 1967). Based on C-T scans, the vertebral bodies had internally fused in such a manner as to constrain dorsoventral movement of the column, a specific signal of the disorder (Wilkinson, 1967). The vertebral canal's generally shrunken appearance was evidence for compression and deterioration of the spinal cord shortly before death, a state primarily consonant with spondylosis deformans (Hultgren et al., 1987). Finally, the column as a whole appeared strikingly similar to an illustrative depiction of the condition in the macerated skeleton of a domestic cat (Seawright and English, 1964). In the absence of clinical findings, it is true that a diagnosis of spondylosis deformans is open to alternative interpretation and cannot be conclusive; nevertheless, all the available morphological signs taken together, especially the distinctive signature reaction of extensive bony bridging at intervertebral spaces, makes the diagnosis the most appropriate under the circumstances presented.

Trauma is the most commonly assigned cause for the condition, and most cases described have been attributed to mechanically-induced defects (Smith, 1968). Excessive flexion or hyperextension of the spine, continuous and heavy strain on the back, or a blunt, crushing blow may be initially responsible (Hultgren et al., 1987). In humans, the disorder is associated with, and perhaps caused by, strenuous physical work (Julkunen et al., 1981). Any traumatic or overloading event could therefore have precipitated the condition in this animal. Once initiated, spondylosis advances progressively with age, being a degenerative condition (Lombardi and Passerini, 1964). Physiologically, the resultant compression of the spinal cord compromises blood flow and affects signal conduction at the nerve roots achieving an ever-increasing resistance to engaging in normal motions (Ruge, 1977). The large-scale clinical significance of the disorder is that it re-

flects underlying skeletal, neurological and vascular instability which, by a certain stage, cannot be reversed (Wheeler, 1992; Wheeler and Sharp, 1994).

The cause of death recorded by the collector, maggot or screwworm infection, is instructive. *Lucilia hominivorax* is a species of blowfly (Diptera: Calliphoridae) commonly known as the screw-worm or blue-bottle fly (James, 1955). *Lucilia* spp. individuals lay their eggs in the nostrils or open wounds of the host. A lesion as small as a tick bite is sufficient to admit entry to the larvae, which are specific for necrotic tissue (Abram and Froimson, 1987). Most often, wild and domestic animals serve as hosts, primarily deer (*Odocoileus* spp.), cattle, sheep and goats; infrequently, human (Abram and Froimson, 1987) and canid (Wetzel and Fischer, 1971) hosts have been recorded. The larvae, obligate parasites called screw-worms, give rise to myiasis.

Secondary severe infection arising from myiasis can be fatal (Abram and Froimson, 1987), and the state of the body upon death is sufficiently characteristic that the field remarks on this specimen had validity. The coyote's infection with screw-worm larvae, nevertheless, must have required either incapacity or wounding, prerequisites perfectly consistent with a trauma capable of generating a spondylitic condition. The extensive vertebral distortions here were constructed over a much longer period of time than that in which a death-inducing blowfly infection would have required to take effect.

It may be surmised that the entire constellation of physiological phenomena associated with late-stage spondylosis deformans was experienced by the coyote, including locomotor pain in the pectoral and pelvic girdles, loss of coordination and dexterity in all limbs, generalized muscle spasm, and appendicular sensory impairment (Smith, 1968). It is almost certain that the normal range of maneuverability in locomotion was impaired in the animal.

Other vertebral disorders produce col-

umn alterations similar to spondylosis deformans, and differential diagnosis is required. I considered three alternatives: congenital or developmental deformity, osteoarthritis, and diffuse idiopathic skeletal hyperostosis (DISH).

First, the defects analyzed here shared some tangential similarities with congenital anomalies previously described in domestic dogs. In one case, a 4-mo-old Rottweiler was observed to have fused cervical vertebrae such that disk spaces and articulations were unrecognizable (Van den Brande and Dennis, 1994). The investigators diagnosed the condition as complex congenital abnormality in the absence of any history of previous trauma. In another case, a malformed occipito-atlanto-axial complex in a 13-wk-old Saint Bernard was also diagnosed as an undefined congenital abnormality (Watson et al., 1988). In both cases, the conditions observed were incompatible with life. A more well-described congenital defect which often mimics some spondylotic-type vertebral changes is spina bifida, generally defined as the absence of a portion of the dorsal elements of the vertebrae owing to failure of formation during embryonic development (Bailey and Morgan, 1992). Spina bifida is the most common aspect of a larger pathological complex involving the defective fusion of structures that otherwise normally unite (Bailey and Morgan, 1992). The exposed dorsal surfaces of T11, T12, and the coccygeal vertebrae in this specimen did present a slight bifid appearance, suggesting spina bifida.

Nevertheless, the morphological nature of the entire column's malformations, when examined with the age of the animal in mind, necessarily precludes a diagnosis of congenital defect, including of spina bifida. One, due to the incomplete closure of the neural arch or the incomplete fusion of spinous processes, spina bifida typically results in a widening of the spinal canal and thinning of the pedicles (Craigmile, 1977); the spinal canal in this specimen had, to the contrary, been narrowed over-

all and many pedicles enlarged by osteogenesis, two trends which characteristically occur in spondylosis (Ruge, 1977; Lombardi and Passerini, 1964). Two, a sign of advanced spina bifida is the absence of dorsal spinous processes (Parker et al., 1973); here, the only vertebrae from which spinous processes were absent were C3 through C7 and the sacrum. Moreover, in the cervical elements, it appeared that processes had quite likely originally existed and had subsequently fused or merged onto the dorsal surface. The emergence and consequent resorption of vertebral structures is entirely inconsistent with spina bifida (Roessmann, 1986; Stark, 1977). Three, congenital skeletal or spinal cord abnormalities register, as a rule, significant clinical signs well within the first year of life (Moore, 1992). Indeed, in the overwhelming majority of cases of spina bifida reported in canids, as with the idiopathic congenital defects described above, conditions are already in an advanced and essentially lethal stage in infant or young juvenile animals ranging from neonate to 9-mo-old (Clayton and Boyd, 1983; Wilson et al., 1979; Parker et al., 1973; Chesney, 1973; Furneaux et al., 1973). The coyote examined, on the other hand, was no juvenile but a large, fully-developed adult; no individual could have survived to adulthood with defects such as those which this animal possessed being present at birth, even had they originated in a milder state. The pathological problems in this coyote stemmed from overgrowth, proliferation, and fusion of bone in response to an outside agent, not to a failure of bone to form properly.

A second alternative diagnosis was osteoarthritis. The fact that the balance of this animal's skeleton was unaffected in any way precluded that diagnosis, however. In canids, most cases of arthritis involve degenerative skeletal changes (Olsson, 1971). Osteoarthritis in particular, however, would certainly be expected to result in responses in articulating appendicular elements, or in distal areas of the skeleton

(Fox, 1939; Cross, 1940; Mahan and Gipson, 1978); but no extra-vertebral changes were observed. In addition, vertebral involvement is not even considered an essential diagnostic criterion in canid osteoarthritis (Rothschild and Rothschild, 1994). Even then, radiological changes produced in the spine by arthritic effects are much more likely to appear as eroded, rather than sclerotic or collapsed, vertebral plates (Young, 1967).

Finally, the flowing ossification of the vertebral processes is slightly consistent with DISH (Woodard et al., 1985), but that disorder almost always affects the pelvis and appendages, creating osteophytes and spurs throughout limb joint surfaces (Utsinger, 1984). No structures of that nature were presented.

The diagnosis demonstrates the potential of osteopathological analysis for increasing the accuracy of health records compiled from field notes. In sum, the differential diagnosis of spondylosis deformans is possible in dry skeletal tissues because of the disorder's restricted vertebral involvement. In advanced stages, the marked rigidity between vertebrae and the marginal exostoses at vertebral joints are idiosyncratic (Seawright et al., 1967). Although the disorder is usually restricted to the thoracic and lumbar regions of the spine (Morgan et al., 1967), cervical attacks are not uncommon (Hultgren et al., 1987). It is reasonable to believe that a late-stage attack of the disorder in a living coyote would create the impacts produced in this specimen, complicated by an infection reaction.

ACKNOWLEDGMENTS

I thank L. Gordon and R. Thorington at the United States National Museum in Washington, D.C., as well as G. Daleo of Children's Hospital in San Diego for assistance on this project. In addition, I thank B. Van Valkenburgh and two anonymous reviewers for providing useful comments on earlier drafts of this manuscript.

LITERATURE CITED

- ABRAM, L. J., AND A. I. FROMISON. 1987. Myiasis (maggot infection) as a complication of fracture management. *Orthopedics* 10: 625-627.
- BAILEY, C. S., AND J. P. MORGAN. 1992. Congenital spinal malformations. *Veterinary Clinics of North America: Small Animal Practice* 22: 985-1016.
- BARNES, E. 1994. Developmental defects of the axial skeleton in paleopathology. University Press of Colorado, Nivot, Colorado, 360 pp.
- BRAIN, L., AND M. WILKINSON. 1967. Symptomatology. In *Cervical spondylosis and other disorders of the cervical spine*, L. Brain and M. Wilkinson (eds.), W. B. Saunders Company, Philadelphia, Pennsylvania, pp. 124-132.
- CARLSON, W. 1967. *Veterinary radiology*. Lea and Febinger, Philadelphia, Pennsylvania, 666 pp.
- CHESNEY, C. J. 1973. A case of spina bifida in a chihuahua. *The Veterinary Record* 93: 120-121.
- CLAYTON, H. M., AND J. S. BOYD. 1983. Spina bifida in a German shepherd puppy. *The Veterinary Record* 112: 13-15.
- CRAIGMILE, T. K. 1977. Congenital anomalies of the spine. In *Spinal disorders*, D. Ruge (ed.), Lea and Febinger, Philadelphia, Pennsylvania, pp. 223-248.
- CROSS, E. C. 1940. Arthritis among wolves. *The Canadian Field-Naturalist* 54: 2-4.
- EDEIKEN, J. 1981. Roentgen diagnosis of diseases of bone. In *Section 6 of Golden's Diagnostic Radiology*, J. H. Harris (ed.), Williams and Wilkins, Baltimore, Maryland, 1,557 pp.
- FORRESTER, D. M., AND J. C. BROWN. 1987. *The radiology of joint disease*. W. B. Saunders Company, Philadelphia, Pennsylvania, 568 pp.
- FOX, H. 1939. Chronic arthritis in wild animals. *Transactions of the American Philosophical Society* 31: 73-148.
- FURNEAUX, R. W., C. E. DOIGE, AND M. M. KAYE. 1973. Syringomyelia and spina bifida occulta in a samoyed dog. *Canadian Veterinary Journal* 14: 317-321.
- HULTGREN, B. D., E. WALLNER-PENDLETON, B. J. WATROUS, AND L. L. BLYTHE. 1987. Cervical dorsal spondylosis with spinal cord compression in a black swan (*Cygnus atratus*). *Journal of Wildlife Diseases* 23: 705-708.
- JAMES, M. T. 1955. The blowflies of California. *Bulletin of the California Insect Survey*, Vol. 4, Number 1. University of California Press, Berkeley, California, 34 pp.
- JULKUNEN, H., P. KNECKT, AND A. AROMAA. 1981. Spondylosis deformans and diffuse idiopathic skeletal hyperostosis (DISH) in Finland. *Scandinavian Journal of Rheumatology* 10: 193-203.
- LANGELAND, M., AND F. LINGAAS. 1995. Spondylosis deformans in the boxer: estimates of heritability. *Journal of Small Animal Practice* 36: 166-169.
- LOMBARDI, G., AND A. PASSERINI. 1964. Spinal cord

- diseases: A radiologic and myelographic analysis. Williams and Wilkins Company, Baltimore, Maryland, 175 pp.
- MAHAN, B. R., AND P. S. GIPSON. 1978. Osteoarthritis in a coyote \times dog hybrid from Nebraska. *Journal of Wildlife Diseases* 14: 395–398.
- MILLER, M. 1964. *Anatomy of the dog*. W. B. Saunders Company, London, United Kingdom, 941 pp.
- MOORE, M. P. 1992. Approach to the patient with spinal disease. *Veterinary Clinics of North America: Small Animal Practice* 22: 751–780.
- MORGAN, J. P., G. LJUNGGREN, AND R. READ. 1967. Spondylosis deformans (vertebral osteophytosis) in the dog. *Journal of Small Animal Practice* 8: 57–66.
- OLSSON, S. 1971. Degenerative joint disease (osteoarthritis): A review with special reference to the dog. *Journal of Small Animal Practice* 12: 333–342.
- PARKER, A. J., R. D. PARK, C. S. BYERLY, AND J. L. STOWATER. 1973. Spina bifida with protrusion of spinal cord tissue in a dog. *Journal of the American Veterinary Association* 163: 158–160.
- ROESSMANN, U. 1986. The embryology and pathology of dysraphias. In *Spina bifida—neural tube defects*, D. Voth and P. Glees (eds.), Walter de Gruyter Company, Berlin, Germany, pp. 17–20.
- ROTHSCHILD, B., AND C. ROTHSCCHILD. 1994. No laughing matter: Spondyloarthropathy and osteoarthritis in *Hyaenidae*. *Journal of Zoo and Wildlife Medicine* 25: 259–263.
- RUGE, D. 1977. Spondylosis. In *Spinal disorders*, D. Ruge (ed.), Lea and Febiger, Philadelphia, Pennsylvania, pp. 315–322.
- SCHMIDT, R. E., AND G. B. HUBBARD. 1987. *Atlas of zoo animal pathology. I. Mammals*. CRC Press, Boca Raton, Florida, 355 pp.
- SCHMORI, G., AND H. JUNGHANS. 1959. *The human spine in health and disease*. Grune and Stratton, New York, New York, 285 pp.
- SEAWRIGHT, A. A., AND P. B. ENGLISH. 1964. Deforming cervical spondylosis in the cat. *Journal of Pathology and Bacteriology* 88: 503–509.
- , ———, AND R. J. W. GARTNER. 1967. Hypervitaminosis A and deforming cervical spondylosis of the cat. *Journal of Comparative Pathology* 77: 29–43.
- SMITH, B. H. 1968. Cervical spondylosis and its neurological complications. Charles C. Thomas Company, Springfield, Illinois, 231 pp.
- STARK, G. D. 1977. *Spina bifida: Problems and management*. Blackwell Scientific Publications, Oxford, United Kingdom, 192 pp.
- UTSINGER, P. D. 1984. Diffuse idiopathic skeletal hyperostosis (DISH, ankylosing hyperostosis). In *Osteoarthritis: Diagnosis and Management*, R. W. Moskowitz (ed.), W. B. Saunders Company, Philadelphia, Pennsylvania, pp. 225–233.
- VAN DEN BRANDE, P., AND R. DENNIS. 1994. Congenital anomaly of the cervical vertebral column of a dog. *The Veterinary Record* 135: 436.
- WALLACH, J. D., AND W. J. BOEVER. 1983. *Diseases of exotic animals*. W. B. Saunders Company, Philadelphia, Pennsylvania, 1,159 pp.
- WATSON, A. G., A. DE LAHUNTA, AND H. E. EVANS. 1988. Morphology and embryological interpretation of a congenital occipito-atlanto-axial malformation in a dog. *Teratology* 38: 451–459.
- WETZEL, V. H., AND P. FISCHER. 1971. Wundinfektion beim Hund durch die Schmeissfliege *Lucilia caesar* (Linnaeus, 1758) (*Diptera: Calliphoridae*). *Deutsche Tierärztliche Wochenschrift* 78: 351–3.
- WHEELER, S. J. 1992. Lumbosacral disease. *Veterinary Clinics of North America: Small Animal Practice* 22: 937–950.
- , AND N. J. H. SHARP. 1994. *Small animal spinal disorders: Diagnosis and surgery*. Mosby-Wolfe, London, 224 pp.
- WILKINSON, M. 1967. Pathology. In *Cervical spondylosis and other disorders of the cervical spine*, L. Brain and M. Wilkinson (eds.), W. B. Saunders Company, Philadelphia, Pennsylvania, pp. 98–123.
- WILSON, J. W., H. J. KURTZ, H. W. LEIPOLD, AND G. E. LEES. 1979. Spina bifida in the dog. *Veterinary Pathology* 16: 165–179.
- WOODARD, J., P. W. POULOS, R. B. PARKER, R. I. JACKSON, AND J. C. EURELL. 1985. Canine diffuse idiopathic skeletal hyperostosis. *Veterinary Pathology* 22: 317–326.
- YOUNG, A. C. 1967. Radiology and cervical spondylosis. In *Cervical spondylosis and other disorders of the cervical spine*, L. Brain and M. Wilkinson (eds.), W. B. Saunders Company, Philadelphia, Pennsylvania, pp. 133–196.

Received for publication 4 June 1996.