

Abnormal Antler Growth Associated with Testicular Hypogonadism in Red Deer

Authors: Carrasco, L., Fierro, Y., Sánchez-Castillejo, J. M., Hervás, J., Pérez, J., et al.

Source: Journal of Wildlife Diseases, 33(3) : 670-672

Published By: Wildlife Disease Association

URL: <https://doi.org/10.7589/0090-3558-33.3.670>

BioOne Complete (complete.BioOne.org) is a full-text database of 200 subscribed and open-access titles in the biological, ecological, and environmental sciences published by nonprofit societies, associations, museums, institutions, and presses.

Your use of this PDF, the BioOne Complete website, and all posted and associated content indicates your acceptance of BioOne's Terms of Use, available at www.bioone.org/terms-of-use.

Usage of BioOne Complete content is strictly limited to personal, educational, and non - commercial use. Commercial inquiries or rights and permissions requests should be directed to the individual publisher as copyright holder.

BioOne sees sustainable scholarly publishing as an inherently collaborative enterprise connecting authors, nonprofit publishers, academic institutions, research libraries, and research funders in the common goal of maximizing access to critical research.

Abnormal Antler Growth Associated with Testicular Hypogonadism in Red Deer

L. Carrasco, Y. Fierro, J. M. Sánchez-Castillejo, J. Hervás, J. Pérez and J. C. Gómez-Villamandos, Department of Anatomy and Comparative Pathology, Faculty of Veterinary Medicine, University of Córdoba, Avda Medina Azahara 7, 14005-Córdoba, Spain

ABSTRACT: A wild 5-yr-old red deer (*Cervus elaphus*) was culled from a privately owned herd because of deformed antlers, retained velvet and bilateral symmetrical testicular hypogonadism. The clinical and pathological changes seen in this deer were most consistent with congenital hypoplasia, but testicular atrophy was an alternative possibility for the etiology of their condition.

Key words: Antlers, *Cervus elaphus*; red deer, testes, testicular hypogonadism.

Although reports of testicular lesions in ruminants are numerous, these refer mainly domestic cattle (Krishnalingam et al., 1982; Settergren and McEntee, 1992) and sheep (Bruere et al., 1969; Watt, 1978). Testicular pathology is poorly documented in wild animals (Taylor et al., 1964; Murphy and Clugston, 1971; DeMartini and Connolly, 1975).

The term hyporchidism, or hypogonadism, usually refers to those cases in which it is difficult to differentiate grossly between atrophy and hypoplasia because in both cases the testes appear homogeneous, smooth and firmer than normal (Watt, 1978). Even microscopically, differentiation may be difficult due to similar degeneration of seminiferous tubules, interstitial fibrosis, and infiltration of lymphoid cells or histiocytes which are characteristic changes of a testicular atrophy and some cases of hypoplasia (Watt, 1978).

In cervids, a bilateral testicular degeneration in wild mule deer (*Odocoileus hemionus hemionus*) (Murphy and Clugston, 1971), a testicular atrophy in black-tailed deer (*Odocoileus hemionus columbianus*) (DeMartini and Connolly, 1975) and bilateral hypogonadism in white-tailed deer (*Odocoileus virginianus*) (Taylor et al., 1964) have been described. In the two latter cases, the animals had retained vel-

vet (Taylor et al., 1964; DeMartini and Connolly, 1975).

As part of a wild red deer (*Cervus elaphus*) breeding program on a privately owned farm of approximately 1,000 ha in central Spain (38°55'N, 0°36'E) a 5-yr-old stag, that weighed 146 kg, was slaughtered because of deformed antlers. The bay tine grew into the brow tine and the antlers remained in velvet, although the velvet is normally shed during the autumn period of heightened sexual activity. In addition to the antlers abnormalities, the animal lacked secondary sex characteristics, such as a thickened neck.

Due to the alteration of the antlers, the animal was through examined for abnormalities such as endocrine gland tumours or the presence of ovarian tissue. However, at post-mortem examination, the only macroscopic alteration was in the testes (Fig. 1), which were small (~2 cm long and 1, 5 cm in diameter) and hard. However, the epididymis appeared normal in size and consistency. Testes collected from normal adult red deer were approximately 6 cm long and 3 cm in diameter.

Samples from testes and epididymis were fixed in buffered 10% formalin and routinely processed for histological analysis. Sections 4 µm thick were stained with hematoxylin and eosin and the PAS reaction.

Microscopically, the seminiferous tubules were small and almost completely filled with hyalin material, giving the appearance of "ghost tubules" (Fig. 2). Germinal cells were absent and there were few Sertoli cells. The interstitial tissue was thickened (Fig. 2), and isolated groups of apparently inactive Leydig cells were surrounded by fibrous connective tissue. Sper-

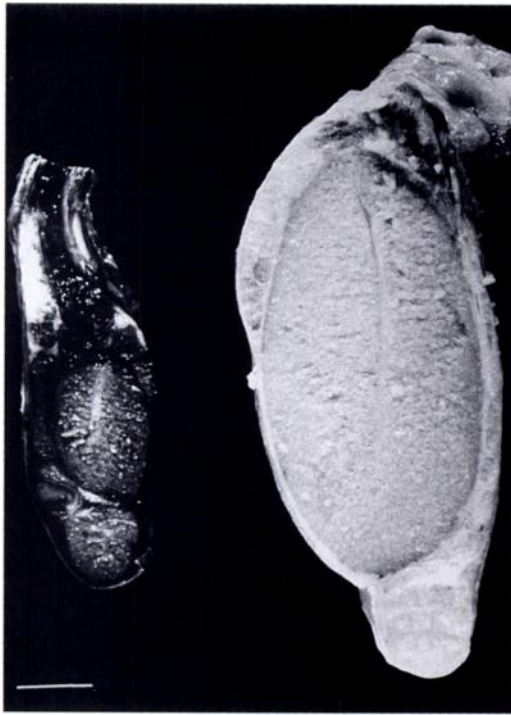

FIGURE 1. Testis of deer with testicular hypoplasia compared with a testis of a normal deer of similar age. Bar = 1 cm.

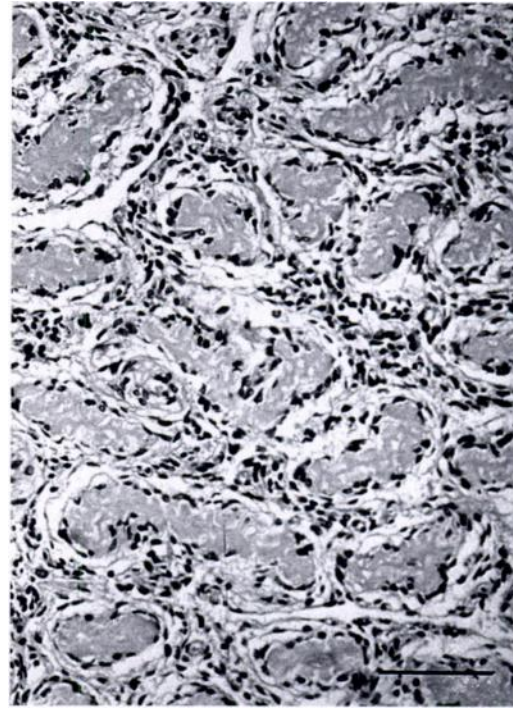


FIGURE 2. Histological section of the hypoplastic testis showing seminiferous tubules of small size, with hyalin material in the lumens, absence of germinal cells, and increased interstitial tissue. H & E. Bar = 100 μ m.

matzoa were not present in the epididymis.

Differentiation of testicular hypoplasia from atrophy is difficult. In the absence of appropriate history, as in the present case, it is impossible. A history of antler development is most important. In cervids, failure to shed antler velvet has been attributed to lack of testosterone (Taylor et al., 1964; Robinson et al., 1967). In cases of testicular atrophy and of bilateral hypogonadism, retention of antler velvet have been reported (Taylor et al., 1964; Robinson et al., 1967; DeMartini and Connolly, 1975), but antler abnormalities have been described only in some cases of testicular atrophy (Taylor et al., 1964; Robinson et al., 1967). If the animal had abnormal antlers every year since puberty, the testicular changes are probably due to hypoplasia (Robinson et al., 1967). However, if the animal had previous antler growth and shedding, this shows and ac-

tive testicular participation with waxing and waning androgen, and the testicular lesion is probably atrophy.

In cervids with testicular atrophy the epididymus was relatively large compared to the testes (Taylor et al., 1964; DeMartini and Connolly, 1975); atrophied testes were less than one half of the length and diameter of normal testes, but their proportional shapes had been retained (Taylor et al., 1964). These characteristics are similar to those seen in our case. Histologically, a substantial reduction, or absence, of germinal epithelium and absence of spermatozoa have been described in testicular atrophy (Taylor et al., 1964; DeMartini and Connolly, 1975). However, in testicular atrophy the parenchyma is replaced by connective tissue (DeMartini and Connolly, 1975), while in hypogonadism only a thickening of the interstitial tis-

sue has been observed (Taylor et al., 1964).

Possible etiologies of hyporchidism include an inflammatory process, a vascular obstruction and a toxicity or congenital hypoplasia. An infectious or inflammatory process was excluded in our case due to lack of an inflammatory infiltrate or connective tissue replacement (Taylor et al., 1964; DeMartini and Connolly, 1975). Vascular obstruction is characterized by a testicular infarct (DeMartini and Connolly, 1975). In white-tailed deer antler abnormalities associated with bilateral hypogonadism were attributed to a plant toxicity. This condition was present in a specific geographical area and had a high incidence (Taylor et al., 1964; Robinson et al., 1967). However, the present case involved a single animal, and the owner had not previously observed similarly affected animals.

Since hypogonadism was bilateral, symmetrical and with normal anatomical relationships in the present case, this indicates a possible genetic defect. In domestic cattle (Bongso et al., 1981) and sheep (Bruere et al., 1969; Bruere, 1970) bilateral testicular hypoplasia has been related to chromosomal alterations. A chromosomal study could not be performed in the present case because only formalin fixed tissue samples were available. However, the clinical and pathological changes were similar to Klinefelter's syndrome in humans, which is characterized by sterility, microorchidism and gynaecomastia (Ferguson-Smith and Glasg, 1958; Dunn et al., 1980). The histopathological characteristics of this syndrome are lack of spermatogenesis (Bruere et al., 1969; Logue et al., 1979), hyalinization and the presence of ghost tubules (Ferguson-Smith and Glasg, 1958), and the presence of few Sertoli cells and a normal number of Leydig cells (Bruere et al., 1969; Dunn et al., 1980).

LITERATURE CITED

- BRUERE, A. N. 1970. Some clinical aspects of hyporchidism (small testes) in the ram. *New Zealand Veterinary Journal* 18: 189-198.
- , R. B. MARSHALL, AND D. P. J. WARD. 1969. Testicular hypoplasia and XXY sex chromosome complement in two rams: the ovine counterpart of Klinefelter's syndrome in man. *Journal of Reproduction and Fertility* 19: 103-108.
- BONGSO, T. A., M. R. JAINUDEEN, AND J. Y. S. LEE. 1981. Testicular hypoplasia in a bull with XX/XY chimerism. *Cornell Veterinarian* 71: 376-382.
- DEMARTINI, J. C., AND G. E. CONNOLLY. 1975. Testicular atrophy in columbian black-tailed deer in California. *Journal of Wildlife Disease* 11: 101-106.
- DUNN, H. O., D. H. LEIN, AND K. MCENTEE. 1980. Testicular hypoplasia in a Hereford bull with 61,XXY karyotype: the bovine Klinefelter's syndrome. *Cornell Veterinarian* 70: 137-146.
- FERGUSON-SMITH, M. A., AND M. B. GLASG. 1958. Chromatin-positive Klinefelter's syndrome (primary microorchidism) in a mental-deficient hospital. *Lancet* i: 928-931.
- KRISHNALINGAM, V., P. W. LADDS, K. W. ENTWISTLE, AND R. G. HOLROYD. 1982. Quantitative macroscopic and histological study of testicular hypoplasia in *Bos indicus* strain bulls. *Research in Veterinary Science* 32: 131-139.
- LOGUE, D. N., M. J. A. HARVEY, C. D. MUNRO, AND B. LENNOX. 1979. Hormonal and histological studies in a 61XXY bull. *Veterinary Record* 104: 500-503.
- MURPHY, B. D., AND R. E. CLUGSTON. 1971. Bilateral testicular degeneration in a wild mule deer (*Odocoileus hemionus*). *Journal of Wildlife Disease* 7: 67-69.
- ROBINSON, R. M., J. W. THOMAS, AND R. G. MARBURGER. 1967. Abnormal antler shedding associated with hypogonadism in central Texas deer. *The Southwestern Veterinarian* 20: 93-98.
- SETTERGREN, I., AND K. MCENTEE. 1992. Germ cell weakness as a cause of testicular hypoplasia in bulls. *Acta Veterinaria Scandinavica* 33: 273-282.
- TAYLOR, D. O. N., J. W. THOMAS, AND R. G. MARBURGER. 1964. Abnormal antler growth associated with hypogonadism in white-tailed deer in Texas. *American Journal of Veterinary Research* 25: 179-185.
- WATT, D. A. 1978. Testicular pathology of merino rams. *Australian Veterinary Journal* 54: 473-478.

Received for publication 10 August 1996.