



## EXPERIMENTAL NARTHECIUM OSSIFRAGUM NEPHROTOXICITY IN CERVIDS FROM NORWAY

Authors: Flåøyen, Arne, Handeland, Kjell, Stuve, Gudbrand, Ryeng, Kathrine A., and Refsum, Thorbjørn

Source: Journal of Wildlife Diseases, 35(1) : 24-30

Published By: Wildlife Disease Association

URL: <https://doi.org/10.7589/0090-3558-35.1.24>

---

BioOne Complete ([complete.BioOne.org](https://complete.BioOne.org)) is a full-text database of 200 subscribed and open-access titles in the biological, ecological, and environmental sciences published by nonprofit societies, associations, museums, institutions, and presses.

Your use of this PDF, the BioOne Complete website, and all posted and associated content indicates your acceptance of BioOne's Terms of Use, available at [www.bioone.org/terms-of-use](https://www.bioone.org/terms-of-use).

Usage of BioOne Complete content is strictly limited to personal, educational, and non - commercial use. Commercial inquiries or rights and permissions requests should be directed to the individual publisher as copyright holder.

---

BioOne sees sustainable scholarly publishing as an inherently collaborative enterprise connecting authors, nonprofit publishers, academic institutions, research libraries, and research funders in the common goal of maximizing access to critical research.

## EXPERIMENTAL *NARTHECIUM OSSIFRAGUM* NEPHROTOXICITY IN CERVIDS FROM NORWAY

Arne Flåøyen,<sup>1,3,5</sup> Kjell Handeland,<sup>2</sup> Gudbrand Stuve,<sup>2</sup> Kathrine A. Ryeng,<sup>4</sup> and Thorbjørn Refsum<sup>2</sup>

<sup>1</sup> Section of Toxicology, National Veterinary Institute, POB 8156 Dep., N-0033 Oslo, Norway

<sup>2</sup> Section of Wildlife Diseases, National Veterinary Institute, POB 8156 Dep., N-0033 Oslo, Norway

<sup>3</sup> Department of Reproduction and Forensic Medicine, Norwegian School of Veterinary Science, POB 8146 Dep., N-0033 Oslo, Norway

<sup>4</sup> Department of Arctic Veterinary Medicine, Norwegian School of Veterinary Science, N-9005 Tromsø, Norway

<sup>5</sup> Corresponding author (e-mail: arne.flaoeyen@vetinst.no)

**ABSTRACT:** One moose (*Alces alces*), two red deer (*Cervus elaphus*), two reindeer (*Rangifer tarandus*) and two fallow deer (*Dama dama*) were dosed intraruminally with an aqueous extract made from 30 g of bog asphodel (*Narthecium ossifragum*) (wet weight) per kg live weight. The moose and one of the two reindeer were mildly depressed and had reduced appetite 3 to 7 days and 1 to 4 days after dosing, respectively. The serum creatinine and urea concentrations increased markedly in the moose and red deer, and moderately in the reindeer. No increase in serum creatinine and urea was observed in the fallow deer. Histopathological examination of the kidneys of the animals, killed 8 to 10 days after dosing, revealed tubular epithelial cell degeneration, necrosis, and regeneration in the moose, red deer and reindeer. The renal lesions were severe in the moose, moderate in the red deer and mild in the reindeer. No histopathological lesions were seen in the kidneys of the fallow deer.

**Key words:** Toxic nephrosis, plant toxins, moose, *Alces alces*, red deer, *Cervus elaphus*, reindeer, *Rangifer tarandus*, fallow deer, *Dama dama*, *Narthecium ossifragum*, bog asphodel.

### INTRODUCTION

During the summers 1995 and 1996, lethal toxic nephrosis was diagnosed in nine free-living moose (*Alces alces*) from Aust-Agder County in southern Norway (Vikøren et al., 1999). Most cases occurred during the second half of June, and it was proposed that the disease had most likely resulted from ingestion of nephrotoxic plants. The summer browsing diet of moose in Aust-Agder has been extensively studied (Danielsen and Olsen, 1994; Damli and Roer, 1995; Bjerga, 1996). Of the 33 different plants reported to be ingested, only *Quercus* spp. (oak), *Narthecium ossifragum* (bog asphodel) and *Rumex acetosella* (field sorrel) are known to be nephrotoxic to domestic ruminants (Malone et al., 1992; Maxie, 1993; Flåøyen et al., 1995a, b, c, 1997a, b). As there were no oxalate crystals in the renal tubules of the affected animals, a typical finding of nephrotoxicoses by *R. acetosella* (Maxie, 1993), this plant could be ruled out.

*Narthecium ossifragum* was the probable cause of a severe outbreak of toxic ne-

phrosis in cattle herds along the coast of southern and western Norway during summer 1992 (Flåøyen et al., 1995a). The disease occurred from June to September with a peak incidence in July and the first half of August. A similar outbreak occurred in a cattle herd in Northern Ireland in 1989 (Malone et al., 1992). Toxicity studies have shown that *N. ossifragum* is nephrotoxic to cattle, sheep and goats (Malone, 1992; Flåøyen et al., 1995b, c; 1997a, b).

*N. ossifragum* is a common plant in wet uncultivated areas of southern and western parts of Norway (Fægri, 1960; Høeg, 1974), and moose may graze extensively on the plant (Bjerga, 1996). The Norwegian red deer (*Cervus elaphus*) population, with its main occurrence in western Norway also has extensive access to *N. ossifragum*.

The main objective of this study was to test the nephrotoxicity of *N. ossifragum* in moose and red deer. Reindeer (*Rangifer tarandus*) and fallow deer (*Dama dama*) were included to study possible interspecies differences in susceptibility among

cervids, whereas goats were included as a biological assay.

#### MATERIALS AND METHODS

An aqueous extract was produced from 15.0 kg (wet matter) *N. ossifragum* flower stems harvested in the flowering period (second half of July and the first half of August). The plant material was stored at  $-20^{\circ}\text{C}$  from collection date until the extract was made. Liquid nitrogen was added to the flower stems and the brittle tissue was chopped finely in a Robot coupe R 301 Ultra (Robot Coupe, S.A., Montceau en Bourgogne, France). The chopped material was suspended in purified water (2 l per kg plant material) and shaken in 1.0 l and 2.5 l flasks on a universal flask-shaking machine (Edmund Bühler S; 25, Tübingen, Germany) for 2 hr at 200 rpm. The mixture was centrifuged in 250 ml cups for 15 min at 10,000 rpm on a Sorvall SS-4 centrifuge (DuPont Company, Wilmington, Delaware, USA). The supernatant was vacuum-filtered through number 1 Whatman filter. The product of a second similar extraction of the plant residue in 15 l of water was combined with that from the first extraction to constitute the aqueous extract. The extracts were stored at  $-20^{\circ}\text{C}$  until dosing. The total amount of extract was 31 l which gave 2.1 ml extract/g plant material.

Two 6-mo-old neutered male Norwegian dairy goats (numbers 6011 and 6021), were included in the study as a biological assay for testing the toxic potential of the extract. The goats were fed 0.1 kg concentrate (Formel sau, Felleskjøpet, Norway) per day and hay *ad libitum* from more than 30 days before dosing and throughout.

One 3-mo-old female moose, 88 kg live weight (lw) on the day of dosing, had been left by her mother a few days after birth and was bottle fed with cow milk substitute until 10 days before dosing. Additionally, the calf had access to grass and other herbage. From 10 days before dosing and throughout it was fed *ad libitum* a mixture of fresh foliage of blueberry (*Vaccinium myrtillus*), raspberry (*Rubus idaeus*), rowan (*Sorbus aucuparia aucuparia*) and sallow (*Salix caprea caprea*). The moose had never had access to *N. ossifragum*.

Two 5-mo-old male red deer, 42 kg (number 1) and 38 kg (number 2) lw on the day of dosing, and one 5-mo-old male fallow deer, 27 kg lw, were weaned from their mothers 28 days before dosing. A second male fallow deer calf (number 2) that was weaned at the same time as the first one was 6-mo-old and 23 kg lw when dosed 1 mo after the first animal. The animals were from a deer farm in western Nor-

way with pastures containing small amounts of *N. ossifragum* (<5%). The red deer and fallow deer were fed 0.20 to 0.25 kg barley per day, some freshly cut grass, and hay *ad libitum* from weaning and throughout the experiment.

Two 18-mo-old male reindeer, 55 kg (number 8) and 62 kg (number 9) lw on the day of dosing, were fed Parat reindeer feed RF 80 (Stormøllen AS, Vaksdal, Norway) *ad libitum* 1 mo before dosing and throughout the experiment. In addition, both animals received approximately 100 g lichen (*Cladina stellaris*) per day. The animals were from Finnmark County in northern Norway, and had had no prior access to *N. ossifragum*.

All animals were dosed intraruminally by stomach tube with aqueous extracts of 30 g (wet matter) plant material/kg live weight. The dose was divided in two equal portions which were given at a 4 hr interval.

Due to animal welfare reasons, negative controls were not included in the study, and the results from the predosing period were regarded to be normal values for each individual.

Blood samples (5 to 10 ml) were taken daily from all animals beginning 7 days before dosing until necropsy. Sera from the moose, red deer, fallow deer and reindeer were analysed for the concentrations of creatinine, urea, calcium, phosphorus and magnesium, and for activities of aspartate aminotransferase (AST) and gamma-glutamyltransferase ( $\gamma$ GT) on a Technicon Axon (Technicon, Dublin, Ireland) at  $37^{\circ}\text{C}$ . The glutamate dehydrogenase (GLDH) activity in serum was analysed on a Technicon RA-1000 (Technicon) at  $37^{\circ}\text{C}$ . Sera from the goats were only analysed for creatinine and urea, while serum from reindeer 9 was additionally analysed for the activity of creatine kinase (CK) on the Technicon Axon to establish whether the increased AST activity measured was caused by muscular lesions or liver damage. All analysis were performed according to standard methods at the Central Laboratory (Norwegian School of Veterinary Science, Oslo, Norway; with internordic control by Labquality, Helsinki, Finland).

The goats and moose were killed on day 8 after dosing, whereas the red deer, fallow deer and reindeer were killed on day 10. All animals were killed by captive bolt stunning and immediate exsanguination.

A full necropsy was performed on all animals. Tissue from lungs, heart, kidneys, liver, spleen, esophagus, small intestine, large intestine, skeletal muscles and bone marrow were fixed in 10% neutral buffered formalin, embedded in paraffin, sectioned at  $5\text{ }\mu\text{m}$ , and stained with haematoxylin and eosin (H&E) for histological examination (Culling et al., 1985). In ad-

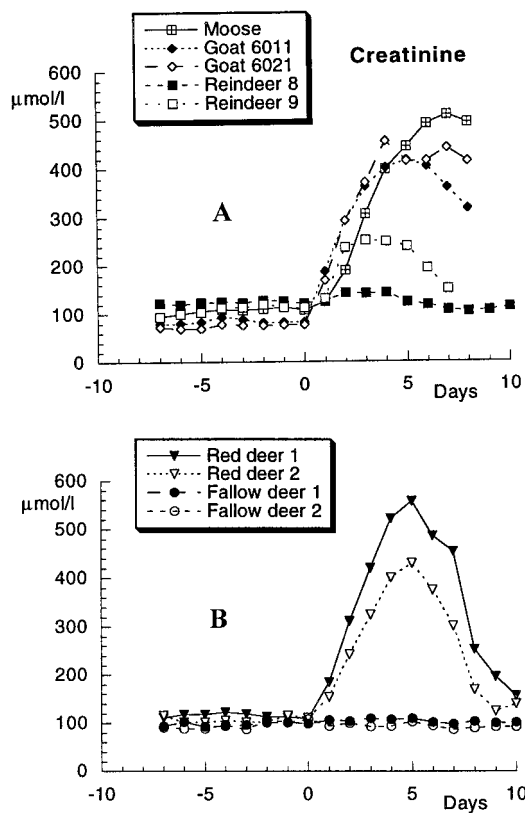


FIGURE 1. Creatinine concentrations in sera from one moose, two goats, two reindeer (A) and two red deer and two fallow deer (B) dosed with a water extract from 30 g *Nartheicum ossifragum* per kg live weight on day 0. The moose and the goats were killed on day 8 whereas the reindeer, red deer and fallow deer were killed on day 10. Due to hemolysis, there are no results from reindeer 9 on days 8–10.

dition, sections from the kidneys were stained with periodic acid-Schiff (Bancroft and Stevens, 1990) and van Gieson (Culling et al., 1985).

### RESULTS

No signs of disease were observed in any of the animals during the pre-dosing period. The moose was mildly depressed on days 6 and 7 after dosing and its appetite was reduced on days 3 to 7. Reindeer 9 was mildly depressed and its appetite was reduced on days 1 to 4 after dosing. We did not observe signs of disease or reduced appetite in the other animals.

Following the dosing, we found marked

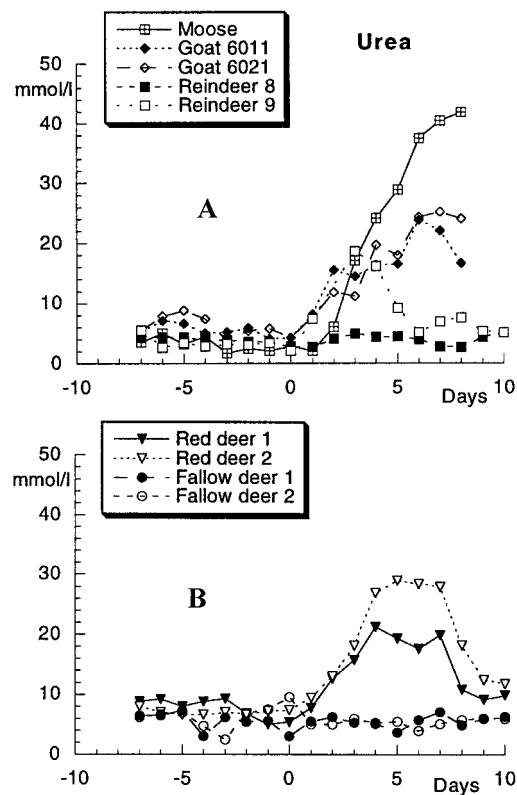


FIGURE 2. Urea concentrations in sera from one moose, two goats, two reindeer (A), and two red deer and two fallow deer (B) dosed with a water extract from 30 g *Nartheicum ossifragum* per kg live weight on day 0. The moose and the goats were killed on day 8 whereas the reindeer, red deer and fallow deer were killed on day 10.

increases in serum creatinine and urea concentrations in the goats, moose and red deer, a moderate increase in serum creatinine and urea concentrations in the reindeer and no changes in the same parameters in the fallow deer (Fig. 1A, B; Fig. 2A, B). Serum magnesium concentrations increased in the moose and the red deer (Fig. 3), and remained unchanged in the fallow deer and reindeer. We did not find any systematic changes in the serum calcium and serum phosphorus concentrations in any of the animals after dosing (Table 1). The activity of AST increased in the moose and in reindeer 9 (Fig. 4). In reindeer 9 increases in  $\gamma$ GT and GLDH activities also were found (Fig. 4). We did

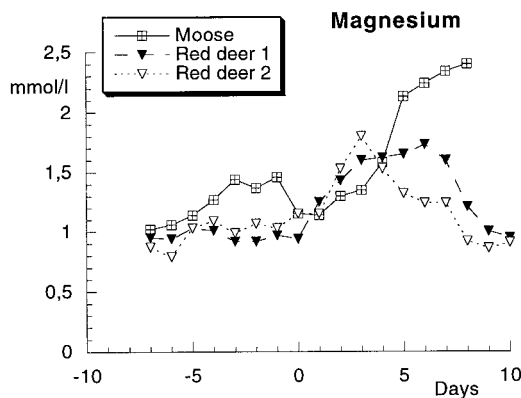


FIGURE 3. Magnesium concentrations in sera from one moose and two red deer dosed with water extract from 30 g *Narthecium ossifragum* per kg live weight on day 0. The moose was killed on day 8 whereas the red deer were killed on day 10.

not find any changes in AST,  $\gamma$ GT and GLDH activities in the other animals (Table 1), and there were no changes in CK activity in reindeer 9 (range 192 to 988 IU/l). Due to hemolysis, we have no results on serum creatinine, phosphorus, magnesium, and the activity of  $\gamma$ GT on days 8 to 10 from reindeer 9.

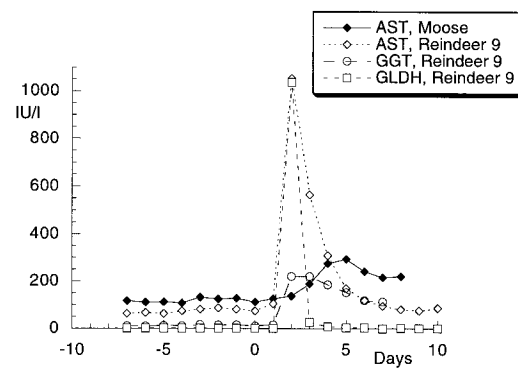


FIGURE 4. Activities of aspartate aminotransferase (AST) in one moose and one reindeer (number 9), and activities of gamma-glutamyltransferase (GGT) and glutamate dehydrogenase (GLDH) in one reindeer (number 9) dosed with water extract from 30 g *Narthecium ossifragum* per kg live weight on day 0. The moose was killed on day 8 whereas the reindeer was killed on day 10. Due to hemolysis, there were no AST results from reindeer 9 on days 9 and 10 and no GGT results on days 8–10.

At necropsy the kidneys of the moose and goats were pale and slightly swollen. The moose also had edema of the renal hilus and papilla. No gross lesions were

TABLE 1. Maximum and minimum concentrations of calcium and phosphorus, and maximum and minimum activities of AST<sup>a</sup>,  $\gamma$ GT<sup>a</sup> and GLDH<sup>a</sup> in sera in the pre- and post-dosing period from one moose, two red deer, two fallow deer and two reindeer dosed with an aqueous extract from 30 g *Narthecium ossifragum*/kg live weight.

Species	Calcium mmol/l		Phosphorus mmol/l		AST <sup>a</sup> IU/l		γGT <sup>a</sup> IU/l		GLDH <sup>a</sup> IU/l	
	min	max	min	max	min	max	min	max	min	max
Moose										
before dosing	2.9	3.1	2.0	3.4	see Fig. 4		22	27	0	3
after dosing	2.8	3.3	2.0	3.6			21	37	0	4
Red deer										
before dosing	2.3	2.7	2.4	3.3	52	102	20	114	0	4
after dosing	2.1	2.7	1.9	3.5	46	76	22	70	0	8
Fallow deer										
before dosing	2.1	2.6	1.5	3.6	84	192	31	54	2	29
after dosing	2.1	2.6	1.8	3.5	102	248	22	57	5	48
Reindeer										
before dosing	2.3	2.7	2.3	3.9	63	103	10	33	2	3
after dosing	2.3	2.8	2.2	3.6	78 <sup>b</sup>	114 <sup>b</sup>	27 <sup>b</sup>	30 <sup>b</sup>	0 <sup>b</sup>	3 <sup>b</sup>

<sup>a</sup> See text for full name of compounds tested.

<sup>b</sup> Consist only of results from reindeer number 8. Results from reindeer number 9 are presented in Figure 5 (AST and  $\gamma$ GT) and Figure 6 (GLDH).



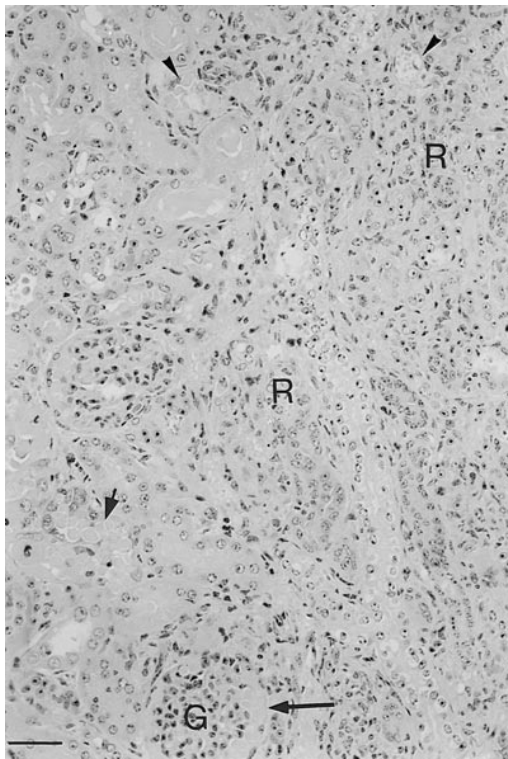


FIGURE 5. Kidney (glomerulus = G) from a moose calf killed eight days after dosing with water extract from 30 g *Narthecium ossifragum* per kg live weight showing extensive necrosis (arrowheads) and regeneration (R) of tubular epithelial cells, dilated tubuli (small arrow) and Bowman's spaces (large arrow) filled by a granular eosinophilic material. H & E. Bar = 50  $\mu$ m.

observed in the kidneys or other organs of the red deer, fallow deer, or reindeer.

Similarly, histological changes varied between animals. The kidneys of the moose, goats, red deer and reindeer had patchy to confluent areas of tubular epithelial degeneration, necrosis and regeneration (Fig. 5). The tubular lumina frequently contained casts consisting of an eosinophilic proteinaceous material. Interstitially, an incipient proliferation of fibroblasts and scattered accumulations of leukocytes could be seen. The renal lesions were severe in the moose and one of the goats (6021), comprising about half of the cortical tissue mass. In the other goat (6011) as well as in the red deer, kidney damage was considerable, but less extensive com-

pared to the former animals, and only slight lesions could be seen in the reindeer. No lesions were seen in the kidneys of the fallow deer. Extrarenal lesions were not found in any of the animals.

## DISCUSSION

The results of the serum analysis and the pathological findings showed that this dose of *N. ossifragum* was toxic to the moose, the red deer and the reindeer. The susceptibility of the moose and red deer seemed similar to that of goats which were included as a biological assay with known susceptibility to the toxin (Flåøyen et al., 1997b). The reindeer were less susceptible, and the two fallow deer were resistant to the dose given. We suggest these differences reflect species differences of cervids in susceptibility to the toxin. However, the number of experimental animals was low, and they were of different age and sex and had been kept on different diets prior to dosing. Therefore, it cannot be excluded, that results were influenced by individual differences. Age, sex, nutritional status and previous exposure to various chemicals as well as species are all factors which are well known to influence biotransformation and susceptibility to toxicants (Cheeke, 1998). The small amounts of *N. ossifragum* found in the pastures of the red deer and fallow deer in our study may have altered the susceptibility to experimental exposure.

We assume our findings reflect species differences in susceptibility to the nephrotoxic component of *N. ossifragum* due to differences in the detoxification systems in the liver and/or kidneys. However, we cannot exclude that species differences in absorption and distribution may also exist. Inactivation due to species characteristic rumen metabolism could also be involved (Cheeke, 1998).

The increase in serum creatinine and urea concentrations that occurred in the animals shortly after dosing is typical of the disease as is the increase in serum magnesium that occurred simultaneously

in the most susceptible animals (Flåøyen et al., 1995b, c; 1997a, b). Serum creatinine started decreasing before killing in all animals, indicating tubular regeneration, which was also confirmed histopathologically. However, the histopathological examination also revealed some early fibrosis indicating basement membrane damage and thus irreversible damage to the tubules. Our histopathological findings were consistent with those found in experimentally dosed calves, lambs and goats (Flåøyen et al., 1995b, c; 1997b).

The results from the serum phosphorus and calcium analysis as well as activities of AST, GLDH and  $\gamma$ GT also support the results from previous studies in calves, lambs and goats (Flåøyen et al., 1995b, c; 1997b). However, we have difficulty explaining the increased activities of AST in the moose and in reindeer 9, as well as the increased activities of GLDH and  $\gamma$ GT in reindeer 9. A similar response has previously been observed in a non-ruminating calf dosed with an aqueous extract of *N. ossifragum* (Flåøyen et al., 1997a). The AST activity is known to increase in ruminants suffering from liver or muscle damage, whereas the activity of CK increases in animals suffering from muscle damage only (Cornelius, 1989). The results from reindeer 9 indicate that there was no muscular damage in the animal, and we suggest that the increased AST activities both in the moose and in reindeer 9 were due to liver damage. This conclusion is supported by the increases in GLDH and  $\gamma$ GT activities in reindeer 9 as both enzymes are known to increase in ruminants with liver damage (Cornelius, 1989). *Nartheicum ossifragum* has long been known to cause liver damage and secondary photosensitization in sheep (Flåøyen, 1993). However, the results from previous work showed that the hepatotoxic component is not found in aqueous extracts of the plant (Flåøyen et al., 1997a). Therefore, we suggest that the increased AST activities observed both in the moose and in reindeer 9, as well as the increased  $\gamma$ GT and GLDH activities in

reindeer 9, may be due to liver damage unlike that which results in hepatogenous photosensitization in lambs (Flåøyen, 1993).

Our study confirmed the hypothesis that *N. ossifragum* is a potential cause of naturally occurring toxic nephrosis in moose in Aust-Agder, southern Norway (Vikøren et al., 1999). *Nartheicum ossifragum* is a common plant in the area (Fægri, 1960; Høeg, 1974), and Bjerga (1996) found that moose may ingest large amounts of the plant. The ingestion of *N. ossifragum* started in June, the month where most cases of nephrotoxicosis were diagnosed (Vikøren et al., 1999).

According to Bjerga (1996), *N. ossifragum* is an essential feed for individual moose in Aust-Agder throughout the summer. It is not likely that the moose would have continued grazing on the plant, and remained healthy, if its toxicity was constant. Flåøyen et al. (1995c) found that lambs fed 15 g *N. ossifragum*/kg live weight for 10 consecutive days were susceptible to the nephrotoxin only on the first day of feeding. A similar induction of tolerance for the toxin most likely occurs in moose. This acquired tolerance is most probably caused by induced activities of microsomal or cytosolic enzymes of the liver and/or kidneys (Cheeke, 1998). Naturally occurring disease in moose may result from the ingestion of a substantial initial dose of *N. ossifragum*.

Early summer oak leaf browsing is considered to be the second possible cause of the toxic nephrosis in moose in Aust-Agder (Vikøren et al., 1999). Experimental studies should be carried out to clarify whether early summer oak leaves are nephrotoxic, and thus be involved in the aetiology of this disease.

#### ACKNOWLEDGMENTS

We thank J. T. Solheim for helping us conduct the experiment in red deer and fallow deer, and the Directorate for Nature Management for the financial support.

## LITERATURE CITED

- BANCROFT, J. D., AND A. STEVENS. 1990. Theory and practice of histological techniques, 3rd Edition. Churchill Livingstone, Edinburgh, UK, 726 pp.
- BJERGA, M. 1996. Feeding ecology of moose (*Alces alces*) along an altitudinal gradient in Aust-Agder. M.Sc. Thesis, University of Oslo, Oslo, Norway, 40 pp. [In Norwegian]
- CHEEKE, P. R. 1998. Natural toxicants in feeds, forages, and poisonous plants, 2nd Edition. Interstate Publishers, Danville, Illinois, 479 pp.
- CORNELIUS, C. E. 1989. Liver function. In *Clinical biochemistry of domestic animals*, J. J. Kaneko (ed.). Academic Press, San Diego, California, pp. 364–397.
- CULLING, C. F. A., R. T. ALLISON, AND W. T. BARR. 1985. Cellular pathology technique, 4th Edition. Butterworth & Co., London, UK, 642 pp.
- DAMLI, K. G. S., AND O. A. ROER. 1995. Summer browsing and choice of habitat of moose in Aust-Agder. M.Sc. Thesis, Agricultural University of Norway, Ås, Norway, 55 pp. [In Norwegian]
- DANIELSEN, I., AND M. OLSEN. 1994. The summer forage of moose in Aust-Agder. M.Sc. Thesis, Agricultural University of Norway, Ås, Norway, 51 pp. [In Norwegian]
- FLÅØYEN, A. 1993. Studies on the aetiology and pathology of alvelid with some comparisons to sporidesmin intoxication. Ph.D. Thesis, Norwegian College of Veterinary Medicine, Oslo, Norway, 109 pp.
- FLÅØYEN, A., M. BINDE, B. BRATBERG, B. DJØNNE, M. FJØLSTAD, H. GRØNSTØL, H. HASSAN, P. G. MANTLE, T. LANDSVERK, J. SCHÖNHEIT, AND M. H. TØNNESEN. 1995a. Nephrotoxicity of *Nartheicum ossifragum* in cattle in Norway. *Veterinary Record* 137: 259–263.
- , B. BRATBERG, A. FRØSLIE, AND H. GRØNSTØL. 1995b. Nephrotoxicity and hepatotoxicity in calves apparently caused by experimental feeding with *Nartheicum ossifragum*. *Veterinary Research Communications* 19: 63–73.
- , ———, AND H. GRØNSTØL. 1995c. Nephrotoxicity in lambs apparently caused by experimental feeding with *Nartheicum ossifragum*. *Veterinary Research Communications* 19: 75–79.
- , ———, A. FRØSLIE, H. GRØNSTØL, W. LANGSETH, P. G. MANTLE, AND A. VON KROGH. 1997a. Further studies on the presence, qualities and effects of the toxic principles from *Nartheicum ossifragum* plants. *Veterinary Research Communications* 21: 137–148.
- , ———, ———, ———, ———, ———, AND ———. 1997b. Nephrotoxicity in goats by dosing with water extract from *Nartheicum ossifragum* plants. *Veterinary Research Communications* 21: 499–506.
- FÆRI, K. 1960. *Nartheicum ossifragum*. In *Maps of distribution of Norwegian plants*, K. Fægri, O. Gjærevoll, and J. Lid (eds.). Oslo University Press, Oslo, Norway, pp. 95.
- HØEG, O. A. 1974. *Nartheicum ossifragum* (L.) Huds., rome. In *Planter og tradisjon. Floraen i levende tale og tradisjon i Norge 1925–1973* [In Norwegian] O. A. Høeg (ed.). Universitetsforlaget, Oslo, Norway, pp. 464–466.
- MALONE, F. E., S. KENNEDY, G. A. C. REILLY, AND F. M. WOODS. 1992. Bog asphodel (*Nartheicum ossifragum*) poisoning in cattle. *Veterinary Record* 131: 100–103.
- MAXIE, M. G. 1993. Nephrotoxic tubular necrosis. In *Pathology of domestic animals*, Vol. 2, 4th Ed. K. V. F. Jubb, P. C. Kennedy, and N. Palmer (eds.). Academic Press, San Diego, California, pp. 489–495.
- VIKØREN, T., K. HANDELAND, G. STUVE, AND B. BRATBERG. 1999. Toxic nephrosis in moose in Norway. *Journal of Wildlife Diseases* 35: In Press.

Received for publication 26 March 1998.