

EXERTIONAL MYOPATHY IN TRANSLOCATED RIVER OTTERS FROM NEW YORK

Authors: Hartup, Barry K., Kollias, George V., Jacobsen, Matthew C., Valentine, Beth A., and Kimber, Kevin R.

Source: Journal of Wildlife Diseases, 35(3) : 542-547

Published By: Wildlife Disease Association

URL: <https://doi.org/10.7589/0090-3558-35.3.542>

BioOne Complete (complete.BioOne.org) is a full-text database of 200 subscribed and open-access titles in the biological, ecological, and environmental sciences published by nonprofit societies, associations, museums, institutions, and presses.

Your use of this PDF, the BioOne Complete website, and all posted and associated content indicates your acceptance of BioOne's Terms of Use, available at www.bioone.org/terms-of-use.

Usage of BioOne Complete content is strictly limited to personal, educational, and non - commercial use. Commercial inquiries or rights and permissions requests should be directed to the individual publisher as copyright holder.

BioOne sees sustainable scholarly publishing as an inherently collaborative enterprise connecting authors, nonprofit publishers, academic institutions, research libraries, and research funders in the common goal of maximizing access to critical research.

EXERTIONAL MYOPATHY IN TRANSLOCATED RIVER OTTERS FROM NEW YORK

Barry K. Hartup,^{1,4} George V. Kollias,¹ Matthew C. Jacobsen,² Beth A. Valentine,^{2,3} and Kevin R. Kimber¹

¹ Wildlife Health Laboratory, Department of Clinical Sciences, College of Veterinary Medicine, Cornell University, Ithaca, New York 14853, USA

² Department of Pathology, College of Veterinary Medicine, Cornell University, Ithaca, New York 14853, USA

³ Present address: Department of Pathology, College of Veterinary Medicine, Oregon State University, Corvallis, Oregon 97331, USA

⁴ Corresponding author (e-mail: bkh4@cornell.edu)

ABSTRACT: Lesions consistent with exertional myopathy (EM) were documented postmortem in four North American river otters (*Lutra canadensis*) during translocation for a population restoration project. Clinical signs in these otters included depression, anorexia and shock. Gross lesions in one otter included locally extensive linear, pale areas within the subscapularis, rectus abdominis, quadriceps, and dorsal laryngeal muscles. Microscopic lesions were characterized by acute to subacute myofiber necrosis of varying severity, and occurred in a variety of skeletal muscles as well as cardiac muscle in one otter. Based on these observations, we conducted a retrospective review of records of otters which experienced similar capture, transfer, and holding protocols between 1995 and 1997, but with a successful outcome ($n = 69$). Significant elevations in serum aspartate aminotransferase (AST) and creatine kinase (CK) were observed in 19 (28%) of the otters, but may have been higher due to delayed sample collection from some otters. However, none of the otters with elevated enzymes exhibited clinical signs suggestive of EM. These findings indicate that river otters may develop EM when translocated, but many cases may be mild or clinically inapparent.

Key words: Clinical pathology, exertional myopathy, *Lutra canadensis*, pathology, river otter, skeletal muscle, translocation.

INTRODUCTION

Exertional myopathy (EM), or capture myopathy, is a non-infectious, metabolic disease of wild and domestic animals (Bartsch et al., 1977; Harris, 1993). In mammals, the disease has been documented primarily in cervids (Wallace et al., 1987). Other mammalian taxa, such as marsupials, cetaceans, pinnipeds, rodents and primates are also represented in the EM literature (reviewed by Williams and Thorne, 1996). Exertional myopathy has been diagnosed in working and racing domestic dogs (Gannon, 1980; Howerth and McCrindle, 1982), yet reports of EM in wild carnivores remain anecdotal.

In wild animals, EM is most often associated with capture or restraint procedures involving significant muscle exertion and stress. The pathogenesis of EM in wildlife has been described by Chalmers and Barrett (1982) and Spraker (1993) as a complex process involving metabolic and lactic acidosis, hyperkalemia and sympa-

thetic response or shock. Clinical signs are varied, and may include depression, ataxia, muscle weakness and pain. Skeletal muscle necrosis and acute renal failure are common sequelae of EM. Clinical laboratory findings, in addition to those noted above, may include myoglobinuria, azotemia, and elevations in serum creatine kinase (CK), aspartate aminotransferase (AST), and lactate dehydrogenase (LDH). In severe cases, death may occur acutely within hours, or more commonly between two and four days after the onset of clinical signs. Chronically affected animals may experience a delayed-peracute syndrome causing death weeks later.

Techniques that involve long periods of restraint, promote struggling from unnatural positioning, or include lengthy pursuit during capture are major factors in the development of EM in wildlife (Williams and Thorne, 1996). To our knowledge, no studies have estimated the prevalence of EM in carnivores undergoing translocation, de-

spite the current popularity of translocation of native predators from extant populations. The purpose of the present study was to describe myopathic lesions observed in four North American river otters (*Lutra canadensis*) undergoing translocation, and to determine the prevalence of muscle enzyme elevations suggestive of EM in a cohort of successfully translocated river otters.

MATERIALS AND METHODS

River otters were captured during the fall of 1995, 1996 and 1997 from the Adirondack (43°00' to 45°00'N, 73°50' to 76°00'W) and Catskill regions (41°00' to 42°00'N, 73°50' to 75°00'W) of New York State, and translocated as part of a population restoration project in the western portion of the state. All otter captures were made by specially licensed private trappers that attended annual training seminars given by the New York State Department of Environmental Conservation (NYSDEC; Albany, New York, USA). All otters in this study were captured using foothold traps. Foothold trap sizes #1 to #2, and #11 were allowed with various modifications such as padding, offset jaw widths of 3/32 to 1/8 in., and replacement of stock springs with #2 coil springs. Foothold trap sets had a minimum of three swivel points between the stake and trap; four were mandatory by the 1997 season. All traps were checked minimally every 24 hr. Otter restraint for removal from foothold traps was accomplished either through the use of a catch-pole or net, or with a wooden shield to guide the otter into a transport box.

Once delivered to NYSDEC biologists, otters were placed in wood and vinyl coated mesh transport cages (48 cm × 71 cm × 1 m) and driven by covered pickup truck to Cornell University (CU; Ithaca, New York, USA). The mean time between removal from the trap and arrival at CU was 1.7 days. Under normal circumstances, otters were given a detailed health assessment within days of arrival at the holding facility, and maintained under a standard protocol for 2 to 3 wk prior to release (Kollias, 1998). Otters that died at CU were necropsied the same day. Tissue sections of all major organ systems and visible lesions were fixed in 10% neutral buffered formalin, embedded in paraffin, sectioned at 5 to 6 µm, and stained with hematoxylin and eosin. The severity of microscopic lesions in skeletal muscle were graded as mild, moderate, or severe by agreement of two pathologists.

Muscle enzyme levels (AST and CK) were determined retrospectively in serum samples of 69 otters to estimate the prevalence of EM in otters undergoing translocation by these methods. These enzymes were chosen because they provide a valuable adjunct to the diagnosis of neuromuscular diseases and the concentrations of the enzymes are usually low in serum in the presence of healthy myofibers (Cardinet, 1997). Data from otters captured by other methods (box traps, $n = 4$) or that had incomplete enzyme values ($n = 8$) were excluded. Data from otters with severe injuries or pathologic conditions identified at necropsy ($n = 10$) that may have resulted in cellular leakage or decreased clearance of AST or CK also were excluded to limit potential bias in our estimate of EM prevalence in the translocated population. No enzyme data was available for comparative purposes from the four otters diagnosed with EM lesions described herein due to lack of samples.

The AST and CK levels in the serum samples were measured using a Hitachi 911 analyzer and reagents supplied by the manufacturer (Boehringer Mannheim Corp., Indianapolis, Indiana, USA). Otters were classified as having normal or elevated enzyme levels; the latter consisted of both AST > 200 IU/L and CK > 1000 IU/L. These cut points were developed after consideration of values reported for recently captured and/or transported river otters (Serfass et al., 1993) and longer-term captive otters (Hoover et al., 1985; Davis et al., 1992). Lastly, because we suspected muscle enzyme levels may have declined while otters awaited serum sampling, we used Mantel-Haenszel chi-square to test for an association between enzyme status and the number of days between capture and serum collection (≤ 5 or > 5 days) (Epi Info 6.04; 1997 Version; Centers for Disease Control and Prevention, Atlanta, Georgia, USA). Statistical significance was established at $P < 0.05$.

RESULTS

Four otters died during the project period and exhibited gross or histological lesions consistent with EM (three in 1995, one in 1996). An adult male otter (case 1) weighing 4.9 kg was presented 2 days after capture. The otter continually exhibited escape behavior from the wooden transport box prior to delivery, and was offered only water prior to delivery. On presentation, the otter was depressed, hypothermic (24 C), dehydrated (10–12%) and exhibited a weak pulse. Shock therapy consisted

TABLE 1. Distribution and severity of microscopic lesions in muscle from four river otters with exertional myopathy in New York.

Case	Trapped limb	Muscles affected	Severity
1	Unknown	Subscapularis, longissimus dorsi, quadriceps	Mild
2	Unknown	Subscapularis, rectus abdominus, quadriceps, dorsal laryngeal, cardiac	Severe
3	Left rear	Left thigh ^a , masseter	Mild
4	Left front	Medial right thigh ^a , longissimus dorsi, left infraspinatus	Severe

^a Muscle not specified.

of intraosseous administration of warmed fluids, dextrose, and dexamethasone, and supplemental heat. Warmed subcutaneous fluids, antibiotics, and nutritional supplements were given 1 hr later. The otter did not survive overnight, dying approximately 3 days after capture.

A juvenile female otter (case 2) weighing 3.7 kg was presented within 24 hr after capture. The otter had eaten and drank during transport and appeared alert and responsive upon delivery. There were no visible injuries. The otter ate, drank, and eliminated normal feces for 3 days, and then was found dead, approximately 4 days after capture.

A 4.4 kg adult female otter (case 3) was presented 2 days after capture. The otter was offered minnows and salmon prior to delivery, but may not have eaten. At presentation, the otter was depressed and mild epistaxis was noted. The following day, the otter remained depressed and was treated with fluids, antibiotics, and nutritional supplements. The otter remained depressed and anorexic over the next day despite additional treatments. The otter died 4 days after capture.

A 7.6 kg adult male otter (case 4) was presented 2 days after capture. The otter was alert, but had loose, light brown, mucoid feces. The otter ate well overnight and was started on oral antibiotics. The following morning, the otter had foamy, copious diarrhea. Anaerobic culture of the fresh feces yielded many *Clostridium perfringens*, but no detectable *Clostridium* exotoxin. An evaluation of feces for para-

sites was negative. The otter died later that day, 3 days post-capture.

No gross pathological changes were observed in skeletal muscle in cases 1, 3 and 4 at necropsy. Locally extensive linear pale zones were present bilaterally within the subscapularis, rectus abdominus, quadriceps and dorsal laryngeal muscle groups of case 2. Adequate body fat stores were noted in cases 2 to 4, whereas case 1 had minimal body fat and severe tooth wear of longstanding duration suggesting advanced age. Muroid intestinal contents were present in all cases; gastrointestinal hemorrhage was observed in case 1. *Clostridium perfringens* was isolated from anaerobic cultures of the large intestine and spleen of case 1. Pneumonia with abscessation and pyothorax was observed in case 2. Aerobic culture of lung and thoracic fluid from case 2 yielded *Streptococcus spp.*, *E. coli*, and *Salmonella arizona*. Traumatic lesions (mild subcutaneous edema and hemorrhage) at the trapping site were noted in case 3 only.

Acute to subacute myofiber necrosis was present in skeletal muscle sections examined microscopically from all four otters (Table 1). Severity ranged from mild, with necrotic fibers scattered throughout the muscle section (cases 1 and 3), to severe, with large contiguous areas of fiber necrosis (cases 2 and 4; Fig. 1). In each case, severity of myofiber necrosis varied within muscles, with apparent sparing of some fibers. Necrotic fibers were characterized by cytoplasmic fragmentation, often with associated interstitial and intracytoplasmic

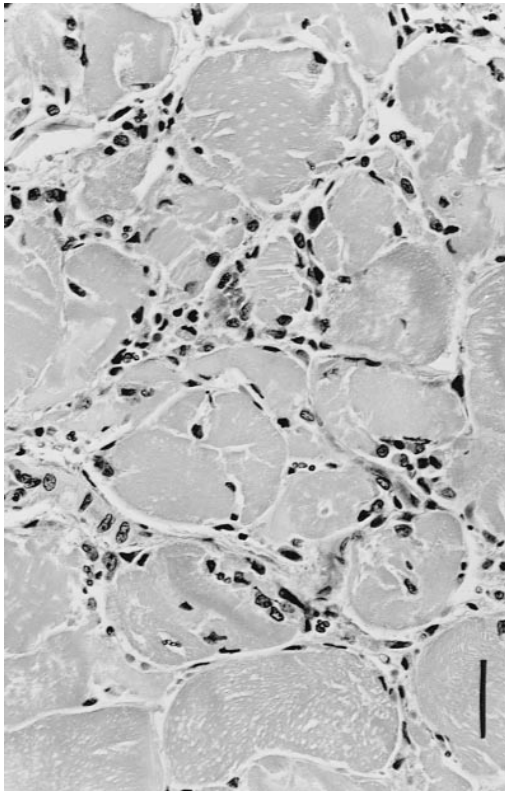


FIGURE 1. Severe subacute muscle fiber necrosis in a river otter (*Lutra canadensis*) with numerous inter- and intrafiber macrophages. H&E. Bar = 25 μ m.

macrophages. Mild multifocal mineralization of affected fibers was evident in cases 2 and 3. Scattered necrotic myofibers were found within the ventricular myocardium of case 2. The dorsal cervical muscles were not affected in case 4.

Small numbers of intraalveolar nematode parasites (*Crenosoma spp.*) with minimal surrounding inflammation were found microscopically in cases 1 and 3. Pleuritis and necrotizing pneumonia with associated bacteria was present in case 2. Several small foci of subendocardial fibrovascular proliferation were found in case 3. Prominent intestinal goblet cells and intraluminal mucus were present in the small intestine of all cases. No significant lesions were present in sections of other organs examined.

The median AST level of the successfully translocated otters was 137 IU/L

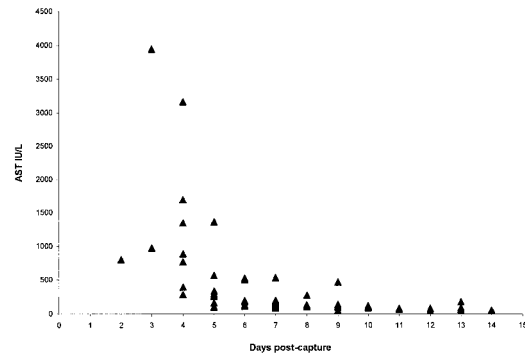


FIGURE 2. Serum aspartate aminotransferase (AST) levels measured in 69 river otters during translocation.

(range 43–3944 IU/L), and the median CK level was 726 IU/L (range 105–12,946 IU/L). Twenty-eight percent (19/69) of otters were classified as having both elevated AST and CK levels. Most elevations of AST and CK were documented within five days of capture (Figs. 2, 3). A significant association was observed between enzyme status and the time between capture and serum collection ($P < 0.01$). Seventy-one percent (15/21) of otters sampled five or fewer days after capture had elevated AST and CK levels, compared to 8% (4/48) of otters sampled 6 or more days after capture. None of these otters exhibited clinical signs consistent with EM described in cases 1 to 4 above. Typically, the otters remained quiet and adapted slowly to captivity, with activity and food consumption

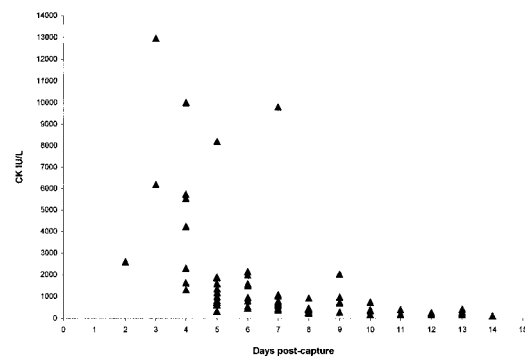


FIGURE 3. Serum creatine kinase (CK) levels measured in 69 river otters during translocation.

increasing stepwise over the first 2 days after arrival at the holding facility.

DISCUSSION

In each of the four necropsied otters, EM appeared to be one of a constellation of pathological processes that presumably contributed to the otters' clinical deterioration, but could not be identified as the sole cause of death. Among eight other otters necropsied during the project period, clostridial enterotoxemia and pulmonary nematodiasis were the most common pathological findings observed. None of these cases exhibited gross or microscopic evidence of EM.

Myopathic lesions were not localized to the trapped limb in the four otters. The distribution of affected muscles was quite generalized, involving muscles of the head, axial and appendicular skeleton likely subject to damage by prolonged escape behavior during trapping or confinement. We believe this demonstrates the potential for a significant systemic metabolic insult that may contribute to mortality in translocated river otters. Renal tubular necrosis, as a sequelae to the release of myoglobin from damaged skeletal muscle, was not observed in any of the otters examined post-mortem, despite the presence of likely predisposing factors, such as dehydration and metabolic acidosis, prior to death (Harris, 1993).

The enzyme levels measured in the successfully translocated otters were consistent with those reported for recently captured and transported river otters (Hoover et al., 1985; Serfass et al., 1993). The kinetics of AST and CK catabolism and elimination are unknown for river otters, but are assumed to be similar to domestic carnivores (Duncan et al., 1994). Creatine kinase levels typically rise within hours following acute muscle damage and remain elevated for only a few days, whereas AST levels rise within days but may persist for weeks. Cardinet (1997) suggests this pattern may be due to differential disappearance rates for AST and CK, as observed in

horses with paralytic myoglobinuria. This difference cannot be confirmed by our study because otters were not sampled at the time of capture or sequentially prior to release.

The magnitude and variation of AST and CK elevations in translocated otters appear similar with those of other species subjected to capture or restraint procedures (Bollinger et al., 1989; Kock et al., 1987; Williams et al., 1992). However, these data are not directly comparable because of the different capture methods employed, sampling times of subjects relative to capture, and potential species differences. Creatine kinase is accepted as one of the most specific and sensitive indices of muscle damage or necrosis in all species (Harris, 1993). Aspartate aminotransferase lacks organ specificity, however, with high concentrations in the skeletal and cardiac muscle, liver and erythrocytes, and may be most useful as a prognostic aid in conjunction with CK (Cardinet, 1997). Elevations of these enzymes are roughly proportional to the mass of tissue affected, although there is debate on this point (Duncan et al., 1994). Alternatively, increases in serum AST and CK levels may be due to alterations in cell permeability (leakage), increased synthesis or impaired clearance (Harris, 1993).

In our study, 28% of river otters subjected to capture, long-distance transportation and brief captivity showed abnormal elevations in serum enzymes consistent with myopathy. Abnormal AST and CK levels were likely more prevalent in otters within the first days of translocation, prior to when most otters of this study were sampled. We conclude that a high percentage of river otters translocated by the methods described herein develop mild or clinically inapparent EM.

ACKNOWLEDGMENTS

We thank the Board of Directors, especially D. Money, and the many volunteers of the New York River Otter Project, Inc. for their support. This project also benefited from the cooperation and interest of participating trappers of the

New York State Trappers Association. Assistance was also generously provided by B. Penrod and various personnel of the New York State Department of Environmental Conservation, Division of Wildlife.

LITERATURE CITED

- BARTSCH, R. C., E. E. MCCONNELL, G. D. IMES, AND J. M. SCHMIDT. 1977. A review of exertional rhabdomyolysis in wild and domestic animals and man. *Veterinary Pathology* 14: 314–324.
- BOLLINGER, T., G. WOBESER, R. G. CLARK, D. J. NIEMAN, AND J. R. SMITH. 1989. Concentration of creatine kinase and aspartate aminotransferase in the blood of wild mallards following capture by three methods for banding. *Journal of Wildlife Diseases* 25: 225–231.
- CARDINET, G. H. 1997. Skeletal muscle function. *In* Clinical biochemistry of domestic animals. 5th Edition, J. J. Kaneko, J. W. Harvey, and M. L. Bruss (eds.). Academic Press, San Diego, California, pp. 407–440.
- CHALMERS, G. A., AND M. W. BARRETT. 1982. Capture myopathy. *In* Noninfectious diseases of wildlife, G. L. Hoff and J. W. Davis (eds.). Iowa State University Press, Ames, Iowa, pp. 84–94.
- DAVIS, H. G., R. J. AULERICH, S. J. BURSIA, J. G. SIKARSKIE, AND J. N. STUHT. 1992. Hematologic and blood chemistry values of the northern river otter (*Lutra canadensis*). *Scientific* 16: 267–271.
- DUNCAN, J. R., K. W. PRASSE, AND E. A. MAHAFFEY. 1994. *Veterinary Laboratory Medicine: Clinical Pathology*. 3rd Edition. Iowa State University Press, Ames, Iowa, 300 pp.
- GANNON, J. R. 1980. Exertional rhabdomyolysis (myoglobinuria) in the racing greyhound. *In* Current veterinary therapy, VII, R. W. Kirk (ed.). W. B. Saunders Company, Philadelphia, Pennsylvania, pp. 783–787.
- HARRIS, P. A. 1993. Comparative aspects of exertional myopathy. *In* Veterinary science—Growth points and comparative medicine, Vol. 4, A. R. Michell (ed.). C. A. B. International, Wallingford, Oxon, UK, pp. 115–138.
- HOOVER, J. P., R. J. BAHR, M. A. NIEVES, R. T. DOYLE, M. A. ZIMMER, AND S. E. LAUZON. 1985. Clinical evaluation and prerelease management of American river otters in the second year of a reintroduction study. *Journal of the American Veterinary Medical Association* 187: 1154–1161.
- HOWERTH, E. W., AND C. M. E. MCCRINDLE. 1982. Acute renal failure in a dog following exertional rhabdomyolysis. *Journal of the South African Veterinary Association* 52: 115–117.
- KOCK, M. D., R. K. CLARK, C. E. FRANTI, D. A. JESSUP, AND J. D. WEHAUSEN. 1987. Effects of capture on biological parameters in free-ranging bighorn sheep (*Ovis canadensis*): Evaluation of normal, stressed and mortality outcomes and documentation of postcapture survival. *Journal of Wildlife Diseases* 23: 652–662.
- KOLLIAS, G. V. 1998. Health assessment, medical management, and prerelease conditioning of translocated North American river otters. *In* Zoo and wild animal medicine, current therapy 4, M. E. Fowler and R. E. Miller (eds.). W. B. Saunders Company, Philadelphia, Pennsylvania, pp. 443–448.
- SERFASS, T. L., R. L. PEPER, M. T. WHARY, AND R. P. BROOKS. 1993. River otter (*Lutra canadensis*) reintroduction in Pennsylvania: Prerelease care and clinical evaluation. *Journal of Zoo and Wildlife Medicine* 24: 28–40.
- SPRAKER, T. R. 1993. Stress and capture myopathy in artiodactyls. *In* Zoo and wild animal medicine, current therapy 3, M. E. Fowler (ed.). W. B. Saunders Company, Philadelphia, Pennsylvania, pp. 481–488.
- WALLACE, R. S., M. BUSH, AND R. J. MONTALI. 1987. Deaths from exertional myopathy at the National Zoological Park from 1975–1985. *Journal of Wildlife Diseases* 23: 454–462.
- WILLIAMS, E. S., AND E. T. THORNE. 1996. Exertional myopathy (Capture myopathy). *In* Noninfectious diseases of wildlife. 2nd Edition, A. Fairbrother, L. N. Locke, and G. L. Hoff (eds.). Iowa State University Press, Ames, Iowa, pp. 181–193.
- WILLIAMS, T. D., A. H. REBAR, R. F. TECLAW, AND P. E. YOOS. 1992. Influence of age, sex, capture technique, and restraint on hematologic measurements and serum chemistries of wild California sea otters. *Veterinary Clinical Pathology* 21: 106–110.

Received for publication 10 April 1998.