

Avian Pox in Sanderlings from Florida

Authors: Kreuder, Christine, Irizarry-Rovira, Armando R., Janovitz, Evan B., Deitschel, P. J., and DeNicola, Dennis B.

Source: Journal of Wildlife Diseases, 35(3) : 582-585

Published By: Wildlife Disease Association

URL: <https://doi.org/10.7589/0090-3558-35.3.582>

BioOne Complete (complete.BioOne.org) is a full-text database of 200 subscribed and open-access titles in the biological, ecological, and environmental sciences published by nonprofit societies, associations, museums, institutions, and presses.

Your use of this PDF, the BioOne Complete website, and all posted and associated content indicates your acceptance of BioOne's Terms of Use, available at www.bioone.org/terms-of-use.

Usage of BioOne Complete content is strictly limited to personal, educational, and non - commercial use. Commercial inquiries or rights and permissions requests should be directed to the individual publisher as copyright holder.

BioOne sees sustainable scholarly publishing as an inherently collaborative enterprise connecting authors, nonprofit publishers, academic institutions, research libraries, and research funders in the common goal of maximizing access to critical research.

Avian Pox in Sanderlings from Florida

Christine Kreuder,^{1,4} Armando R. Irizarry-Rovira,² Evan B. Janovitz,³ P. J. Deitschel,¹ and Dennis B. DeNicola,² ¹ Care and Rehabilitation of Wildlife, Inc., PO Box 150, Sanibel, Florida 33957, USA; ² Department of Veterinary Pathobiology, Purdue University School of Veterinary Medicine, West Lafayette, Indiana 47907, USA; ³ Animal Disease Diagnostic Laboratory, Purdue University, West Lafayette, Indiana 47907, USA; and ⁴ Corresponding author (email: ckreuder@aol.com).

ABSTRACT: Avian pox was diagnosed in three sanderlings (*Calidris alba*) on Sanibel Island, Florida (USA) in February 1997. All three cases had large tumor-like lesions which contributed significantly to their mortality. Poxvirus infection was confirmed by cytology, histopathology, and electron microscopy. This is the first report of poxvirus infection in sanderlings.

Key words: Avian pox, *Calidris alba*, case report, cytology, sanderlings.

Avian poxvirus has been documented in many species of birds but there are few reports of naturally occurring infection in wild shorebird populations (Green, 1969; Jacobson et al., 1980; Wingate et al., 1980). It has been described in the dunlin (*Calidris alpina*) (Green, 1969), the white-tailed tropicbird (*Phaethon lepturus*) (Wingate et al., 1980), the Canada Goose (*Branta canadensis*) (Cox, 1979), the royal tern (*Thalasseus maximus*), and others (Jacobson et al., 1980). The disease can be fatal to the affected bird, or it can be self-limiting (Wingate et al., 1980; Deem et al., 1997; Tripathy and Reed, 1997). The antigenic relationships between poxviruses isolated from waterfowl vary, and gulls experimentally infected with fowl poxvirus did not exhibit clinical signs (Ritchie, 1995). Sanderlings (*Calidris alba*) are a common migrant to the coastal USA during the wintertime and large numbers winter along the Gulf Coast. During a 2 wk period in February 1996, three adult sanderlings were found by members of the public on the gulf beaches of Sanibel Island (Florida, USA; 26°25'N, 82°07'W). All three were admitted to the clinic at Care and Rehabilitation of Wildlife (C.R.O.W., Sanibel Island, Florida, USA) with large tumor-like masses on both feathered and unfeathered skin.

Case 1 presented with lethargy, severe hypothermia, dehydration, and emaciation. A 2.5 cm diameter mass incorporating several feather shafts was noted on the dorsal surface over the distal radius and ulna of the left wing. Another 0.5 cm diameter mass was adjacent covering the dorsal surface of the carpus. Both masses appeared edematous, hyperemic and fibrotic, and they were bleeding at the surface. Attempts were made to correct the hypothermia and dehydration but the patient expired within 1 hr of admission. Necropsy revealed no other gross abnormalities. The entire left wing was placed in formalin.

Case 2 was alert and active on admission. Physical examination revealed mild dehydration, thin body condition, and a 3 cm diameter mass on the dorsal surface of the left wing between the elbow and shoulder. Several feather shafts protruded from the mass. The surface of the mass appeared ulcerated and was bleeding profusely. The patient was rehydrated, placed on systemic antibiotics, and the wing was pressure wrapped to slow the bleeding. Mass removal was planned once the patient was stable. Four days after admission, the bird became anorectic and a 1 cm mass was discovered at the base of the tongue. The sanderling was euthanized and the left wing and oral mass were placed in formalin. Necropsy revealed no other gross abnormalities.

Case 3 was admitted with hypothermia, severe dehydration and emaciation. A 2.5 cm diameter mass was noted at the base of the beak incorporating soft tissue of the maxilla and mandible (Fig. 1). External appearance of the mass was similar to that of the masses seen on the other patients.



FIGURE 1. Proliferative mass of avian pox at the base of the beak in a sanderling in Florida (USA).

Based on the grave prognosis, the patient was euthanized immediately. Necropsy again revealed no other lesions grossly.

Tissue samples from Case 1 and Case 2 were sent to diagnostic pathology laboratories (Antech Diagnostics, Farmingdale, New York, USA, and Veterinary Clinical Pathology Laboratory, Purdue University, West Lafayette, Indiana, USA). Cytologic preparations were stained with Hematology three-step® (Accra Lab, New Jersey, USA) cytologic stain. Tissues collected at necropsy were fixed in 10% buffered neutral formalin, embedded in paraffin, sectioned 5 μm , and stained with hematoxylin-eosin. For transmission electron microscopy, the tissues that had been fixed in 10% buffered neutral formalin were transferred into 3% glutaraldehyde, sectioned in $<1\text{mm}^3$ portions, postfixed in osmium tetroxide, dehydrated in progressive series of alcohol and propylene oxide, and embedded in Epon (Polysciences Inc., Warrington, Pennsylvania, USA) by the Electron Microscopy Laboratory (School of Veterinary Medicine, Purdue University, West Lafayette, Indiana, USA). Thin sections were stained with uranyl acetate and Reynold's lead citrate and examined using a JEM-100CX transmission electron microscope (JEOL, Tokyo, Japan).

The cytologic preparations (imprints) of the lesions consisted primarily of moderate numbers of erythrocytes and numerous squamous epithelial cells in a finely granular, amorphous magenta background. The

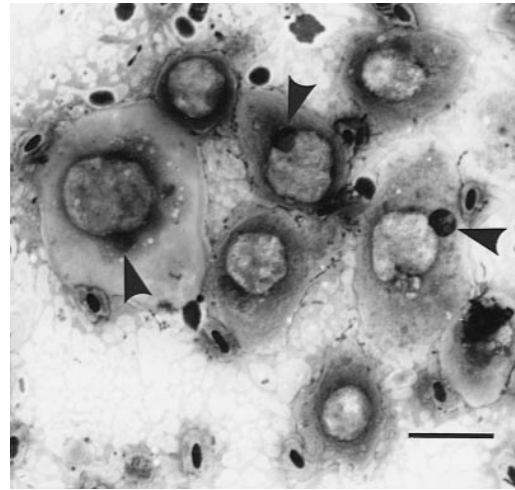


FIGURE 2. Photomicrograph of the cytologic preparation of the mass at the base of the beak of a sanderling with avian pox. Numerous swollen keratinocytes with single intracytoplasmic, pale, round to polygonal viral inclusions displacing the nucleus peripherally (arrowheads point to the nuclei of the cells). Hematology Three Step. Bar = 20 μm .

swollen, distorted, round mononuclear squamous cells varied in size from 25–40 μm in diameter and possessed moderate to abundant amounts of well-delineated, finely granular pink cytoplasm. Single, prominent, round, 10–20 μm in diameter coarsely granular, pale pink, intracytoplasmic viral inclusions were present and displaced the nucleus peripherally. Nuclei were round to oval and 5–8 μm in diameter (Fig. 2). Many similarly appearing structures identified as inclusions also were present cell free.

Histopathologic sections of the submitted lesions consisted of islands and cords of markedly hyperplastic and invasive epidermal stratified squamous epithelium in a dense fibroblastic stroma. These islands and cords consisted of swollen, pale keratinocytes in progressive stages of cornification, with foamy, vacuolated eosinophilic cytoplasm and single, round, 5–15 μm in diameter, homogeneous, dense eosinophilic intracytoplasmic viral inclusions (Bollinger bodies). Keratinocyte nuclei were displaced and distorted by the viral inclusions. The proliferated islands and cords

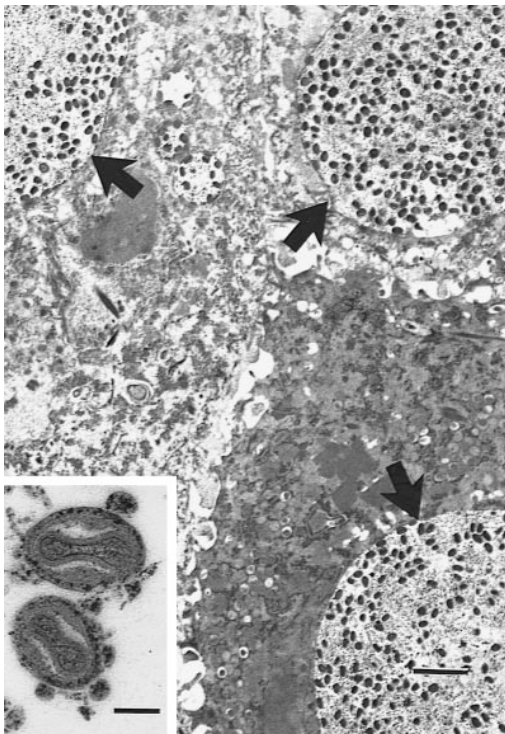


FIGURE 3. Electron micrograph of ultrathin sections of the mass at the base of the beak of a sanderling with avian pox. The figure shows swollen, degenerate keratinocytes with intracytoplasmic membrane bound inclusions with numerous virions (arrows). Bar = 2 μ m. The inset shows the detail of the typical poxvirus virions with an electron dense biconcave nucleocapsid core, two lateral bodies and an outer lipoprotein coat. Bar = 100 nm.

had centers of amorphous, eosinophilic, keratinaceous debris mixed with variable numbers of cell-free viral inclusions. At the edges of the lesion the epidermis became progressively hyperplastic and was continuous with the invasive proliferated tissues. Eosinophilic, amorphous keratinaceous crusts were present on the surface.

Ultrastructurally, swollen keratinocytes contained round, membrane bound cytoplasmic vesicles. These were filled with numerous, 250–300 \times 150 nm mature virions and free electron-dense outercoat tubules (Fig. 3). The oval to brick-shaped virions possessed an electron-dense biconcave nucleocapsid core, an intermediate coat enclosing two lateral bodies, and an outer lipoprotein coat (Tripathy and Reed,

1997). Immature viral particles were present outside and were identified budding into the vesicles as they gained the outer lipoprotein coat (Cheville, 1994; Moss, 1996).

Based on the cytological, histopathological, and ultrastructural findings, poxvirus infection was diagnosed. The pathologic changes seen at the light microscopic and ultrastructural levels are consistent with other reported cases of poxvirus in birds (Cox, 1980; Wingate et al., 1980; Jacobson et al., 1980; Campbell, 1988; Gerlach, 1994; Ritchie, 1995; Tsai et al., 1997; Deem et al., 1997). In all three cases, poxvirus infection is believed to be an important, if not direct, cause of the birds death. Blood loss at the wing mass was significant in Cases 1 and 2 and was worsened by self-inflicted trauma to the lesion in Case 2. The sheer mass and weight of the wing lesions would not have permitted flight in these birds. The maxilla/mandibular lesion in Case 3 prevented feeding. The rapidity with which a second lesion developed in the oral cavity of Case 2 is common with poxvirus infections. It is possible that the wing masses incorporating feathered skin developed secondary to trauma caused by preening. The precise mode of transmission of poxvirus in sanderlings is not known nor do we recognize what impact, if any, poxvirus may have on sanderling populations.

The assistance of D. VanHorn, P. Lockerd, and N. Martin is gratefully acknowledged. M. Calderwood-Mays is also acknowledged for her histopathologic diagnosis of poxvirus in the first case admitted to the clinic.

LITERATURE CITED

- CAMPBELL, T. 1988. Avian hematology and cytology. Iowa State University Press, Ames, Iowa, 101 pp.
- CHEVILLE, N. 1994. Ultrastructural pathology: An introduction to interpretation. Iowa State University Press, Ames, Iowa, 946 pp.
- COX, W. 1980. Avian pox infection in a Canada Goose (*Branta canadensis*). *Journal of Wildlife Diseases* 16: 623–626.
- DEEM, S., D. HEARD, AND J. FOX. 1997. Avian pox

- in Eastern Screech owls and Barred owls from Florida. *Journal of Wildlife Diseases* 33: 323–327.
- GERLACH, H. 1994. Viruses. *In* Avian medicine: Principles and applications, B. Ritchie, G. Harrison, and L. Harrison (eds.). Wingers Publishing Incorporated, Lake Worth, Florida, pp. 862–948.
- GREEN, G. 1969. Suspected poxvirus of a dunlin. *British Birds* 62:26–27.
- JACOBSON, E., B. RAPHAEL, H. NUGUYEN, E. GREINER, AND T. GROSS. 1980. Avian poxvirus infection, aspergillosis and renal trematodiasis in a royal tern. *Journal of Wildlife Diseases* 16: 627–631.
- MOSS, B. 1996. Poxviridae: The viruses and their replication. *In* Field's virology, 3rd Edition, B. Fields, D. Knipe, P. Howley, R. Chanock, J. Melnick, T. Monath, B. Roizman, and S. Straus (eds.). Lippincott-Raven Publishers, Philadelphia, Pennsylvania, pp. 2637–2671.
- RITCHIE, B. 1995. Avian viruses: Function and control. Wingers Publishing Incorporated, Lake Worth, Florida, 525 pp.
- TRIPATHY, D., W., AND REED 1997. Pox. *In* Diseases of poultry, 10th Edition, B. Calnek, H. Barnes, C. Beard, L. McDougald, and Y. Saif (eds.). Iowa State University Press, Ames, Iowa, pp. 643–659.
- TSAI, S., T. CHANG, S. YANG, Y. CHI, R. CHER, M. CHIEN, AND C. ITAKURA. 1997. Unusual lesions associated with avian poxvirus infection in rose-faced lovebirds (*Agapornis roseicollis*). *Avian Pathology* 26: 75–82.
- WINGATE, D., I. BARKER, AND N. KING. 1980. Poxvirus infection of the white-tailed tropicbird (*Phaethon lepturus*) in Bermuda. *Journal of Wildlife Diseases* 16: 619–622.

Received for publication 13 July 1998.