

## **PATHOLOGY OF EXPERIMENTAL MYCOPLASMOSIS IN AMERICAN ALLIGATORS**

Authors: Brown, D. R., Nogueira, M. F., Schoeb, T. R., Vliet, K. A., Bennett, R. A., et al.

Source: Journal of Wildlife Diseases, 37(4) : 671-689

Published By: Wildlife Disease Association

URL: <https://doi.org/10.7589/0090-3558-37.4.671>

---

BioOne Complete ([complete.BioOne.org](https://complete.BioOne.org)) is a full-text database of 200 subscribed and open-access titles in the biological, ecological, and environmental sciences published by nonprofit societies, associations, museums, institutions, and presses.

Your use of this PDF, the BioOne Complete website, and all posted and associated content indicates your acceptance of BioOne's Terms of Use, available at [www.bioone.org/terms-of-use](https://www.bioone.org/terms-of-use).

Usage of BioOne Complete content is strictly limited to personal, educational, and non - commercial use. Commercial inquiries or rights and permissions requests should be directed to the individual publisher as copyright holder.

---

BioOne sees sustainable scholarly publishing as an inherently collaborative enterprise connecting authors, nonprofit publishers, academic institutions, research libraries, and research funders in the common goal of maximizing access to critical research.

## PATHOLOGY OF EXPERIMENTAL MYCOPLASMOSIS IN AMERICAN ALLIGATORS

D. R. Brown,<sup>1,5</sup> M. F. Nogueira,<sup>1,4</sup> T. R. Schoeb,<sup>1</sup> K. A. Vliet,<sup>2</sup> R. A. Bennett,<sup>3</sup> G. W. Pye,<sup>3</sup> and E. R. Jacobson<sup>3</sup>

<sup>1</sup> Department of Pathobiology, College of Veterinary Medicine, University of Florida, Gainesville, Florida 32611, USA

<sup>2</sup> Department of Zoology, College of Liberal Arts and Sciences, University of Florida, Gainesville, Florida 32610, USA

<sup>3</sup> Department of Small Animal Clinical Sciences, College of Veterinary Medicine, University of Florida, Gainesville, Florida 32611, USA

<sup>4</sup> College of Veterinary Medicine and Animal Sciences, University of Sao Paulo, Botucatu, Sao Paulo 18618-000, Brazil

<sup>5</sup> Corresponding author (e-mail: brownd@mail.vetmed.ufl.edu)

**ABSTRACT:** *Mycoplasma alligatoris* was the suspected etiology of an epidemic of acute multisystemic inflammatory disease which emerged in captive American alligators (*Alligator mississippiensis*) in Florida (USA) in 1995. In an experimental inoculation study conducted from April through October 1999, 18 alligators were inoculated with 10<sup>2</sup>, 10<sup>4</sup>, or 10<sup>6</sup> colony forming units (CFU) of *M. alligatoris* by instillation into the glottis. As early as 1 wk post-inoculation (PI), mycoplasma were cultured from blood of three of six alligators inoculated with 10<sup>6</sup> CFU. Two of those died and the third was euthanatized within 4 wk PI. Necropsy gross findings included fibrinous polyserositis and polyarthritis. Histopathologic changes in affected individuals included pulmonary edema, interstitial pneumonia, pericarditis, myocarditis, meningitis, and synovitis. Mycoplasma were cultured quantitatively in high numbers from trachea, lung, coelomic cavity, liver, spleen, interior of pericardial sac, heart, blood, brain, and limb joints. In alligators inoculated with 10<sup>6</sup> CFU, heterophilia and moderate hyperglycemia peaked about 4 wk PI, and seroconversion occurred by 6 to 8 wk PI. Necropsy gross and histologic findings were generally unremarkable for the surviving alligators inoculated with 10<sup>6</sup> CFU, alligators inoculated with 10<sup>2</sup> or 10<sup>4</sup> CFU, and four uninoculated control alligators. Mycoplasma were not cultured at any time point from those alligators. The findings confirm that *M. alligatoris* can cause fulminant inflammatory disease and rapid death of alligators.

**Key words:** *Alligator mississippiensis*, *Mycoplasma alligatoris*, American alligator, mycoplasmosis, pathology.

### INTRODUCTION

An epidemic of acute fatal multisystemic inflammatory disease, including pneumonia, pericarditis, and multifocal arthritis, emerged in captive American alligators (*Alligator mississippiensis*) in St. Johns County, Florida, USA, in 1995. The affected group was composed of 200 to 300 kg adult males that were older than 30 yr, housed in a 20 × 50 m outdoor sandy enclosure with a central spring-fed pool. Thirty-three alligators died and thirteen moribund alligators were euthanatized within 1 mo of the index case. No probative abnormalities in blood cell counts or plasma biochemistry were observed. Results of toxicant, heavy metal, mineral, and vitamin analyses of tissues and serum were unremarkable. Results of routine aerobic and anaerobic bacterial culture of blood

and lung tissue samples were uninformative regarding the etiology of the disease. Attempts to isolate virus from pneumonic lung tissue samples were unsuccessful. However, a previously undescribed species of mycoplasma, *Mycoplasma alligatoris* (Brown et al., 2001a), was later cultured from multiple tissues and body fluids of affected alligators. No mycoplasma could be cultured or detected by polymerase chain reaction (PCR) from blood or tissues of five healthy control alligators that were euthanatized for diagnostic necropsy, which finding implicated *M. alligatoris* as a possible etiologic agent (Clippinger et al., 2001).

A subsequent pilot experimental inoculation study fulfilled the Henle-Koch-Evans postulates for *M. alligatoris* as the etiology of fatal mycoplasmosis of alligators. Four healthy alligators were inoculat-

ed with  $1 \times 10^6$  colony forming units (CFU) of *M. alligatoris* by intracoelomic injection ( $n = 2$ ) or by instillation into the glottis ( $n = 2$ ). A control alligator received sterile broth. Three of four inoculated alligators died between 1 and 3 wk post-inoculation (PI) with systemic mycoplasmosis. Regardless of inoculation route, *M. alligatoris* was re-isolated post-mortem from multiple organs and body fluids. Pathology included diffuse interstitial pneumonia, severe fibrinous pericarditis, arthritis of the stifle and elbow joints, lymphocytic periportal hepatitis, lymphocytic interstitial nephritis, and lymphoid splenic hyperplasia (Clippinger et al., 2001). The 6-wk PI anti-*M. alligatoris* antibody titer of the surviving alligator rose to 1:640 and remained constant for the following 8 wk. The control remained seronegative (titer 1:<10) and free of mycoplasma at necropsy after 14 wk (Brown et al., 2001a). The findings were remarkable because mycoplasmosis generally occurs as a chronic disease which, with the exception of *Mycoplasma mycoides* subsp. *mycoides* in ruminants, is rarely lethal in animals.

Understanding the pathogenesis of *M. alligatoris* mycoplasmosis is essential to prevent or respond to possible future epidemics. In this paper we report the results of detailed pathological, hematological, and bacteriological examinations of alligators following experimental inoculation with different doses of *M. alligatoris*.

#### MATERIALS AND METHODS

Twenty-two young adult female American alligators (116 to 147 cm; 6 to 13 kg) were obtained from the St. Augustine Alligator Farm and Zoological Park (St. Augustine, Florida, USA) in April, 1999. The alligators were kept indoors at the University of Florida (UF) Biosafety Level 2 Large Animal Containment Facility (Gainesville, Florida, USA). The alligators were maintained in new galvanized metal tanks 2 m long  $\times$  1 m wide  $\times$  0.5 m high, tilted and partially filled with tap water, with expanded-metal tops. There were two alligators of the same size and treatment group per tank. The alligators were observed three times per day by trained caretakers. Each alligator was provided

two times per week 125 g of a complete pelleted ration, containing 45% crude protein, 8% crude fat, and 3.5% crude fiber, which they were used to consuming. The water in each tank was changed three times per week. All wastewater was disinfected before being discharged. Room temperature was constant 26.5 C. Room lights were on daily from 07:00 until 16:00 hr.

A baseline blood sample from each alligator was collected from the supravertebral sinus in a lithium-heparinized glass container, and analyzed in the Clinical Pathology laboratories at the UF Veterinary Medical Teaching Hospital (Gainesville, Florida). Red blood cell counts and hemoglobin concentrations were determined by using a Coulter hematology analyzer (Beckman Coulter, Fullerton, California, USA). White blood cell counts were determined manually. Plasma biochemical values were determined by using the Alcyon clinical chemistry system (Abbott Laboratories, Abbott Park, Illinois, USA). A cloacal lavage specimen from each alligator was examined for evidence of parasites by using standard methods of flotation and sedimentation. Blood test results were unremarkable, and no parasites were detected. The baseline blood samples were cultured in American Type Culture Collection (ATCC) mycoplasma medium 988 broth (SP4; Tully, 1995), supplemented with fetal bovine serum (20% v/v), in ambient air, and on SP4 agar in 5% CO<sub>2</sub>, at 30 C. All baseline blood samples were culture negative for mycoplasma. Baseline lithium-heparinized plasma samples from all alligators were screened by enzyme-linked immunosorbent assay (ELISA) for specific anti-*M. alligatoris* antibodies (Brown et al., 2001b). All alligators were seronegative at intake.

The alligators were acclimated for 6 wk post-transportation. Alligators ( $n = 6$  per group) were inoculated by instillation into the glottis of 1 ml of SP4 broth containing  $1 \times 10^2$ ,  $1 \times 10^4$ , or  $1 \times 10^6$  CFU of third-passage *M. alligatoris* strain A21JP2<sup>T</sup>. As negative controls, four alligators received either inoculation with sterile broth or no treatment of any kind. Blood samples were obtained from the supravertebral sinus in lithium-heparinized glass containers from all alligators at weekly intervals for 4 wk, then biweekly, until the alligators died or were euthanatized 12 to 16 wk PI. For mycoplasma culture at each time point, 20  $\mu$ l of blood was added to 1 ml of SP4 broth, then 20  $\mu$ l of that culture was inoculated onto SP4 agar. Broths and agar plates were incubated as described above. Mycoplasma growth in broth was detected by a color change from red to yellow as a result of acidification of the broth following glucose fermentation. Mycoplasma colonies

growing on agar plates were visualized by using a dissecting microscope. Plasma was stored at  $-70^{\circ}\text{C}$  in polypropylene cryovials for ELISA. Because of clinical laboratory constraints, only a subset of the blood samples could be analyzed by hematology and clinical biochemistry at each time point.

A complete diagnostic necropsy was performed on each alligator. Necropsies were completed by October 1999. For euthanasia, 0.5 ml/kg of a solution containing 390 mg/ml of pentobarbital sodium and 50 mg/ml phenytoin sodium (Beuthanasia-D Special, Schering-Plough, Kenilworth, New Jersey, USA) was administered by injection into the supravertebral sinus. When the alligator was unresponsive to a painful stimulus, the cervical spinal cord was severed.

Samples of tissues (trachea, lung, heart, spleen, liver, brain), ultrafine-tip nylon swabs (glottis, conjunctivae, interior of pericardial sac, interior of coelomic cavity, tonsils, limb joints) and body fluids (blood, cerebrospinal fluid) were collected aseptically for quantitative mycoplasma culture. Neat samples were 0.5 g minced tissue, an expressed swab, or 20  $\mu\text{l}$  fluid, in 1 ml SP4 broth. Neat samples were serially diluted ten-fold to  $10^{-8}$  in SP4 broth, then 20  $\mu\text{l}$  of each dilution was inoculated onto SP4 agar. Broths and plates were incubated and observed as described above. The identity of mycoplasma recovered by culture was confirmed by restriction endonuclease analysis of the 16S rRNA gene after amplification by PCR (Brown et al., 1996).

Blood was collected from the supravertebral sinus in lithium-heparinized glass containers for hematology, biochemistry, and ELISA for specific anti-*M. alligatoris* antibodies. Blood was obtained by aseptic heart puncture for standard bacterial culture in brain-heart infusion broth at room temperature and  $37^{\circ}\text{C}$ . Broths which turned turbid were subcultured on sheep's blood agar and eosin-methylene blue agar, and isolates were identified by using the Minitek System (Becton Dickinson Microbiology Systems, Cockeysville, Maryland, USA). The ELISA values were analyzed by repeated measures analysis of variance with main effects of week PI and treatment group. Seroconversion was defined as statistically significant increase from the pre-inoculation group mean. A value of  $P < 0.05$  was considered significant. Fisher's protected LSD was used for post-hoc comparisons if main effects were significant. Statistical analyses were done with Statview 5.0.1, 1998 version (SAS Institute, Cary, North Carolina, USA).

Samples of tissues (trachea, lung, pericardium, heart, spleen, liver, kidney, brain, tonsil,

limb joint synovium) were fixed in 10% neutral buffered formalin, embedded in paraffin, sectioned, and stained with hematoxylin and eosin (Sheehan and Hrapchak, 1980). Liver sections were also stained with Perl's iron stain (Luna, 1968). Tissue sections were examined by using light microscopy and graded for lesions by a pathologist who did not know the treatment group of each specimen. *Normal* was occasional heterophils or lymphocytes, and no edema or changes in tissue structure. *Mild* changes were small multifocal lymphoid aggregates, small numbers of diffuse heterophils or lymphocytes, mild edema, and mild changes in tissue structure. *Moderate* changes were multifocal to focally extensive lymphoid aggregates, moderate numbers of diffuse heterophils and lymphocytes, moderate edema, and disorganization of tissue structure. *Severe* changes were large numbers of heterophil and lymphocyte infiltrates, marked edema, and necrosis.

## RESULTS

*Mycoplasma alligatoris* was cultured as early as 1 wk PI from peripheral blood of three alligators inoculated with  $10^6$  CFU. One of those (accession number AA168067) died abruptly after 1 wk PI, another (AA165094) died abruptly after 4 wk PI, and the third (AA165089) was euthanized after 4 wk PI because it had sudden onset of overt signs of neuromuscular dysfunction including gaping mouth and postural instability. Disseminated mycoplasmosis was demonstrated at necropsy of those alligators by positive cultures obtained from every site sampled except glottis and conjunctivae (Table 1). Mycoplasma were not cultured at any time point from peripheral blood or from any tissue of the surviving three alligators inoculated with  $10^6$  CFU, 12 alligators inoculated with  $10^2$  or  $10^4$  CFU, or any negative controls, and no signs of disease were observed in those alligators.

Hematological and plasma biochemical data were incomplete enough that meaningful statistical analyses of effects of inoculation with *M. alligatoris* were not possible. In alligators inoculated with  $10^6$  CFU, moderate heterophilia (about a 50% increase from baseline in the number of heterophils in peripheral blood) peaked 3

TABLE 1. Association of *Mycoplasma alligatoris* infection with histological lesions in alligators.

Site	AA165089 <sup>a</sup>		AA165094 <sup>a</sup>		AA168067 <sup>a</sup>	
	Mycoplasma <sup>b</sup>	Lesion scores <sup>c</sup>	Mycoplasma <sup>b</sup>	Lesion scores <sup>c</sup>	Mycoplasma <sup>b</sup>	Lesion scores <sup>c</sup>
Trachea <sup>d</sup>	<30	mild	<30	normal	<30	normal
Lung <sup>e</sup>	7.4 × 10 <sup>9</sup>	mild	1.0 × 10 <sup>4</sup>	normal	4.9 × 10 <sup>1</sup>	mild
Pericardium <sup>d</sup>	8.9 × 10 <sup>9</sup>	severe	4.2 × 10 <sup>5</sup>	mild	<30	normal
Heart <sup>e</sup>	>3 × 10 <sup>10</sup>	severe	9.1 × 10 <sup>3</sup>	mild	<30	mild
Spleen <sup>e</sup>	4.7 × 10 <sup>1</sup>	normal	3.7 × 10 <sup>3</sup>	normal	1.0 × 10 <sup>2</sup>	mild
Liver <sup>e</sup>	8.6 × 10 <sup>6</sup>	severe	1.1 × 10 <sup>4</sup>	normal	1.0 × 10 <sup>2</sup>	normal
Brain <sup>e</sup>	1.2 × 10 <sup>4</sup>	severe	1.1 × 10 <sup>3</sup>	mild	<30	normal
Left elbow <sup>d</sup>	3.9 × 10 <sup>3</sup>	normal	<30	normal	<30	normal
Right elbow <sup>d</sup>	3.7 × 10 <sup>3</sup>	normal	<30	normal	6.0 × 10 <sup>3</sup>	severe
Left knee <sup>d</sup>	5.5 × 10 <sup>2</sup>	normal	8.3 × 10 <sup>8</sup>	moderate	negative	normal
Right knee <sup>d</sup>	8.0 × 10 <sup>1</sup>	normal	4.6 × 10 <sup>8</sup>	moderate	negative	normal
Tonsil <sup>d</sup>	negative	mild	negative	normal	<30	normal
Coelomic cavity <sup>d</sup>	6.2 × 10 <sup>7</sup>	N/A <sup>f</sup>	1.3 × 10 <sup>5</sup>	N/A <sup>f</sup>	negative	N/A <sup>f</sup>

<sup>a</sup> Animal accession number.  
<sup>b</sup> Colony forming units per sample.  
<sup>c</sup> Normal was occasional heterophils or lymphocytes, and no edema or changes in tissue structure. Mild changes were small multifocal lymphoid aggregates, small numbers of diffuse heterophils or lymphocytes, mild edema, and mild changes in tissue structure. Moderate changes were multifocal to focally extensive lymphoid aggregates, moderate numbers of diffuse heterophils and lymphocytes, moderate edema, and disorganization of tissue structure. Severe changes were large numbers of heterophil and lymphocyte infiltrates, marked edema, and necrosis.  
<sup>d</sup> Sample was an ultrafine-tip nylon swab.  
<sup>e</sup> Sample was 0.5 g minced tissue.  
<sup>f</sup> Not assessed.

to 4 wk PI, and blood glucose was elevated about 2-fold from baseline by 3 to 4 wk PI, consistent with systemic inflammatory disease. Moderate lymphocytopenia (about a 50% decrease from baseline in the number of lymphocytes) was observed at necropsy of the alligators that died. No other effects on other blood cell counts, plasma electrolytes, or liver function indicators in any group were noted.

Statistical power to detect seroconversion in the group inoculated with 10<sup>6</sup> CFU was reduced because half of those alligators died before specific antibody could be produced (Brown et al., 2001b). The mean anti-*M. alligatoris* antibody level among the surviving alligators in that group rose to about 2-fold higher (*P* < 0.05) than the pre-inoculation mean beginning 6 wk PI. Trends toward seroconversion in the groups inoculated with 10<sup>2</sup> or 10<sup>4</sup> CFU were not significant. Uninoculated controls did not seroconvert.

Heart blood samples cultured for bacteria other than mycoplasma were negative

at necropsy except for alligators that had superficial skin lesions or bite wounds. *Aeromonas hydrophila*, *Micrococcus kristinae*, *Proteus vulgaris*, and *Vibrio parahaemolyticus* were cultured from blood of one alligator in the uninoculated control group, which had a bite wound on its leg. *Staphylococcus cohnii* was cultured from blood of one alligator in the low-dose group, which had tan-colored friable lesions on jaw and dorsal skin. *Micrococcus kristinae* was cultured from blood of a second alligator in the low-dose group, which had a raw lesion on its neck. One alligator in the high-dose group (AA168067), which had a bite wound on its leg, had bacteremia of *A. hydrophila*, *Proteus mirabilis*, and *V. parahaemolyticus*. Encysted nymphs of the pentastome *Sebekia mississippiensis* were recovered from the lungs, and a single male ascarid *Dujardinascaris waltoni* was present in the stomach, at necropsy of another alligator in the high-dose group.

Gross anatomical and histological findings at necropsy were normal for all alli-



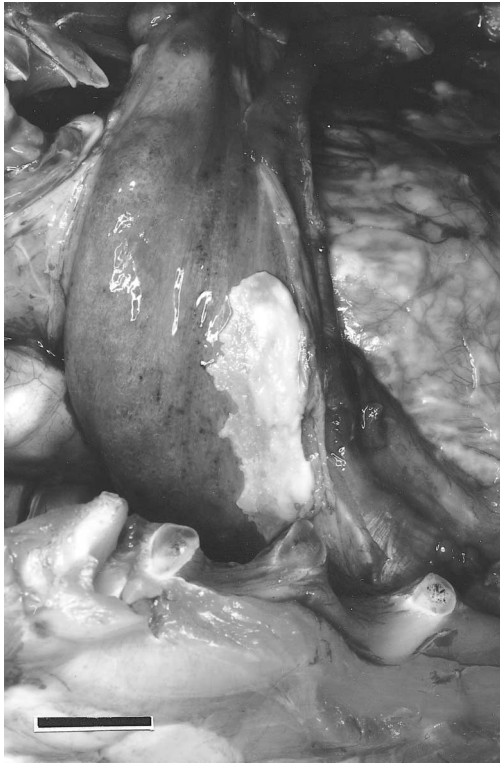

FIGURE 1. Fibrinous pleuritis following inoculation of an American alligator with  $1 \times 10^6$  CFU of *Mycoplasma alligatoris*. Bar = 3 cm.

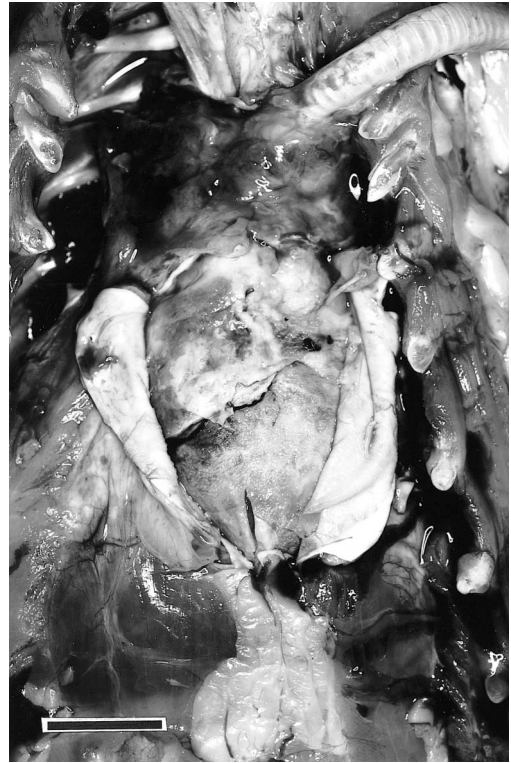

FIGURE 2. Fibrinous epicarditis and pericarditis following inoculation of an American alligator with  $1 \times 10^6$  CFU of *Mycoplasma alligatoris*. Bar = 3 cm.

gators in the uninoculated control (including the individual with Gram-negative bacteremia), lowest-dose, and medium-dose groups, and for the three alligators in the highest-dose group which did not develop *M. alligatoris* septicemia. Among the three alligators that died with disseminated mycoplasmosis, gross pathologic findings at necropsy (Table 1) were variable but presented an overall picture of acute multi-systemic inflammatory disease. In affected alligators the lungs had local purple discoloration with congestion and fibrinous pleuritis (Fig. 1). Edema fluid, heterophils, and small numbers of mononuclear cells were present in the lung interstitium. The thickened pericardium showed moderate fibrinous pericarditis to pyogranulomatous inflammation (Fig. 2). The myocardium displayed small multifocal areas of necrosis to severe fibrinous pyogranulomatous myocarditis, with vacuoles within the myo-

cardium, and endocarditis. Fibrin and serous exudate were present within the thickened liver capsule (Fig. 3), and the surface of the liver had pyogranulomatous inflammation. Small numbers of mononuclear cells and increased numbers of lymphocytes were present in periportal areas. The spleen displayed loss of normal architecture, multifocal areas of necrosis, and lymphoid follicle depletion, with increased numbers of mononuclear cells, macrophages, and heterophils throughout the spleen. The forebrain, midbrain, hindbrain, and cerebellum displayed diffuse moderate to severe heterophilic lymphocytic or pyelogrammatous meningitis (Figs. 4, 5). No significant gross or histological changes were noted in the kidneys. Affected alligators had arthritis of one or more limb joints, with subcutaneous edema and cloudy yellow inspissated synovial fluid. There was mild to moderate thick-

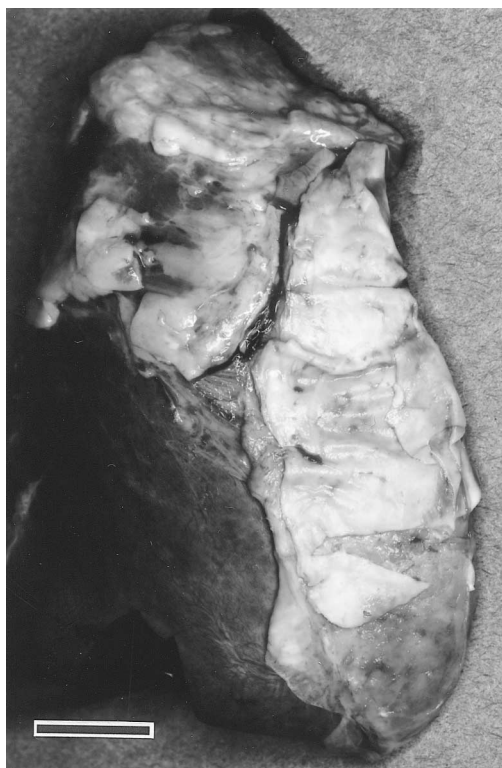


FIGURE 3. Fibrin sheets within thickened liver capsule following inoculation of an American alligator with  $1 \times 10^6$  CFU of *Mycoplasma alligatoris*. Bar = 2 cm.

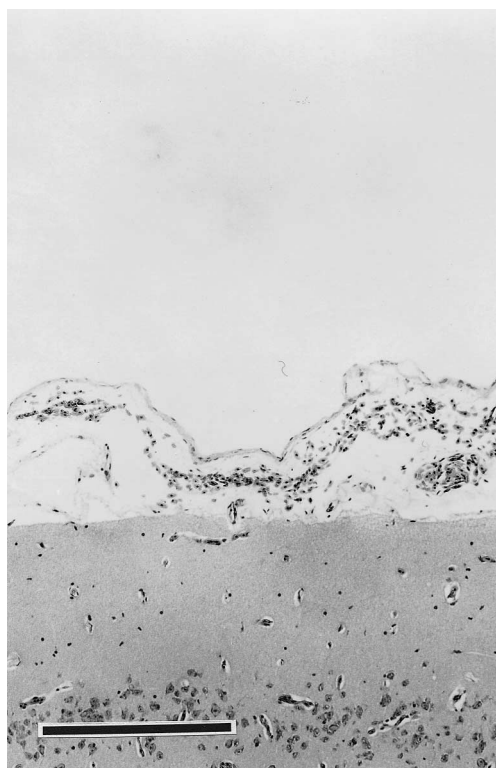


FIGURE 4. Histologic section of brain of an American alligator showing normal meninges following sham inoculation with sterile broth. Bar = 200  $\mu$ m.

ening of the synovial lining, with infiltrates of heterophils and lymphocytes. More severely affected joints had moderate necrotizing synovitis with pyogranulomatous inflammation (Fig. 6). No significant lesions were noted in joints of the axial skeleton.

#### DISCUSSION

The disease following experimental inoculation of alligators with *M. alligatoris* was clinically similar to that observed during the natural epidemic which occurred in 1995 among captive alligators in Florida. The disease was acute, with death occurring as early as 1 wk after exposure. Indicators of the disease were nonspecific reflections of multisystemic inflammation, such as lethargy and edema, and moderate hematologic and plasma biochemical changes. The pathology following experi-

mental inoculation of alligators with  $1 \times 10^6$  CFU of *M. alligatoris* was also similar to that resulting from the natural disease. Pathologic changes associated with the mycoplasma infection were fibrinous polyserositis and polyarthritides, leading to fulminant inflammatory disease and death, probably caused by meningitis and pneumonia, in half of the alligators exposed to that dose. Doses of  $1 \times 10^2$  or  $1 \times 10^4$  CFU of *M. alligatoris* did not cause mycoplasmosis in alligators when instilled into the glottis.

The disease is potentially significant to both captive and wild alligators. Ranches in the U.S. Gulf Coast states annually process approximately 175,000 alligators for hides and meat (Louisiana Cooperative Extension Service, 2000; Lane and King, 1996). Live alligators are frequently exchanged among collections, and are also

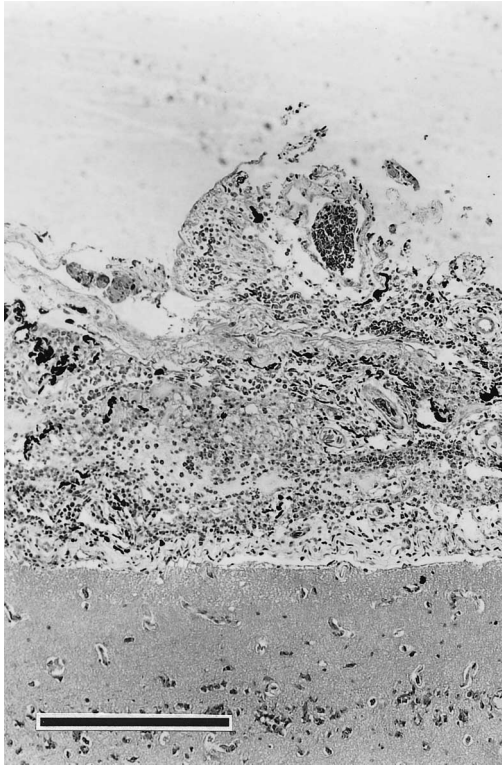


FIGURE 5. Histologic section of brain of an American alligator showing heterophilic meningitis following inoculation with  $1 \times 10^6$  CFU of *Mycoplasma alligatoris*. Bar = 200  $\mu$ m.

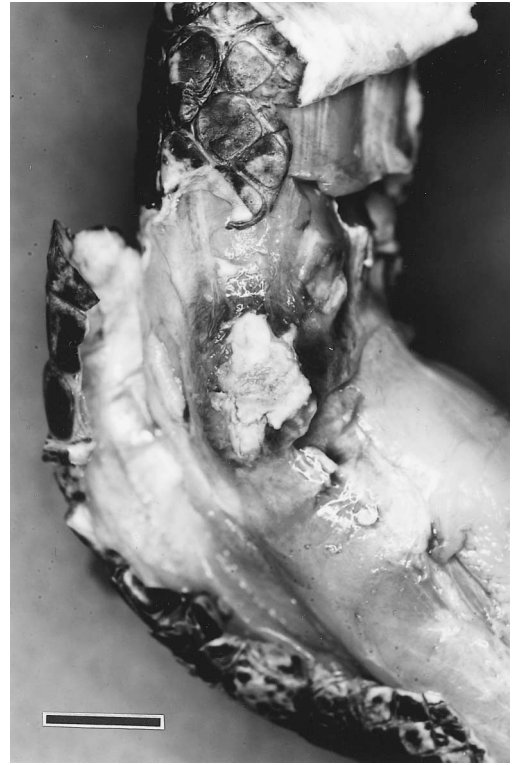

FIGURE 6. Subcutaneous edema and necrotizing synovitis of the elbow of an American alligator following inoculation with  $1 \times 10^6$  CFU of *Mycoplasma alligatoris*. Bar = 3 cm.

exported from the U.S. for commercial production. Once the mycoplasma enters one production facility, there may be significant potential for spread of *M. alligatoris* among ranches with associated economic risk. Alligator ranching is based on collection of eggs and hatchlings from the wild. For that reason, some wild populations are intermittently replenished with juvenile alligators repatriated after “head-starting” hatchlings from eggs collected in the wild. That practice could provide a vector for *M. alligatoris* transmission from captive alligators of diverse origins to local wild populations. Potential spread of mycoplasmosis might now be prevented by appropriate screening by mycoplasma culture or serology.

Because seroconversion in reptiles usually takes 6 to 8 wk (Lerch et al., 1967; Schumacher et al., 1993), an acutely lethal

pathogen such as *M. alligatoris* may escape serological detection at necropsy of alligators that die abruptly. Testing of paired plasma samples, obtained at least 8 wk apart, would be necessary to minimize the risk of false negative ELISA results. Any ELISA result should be interpreted in the context of age, sex, and seasonal effects on reptile immune competence (Zapata et al., 1992), which may also influence susceptibility to and severity of infectious diseases. However, *M. alligatoris* should be easily culturable on SP4 medium from blood or minced tissue samples of infected alligators that die abruptly. Alligators which were exposed to  $10^6$  CFU of *M. alligatoris* but did not develop clinical disease had seroconverted and seemed to have cleared the mycoplasma infection by 12 wk after exposure, suggesting that seropositive sta-



tus indicated past exposure but not necessarily current infection.

Although *A. hydrophila* and Gram-negative enteric bacteria have been implicated in septicemia of crocodilians (Novak and Seigel, 1986), *A. hydrophila* has also been cultured with high frequency from internal tissues of healthy alligators (Gorden et al., 1979). There was no evidence that secondary infections were responsible for the pathologic effects observed in the present study, and *M. alligatoris* may be retrospectively considered as a possible etiology of alligator deaths without apparent cause formerly attributed to *A. hydrophila* infection (Gorden et al., 1979). *Sebekia mississippiensis* and *D. waltoni* are also normally found in healthy alligators (Hazen et al., 1978).

One other mycoplasmal disease of crocodilians has been described. Polyarthrititis in young Nile crocodiles (*Crocodylus niloticus*) ranched in Zimbabwe was caused by *Mycoplasma crocodyli* (Mohan et al., 1995; Kirchhoff et al., 1997). Although *M. crocodyli* and *M. alligatoris* are very closely related, as indicated by 98% 16S rRNA gene nucleotide sequence similarity (D. R. Brown et al., unpubl. data), even intracoelomic or intrapleural inoculation with  $10^9$  CFU of *M. crocodyli* into Nile crocodiles was not fatal (Mohan et al., 1997). In an experimental inoculation host-range study, conducted concurrently with the present study described above, broad-nosed caiman (*Caiman latirostris*), which are phylogenetically close relatives of alligators, were similarly susceptible to lethal *M. alligatoris* infection, while phylogenetically distant Siamese crocodiles (*Crocodylus siamensis*) became colonized by the mycoplasma but did not experience disease (G. W. Pye, unpubl. data). That finding may have relevance to the yet unidentified reservoir of the 1995 epidemic, which occurred in a collection that included all 23 crocodilian species.

#### ACKNOWLEDGMENTS

This work was supported by U.S. Department of Agriculture NRICGP grant 9802614,

Morris Animal Foundation grant 98ZO-44, and contributions from the St. Augustine Alligator Farm and Zoological Park. Technical assistance by D. Duke and B. Crenshaw is gratefully acknowledged. Published as University of Florida College of Veterinary Medicine Journal Series No. 591.

#### LITERATURE CITED

- BROWN, D. R., T. L. CLIPPINGER, K. E. HELMICK, I. M. SCHUMACHER, R. A. BENNETT, C. M. JOHNSON, K. A. VLIET, E. R. JACOBSON, AND M. B. BROWN. 1996. Mycoplasma isolation during a fatal epizootic of captive alligators (*Alligator mississippiensis*) in Florida. *International Organization of Mycoplasma Letters* 4: 42–43.
- , J. M. FARLEY, L. A. ZACHER, J. M.-R. CARLTON, T. L. CLIPPINGER, J. G. TULLY, AND M. B. BROWN. 2001a. *Mycoplasma alligatoris* sp. nov., from American alligators. *International Journal of Systematic and Evolutionary Microbiology* 51: 419–424.
- , I. M. SCHUMACHER, M. F. NOGUEIRA, L. J. RICHEY, L. A. ZACHER, T. R. SCHOEK, K. A. VLIET, R. A. BENNETT, E. R. JACOBSON, AND M. B. BROWN. 2001b. Detection of antibodies to a pathogenic mycoplasma in American alligators (*Alligator mississippiensis*), broad-nosed caimans (*Caiman latirostris*), and Siamese crocodiles (*Crocodylus siamensis*). *Journal of Clinical Microbiology* 39: 285–292.
- CLIPPINGER, T. L., R. A. BENNETT, C. M. JOHNSON, K. A. VLIET, S. L. DEEM, J. OROS, E. R. JACOBSON, I. M. SCHUMACHER, D. R. BROWN, AND M. B. BROWN. 2001. Morbidity and mortality associated with a new mycoplasma species from captive American alligators (*Alligator mississippiensis*). *Journal of Zoo and Wildlife Medicine* 31: 303–314.
- GORDEN, R. W., T. TC. HAZEN, G. W. ESCH, AND C. B. FLIERMANS. 1979. Isolation of *Aeromonas hydrophila* from the American alligator, *Alligator mississippiensis*. *Journal of Wildlife Diseases* 15: 239–243.
- HAZEN, T. C., J. M. AHO, T. M. MURPHY, G. W. ESCH, AND G. D. SCHMIDT. 1978. The parasite fauna of the American alligator (*Alligator mississippiensis*) in South Carolina. *Journal of Wildlife Diseases* 14: 435–439.
- KIRCHHOFF, H., K. MOHAN, R. SCHMIDT, M. RUNGE, D. R. BROWN, M. B. BROWN, C. M. FOGGIN, P. MUVAVARIRWA, H. LEHMANN, AND J. FLOSSDORF. 1997. *Mycoplasma crocodyli* sp. nov., a new species from crocodiles. *International Journal of Systematic Bacteriology* 47: 742–746.
- LANE, T. J., AND F. W. KING. 1996. Alligator production in Florida. Florida Cooperative Extension Service Publication VM-52, University of

- Florida Institute of Food and Agricultural Science, Gainesville, Florida, 3 pp.
- LERCH, E. G., S. E. HUGGINS, AND A. H. BARTEL. 1967. Comparative immunology. Active immunization of young alligators with hemocyanin. *Proceedings of the Society for Experimental Biology and Medicine* 124: 448–451.
- LOUISIANA COOPERATIVE EXTENSION SERVICE. 2000. Louisiana summary of agriculture and natural resources. Louisiana State University Agricultural Center, Baton Rouge, Louisiana.
- LUNA, L. G. (ED.). 1968. *Manual of histologic staining methods of the Armed Forces Institute of Pathology*. McGraw-Hill, New York, New York, 258 pp.
- MOHAN, K., C. M. FOGGIN, P. MUVAVARIRWA, J. HONYWILL, AND A. PAWANDIWA. 1995. Mycoplasma-associated polyarthritis in farmed crocodiles (*Crocodylus niloticus*) in Zimbabwe. *Onderstepoort Journal of Veterinary Research* 62: 45–49.
- , ———, ———, AND ———. 1997. Vaccination of farmed crocodiles (*Crocodylus niloticus*) against *Mycoplasma crocodyli* infection. *The Veterinary Record* 141: 476.
- NOVAK, S. S., AND R. A. SEIGEL. 1986. Gram-negative septicemia in American alligators (*Alligator mississippiensis*). *Journal of Wildlife Diseases* 22: 484–487.
- SCHUMACHER, I. M., M. B. BROWN, E. R. JACOBSON, B. R. COLLINS, AND P. A. KLEIN. 1993. Detection of antibodies to a pathogenic mycoplasma in desert tortoises (*Gopherus agassizii*) with upper respiratory tract disease. *Journal of Clinical Microbiology* 31: 1454–1460.
- SHEEHAN, D. C., AND B. B. HRAPCHAK. 1980. *Theory and practice of histotechnology*. Mosby, St. Louis, Missouri, 481 pp.
- TULLY, J. G. 1995. Culture medium formulation for primary isolation and maintenance of mollicutes. *In* *Molecular and diagnostic procedures in mycoplasma*, Vol. 1, S. Razin and J. G. Tully (eds.). Academic Press, San Diego, California, pp. 33–39.
- ZAPATA, A. G., A. VARAS, AND M. TORROBA. 1992. Seasonal variations in the immune system of lower vertebrates. *Immunology Today* 13: 142–147.

*Received for publication 15 July 2000.*