

## **European Brown Hare Syndrome in Free-ranging European Brown and Mountain Hares from Switzerland**

Authors: Frölich, Kai, Haerer, Gunther, Bacciarini, Luca, Janovsky, Martin, Rudolph, Michael, et al.

Source: Journal of Wildlife Diseases, 37(4) : 803-807

Published By: Wildlife Disease Association

URL: <https://doi.org/10.7589/0090-3558-37.4.803>

---

BioOne Complete ([complete.BioOne.org](https://complete.BioOne.org)) is a full-text database of 200 subscribed and open-access titles in the biological, ecological, and environmental sciences published by nonprofit societies, associations, museums, institutions, and presses.

Your use of this PDF, the BioOne Complete website, and all posted and associated content indicates your acceptance of BioOne's Terms of Use, available at [www.bioone.org/terms-of-use](https://www.bioone.org/terms-of-use).

Usage of BioOne Complete content is strictly limited to personal, educational, and non - commercial use. Commercial inquiries or rights and permissions requests should be directed to the individual publisher as copyright holder.

---

BioOne sees sustainable scholarly publishing as an inherently collaborative enterprise connecting authors, nonprofit publishers, academic institutions, research libraries, and research funders in the common goal of maximizing access to critical research.

## European Brown Hare Syndrome in Free-ranging European Brown and Mountain Hares from Switzerland

Kai Frölich,<sup>1,4</sup> Gunther Haerer,<sup>2</sup> Luca Bacciarini,<sup>2</sup> Martin Janovsky,<sup>2</sup> Michael Rudolph,<sup>1</sup> and Marco Giacometti<sup>3</sup> <sup>1</sup>Institute for Zoo and Wildlife Research Berlin, Alfred-Kowalke-Strasse 17, P.O. Box 601103, 10252 Berlin, Germany; <sup>2</sup>Center of Fish and Wildlife Health, Institute of Animal Pathology, University of Berne, Länggass-Strasse 122, 3012 Berne, Switzerland; <sup>3</sup>Wildvet Projects, CH-7605 Stampa, Switzerland; <sup>4</sup>Corresponding author (e-mail: froelich@izw-berlin.de).

**ABSTRACT:** From 1997 to 2000, complete necropsy and histopathologic investigations were performed on 157 free-ranging European brown hares (*Lepus europaeus*) found dead throughout Switzerland. Organ samples of all these individuals (157 livers and 107 spleens available) were tested for European brown hare syndrome virus (EBHSV)-antigen by enzyme-linked immunosorbent assay (ELISA) test kit. Furthermore, 60 additional blood samples were tested for antibodies against EBHSV by ELISA. In addition, liver samples of 87 free-ranging mountain hares (*Lepus timidus*) hunted in 1996 were tested for EBHSV-antigen. In two European brown hares from southern Switzerland lesions suggestive of changes induced by EBHSV were present, and high titers of EBHSV-antigen were detected in both liver and spleen samples of these animals. Based on negative staining electron microscopy investigations of liver and spleen homogenates, we observed calicivirus in one antigen-positive hare. Low EBHSV-antigen titers were found in three additional European brown hares from central and western Switzerland, but EBHS-lesions were absent. Antibodies against EBHSV were not detected in any of the sera of European brown hares, and EBHSV-antigen was not found in the samples of mountain hares. This is the first report of EBHS in European brown hares from Switzerland.

**Key words:** Calicivirus, European brown hare syndrome, *Lepus europaeus*, *Lepus timidus*, pathology, serological survey.

In 1989, Lavazza and Vecchi (1989) found viral particles in European brown hares (*Lepus europaeus*) which had died from European brown hare syndrome (EBHS) by negative staining immune electron microscopy of the liver. The causative agent of EBHS is a small (30 to 35 nm) icosahedral, non-enveloped and hemagglutinating virus (Gavier-Widen and Mörner, 1991) and is classified as a calicivirus (Ohlinger and Thiel, 1991). Caliciviruses are spread by oral and nasal transmission (Xu

and Chen, 1989). In the field, the fecal-oral route of transmission is probably the most important one (Morisse et al., 1991). European brown hare syndrome has been demonstrated in European brown hares and in mountain hares (*Lepus timidus*), and has been reported in many European countries (Morisse, 1988; Eskens and Volmer, 1989; Marcato et al., 1989; Henriksen et al., 1989; Okerman et al., 1989; Chasey and Duff, 1990; Sostaric et al., 1991; Gavier-Widen and Mörner, 1993; Salmela et al., 1993; Steineck and Nowotny, 1993; Nauwynck et al., 1993; Gortazar and de Luco, 1995; Frölich et al., 1996; Slamecka et al., 1997). However, until now neither EBHSV-antigen nor corresponding pathology has been found in lagomorphs in Switzerland. Only one report exists for antibodies against caliciviruses in European brown hares in this country (Büttner, 1996). Our objective was to determine whether free-ranging European brown hares and mountain hares were naturally infected by EBHSV in Switzerland.

We collected 157 carcasses of European brown hares found dead all over Switzerland (45°49' to 47°49'N, 5°57' to 10°30'E) between 1997 and 2000. Geographical distribution of the samples is shown in Figure 1. European brown hares were sent to the Institute of Animal Pathology (University of Berne, Berne, Switzerland) by state game keepers and necropsied following standard protocols (Roffe et al., 1996). Selected organs (lung, heart, liver, spleen, kidney, and testicle or uterus) as well as organs showing apparent lesions were collected from all 157 animals, fixed in 4% phosphate-buffered formalin (pH 7.4), and embedded in paraffin. Histological

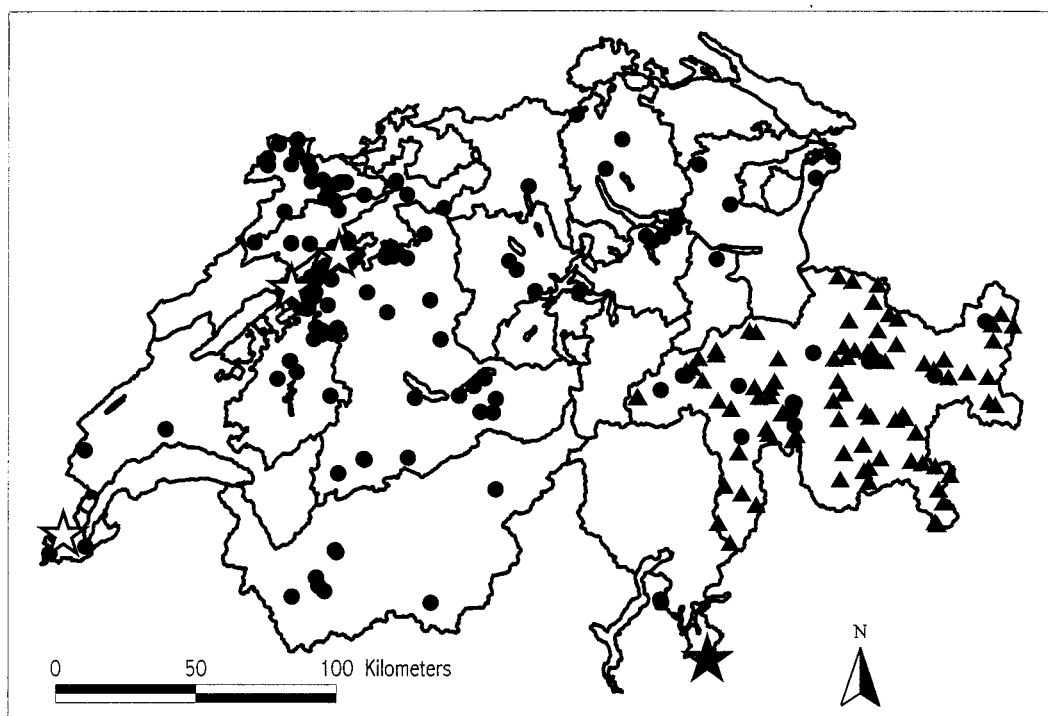


FIGURE 1. Geographical distribution of hares sampled in Switzerland in 1997–2000. Triangles and circles represent EBHS-antigen negative mountain hares and European brown hares, respectively. Low titer antigen positive European brown hares are indicated by white stars, while high antigen positive European brown hares with EBHS lesions are indicated by a black star.

sections of 4 to 6  $\mu\text{m}$  were cut and stained with hematoxylin and eosin. Lesions considered to be suggestive of EBHS were predominant periportal necrosis and degeneration of the hepatocytes characterized by single, group, and mass cell necrosis, and karyorrhexis, karyolysis, or karyopyknosis with scattered foci of lymphohistiocytic infiltrates (Capucci et al., 1991; Marcato et al., 1991). Tissue of 27 decomposed brown hares (17%) was not used for histology. In addition, liver samples of 87 mountain hares hunted in Grisons (a Canton in the eastern Swiss Alps;  $46^{\circ}10'$  to  $47^{\circ}03'N$ ,  $8^{\circ}46'$  to  $10^{\circ}30'E$ ), were collected in October and November 1996. Mountain hares were culled by local hunters, and livers were sampled by state game keepers within 24 hr after death. In contrast to European brown hares, perished mountain hares could not be investigated because carcasses are generally not found in those

remote mountainous regions. Therefore, pathological investigations were not conducted in mountain hares.

Virological analyses were performed on organ samples from all European brown hares (157 livers and 107 available spleens), on 60 blood samples available from the same species and on liver samples from 87 mountain hares. Blood was collected and centrifuged, and sera were stored at  $-20^{\circ}\text{C}$ . Liver and spleen samples were tested for EBHSV-antigen, while sera were tested for specific antibodies against EBHSV. For antigen demonstration and serological tests, we used EBHSV-antigen and antibody-blocking ELISA test kits according to the prescription of Frölich et al. (1996). Briefly, the EBHSV antigen ELISA microplates (Maxisorp, Nunc-Roskilde, Denmark) were coated with rabbit anti-EBHSV immunoglobulin G (IgG), washed, and the super-

natant from the test material or dilutions thereof were analyzed as quadruplicates. European brown hare syndrome virus-positive (Bundesforschungsanstalt für Viruskrankheiten, Tübingen, Germany) and negative control samples (Institut für Versuchstierkunde, Berlin, Germany) were included. Following an incubation period overnight at 5 °C and a washing step, immunosorbent treated guinea-pig anti EBHSV hyperimmune serum was added to two of the wells, and the same concentration of normal guinea-pig serum to the other two wells per test sample. Following another incubation period of 30 min at 37 °C and another washing procedure, the wells were further incubated with rabbit anti-guinea-pig peroxidase conjugate (Denmark code P141, DAKO Diagnostik GmbH, Hamburg, Germany). After washing, the fixed enzymes reacted for 10 min with orthophenylene-diamine (OPD) substrate including perhydrol (Sigma-Chemie GmbH, Deisenhofen, Germany). The reaction was stopped with H<sub>2</sub>SO<sub>4</sub> and the results were read at 490 nm on a MTF 10 spectrophotometer (Wissenschaftlicher Gerätebau, Berlin, Germany). The mean optical density (OD) of the negative controls was calculated. Test samples that deviated significantly >3 standard deviation (SD) from the mean of the controls in a dilution of  $\geq 1:10$  were considered positive. In addition, all positive samples were repeated three times. Only samples that were positive in all repetitions were regarded EBHSV-antigen positive. European brown hare syndrome antibody ELISA is a modification of the antigen ELISA technique as described above was used for detection of blocking antibodies against EBHSV in a competitive assay. Briefly, 50  $\mu$ l of the 1:4 diluted serum sample was added to IgG anti-RHDV or IgG anti-EBHSV precoated wells, followed by 50  $\mu$ l of EBHSV-antigen suspension, giving an OD value of about 1,000 with negative serum. After incubation overnight at 5 °C, the previously described procedure for the antigen ELISA was followed. The mean OD

of the negative control sera was calculated. Sera that deviated < 3 SD from the mean of negative control sera in a dilution of  $\geq 1:10$  were considered antibody positive.

Liver and spleen specimens of EBHSV-antigen positive hares, frozen at -70 °C, were examined by electron microscopy using the negative staining technique (Gelderbloom and Özel, 1983). First, the homogenate was centrifuged at  $10,000 \times G$  for 15 min to eliminate the gross debris. Thereafter, the supernatant was centrifuged at  $135,000 \times G$  for 5 min and the sediment was placed on 400 mesh copper grids (Baltec, Walluf, Germany) covered with formvar film and coated with carbon (Plano, Marburg, Germany). Finally, the grids were negatively stained with 2% phosphotungstic acid (Serva, Heidelberg, Germany) pH 6.5 and checked by an EM 902 A electron microscope (Carl Zeiss, Oberkochen, Germany).

In two European brown hares from Ticino, a Canton in southern Switzerland (Fig. 1), lesions suggestive of changes induced by EBHSV were found on histologic examination. Major histologic lesions were restricted to the liver parenchyma and characterized by midzonal- and perilobular, large extensive to coalescing areas of coagulative and lytic necrosis and partial replacement of the parenchyma by erythrocytes. Additional lesions were characterized by multiple subendocardial hemorrhages and tubular nephrosis. Moreover, these two individuals showed high EBHSV-antigen titers. The two liver samples were positive up to a dilution of 1:1,000 and the two spleen samples were positive when diluted 1:10,000 and 1:1,000, respectively. Virus particles characteristic of calicivirus were found in liver and spleen homogenate in one of these high antigen-positive hares by negative staining electron microscopy. The icosahedral particles of 30–40 nm diameter were seen following high speed centrifugation, they occurred singly spaced. They were partially damaged during preparation, but most of them showed the char-

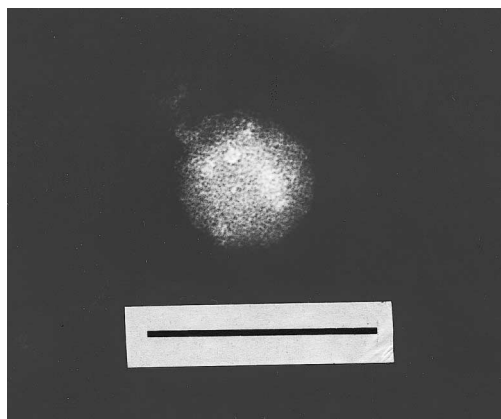


FIGURE 2. Electron micrograph of a negatively stained calicivirus (EBHSV) isolated after high speed centrifugation. Bar = 100 nm.

acteristic cup-like depressions of the surface (Fig. 2). In three additional European brown hares from central and western Switzerland, low EBHSV-antigen titers were found, but EBHS-lesions were absent. Sera were not available for two of these animals, and antibodies were not detected in the other. The three liver and the two spleen samples available were positive up to a dilution of 1:10. None of the 60 sera from European brown hares showed antibodies against EBHSV. In the mountain hares, EBHSV-antigen was not detected in any of the 87 liver samples.

Based on hepatic lesions and high positive antigen titers, EBHS was diagnosed in two European brown hares. The diagnosis of calicivirus was supported by negative staining electron microscopy. These viral particles morphologically resemble those observed by Poli et al. (1991) in spleen and liver of hare with acute hepatitis. This represents the first report of EBHS in Switzerland. Furthermore, three additional individuals showed low titers indicating a possible exposure to EBHSV. Two of these hares were killed by road traffic, the third one showed an infection with *Listeria monocytogenes* and was predated by a dog. Histologically, no lesions suggestive of changes induced by EBHSV were present. In these cases, (1) hares

could have been infected with a non or less pathogenic calicivirus strain, (2) infection was in an early viremic stage or (3) antigen detection (low titer of 1:10) may have been doubtful. In the Swiss mountain hare population, no evidence of EBHSV-infection was found. However, the results are not directly comparable, since in European brown hares necropsy, antigen demonstration, and serology were performed, whereas in mountain hares only liver samples were investigated for antigen detection. The two individuals showing EBHS originated from a region south of the Alps. This local subpopulation unit is part of the European brown hare metapopulation of northern Italy, where the disease is known to be widespread (Scicluna et al., 1994). The three individuals showing low EBHSV-antigen titers and no lesions suggestive of changes induced by EBHSV came from Swiss regions located north of the Alps. In this area, EBHS was not reported to cause losses until now. This may be due to (1) the relative isolation of hares due to the geomorphological characteristics of the country (in the South and East surrounded by the Alps, in the East and North by the river Rhine, and in the West surrounded by the Jura Mountains, all of which can be barriers to brown hare dispersal), (2) the low population density of brown hares in Switzerland (Büttner, 1996), and (3) the import of brown hares (which could be infected with EBHSV, Zanni et al., 1995) for release has been illegal for more than 10 yr in Switzerland.

In conclusion, this is the first report of EBHS in Switzerland. Furthermore, two distinct epidemiological situations may be present due to the existence of two separate European brown hare-metapopulations, one in the southern and one in the northern Alps.

#### LITERATURE CITED

- BÜTTNER, S. 1996. Gesundheitszustand der Feldhasen (*Lepus europaeus*) in der Schweiz. Thesis,



- Veterinary Medical University of Berne, Berne, Switzerland, 99 pp.
- CAPUCCI, L., M. T. SCICLUNA, AND A. LAVAZZA. 1991. Diagnosis of viral hemorrhagic disease of rabbits and the European brown hare syndrome. *Revue Scientifique et technique. Office International des Epizooties* 10: 347–370.
- CHASEY, D., AND P. DUFF. 1990. European brown hare syndrome and associated virus particles in the UK. *The Veterinary Record* 126: 623–624.
- ESKENS, U., AND K. VOLMER. 1989. Untersuchungen zur Ätiologie der Leberdystrophie des Feldhasen (*Lepus europaeus*, Pallas). *Deutsche Tierärztliche Wochenschrift* 96: 464–466.
- FRÖLICH, K., H. H. D. MEYER, Z. PIELOWSKI, L. RONSHOLT, S. V. SECK-LANZENDORF, AND M. STOLTE. 1996. European brown hare syndrome in free-ranging hares in Poland. *Journal of Wildlife Diseases* 32: 280–285.
- GAVIER-WIDEN, D., AND T. MÖRNER. 1991. Epidemiology and diagnosis of the European brown hare syndrome in Scandinavian countries. *Revue Scientifique et technique. Office International des Epizooties* 10: 453–458.
- , AND ———. 1993. Descriptive epizootiological study of European brown hare syndrome in Sweden. *Journal of Wildlife Diseases* 29: 15–20.
- GELDERBLUM, H., AND M. ÖZEL. 1983. Zur Virusdiagnostik mit dem Elektronenmikroskop. *Klein-tierpraxis* 28: 39–45.
- GORTAZAR, C., AND D. F. DE LUCO. 1995. La enfermedad hemorrágica de la liebre. *Trofeo* 295: 30–34.
- HENRIKSEN, P., D. GAVIER, AND F. ELLING. 1989. Acute necrotising hepatitis in Danish farmed hares. *The Veterinary Record* 125: 486–487.
- LAVAZZA, A., AND G. VECCHI. 1989. Osservazioni su alcuni episodi di mortalità nelle lepri. Evidenziazione al microscopio elettronico di una particella virale. *Nota preliminare. Selezione Veterinaria* 30: 461–467.
- MARCATO, P. S., C. BENAZZI, M. GALEOTTI, AND L. SALDA DELLA. 1989. Infective necrotic hepatitis of leporids. *Rivista di Coniglicultura* 26: 41–50.
- , G. VECCHI, M. GALEOTTI, L. DELLA SALDA, G. SARLI, AND P. LUCIDI. 1991. Clinical and pathological features of viral hemorrhagic disease of rabbits and the European brown hare syndrome. *Revue Scientifique et technique. Office International des Epizooties* 10: 371–390.
- MORISSE, J.-P. 1988. Hemorrhagic septicemia syndrome in rabbits: First observations in France. *Le Point Vétérinaire* 20: 79–83.
- , G. LE GALL, AND E. BOILLETOT. 1991. Hepatitis of viral origin in Leporidae: introduction and aetiological hypotheses. *Revue Scientifique et technique. Office International des Epizooties* 10: 283–295.
- NAUWYNCK, H., P. CALLEBAUT, J. PEETERS, R. DUCATTELE, AND E. UYTTEBROEK. 1993. Susceptibility of hares and rabbits to Belgian isolate of European brown hare syndrome virus. *Journal of Wildlife Diseases* 29: 203–208.
- OHLINGER, V. F., AND H. J. THIEL. 1991. Identification of the viral hemorrhagic disease virus of rabbits as a calicivirus. *Revue Scientifique et technique. Office International des Epizooties* 10: 311–323.
- OKERMAN, L., P. VAN DE KERCKHOVE, S. OSAER, L. DEVRIESE, AND E. UYTTEBROEK. 1989. European brown hare syndrome in captive hares (*Lepus capensis*) in Belgium. *Vlaams Diergeneeskundig Tijdschrift* 58: 44–46.
- POLI, A., M. NIGRO, D. GALLAZZI, G. SIRONI, A. LAVAZZA, AND D. GELMETTI. 1991. Acute hepatitis in the European brown hare (*Lepus europaeus*) in Italy. *Journal of Wildlife Diseases* 27: 621–629.
- ROFFE, T. J., M. FRIEND, AND L. N. LOCKE. 1996. Evaluation of causes of wildlife mortality. In *Research and management techniques for wildlife and habitats*, 5th Edition, revised, T. A. Bookhout (ed.). The Wildlife Society, Bethesda, Maryland, pp. 324–348.
- SALMELA, P., K. BELAK, AND D. GAVIER-WIDEN. 1993. The occurrence of European brown hare syndrome in Finland. *Acta Veterinaria Scandinavia* 34: 215–217.
- SCICLUNA, M. T., A. LAVAZZA, AND L. CAPUCCI. 1994. European brown hare syndrome in northern Italy: results of a virological and serological survey. *Revue Scientifique et technique. Office International des Epizooties* 13: 893–904.
- SLAMECKA, J., P. HELL, AND J. RATISLAV. 1997. Brown hare in the Westslovak lowland. *Acta Scientiarum Naturalium Academiae Scientiarum Bohemicae Brno* 31: 1–115.
- SOSTARIC, B., Z. LIPEJ, AND R. FUCHS. 1991. The disappearance of free living hares in Croatia: 1. European brown hare syndrome. *Veterinarski Arhiv* 61: 133–150.
- STEINECK, TH., AND N. NOWOTNY. 1993. European brown hare syndrome (EBHS) in Österreich: Epizootiologische Untersuchungen. *Tierärztliche Umschau* 48: 225–229.
- ZANNI, M. L., G. POGLAYEN, F. MARZADORI, M. C. BENASSI, L. CAPUCCI, E. CARPENÉ, M. FABBI, S. MAGNINO, S. TAGLIABUE, R. RODA, A. TASSELLI, R. SERRA, L. VENTURI, M. BARTOLUCCI, R. GALUPPI, AND A. LAVAZZA. 1995. Monitoraggio sanitario nella lepre (*Lepus europaeus* PALLAS) in Provincia di Ravenna. *Selezione Veterinaria* 36: 1–26.
- XU, Z. J., AND W. X. CHEN. 1989. Viral hemorrhagic disease in rabbits: A review. *Veterinary Research Communications* 13: 205–212.

Received for publication 28 June 2000.