

Fatal Spirochetosis Due to a Relapsing Fever-like Borreliasp. in a Northern Spotted Owl

Authors: Thomas, Nancy J., Bunikis, Jonas, Barbour, Alan G., and Wolcott, Mark J.

Source: Journal of Wildlife Diseases, 38(1) : 187-193

Published By: Wildlife Disease Association

URL: <https://doi.org/10.7589/0090-3558-38.1.187>

BioOne Complete (complete.BioOne.org) is a full-text database of 200 subscribed and open-access titles in the biological, ecological, and environmental sciences published by nonprofit societies, associations, museums, institutions, and presses.

Your use of this PDF, the BioOne Complete website, and all posted and associated content indicates your acceptance of BioOne's Terms of Use, available at www.bioone.org/terms-of-use.

Usage of BioOne Complete content is strictly limited to personal, educational, and non - commercial use. Commercial inquiries or rights and permissions requests should be directed to the individual publisher as copyright holder.

BioOne sees sustainable scholarly publishing as an inherently collaborative enterprise connecting authors, nonprofit publishers, academic institutions, research libraries, and research funders in the common goal of maximizing access to critical research.

Fatal Spirochetosis Due to a Relapsing Fever-like *Borrelia* sp. in a Northern Spotted Owl

Nancy J. Thomas,^{1,3} Jonas Bunikis,² Alan G. Barbour,² and Mark J. Wolcott,¹ ¹ U.S. Geological Survey, National Wildlife Health Center, 6006 Schroeder Road, Madison, Wisconsin 53711, USA; ² Departments of Microbiology and Molecular Genetics and Medicine, University of California, Irvine, California 92697-4025, USA; ³ Corresponding author (e-mail: nancy_thomas@usgs.gov)

ABSTRACT: Acute septicemic spirochetosis was diagnosed in an adult male northern spotted owl (*Strix occidentalis caurina*) found dead in Kittitas County, Washington, USA. Gross necropsy findings included marked enlargement of the liver and spleen and serofibrinous deposits on the serous membranes lining the body cavities and the pericardial and perihepatic sacs. Microscopic observations included macrophage infiltration in the liver and spleen with mild thrombosis and multifocal necrosis, as well as hemorrhage and acute inflammation in the choroid plexus of the brain. No viruses or pathogenic bacteria were isolated from brain, liver, or spleen, and no parasites were found in blood smears or impression smears of the liver. Chlamydial culture attempts were unsuccessful and no chlamydial antibodies were detected in serum. In silver-stained microscopic sections and by transmission electron microscopy of liver, numerous long, thin, spiral-shaped bacteria were seen in the liver, spleen, cerebral ventricles, and within blood vessels in many organs. The organism was identified as a member of the *Borrelia* genus by sequence analysis of the PCR-amplified 16S rRNA gene. The most closely related species is *B. hermsii*, an agent of relapsing fever in humans in the western United States. This is the first report of a relapsing fever-related *Borrelia* in a wild bird.

Key words: Avian, bird, *Borrelia hermsii*, case report, disease, northern spotted owl, pathology, relapsing fever, spirochete, *Strix occidentalis caurina*.

The northern spotted owl (*Strix occidentalis caurina*) is a nonmigratory, medium-sized owl that inhabits coniferous forests in the mountains of the Pacific Northwest USA and southwestern British Columbia, Canada (Gutiérrez, 1996). Conservation of the northern spotted owl has been a highly contentious issue between environmentalists and the timber industry because of this species' association with late-succession forests. Habitat loss and a declining population prompted

the U.S. to list the northern spotted owl as threatened under the Endangered Species Act in 1990.

Public attention for the past 20 yr has resulted in extensive studies into many aspects of the owl's natural history and demographics. Information about the causes of mortality makes important contributions to these studies. The primary causes of death cited for northern spotted owls are starvation, predation by great horned owls (*Bubo virginianus*) and goshawks (*Accipiter gentilis*), and accidental collisions (Gutiérrez, 1996). These causes are similarly reflected in National Wildlife Health Center (NWHC; Madison, Wisconsin, USA) diagnostic data that documented the causes of death for 75 free-flying northern spotted owls since 1986 (53% emaciation from unknown cause, 17% traumatic injuries, 12% undetermined causes, 11% miscellaneous causes, 4% disease, and 3% suspected intoxication; NWHC unpubl. data). Deaths due to infectious disease were rare in these data, but here we describe the case of a northern spotted owl that succumbed to infection by an unusual spirochete.

An adult male northern spotted owl was found dead in Kittitas County (Washington, USA) on 5 August 1994. The bird had been observed behaving normally during radiotelemetry studies 2 wk earlier. The carcass was shipped chilled by overnight commercial carrier to the NWHC for necropsy. On gross examination, the owl had striking enlargement of the liver and spleen. The liver had rounded margins and was brown with a distinct pale reticular pattern visible on the capsular and cut surfaces. The elongate spleen was pale, mot-

tled, and 3×1.2 cm. Clear yellow fibrinous deposits coated serous membranes in the body cavities, clung to the splenic capsule, and were accumulated in the perihepatic sacs. Clear yellow serofibrinous exudate filled the pericardial sac. The bird was in fair body condition and weighed 490 g.

Samples of brain, heart, lung, trachea, kidney, liver, spleen, pancreas, and intestine were fixed in 10% buffered formalin, paraffin embedded, sectioned at 5 μ m, and stained with hematoxylin and eosin for light microscopy. Liver and spleen sections were stained with Ziehl-Nielsen acid fast, Taylor's gram, modified Gimenez, and Gomori's iron stain, and kidney sections were stained with Gomori's iron and Ralph's stain for hemoglobin (Luna, 1968; Andersen, 1998). By light microscopy, the pale reticular pattern in the liver appeared as bridges of fatty degeneration between portal regions, along with accumulations of periportal macrophages and granulocytes. The predominate microscopic feature of the spleen was hyperplasia of macrophages, reticular cells, and plasma cells along with diminution of the lymphoid follicles. Occasional fibrin thrombi and foci of coagulative necrosis were noted in the liver and spleen. The choroid plexus of the third ventricle in the brain had acute hemorrhage and granulocyte infiltration and the lateral ventricles were mildly distended by proteinaceous fluid (Fig. 1). Mild heterophilic meningitis was concentrated near the cerebellum. The heart had only mild vascular-oriented pericarditis and superficial myocarditis. Mild renal tubular cast formation and bright red granules that did not stain as hemosiderin or hemoglobin in the proximal renal tubular epithelium suggested proteinuria.

Bacterial isolations from brain, liver, and spleen were attempted using routine culture techniques incorporating 5% sheep blood agar and eosin methylene blue agar (Remel, Lenexa, Kansas, USA) and in a *Salmonella*-selective culture method using both Hektoen-Enteric Agar (Remel) and

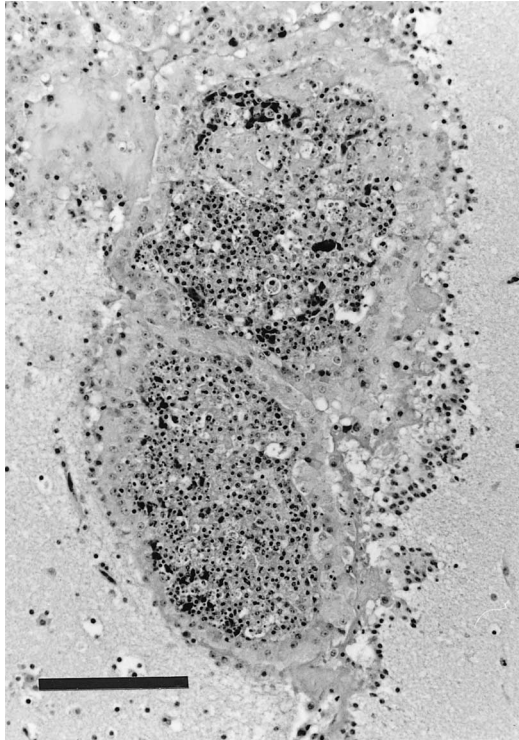


FIGURE 1. Choroid plexus in the brain of a northern spotted owl. The stroma is distended by inflammatory cells and fibrin. HE. Bar = 125 μ m.

XLT4 Agar (Difco Laboratories, Detroit, Michigan, USA) after enrichment in Dulcitol-Selenite Broth (NWHC). No bacteria were isolated from brain or liver and an *Enterococcus* sp. isolated from spleen was considered to be a postmortem contaminant. Brain, liver, and spleen were negative for viruses following culture in embryonated chicken eggs and muscovy duck embryo fibroblasts (Docherty and Slota, 1988; Senne, 1998). *Chlamydia psittaci* was not isolated from brain, liver, and spleen at the US Department of Agriculture (USDA) National Veterinary Services Laboratory (Ames, Iowa, USA). Serum collected from clotted blood in the heart was negative for antibody to *C. psittaci* by the latex agglutination test at the Texas Veterinary Medical Diagnostic Laboratory (College Station, Texas, USA). No parasites were found on gross examination, in squash preparations of liver, lung, and kid-

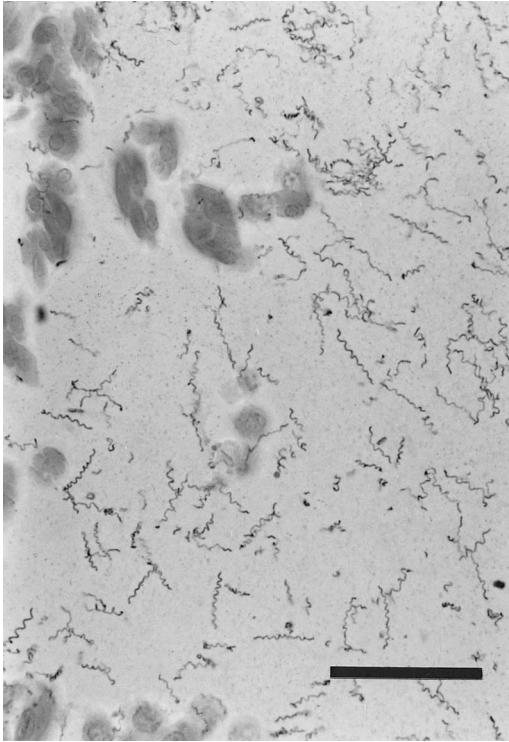


FIGURE 2. Numerous spirochetes in the lumen of an hepatic vein of a northern spotted owl. Steiner stain. Bar = 25 μm .

ney, or in Giemsa-stained (Garcia and Bruckner, 1993) blood smears. Unidentified unsporulated coccidial oocysts and *Capillaria* sp. detected in scrapings of the gastrointestinal mucosa were considered incidental.

When a modified Steiner's silver stain for spirochetes (Garvey et al., 1985) was applied to tissue sections numerous long, thin, spiral bacteria were visible in blood vessels throughout the body (Fig. 2) and were accumulated in the cerebral lateral and third ventricles. Spirochetes were lying in tangles in the hepatic sinusoids and were scattered throughout the splenic parenchyma. Spirochetes were occasionally present in renal tubules but were infrequent there in comparison with the renal glomerular and interstitial blood vessels. For comparison, liver sections from 13 northern spotted owls that died in Kittitas County (Washington, USA) ($n = 6$) or

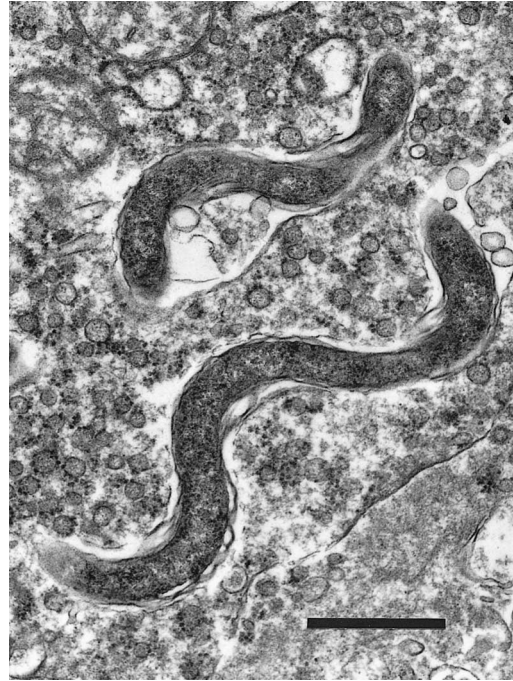

FIGURE 3. Transmission electron micrograph of two spirochetes in the space of Disse in the northern spotted owl's liver. Bar = 1 μm .

Oregon (USA) ($n = 7$) were similarly stained, and contained no visible spirochetes. The 13 owls had been previously diagnosed as traumatic deaths, handling accidents, or emaciated.

Giemsa-stained impression smears of liver contained faintly staining spirochetes. By transmission electron microscopy of Karnovsky-fixed liver, post-fixed with 1% osmium tetroxide and stained with 2% uranyl acetate before embedding in Epon Araldite and ultra-thin sectioning, multiple spiral bacteria, with a wavelength of approximately 1.9 μm and diameter of approximately 0.25 μm , were seen in hepatic sinusoids (Fig. 3).

Retrospective attempts to culture the spirochete from tissue samples that had been stored frozen at -70°C were unsuccessful. Samples of brain, liver, spleen, and clotted blood were inoculated into BSK-H supplemented with 10% rabbit serum (Sigma, St. Louis, Missouri, USA) and incubated at 37°C with 5–6% CO_2 . A portion

TABLE 1. Percent identity between DNA sequences of 16S rRNA genes of the owl spirochete and selected *Borrelia* spp.

Species	Species								
	Bh	Bt	Bp	Bcr	Ba	Bco	Bl	Bbi	Bb ^a
Owl spirochete	99.6	99.1	99.0	98.9	98.8	98.4	98.0	96.4	96.3
<i>B. hermsii</i> (Bh)	100	99.3	99.2	99.0	98.5	98.7	98.1	96.6	96.5
<i>B. turicatae</i> (Bt)		100	99.9	99.2	98.8	98.9	98.4	96.7	96.6
<i>B. parkeri</i> (Bp)			100	99.1	98.7	98.8	98.4	96.7	96.7
<i>B. crocidurae</i> (Bcr)				100	98.8	98.9	98.1	96.4	96.5
<i>B. anserina</i> (Ba)					100	98.2	97.5	96.3	96.3
<i>B. coriaceae</i> (Bco)						100	98.3	96.4	96.2
<i>B. lonestari</i> (Bl)							100	96.0	95.8
<i>B. bissettii</i> (Bbi)								100	99.6

^a *B. burgdorferi* sensu stricto.

of the culture was examined for spirochetes periodically using phase-contrast microscopy. Cultures were subcultured one time at day 4, and both culture sets were considered negative for spirochetes after 4 wk. The culture attempt was repeated by inoculating the same tissue samples into BSK II medium (Barbour, 1984) and incubating at 34 C, but there was no spirochete growth after 3 wk.

The spirochete was identified in frozen liver tissue using polymerase chain reaction (PCR) and sequence analysis of the 16S rRNA gene. Total DNA from the liver specimen was obtained by using DNeasy Tissue Kit (QIAGEN Inc., Valencia, California, USA). Sequences of primers and PCR conditions for amplification of partial 16S rRNA gene of *Borrelia* species have been described previously (Barbour et al., 1996). The PCR product was purified by gel extraction (QIAquick Gel Extraction Kit, QIAGEN, Inc.), ligated into pCR2.1 vector (TA Cloning Kit, Invitrogen, Carlsbad, California), and transformed into *E. coli*. Both strands of the insert of the recombinant plasmid were sequenced. The following *Borrelia* spp. 16S rRNA gene sequences were used for comparison: *B. burgdorferi* sensu stricto (GenBank accession number M88329), *B. lonestari* (U23211), *B. anserina* (U42284), *B. turicatae* (U42299), *B. parkeri* (U42296), *B. coriaceae* (U42286), *B. hermsii* (U42292),

B. crocidurae (U42302), and *B. bissettii* (AJ224141). Multiple sequences were aligned with aid of the Higgins-Sharp routine using default values of the MacDNASIS Pro suite (version 3.6) of programs from Hitachi Software (San Bruno, California). Partial 16S rRNA sequence of the owl spirochete has been assigned GenBank (<http://www.ncbi.nlm.nih.gov/Genbank>) accession number AF116903.

The PCR using the owl liver DNA preparation as a template and a pair of primers specific for the 16S rRNA gene of *Borrelia* spp. produced an approximately 1300 bp fragment. This fragment was cloned, sequenced, and 1290 bp were compared with the analogous sequences of selected *Borrelia* spp. with exclusion of the primer target sequences from the analysis (Table 1). The 16S rRNA gene sequences of the owl spirochete was nearly identical at 99.6% to a strain of *B. hermsii*, an agent of relapsing fever in western United States and Canada. There was less similarity with sequences of other New World relapsing fever borrelias (*B. turicatae* and *B. parkeri*), an Old World relapsing fever species (*B. crocidurae*), the avian borreliosis agent (*B. anserina*), a species found in *Amblyomma americanum* ticks (*B. lonestari*) (Barbour et al., 1996), and two Lyme disease *Borrelia* complex species (*B. burgdorferi* and *B. bissettii*) of North America.

Avian spirochetosis, or borreliosis,

caused by *B. anserina*, is uncommon in the U.S., but outbreaks occasionally have been reported in poultry or captive gamebirds (Mathey and Siddle, 1955; Cooper and Bickford, 1993). The Lyme disease agent, *B. burgdorferi*, was isolated in surveys of clinically normal wild birds in the U.S., but has not been associated with morbidity or mortality in birds (Mather et al., 1989; Burgess et al., 1993; McLean et al., 1993; Bishop et al., 1994; Durden et al., 1997). Similarly, *B. garinii*, an agent of Lyme disease in Europe, was detected in wild seabirds and game birds, but is not considered an avian pathogen (Olsen et al., 1995; Kurtenbach et al., 1998). Other borreliac diseases in the U.S. are the tick-borne relapsing fevers of humans, caused by *B. turicatae* in the southwest and *B. hermsii* in the mountainous west (Barbour and Hayes, 1986). *Borrelia hermsii* is endemic in the Cascade mountain range in Washington where this northern spotted owl was found (Dworkin et al., 1998).

The lesions in this owl clearly indicated that the bird died from an acute to subacute, overwhelming infection. The lesions of typical avian spirochetosis due to *B. anserina* are similar to those seen in this owl and include hepatomegaly, splenomegaly, fibrinous polyserositis, thrombosis, necrosis, and vast numbers of circulating organisms (Cooper and Bickford, 1993). However, erythrophagocytosis and hemosiderosis that are common in avian spirochetosis were not evident here. The involvement of the choroid plexus in the northern spotted owl was somewhat unique and probably related to the vascularity of that tissue. No primary involvement of the brain was apparent and meningitis was very mild; however, the choroid plexus may be the site of entry of borrelias into the central nervous system (Cadavid and Barbour, 1998).

Proteinuria is difficult to confirm post-mortem but was suggested by the granules and casts in the owl's renal tubules. Proteinuria was reported in 46% of clinical human patients in Dworkin et al.'s (1998)

review of tick-borne relapsing fever in the northwestern U.S.; the mechanism is unknown but could result from mechanical injury to glomerular capillaries. The severe consequences of spirochete infection in this case suggest that the owl was an accidental host for this pathogen, rather than serving as a reservoir host in the organism's transmission cycle.

The source of the *Borrelia* sp. and means of exposure for the northern spotted owl are unknown. The principle vectors known to transmit borreliosis in the U.S. are ticks, specifically the soft-bodied *Argas* sp. and *Ornithodoros* sp. for avian spirochetosis and the relapsing fevers, respectively, and *Ixodes* sp. for Lyme disease. Mites and biting insects have also been implicated in mechanically transmitting avian spirochetosis (Barnes, 1997). Ectoparasites reported for the northern spotted owl are limited to lice and hippoboscids found on live-captured owls or museum specimens (Young et al., 1993; Hunter et al., 1994). These parasite survey methods are unlikely to detect nest-dwelling argasid ticks. Northern spotted owls are territorial and monogamous, utilizing either tree cavities or platforms, such as old raptor nests (Buchanan et al., 1993; Forsman and Giese, 1997). Nests are reused at a rate of 18–25% (Forsman and Giese, 1997), making a nest-associated transmission cycle conceivable. A more likely alternative, however, may be direct transmission by predation or through contact with secretions or excreta from an infected individual. Experimental transmission of relapsing fever infection to rats and dogs through consumption of brains of infected animals has been documented (Joyeux and Sautet, 1938; Horrenberger, 1955). Small rodents serve as reservoirs for the agents of the relapsing fevers and Lyme disease, and the principle prey of northern spotted owls are dusky-footed and bushy-tailed woodrats (*Neotoma fuscipes* and *N. cinerea*, respectively), northern flying squirrels (*Glaucomys sabrinus*), and red tree voles (*Phenacomys longicaudus*).

dus) (Forsman et al., 1984; Gutiérrez, 1996).

In a previous study chickens were successfully infected with *B. duttonii*, an agent of human relapsing fever in Africa, through direct inoculation (Kervan, 1947). In this case we have found the first evidence that fatal disease may be caused by a relapsing fever species of *Borrelia* in birds. Such cases could be prone to under-reporting because spirochetes are not readily detected using most routine avian diagnostic techniques. Techniques useful for diagnosis of suspected borreliosis include dark field microscopy of fresh, wet tissue preparations or spirochete-specific histochemical stains of fixed tissue.

The relationship between the owl *Borrelia* and agents of human disease is under further investigation. While any cause of mortality in an endangered or declining species may be of concern, the significance of this finding to the northern spotted owl and other species remains unclear until the source of the agent and means of transmission are better explained.

The authors sincerely thank D. Herter of Raedeke Associates for submitting the specimen for necropsy, S. Sovern and E. Forsman for field information, and the NWHC diagnostic laboratory staff for performing laboratory analyses for this case. The work was supported in part by a co-operative research agreement from the Centers for Disease Control and Prevention to A.G.B.

LITERATURE CITED

- ANDERSEN, A. A. 1998. Chlamydiosis. In A laboratory manual for the isolation and identification of avian pathogens, 4th Edition, D. E. Swayne, J. R. Glisson, M. W. Jackwood, J. E. Pearson and W. M. Reed (eds.). American Association of Avian Pathologists, Kennett Square, Pennsylvania, pp. 81–88.
- BARBOUR, A. G. 1984. Isolation and cultivation of Lyme disease spirochetes. *Yale Journal of Biology and Medicine* 57: 521–525.
- , AND S. F. HAYES. 1986. Biology of *Borrelia* species. *Microbiological Reviews* 50: 381–400.
- , G. O. MAUPIN, G. J. TELTOW, C. J. CARTER, AND J. PIESMAN. 1996. Identification of an uncultivable *Borrelia* species in the hard tick *Amblyomma americanum*: Possible agent of a Lyme disease-like illness. *Journal of Infectious Diseases* 173: 403–409.
- BARNES, H. J. 1997. Spirochetosis (borreliosis). In *Diseases of poultry*, 10th Edition, B. W. Calnek, H. J. Barnes, C. W. Beard, L. R. McDougald and Y. M. Saif (eds.). Iowa State University Press, Ames, Iowa, pp. 318–324.
- BISHOP, K. L., M. I. KHAN, AND S. W. NIELSEN. 1994. Experimental infection of northern bobwhite quail with *Borrelia burgdorferi*. *Journal of Wildlife Diseases* 30: 506–513.
- BUCHANAN, J. B., L. L. IRWIN, AND E. L. MCCUTCHEN. 1993. Characteristics of spotted owl nest trees in the Wenatchee National Forest. *Journal of Raptor Research* 27: 1–7.
- BURGESS, E. C., M. D. WACHAL, AND T. D. CLEVEN. 1993. *Borrelia burgdorferi* infection in dairy cows, rodents and birds from four Wisconsin dairy farms. *Veterinary Microbiology* 35: 61–77.
- CADAVID, D., AND A. G. BARBOUR. 1998. Neuroborreliosis during relapsing fever: Review of the clinical manifestations, pathology, and treatment of infections in humans and experimental animals. *Clinical Infectious Diseases* 26: 151–164.
- COOPER, G. L., AND A. A. BICKFORD. 1993. Spirochetosis in California game chickens. *Avian Diseases* 37: 1167–1171.
- DOCHERTY, D. E., AND P. G. SLOTA. 1988. Use of muscovy duck embryo fibroblasts for the isolation of viruses from wild birds. *Journal of Tissue Culture Methods* 11: 165–170.
- DURDEN, L. A., R. G. MCLEAN, J. H. OLIVER JR., S. R. UBICO, AND A. M. JAMES. 1997. Ticks, Lyme disease spirochetes, trypanosomes, and antibody to encephalitis viruses in wild birds from coastal Georgia and South Carolina. *Journal of Parasitology* 83: 1178–1182.
- DWORKIN, M. S., D. E. ANDERSON JR., T. G. SCHWAN, P. C. SHOEMAKER, S. N. BANERJEE, B. O. KASSEN, AND W. BURGDOFFER. 1998. Tick-borne relapsing fever in the northwestern United States and southwestern Canada. *Clinical Infectious Diseases* 26: 122–131.
- FORSMAN, E. D., AND A. R. GIESE. 1997. Nests of northern spotted owls on the Olympic Peninsula, Washington. *Wilson Bulletin* 109: 28–41.
- , E. C. MESLOW, AND H. M. WIGHT. 1984. Distribution and biology of the spotted owl in Oregon. *Wildlife Monographs* 87: 1–64.
- GARCIA, L. S., AND D. A. BRUCKNER. 1993. *Diagnostic medical parasitology*, 2nd Edition. American Society for Microbiology, Washington, D. C., p. 587.
- GARVEY, W., A. FATHI, AND F. BIGELOW. 1985. Modified Steiner's stain for demonstration of spirochetes. *Journal of Histotechnology* 8: 15–17.
- GUTIÉRREZ, R. J. 1996. Biology and distribution of the northern spotted owl. In *Demography of the*

- northern spotted owl, Studies in avian biology No. 17, E. D. Forsman, S. DeStefano, M. G. Raphael and R. J. Gutiérrez (eds.). Cooper Ornithological Society, Camarillo, California, pp. 2–5.
- HORRENBARGER, R. 1955. Transmission expérimentale de *Spirochaeta hispanica* au chien par morsure de rat. Comptes Rendu Societe Biologie 149: 1432–1444.
- HUNTER, J. E., R. J. GUTIÉRREZ, A. B. FRANKLIN, AND D. OLSON. 1994. Ectoparasites of the spotted owl. Journal of Raptor Research 28: 232–235.
- JOYEUX, C., AND J. SAUTET. 1938. Importance de la voie digestive pour la transmission du *Spirochaeta duttonii*. Bulletin Societe du Pathologie Exotique 31: 279–281.
- KERVAN, P. 1947. Recherches sur la sensibilité du poulet a *Spirochaeta duttonii*. Absence d'immunité contre *Spirochaeta gallinarum*. Bulletin Société du Pathologie Exotique 40: 152–155.
- KURTENBACH, K., M. PEACEY, S. G. RIJPKEMA, A. N. HOODLESS, P. A. NUTTALL, AND S. E. RANDOLPH. 1998. Differential transmission of the genospecies of *Borrelia burgdorferi* sensu lato by game birds and small rodents in England. Applied Environmental Microbiology 64: 1169–1174.
- LUNA, L. G. (ed.). 1968. Manual of histologic staining methods of the Armed Forces Institute of Pathology, 3rd Edition. McGraw Hill Book Company, New York, New York, 258 pp.
- MATHER, T. N., S. R. TELFORD III, A. B. MACLACHLAN, AND A. SPIELMAN. 1989. Incompetence of catbirds as reservoirs for the Lyme disease spirochete (*Borrelia burgdorferi*). Journal of Parasitology 75: 66–69.
- MATHEY, W. J. JR., AND P. J. SIDDLE. 1955. Spirochetosis in pheasants. Journal of the American Veterinary Medical Association 126: 123–126.
- MCLEAN, R. G., S. R. UBICO, C. A. NORTON HUGHES, S. M. ENGSTROM, AND R. C. JOHNSON. 1993. Isolation and characterization of *Borrelia burgdorferi* from blood of a bird captured in the Saint Croix River Valley. Journal of Clinical Microbiology 31: 2038–2043.
- OLSEN, B., D. C. DUFFY, T. G. JAENSON, A. GYLFE, J. BONNEDAHL, AND S. BERGSTROM. 1995. Transhemispheric exchange of Lyme disease spirochetes by seabirds. Journal of Clinical Microbiology 33: 3270–3274.
- SENNE, D. A. 1998. Virus propagation in embryonating eggs. In A laboratory manual for the isolation and identification of avian pathogens, D. E. Swayne, J. R. Glisson, M. W. Jackwood, J. E. Pearson and W. M. Reed (eds.). American Association of Avian Pathologists, Kennett Square, Pennsylvania, pp. 235–240.
- YOUNG, K. E., A. B. FRANKLIN, AND J. P. WARD. 1993. Infestation of northern spotted owls by hippoboscids (Diptera) flies in northwestern California. Journal of Wildlife Diseases 29: 278–283.

Received for publication 11 October 2000.