



Lymphosarcoma in a Sea Otter (*Enhydra lutris*)

Authors: Kim, J-H., Kim, B-H., Kim, J-H., Yoo, M-J., and Kim, D-Y.

Source: Journal of Wildlife Diseases, 38(3) : 616-617

Published By: Wildlife Disease Association

URL: <https://doi.org/10.7589/0090-3558-38.3.616>

BioOne Complete (complete.BioOne.org) is a full-text database of 200 subscribed and open-access titles in the biological, ecological, and environmental sciences published by nonprofit societies, associations, museums, institutions, and presses.

Your use of this PDF, the BioOne Complete website, and all posted and associated content indicates your acceptance of BioOne's Terms of Use, available at www.bioone.org/terms-of-use.

Usage of BioOne Complete content is strictly limited to personal, educational, and non - commercial use. Commercial inquiries or rights and permissions requests should be directed to the individual publisher as copyright holder.

BioOne sees sustainable scholarly publishing as an inherently collaborative enterprise connecting authors, nonprofit publishers, academic institutions, research libraries, and research funders in the common goal of maximizing access to critical research.

Lymphosarcoma in a Sea Otter (*Enhydra lutris*)

J.-H. Kim,¹ B.-H. Kim,² J.-H. Kim,² M.-J. Yoo,³ and D.-Y. Kim^{1,4} ¹National Veterinary Research and Quarantine Service, Anyang, Korea; ²Department of Veterinary Pathology, College of Veterinary Medicine and School of Agricultural Biotechnology, Seoul National University, Suwon, 441-744, Korea; ³Seoul Grand Park, Seoul, Korea; ⁴Corresponding author (email: daeyong@plaza.snu.ac.kr)

ABSTRACT: Lymphoblastic lymphosarcoma involving the mesenteric lymph node and thymus was discovered in a 4 yr old male sea otter (*Enhydra lutris*). Diagnosis was based on gross and light microscopic studies. The cause of this neoplasm was not determined. This is the first case of lymphosarcoma reported in sea otters.

Key words: Case report, *Enhydra lutris*, lymphosarcoma, otter.

Lymphosarcoma, a neoplastic proliferation of lymphocytes, is relatively common in many domestic and laboratory animal species (Jones et al., 1997). Among members Mustelidae, lymphosarcoma has been reported only in domestic ferrets (Erdman et al., 1992; Batchelder et al., 1996). Only a few cases of spontaneous neoplasia, which include malignant seminoma, malignant ovarian teratoma, and concurrent cholangiocellular carcinoma, leiomyoma, and pheochromocytoma, have been documented in otters (Stetzer et al., 1981; Zachary et al., 1981; Reimer et al., 1998). Here, we describe a case of lymphoblastic lymphosarcoma in a sea otter (*Enhydra lutris*), the first such case reported in this species.

The subject was a 4 yr old male sea otter raised at Seoul Grand Park, Korea. The animal was found dead after a few days of depression, vomiting, and anorexia. Shortly after its death, the otter was submitted to the Department of Veterinary Pathology, Seoul National University for postmortem examination.

On necropsy, the mesenteric lymph node was enlarged (10×5×5 cm). It was firm, tan, and bulged on cut section. Impression smears of the mesenteric lymph node revealed monomorphic round cells with minimal anisocytosis. The thymus was enlarged approximately three times normal size. Other superficial and deep lymph nodes and spleen were unremarkable. A

small amount of blood-tinged fluid was present in the abdominal cavity and mesenteric vessels were very distended. A 10 cm segment of the ileal wall was thickened due to congestion and edema.

Samples of mesenteric lymph node, thymus, lung, heart, liver, spleen, kidney, stomach, and small and large intestines were fixed in 10% phosphate-buffered formalin, routinely processed, and stained with hematoxylin and eosin for light microscopic examination.

Histologically, the mesenteric lymph node consisted of a compact sheet of lymphoblastic lymphocytes with a mild degree of anisocytosis, resulting in complete loss of normal tissue architecture (Fig. 1). Neoplastic cells had round hyperchromatic nuclei and a small amount of cytoplasm (Fig. 1). Frequency of mitotic figures was low (0–3 per high power field). Normal architecture of the thymus was obliterated by sheets of neoplastic cells similar to those

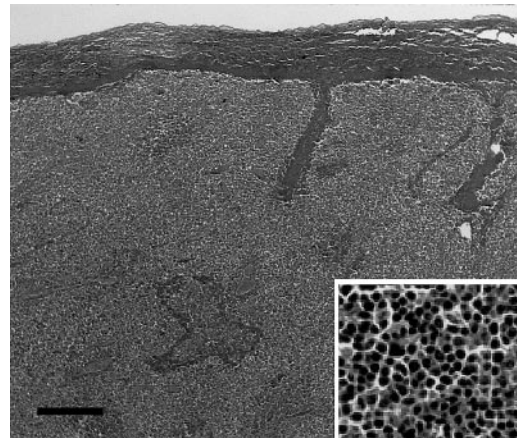


FIGURE 1. Lymphoblastic lymphosarcoma in the mesenteric lymph node of a sea otter. Note sheets of monomorphic lymphoblastic lymphocytes that have hyperchromatic nuclei and a small amount of cytoplasm (insert) HE. Bar=50 μ m.

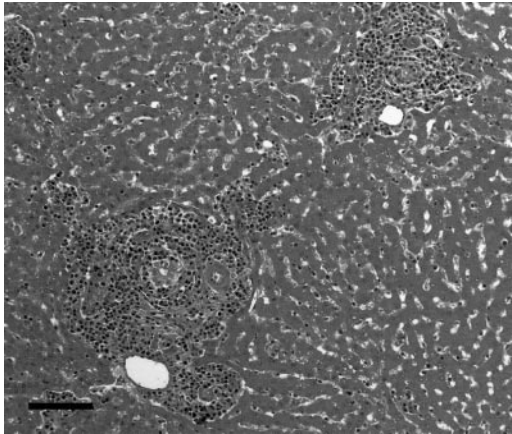


FIGURE 2. Lymphoblastic lymphosarcoma in the liver of a sea otter. Note infiltration of neoplastic cells in the portal area. HE. Bar=80 μ m.

seen in the mesenteric lymph node. Neoplastic infiltrate was noted in the portal areas and sinusoids of the liver (Fig. 2). No neoplastic infiltrates were found in other organs. Transmural necrosis, congestion, and edema were present in the ileum with minimal inflammatory response.

A diagnosis of lymphoblastic lymphosarcoma was made on the basis of gross findings, cytology, and light microscopic features. It is possible that an infarction in the ileum might have occurred secondary to constriction of the mesenteric vessels by the enlarged lymph node.

Cause of this neoplasm remains to be determined; the association of retroviruses, herpesviruses, and lymphoma has been well documented in animals (Jones et al., 1997). Viral immunosuppression or lymphostimulation was thought to facilitate development of malignant lymphoma in domestic ferrets (Kenyon and Williams, 1967). Recently, several cases of juvenile

mediastinal lymphoma were reported in ferrets (Batchelder et al., 1996). Lymphoblastic lymphosarcoma, which often is a T-cell neoplasm, is usually associated with thymic enlargement as seen in this case. Lymphosarcoma is rarely reported in Mustelidae, except for ferrets, and has not been previously reported in sea otters. Additional cases need to be documented to evaluate the biological behavior and prevalence of lymphosarcoma in otters.

This work was supported by the Brain Korea 21 project.

LITERATURE CITED

- BATCHELDER, M. A., S. E. ERDMAN, X. LI, AND J. G. FOX. 1996. A cluster of cases of juvenile mediastinal lymphoma in a ferret colony. *Laboratory Animal Science* 46: 271–274.
- ERDMAN, S. E., F. M. MOORE, R. ROSE, AND J. G. FOX. 1992. Malignant lymphoma in ferrets: Clinical and pathological findings in 19 cases. *Journal of Comparative Pathology* 106: 37–47.
- JONES, T. C., R. D. HUNT, AND N. W. KING. 1997. The hemic and lymphatic system. In *Veterinary pathology*, 6th Edition, T. C. Jones, R. D. Hunt and N. W. King (eds.). Williams and Wilkins, Baltimore, Maryland, pp. 1034–1042.
- KENYON, A. J., AND R. C. WILLIAMS. 1967. Lymphatic leukaemia associated with dysproteinemia in ferrets. *Nature* 214: 1022–1023.
- REIMER, D. C., AND T. P. LIPSCOMB. 1998. Malignant seminoma with metastasis and herpesvirus infection in a free-living sea otter (*Enhydra lutris*). *Journal of Zoo and Wildlife Medicine* 29: 35–39.
- STETZER, E., T. D. WILLIAMS, AND J. W. NIGHTINGALE. 1981. Cholangiocellular adenocarcinoma, leiomyoma, and pheochromocytoma in a sea otter. *Journal of the American Veterinary Medical Association* 179: 1283–1284.
- ZACHARY, J. F., AND S. C. McDONALD. 1981. Malignant ovarian teratoma in a spot-neck otter. *Journal of the American Veterinary Medical Association* 179: 1279–1283.

Received for publication 25 April 2001.