

## **CRYPTORCHIDISM IN FLORIDA PANTHERS: PREVALENCE, FEATURES, AND INFLUENCE OF GENETIC RESTORATION**

Authors: Mansfield, Kristin G., and Land, E. Darrell

Source: Journal of Wildlife Diseases, 38(4) : 693-698

Published By: Wildlife Disease Association

URL: <https://doi.org/10.7589/0090-3558-38.4.693>

---

BioOne Complete ([complete.BioOne.org](https://complete.BioOne.org)) is a full-text database of 200 subscribed and open-access titles in the biological, ecological, and environmental sciences published by nonprofit societies, associations, museums, institutions, and presses.

Your use of this PDF, the BioOne Complete website, and all posted and associated content indicates your acceptance of BioOne's Terms of Use, available at [www.bioone.org/terms-of-use](https://www.bioone.org/terms-of-use).

Usage of BioOne Complete content is strictly limited to personal, educational, and non - commercial use. Commercial inquiries or rights and permissions requests should be directed to the individual publisher as copyright holder.

---

BioOne sees sustainable scholarly publishing as an inherently collaborative enterprise connecting authors, nonprofit publishers, academic institutions, research libraries, and research funders in the common goal of maximizing access to critical research.

# CRYPTORCHIDISM IN FLORIDA PANTHERS: PREVALENCE, FEATURES, AND INFLUENCE OF GENETIC RESTORATION

Kristin G. Mansfield<sup>1,2</sup> and E. Darrell Land<sup>1,3</sup>

<sup>1</sup> Florida Fish and Wildlife Conservation Commission, 566 Commercial Boulevard, Naples, Florida 34104, USA

<sup>2</sup> Current address: Washington Department of Fish and Wildlife, 8702 N. Division Street, Spokane, Washington 99218-1199, USA

<sup>3</sup> Corresponding author (email: landd@fwc.state.fl.us)

**ABSTRACT:** The overall prevalence of cryptorchidism in Florida panthers (*Puma concolor coryi*) from 1972–2001 was 49% (24/49), with a significant increase over time. The earliest age at which descent of both testicles was known to occur was 2 mo and the latest was 10–13 mo. Delayed testicular descent was documented in 23% (8/35) of juveniles examined. Most retained testicles were in the inguinal canal. There was no apparent difference in reproductive success between cryptorchid and normal panthers, although no bilaterally cryptorchid panthers were known to have sired litters. Cryptorchidism was thought to be a manifestation of inbreeding and was one of several factors that led to the development of a genetic restoration plan whereby eight female puma from Texas were released into the panther population in 1995. None of the progeny resulting from genetic restoration efforts has been cryptorchid. This report provides evidence that cryptorchidism in panthers is genetically rather than environmentally based, and demonstrates the utility of genetic restoration for eliminating certain deleterious traits that result from inbreeding.

**Key words:** Cryptorchidism, endangered species, Florida panther, genetic restoration, inbreeding, pathology, *Puma concolor coryi*, reproduction.

## INTRODUCTION

The Florida panther (*Puma concolor coryi*) is a subspecies of puma that formerly intergraded with the eastern cougar (*P. concolor cougar*) to the north, *P. concolor hippolestes* to the northwest, and *P. concolor stanleyana* to the west (Young and Goldman, 1946). During the last century, unregulated killing and loss of habitat to human residential and agricultural development has restricted the Florida panther to an approximately 8,810 km<sup>2</sup> area in south Florida (Maehr, 1990) that supports at least 60–70 individuals (Land and Lacy, 2000). The eastern cougar is now extinct, and constriction of the Florida panther's range has resulted in a loss of dispersal opportunities and, thus, genetic exchange with remaining puma subspecies.

Small isolated populations are vulnerable to loss of genetic diversity, which may in turn lead to the fixation of certain alleles, inbreeding depression, loss of individual fitness, and ultimately extinction. There is evidence that this process is occurring in Florida panthers. Florida panthers have the lowest levels of genetic di-

versity of any subspecies of puma examined (O'Brien et al., 1990). This low genetic diversity is believed responsible for the high frequency of morphologic anomalies, including kinked tails, mid-dorsal whorls of the pelage (Wilkins et al., 1997), heart defects (Cunningham et al., 1999), and abnormal male reproductive traits (Barone et al., 1994). Among the abnormal male reproductive traits is a high prevalence of cryptorchidism, wherein one or both testicles fail to descend into the scrotum. The majority of cases are unilateral, but at least three males have remained bilaterally cryptorchid into adulthood. Since unilaterally cryptorchid animals may have reduced fertility (Kwakami et al., 1984) and bilaterally cryptorchid animals are functionally sterile, this could have obvious implications for the panther's ability to reproduce and therefore persist as a distinct subspecies in nature.

Concern for the genetic health and long-term viability of the Florida panther led to development of a genetic restoration plan to artificially restore gene flow that had historically occurred with another sub-

species of puma (Seal, 1994). Accordingly, in 1995 eight female pumas from Texas (*P. concolor stanleyana*) were released in south Florida to interbreed with Florida panthers. Since then, at least 15 male intercross kittens have been born and seven of these have survived their first year (Land and Lacy, 2000). Here we describe the prevalence, reproductive effects, and clinical features of cryptorchidism in Florida panthers and provide a preliminary report of the impact of genetic restoration on this trait.

### MATERIALS AND METHODS

From February 1972 to September 2001, 77 male Florida panthers  $\geq 1$  mo of age were examined in southern peninsular Florida (south of 27°00'N) by the Florida Fish and Wildlife Conservation Commission. Of these, 56 were live-captured on one or more occasions for radiocollaring, 15 were unmarked individuals killed by vehicles or illegally shot, five were removed from the wild as kittens for captive breeding purposes, and one was permanently placed in captivity as an adult after sustaining severe vehicular trauma.

Panthers  $\geq 5$  mo of age were live-captured and chemically immobilized as previously described (McCown et al., 1990; Roelke, 1990). Younger kittens were handled following Land et al. (1998) and implanted with subcutaneous transponder chips to facilitate later identification. Each captured panther received a complete physical examination, which included palpation of the scrotal and inguinal areas to detect the number of descended testicles. Age was estimated based on tooth color and wear, pelage characteristics, and size (Ashman et al., 1983). For some panthers, age was calculated based on the known denning dates of their radiocollared dams.

Radiocollared panthers were monitored from fixed-wing aircraft three times weekly, which enabled detection of male-female associations, subsequent periparturient behavior and den sites of females, and retrieval of carcasses when panthers died. Sires were assigned by back-dating from the birth date of litters to the time of probable conception and examining radiotelemetry data for evidence of males consorting with the dam during that time. Males that were documented as being with a female that subsequently gave birth after the appropriate gestation period were considered successful sires.

Carcasses that were suitable for postmortem examination were transported to the University

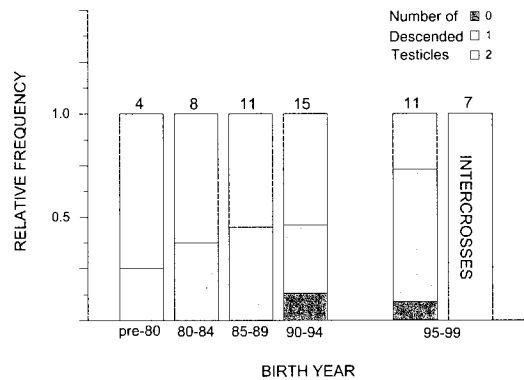


FIGURE 1. Prevalence of cryptorchidism in adult ( $\geq 24$  mo) Florida panthers born between 1971–99. Numbers above bars represent sample size.

of Florida Veterinary Medical Teaching Hospital (Gainesville, Florida, USA) for necropsy. During the necropsy, the presence, location and laterality of retained testicles were determined. If not too autolyzed, testicular tissue was fixed in 10% neutral buffered formalin, embedded in paraffin, sectioned at 5–6  $\mu$ m, and stained with hematoxylin and eosin for histologic examination.

Because data concerning the relatedness among animals were too sparse to be fruitfully incorporated, statistical analyses were performed ignoring relatedness. Logistic regression in which polynomial year trends (up to the quartic) for the log (odds of cryptorchidism) were tested using the SAS System (SAS Institute, Inc., 1999). The Mann-Whitney test was used to compare means and Fisher's exact test was used to test for independence of variables (Zar, 1984). A  $P$  value of  $\leq 0.05$  was considered statistically significant.

### RESULTS

Presence or absence of descended testicles was recorded for 73 of 77 panthers examined. Seven of 73 were intercrossed progeny resulting from Florida panther and Texas puma matings. The intercrosses included two  $F_1$  (*P. concolor coryi*  $\times$  *P. concolor stanleyana*), two  $F_2$  ( $F_1 \times F_1$ ), and three backcross ( $F_1 \times P. concolor coryi$ ) individuals. Of 49 non-intercross panthers that survived to adulthood ( $\geq 24$  mo), 24 (49%) were cryptorchid, including three that were bilaterally cryptorchid. None of the intercross individuals was cryptorchid (Fig. 1). Overall there was an increasing

linear trend in the odds of cryptorchidism over years ( $P=0.03$ ).

Forty-one male panthers were examined at least once as juveniles (<24 mo). The earliest age at which both testicles were noted to be descended was 2 mo and the latest age at which descent of both testicles occurred was between 10–13 mo. In four cases, juveniles were bilaterally cryptorchid when first examined at 6, 7, 8, and 8 mo old respectively, but they were unilaterally cryptorchid when re-examined at 18, 18, 12, and 16 mo, respectively. In another four cases, juveniles were unilaterally cryptorchid when first examined at 1, 5, 7, and 10 mo old respectively, but they were normal when re-examined at 2, 10, 15, and 13 mo, respectively. All six intercross males handled as juveniles had two descended testicles at the time of their first physical examination, which occurred at ages ranging from 8–16 mo. The seventh intercross male had two descended testicles when first examined at 4 yr of age.

One originally bilaterally cryptorchid juvenile died before reaching adulthood. Another was last examined at 18 mo of age before he was lost to follow up due to radiotransmitter failure at 4 yr of age. None of the three surviving originally bilaterally cryptorchid panthers were successful sires. Two of the four originally unilaterally cryptorchid juveniles spent their lives in captivity, the third died before reaching adulthood, and the fourth became a successful sire.

Thirty-five free-ranging, non-intercross males with at least one descended testicle were monitored via radiotelemetry during adulthood. Of these, 18 successfully sired at least one litter of kittens during their lifetime, and 17 were not known to have sired litters. In the successful sire group, eight (44%) of the males were cryptorchid and the remaining individuals were normal. In the group of panthers not known to have sired litters, nine (53%) panthers were cryptorchid.

The mean $\pm$ SD age of successful sires at first reproduction was  $4.3\pm 1.4$  yr. One half

(8/16) of the panthers not known to have sired litters died before the age of four, and 50% of these were killed by older males. When only panthers  $\geq 4$  yr were considered, 7/14 (50%) successful sires were cryptorchid and 3/8 (38%) panthers not known to have sired litters were cryptorchid. This difference was not statistically significant ( $P>0.05$ ).

Laterality of the retained testicle was determined for 19 unilaterally cryptorchid panthers. The right testicle was retained in ten (53%) of the cases and the left testicle was retained in 9 (47%). The location of the retained testicle was determined at necropsy; 12 (80%) of 15 were in the inguinal canal. In two cases, the retained testicle was found in the subcutaneous tissue just caudal to the inguinal ring, and in another it was within the abdominal cavity near the pubic rim. Both testicles were retained in the inguinal canals of two bilaterally cryptorchid individuals, and both testicles of the third bilaterally cryptorchid panther were retained in the subcutaneous tissue caudal to the inguinal ring.

Grossly, retained testicles were smaller than descended. Retained testicles weighed significantly less than descended testicles with a mean $\pm$ SD weight of  $3.5\pm 0.8$  g ( $n=8$ ) for retained and  $9.1\pm 1.6$  g ( $n=10$ ) for descended ( $P<0.01$ ). Histologically, cryptorchid testes were characterized by hypoplastic seminiferous tubules lined by Sertoli cells and reduced numbers of spermatogonia with no evidence of spermatogenesis. In some animals, the seminiferous tubules were surrounded and separated by dense fibrous connective tissue. There were occasional mineral deposits within tubular lumina. These histologic features were not observed in descended testicles.

## DISCUSSION

During the past 29 years of Florida panther monitoring, the overall prevalence of cryptorchidism in adult males was 49%. Twenty-four (69%) of 35 juvenile panthers were cryptorchid when first examined.

However, the number that would have remained cryptorchid into adulthood may be lower, given that delayed testicular descent was documented in at least eight individuals, and seven cryptorchid juveniles that died before reaching adulthood may have eventually had both testicles descend. The high prevalence of cryptorchidism in Florida panthers is in marked contrast to levels reported for presumably non-inbred populations of other species, including 1.0% in humans (Berkowitz et al., 1993), 8.6% in horses (Hayes, 1986), 0.6% in cattle (Saunders and Ladds, 1978), 1.1% in feral goats (Tarigan et al., 1990), 1.2% in dogs (Hayes et al., 1985), 1.7% in domestic cats (Millis et al., 1992), and 3.9% in other populations of puma (Barone et al., 1994).

The pathophysiology of cryptorchidism is not fully known, although a variety of potential etiologies have been proposed. Among these are maternal vitamin A deficiency (Wilson et al., 1953), in utero exposure to high levels of estrogen (Rajfer and Walsh, 1977), and genetic factors (McPhee and Buckley, 1934; Claxton and Yeates, 1972; Cox et al., 1978). Dunbar et al. (1999) ruled out vitamin A deficiency as a likely cause of congenital deformities, including cryptorchidism, in Florida panthers. Facemire et al. (1995) suggested that environmental contaminants, including xenobiotic estrogenic compounds, might be responsible for the high prevalence of cryptorchidism in Florida panthers, although their evidence was inconclusive. Finally, O'Brien et al. (1990) and Barone et al. (1994) provided convincing evidence that genetic factors, specifically low genetic diversity, were responsible for a number of morphologic abnormalities seen in Florida panthers, including cryptorchidism.

Previous work on Florida panthers has demonstrated the existence of two genetic lineages within the wild population (O'Brien et al., 1990). The so-called "Piper stock" is believed to have descended from seven captive puma that were released into Everglades National Park between

1957 and 1967. Genetic analysis suggests that this group may have included Florida panther/Latin American puma hybrids. "Piper stock" animals have greater genetic variability than do "authentic" Florida panthers, and for the most part lack the abnormal morphologic traits, including cryptorchidism, commonly associated with panthers of pure *P. concolor coryi* descent (O'Brien et al., 1990). A genetic basis for cryptorchidism has been demonstrated in numerous species (McPhee and Buckley, 1934; Claxton and Yeates, 1972; Cox et al., 1978; Czeizel et al., 1981). Most authors suggest that in the majority of cases a sex-limited autosomal recessive gene is responsible for cryptorchidism. In the present study, the cryptorchid trait was eliminated in all examined progeny of Texas females, while the prevalence of cryptorchidism appeared to increase in non-intercross panthers born in the same region during the same time period (Fig. 1). This provides further evidence that cryptorchidism in the Florida panther is genetically, rather than environmentally based.

This is the first report of delayed testicular descent in pumas. Dunbar et al. (1996) reported on cryptorchidism and delayed testicular descent in Florida black bears (*Ursus americanus*) and considered retention of testicles during the first year normal. The testicles of domestic cats are descended into the scrotum at birth (Burke, 1986). It is not known whether delayed testicular descent is a normal occurrence in pumas. Delayed testicular descent was observed in normal dogs from a colony with a high incidence of cryptorchidism (Cox et al., 1978). Similarly, we believe that the delayed testicular descent observed in Florida panthers is probably related to the high prevalence of cryptorchidism in this population.

In this study, no bilaterally cryptorchid males were known to have sired litters, including those that were bilaterally cryptorchid when examined as juveniles but later had a testicle descend before reaching adulthood. This suggests that retention of



both testicles, even during a relatively brief period before maturity, may result in permanent sterility. However, sample sizes were small and further investigation is needed before definitive conclusions can be drawn.

There was no apparent difference in the abilities of cryptorchid and non-cryptorchid panthers to sire litters. Approximately half of the adult male population were suspected sires. This is similar to findings in other puma populations, where only a proportion of adult males participate in breeding (Logan et al., 1996). Successful sires tended to be older than males not known to have bred. This is consistent with what is known about the social organization of other puma populations, in that older resident males tend to do most of the breeding (Seidensticker et al., 1973).

Identification of successful panther sires was inferred from radiotelemetry data. Male puma typically establish home ranges with little overlap with other males (Maehr et al., 1990), however, we could not rule out the possibility of unmonitored males siring litters. Currently, DNA microsatellite analysis is showing potential for corroborating or refuting field information. Of 41 panthers for which paternity was inferred from radiotelemetry data, the purported sire was excluded as a possibility in only three instances based on genetic analysis (W. Johnson, unpubl. data).

Preliminary analysis indicates that genetic restoration of the Florida panther appears to hold promise in reducing, if not eliminating, the occurrence of at least one maladaptive trait believed to be the result of inbreeding. Molecular genetic analysis is currently underway to further characterize the genetic structure of the population and how it relates to the expression of cryptorchidism and other morphologic anomalies (Land and Lacy, 2000). Further evaluation will be needed to determine the level at which genetic augmentation must continue to maintain population viability and to conclusively rule out the role of

non-genetic factors in the expression of potentially deleterious traits.

#### ACKNOWLEDGMENTS

We thank O. L. Bass, R. C. Belden, D. K. Jansen, D. S. Maehr, R. T. McBride, J. W. McCown, J. C. Roboski, J. C. Roof, M. E. Roelke, C. M. Glass, M. R. Dunbar, S. K. Taylor, M. A. Lotz, D. Shindle, D. S. Singler, and M. W. Cunningham for their excellent field work and data collection; S. B. Linda for assistance with statistical analyses; C. J. Sigurdson for summarizing histologic findings; and C. Buergelt and other pathologists from the VMTH Department of Pathobiology at the University of Florida for assistance with necropsies. This study was funded by the Florida Fish and Wildlife Conservation Commission and the Florida Panther Trust Fund.

#### LITERATURE CITED

- ASHMAN, D. L., G. C. CHRISTENSEN, M. L. HESS, G. K. TSUKAMOTO, AND M. S. WICKERSHAM. 1983. The mountain lion in Nevada. Federal Aid to Wildlife Restoration Final Report, Project W-48-15. Nevada Fish and Game Department, Reno, Nevada, 66 pp.
- BARONE, M. A., M. E. ROELKE, J. HOWARD, J. L. BROWN, A. E. ANDERSON, AND D. E. WILDT. 1994. Reproductive characteristics of male Florida panthers: Comparative studies from Florida, Texas, Colorado, Latin America, and North American zoos. *Journal of Mammalogy* 75: 150–162.
- BERKOWITZ, G. S., R. H. LAPINSKI, S. E. DOLGIN, J. G. GAZELA, I. R. HOZMAN, AND C. A. BODIAN. 1993. Prevalence and natural history of cryptorchidism. *Pediatrics* 92: 44–49.
- BURKE, T. J. 1986. Small animal reproduction and infertility. Lea and Febiger, Philadelphia, Pennsylvania, 408 pp.
- CLAXTON, J. H., AND N. T. M. YEATES. 1972. The inheritance of cryptorchidism in a small cross-bred flock of sheep. *Journal of Heredity* 63: 141–144.
- COX, V. S., L. J. WALLACE, AND C. R. JESSEN. 1978. An anatomic and genetic study of canine cryptorchidism. *Teratology* 18: 233–240.
- CUNNINGHAM, M. W., M. R. DUNBAR, C. D. BUERGELT, B. L. HOMER, M. E. ROELKE-PARKER, S. K. TAYLOR, R. KING, S. B. CITINO, AND C. GLASS. 1999. Atrial septal defects in Florida panthers. *Journal of Wildlife Diseases* 35: 519–530.
- CZEIZAL, A., E. ERODI, AND J. TOTH. 1981. Genetics of undescended testis. *Journal of Urology* 126: 528–529.
- DUNBAR, M. R., M. W. CUNNINGHAM, J. B. WOOD-

- ING, AND R. P. ROTH. 1996. Cryptorchidism and delayed testicular descent in Florida black bears. *Journal of Wildlife Diseases* 32: 661–664.
- , M. R., M. W. CUNNINGHAM, AND S. B. LINDA. 1999. Vitamin A concentrations in serum and liver from Florida panthers. *Journal of Wildlife Diseases* 35: 171–177.
- FACEMIRE, C. F., T. S. GROSS, AND L. J. GUILLETT, JR. 1995. Reproductive impairment in the Florida panther: Nature or nurture? *Environmental Health Perspectives* 103: 79–86.
- HAYES, H. M. 1986. Epidemiological features of 5009 cases of equine cryptorchidism. *Equine Veterinary Journal* 18: 467–471.
- , H. M. JR., G. P. WILSON, T. W. PENDERGRASS, AND V. S. COX. 1985. Canine cryptorchidism and subsequent testicular neoplasia: Case-control study with epidemiologic update. *Teratology* 32: 51–56.
- KWAKAMI, E., T. TSUTSUI, Y. YAMADA, AND M. YAMAUCHI. 1984. Cryptorchidism in the dog: Occurrence of cryptorchidism and semen quality in the cryptorchid dog. *Japanese Journal of Veterinary Science* 46: 303–308.
- LAND, E. D., AND R. C. LACY. 2000. Introgression level achieved through Florida panther genetic restoration. *Endangered Species Update* 17: 99–103.
- , D. R. GARMAN, AND G. A. HOLT. 1998. Monitoring female Florida panthers via cellular telephone. *Wildlife Society Bulletin* 26: 29–31.
- LOGAN, K. A., L. L. SWEANOR, T. K. RUTH, AND M. G. HORNOCKER. 1996. Cougars of the San Andres mountains, New Mexico. *Federal Aid in Wildlife Restoration Project Final Report W-128-R*. New Mexico Department of Game and Fish, Santa Fe, New Mexico, 280 pp.
- MAEHR, D. S. 1990. The Florida panther and private lands. *Conservation Biology* 4: 167–170.
- MCCOWN, J. W., D. S. MAEHR, AND J. ROBOSKI. 1990. A portable cushion as a wildlife capture aid. *Wildlife Society Bulletin* 18: 34–36.
- MCPHEE, H. C., AND S. S. BUCKLEY. 1934. Inheritance of cryptorchidism in swine. *Journal of Heredity* 25: 295–303.
- MILLIS, D. L., J. G. HAUPTMAN, AND C. A. JOHNSON. 1992. Cryptorchidism and monorchidism in cats: 25 cases (1980–1989). *Journal of the American Veterinary Medical Association* 200: 1128–1130.
- O'BRIEN, S. J., M. E. ROELKE, N. YUHKI, K. W. RICHARDS, W. E. JOHNSON, W. L. FRANKLIN, A. E. ANDERSON, O. L. BASS JR., R. C. BELDEN, AND J. S. MARTENSON. 1990. Genetic introgression within the Florida panther *Felis concolor coryi*. *National Geographic Research* 6: 485–494.
- RAJFER, J., AND P. C. WALSH. 1977. Hormonal regulation of testicular descent: Experimental and clinical observation. *Journal of Urology* 118: 985–990.
- ROELKE, M. E. 1990. Florida panther biomedical investigation, final performance report. *Endangered species project E-1-11 7506*. Florida Game and Fresh Water Fish Commission, Tallahassee, Florida, 178 pp.
- SAS INSTITUTE, INC. 1999. SAS OnlineDoc®, Version 8. SAS Institute, Inc., Cary, North Carolina, <http://www.sas.com>.
- SAUNDERS, P. J., AND P. W. LADDS. 1978. Congenital and developmental anomalies of the genitalia of slaughtered bulls. *Australian Veterinary Journal* 54: 10–13.
- SEAL, U. S. 1994. A plan for genetic restoration and management of the Florida panther (*Felis concolor coryi*). Report to the Florida Game and Fresh Water Fish Commission, Conservation Breeding Specialist Group, SSC/IUCN. White Oak Conservation Center, Yulee, Florida, 23 pp.
- SEIDENSTICKER, J. C., M. G. HORNOCKER, W. V. WILDES, AND J. P. MESSICK. 1973. Mountain lion social organization in the Idaho Primitive Area. *Wildlife Monographs* 35, 60 pp.
- TARIGAN, S., P. W. LADDS, AND R. A. FOSTER. 1990. Genital pathology of feral male goats. *Australian Veterinary Journal* 67: 286–290.
- WILKINS, L., J. M. ARIAS-REVERON, B. STITH, M. E. ROELKE, AND R. C. BELDEN. 1997. The Florida panther (*Puma concolor coryi*): A morphological investigation of the subspecies with a comparison to other North and South American cougars. *Bulletin of the Florida Museum of Natural History* 40: 221–269.
- WILSON, J. G., C. B. ROTH, AND J. WAKANY. 1953. An analysis of the syndrome of malformations induced by maternal vitamin A deficiency. Effects of restoration of vitamin A at various times during gestation. *American Journal of Anatomy* 92: 189–217.
- YOUNG, S. P., AND E. A. GOLDMAN. 1946. The puma—mysterious American cat. Dover Publications, New York, New York, 358 pp.
- ZAR, J. H. 1984. *Biostatistical analysis*, 2nd Edition. Prentice-Hall International, Inc. Englewood Cliffs, New Jersey, 718 pp.

Received for publication 28 December 2001.