

ORAL DISEASE IN FREE-LIVING RED SQUIRRELS (SCIURUS VULGARIS) IN THE UNITED KINGDOM

Authors: Sainsbury, Anthony W., Kountouri, Amalia, DuBoulay, George,
and Kertesz, Peter

Source: Journal of Wildlife Diseases, 40(2) : 185-196

Published By: Wildlife Disease Association

URL: <https://doi.org/10.7589/0090-3558-40.2.185>

BioOne Complete (complete.BioOne.org) is a full-text database of 200 subscribed and open-access titles in the biological, ecological, and environmental sciences published by nonprofit societies, associations, museums, institutions, and presses.

Your use of this PDF, the BioOne Complete website, and all posted and associated content indicates your acceptance of BioOne's Terms of Use, available at www.bioone.org/terms-of-use.

Usage of BioOne Complete content is strictly limited to personal, educational, and non - commercial use. Commercial inquiries or rights and permissions requests should be directed to the individual publisher as copyright holder.

BioOne sees sustainable scholarly publishing as an inherently collaborative enterprise connecting authors, nonprofit publishers, academic institutions, research libraries, and research funders in the common goal of maximizing access to critical research.

ORAL DISEASE IN FREE-LIVING RED SQUIRRELS (*SCIURUS VULGARIS*) IN THE UNITED KINGDOM

Anthony W. Sainsbury,^{1,3} Amalia Kountouri,¹ George DuBoulay,¹ and Peter Kertesz^{1,2}

¹ Institute of Zoology, The Zoological Society of London, Regent's Park, London NW1 4RY, UK

² 29a Brook Street, London W1Y 1AJ, UK

³ Corresponding author (email: tony.sainsbury@ioz.ac.uk)

ABSTRACT: Ninety-one red squirrels (*Sciurus vulgaris*) found dead in the UK between January 1994 and August 1998 were necropsied at the Institute of Zoology (London, UK); their oral cavities were examined visually, and in eight cases, radiographically. Four red squirrels, which had evidence of oral disease when necropsied as part of a mortality survey, also were examined. A low prevalence (prevalence=0.033, SE=0.02, $n=91$) of oral disease was found in free-living red squirrels. In only two cases was oral disease the probable cause of death. Attrition of the cheek teeth (three cases) and overgrowth of the incisors (four cases) were the most common lesions found. Partial anodontia was recorded in one squirrel.

Key words: Incisors, malocclusion, molars, periodontal disease, rodent, rodentia.

INTRODUCTION

Geographic range of the red squirrel (*Sciurus vulgaris*) in the British Isles continues to decline, leading to formation of several increasingly isolated populations (Gurnell, 1993). The reason for this decline and their replacement by the grey squirrel (*Sciurus carolinensis*) remains uncertain. There is evidence that grey squirrels utilize food resources better than red squirrels and consequently live at higher density and out-compete red squirrels (Gurnell and Pepper, 1993). However, there is also evidence that infectious disease may play a part in the demise of the red squirrel (Sainsbury and Gurnell, 1995; Sainsbury et al., 2000).

Oral disease was believed to be a potential cause of red squirrel morbidity and mortality based on the frequency that these diseases, especially malocclusion, is seen in captive, and in some species of free-living, rodents (Miles and Grigson, 1990; Hoff and Hoff, 1996). Sainsbury (1997) stated that malocclusion of the incisors was found in free-living red and grey squirrels and was the probable cause of death in one case in each species, but that the prevalence of malocclusion is unknown.

Variations in the number, size, and shape of rodents' teeth are documented in the literature (Miles and Grigson, 1990).

Instances of extra incisors, supernumerary cheek teeth, absence of teeth, variation in molar size, variation in molar cusp pattern, variation in the position, and number of roots are frequently recorded in various species of free-living rodents. No irregularities in the position of the teeth were observed in 622 specimens of *Sciurus* spp. examined (Miles and Grigson, 1990).

Periodontal disease seems to be common in captivity, but in free-living rodents is not well documented. It has been recorded in populations of house mice (*Mus musculus*), deer mice (*Peromyscus oreas*), pocket mice (*Perognathus longimembris*), and lemmings (*Lemmus trimucronatus*), and associated with infectious, genetic, and/or age-related causes (Miles and Grigson, 1990).

Dento-alveolar abscesses in rodents usually involve the incisor teeth. Depending on the position of the incisor in relation to the molar teeth and the bone of the jaw, the infection spreads to cause discharging sinuses at the base of a molar or alternatively osteomyelitis. Dento-alveolar abscesses have been observed in an alpine marmot (*Marmotta marmotta*), an American beaver (*Castor canadensis*), and a field vole (*Microtus agrestis*; Miles and Grigson, 1990).

Caries seldom occur naturally in rodents due to an inhibitive combination of high

oral pH, absence of cariogenic microflora, and low-sugar diet (Wiggs and Lobprise, 1997). Caries were not found in 3,800 skulls of a variety of free-living rodents examined in various museums (Miles and Grigson, 1990).

There have been few investigations into the etiology of oral disease in free-living rodents; most authors limit themselves to describing the lesions found (Miles and Grigson, 1990). Most of the dental problems documented in pet and captive, wild rodents and lagomorphs are associated with incorrect husbandry and management, or are induced experimentally (Robinson, 1979a,b, 1986; Yankell, 1985; Clark and Olfert, 1986; Eisele, 1986; van Foreest, 1993; Crossley et al., 1997). Dental abnormalities in eruption, occlusion, and attrition are probably much more common in captive than free-living animals (Robinson, 1979a,b; Amand and Tinkelman, 1985).

The teeth of red squirrels are heterodont and the cheek teeth are brachyodont (Kertesz, 1993). Rodent incisors grow continuously and have enamel coating on the full length of their labial surfaces while at the buccal aspect of the incisors only the softer dentine is present, which wears to a chisel-shaped cutting edge (Laidler, 1980). A tooth root is defined as any part of a dental structure that is devoid of enamel externally or internally. Therefore, by definition, rodent teeth do not have anatomical roots and are classified as aradicular "elodonts" (Kertesz, 1993). In this paper, the whole length of an incisor tooth is termed the "anatomical crown," any part of that tooth that is visible in the oral cavity is termed the "clinical crown" (Scott and Symons, 1977), whereas that part of the tooth that is covered by gingival tissues or alveolus will be termed "pseudo-root." In this paper, when indicating a position on an elodont tooth, "incisal" will denote the intraoral extremity of the tooth, and "apical" or "apex" the intra-alveolar extremity of the pseudo-root.

The red squirrels' dental formula is:

$$\frac{1}{1} : \frac{0}{0} : \frac{2}{1} : \frac{3}{3} \times 2 = 22.$$

Red squirrels' lower incisors erupt at 19–21 days of age, and the upper incisors erupt at 31–42 days (Gurnell, 1991). The cheek teeth (molars and premolars) erupt from 7 weeks of age onward, and by 10 weeks of age all the cheek teeth are present (Tittensor, 1980). Primary first lower and only the second upper premolars are shed at 16 weeks of age and are replaced by permanent teeth (Holm, 1987). The first upper premolar is vestigial. There are no canine teeth, and the gap between the incisors and the cheek teeth is called the diastema (Gurnell, 1987).

The cheek teeth are quadrate with rounded blunt, cone-shaped bunodont marginal cusps and a concave central area (fossa) on their occlusal surfaces. The occlusal surfaces of the upper cheek teeth are traversed by weak transverse ridges (Gurnell, 1991; Kertesz, 1993). The prominent inner cusps of the upper cheek teeth grind food in the concavity of the opposing lower teeth while the cusps on the outer surface of the upper cheek teeth shear food against those of the lower cheek teeth (Shorten, 1954). A young squirrel has a layer of enamel covering the surface of each cheek tooth, including the cusps and ridges. As age progresses, this layer gets worn, exposing the underlying dentine (Shorten, 1954). Several authors have used tooth wear for age determination in red squirrels (Naumov, 1934; Kyris, 1937; Shengkan and Mingshu, 1979; Shadrina, 1988).

Squirrels, like all rodents, have a marked degree of rostra-caudal gliding movement in their temporomandibular articulations and can move their jaws backward and forward (Crossley, 1995). The two hemi-mandibles of squirrels are connected by the transversus mandibular muscle that can pull them together. The deep and superficial masseters can act to stretch the transversus mandibular muscle

and thus pull the two hemi-mandibles apart slightly. In this way the incisors of the lower jaw can be moved either toward (closed) or away (open) from each other and can be used to seize and crack nuts (Holm, 1987; Laidler, 1980).

An investigation of the prevalence of oral disease in free-living red squirrels from the UK was initiated to assess the significance of oral disease as a cause of morbidity and mortality and also to discover any factors in the etiology of oral disease in free-living red squirrels.

MATERIALS AND METHODS

In a postmortem study of 273 red squirrels, oral disease was observed at autopsy in four animals (a prevalence of 0.014). On that basis an expected maximum prevalence of oral disease of 0.05 was used to calculate the sample size of $n=73$ as necessary for a more detailed study to estimate prevalence in the UK red squirrel population (Thrusfield, 1995).

Ninety-one red squirrels from the UK collected between January 1994 and August 1998 were examined postmortem and, together with four red squirrels from the 273 examined earlier, were given a detailed oral examination using an oral examination chart (Fig. 1). The red squirrels examined were collected by members of the public, research workers, forest rangers, and others who took part in an appeal for carcasses for a mortality survey and several genetic and ecologic research projects (Sainsbury et al., 1995). The time interval between collection and postmortem examination varied. The carcasses of 16 animals were examined after refrigeration, and 75 following freezing at -20°C . The red squirrels were aged according to the techniques of Kyris (1937), Naumov (1934), Shadrina (1988), and Shengkan and Mingshu (1979).

Thirty-five of the 91 red squirrels, which had 1) apparently died from an acute traumatic death (for example, a probable road traffic collision or kill by predators); 2) for which there was no evidence of infectious or noninfectious disease from postmortem examination; 3) were of good body condition; and 4) for which the carcasses were not decomposed were used as examples of normal anatomy to compare with other animals.

The universal dental notation system proposed by Kertesz (1993) was used for identifying teeth. The length of the dental arch (the measurement from the rostral surface of the first premolar to the caudal surface of the third

molar) and its width (at the level of the third molar [M3] of the left maxilla and mandible) were measured. The clinical crown of the incisors and molars was measured from the gingival margin to the coronal end of the tooth at both the labial and lingual or palatal surface. Measurements were taken with calipers (accuracy ± 1 mm) and refer to length in a straight line. Teeth were examined visually and missing and supernumerary teeth and positioning of teeth were recorded in the dedicated chart. Cases of malocclusion secondary to excessive wear or overgrowth were noted. Loss of tooth substance and cases of attrition, caries, fractures, discolored teeth, enamel defects, and pulp exposure were also recorded.

The periodontal tissues were examined for abnormalities: edema, inflammation, and bleeding of the gingivae were scored from 1 to 4 according to severity. These changes could not be assessed in frozen carcasses. The gingival sulci could not be probed with a Williams' periodontal probe because this instrument was too thick, so a 27 G (0.4×12 mm) needle was filed down and graduated in millimeters, and the sulci were measured ± 1 mm. A sharp probe was used to assess mobility of the teeth, and bone loss was assessed radiographically. Gingivae were evaluated for the presence of gum recession, gum hyperplasia, and epulis. The oral cavity was examined for lesions of the soft tissue (cheeks, lips, tongue), tumors, abscesses, jaw deformities, and jaw movement range.

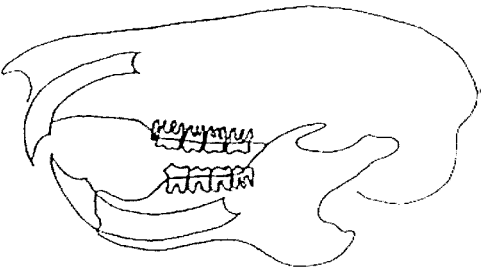
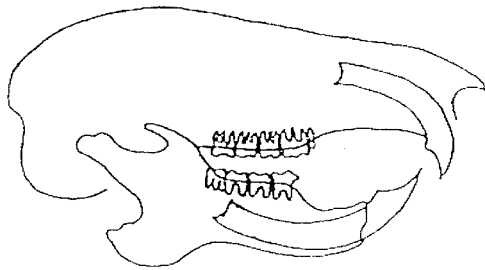
The skulls of eight red squirrels were radiographed, of which six had signs of oral disease and two were apparently normal and used as controls. The mandible was dislocated and divided at its symphysis. Five views were taken: two oblique, a lateral and a dorsoventral of the skull without the mandible, and a lateral of the two hemi-mandibles. Radiographs were produced using a Dean D.38 Mobile Unit with a Dynamax 40 dual focus tube capable of delivering 75–125 KVp and 25–300 mA (Dean, Croydon, UK). Radiographs were made on Fuji Medical X-ray Film HR-E30 (high resolution film) or Fuji Medical X-ray Film MI-MA (mammography film; Fuji Photo Film Co., Ltd., Japan) at 79 cm focus film distance. Exposure times varied between 0.1 and 0.12 sec, at 25–50 mA and 74–78 KVp depending upon the animal's size. The films were wet processed in Polycon X-ray developer (May and Baker, Essex, UK) at 20.4°C . Observations on the radiographs were made by two of the authors (A.K. and G.D.B.).

RESULTS

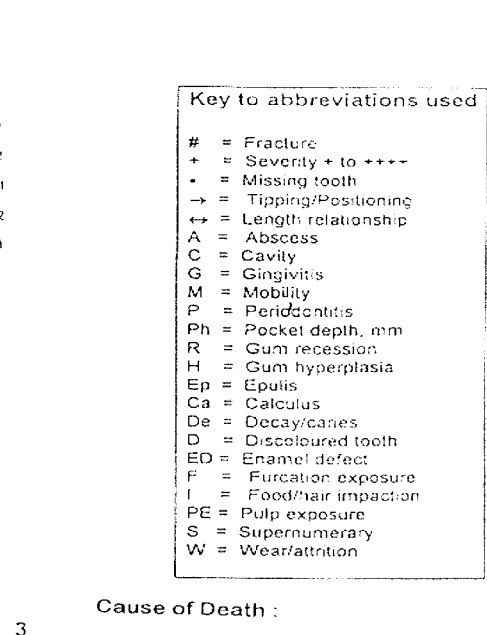
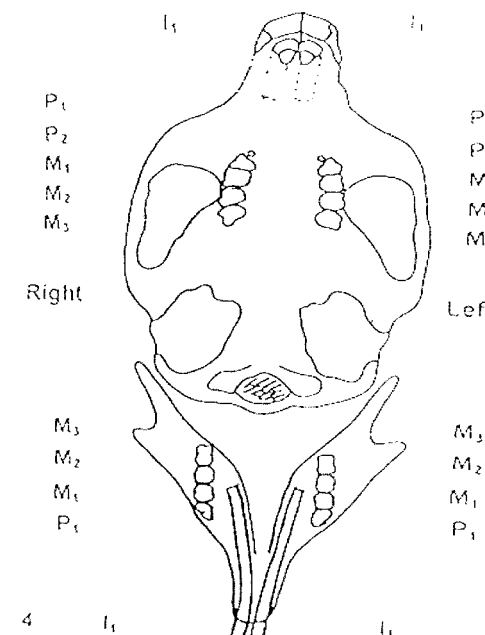
Three of 91 red squirrels examined had oral disease. The prevalence was calculated

Red Squirrrel oral Examination Chart

Case Number & Date :	Sex :	Weight :
X-Ray Number :	Age :	Shin Length:



1 2



Right Left

3 4

Key to abbreviations used

- # = Fracture
- + = Severity + to ++++
- = Missing tooth
- = Tipping/Positioning
- ↔ = Length relationship
- A = Abscess
- C = Cavity
- G = Gingivitis
- M = Mobility
- P = Periodontitis
- Ph = Pocket depth, mm
- R = Gum recession
- H = Gum hyperplasia
- Ep = Epulis
- Ca = Calculus
- De = Decay/caries
- D = Discoloured tooth
- ED = Enamel defect
- F = Furcation exposure
- I = Food/hair impaction
- PE = Pulp exposure
- S = Supernumerary
- W = Wear/attrition

Cause of Death :

Remarks :

FIGURE 1. A sample of the oral examination chart used in this study of red squirrels.

ed as 0.033, the standard error of prevalence was 1.96, and the 95% confidence interval for prevalence was 0.0215 (0.086–0.0018), within which the true prevalence of oral disease in free-living red squirrels is included with 95% certainty.

The length of the dental arch in normal squirrels was 8.5–9.5 mm and its width 2.5–3 mm. The height of the clinical crown of the cheek teeth was 0.5–1 mm.

Molars and premolars occluded in an oblique line. The gingival sulcus depth of the cheek teeth in normal squirrels was less than 0.5 mm. The clinical crowns of the upper incisors were 5–6 mm long at the labial surface and 1.5 mm long at the palatal surface (measured from the gingival margin to the caudal aspect of the tooth tip); the sulcus depth of upper incisors was approximately 3 mm. Clinical

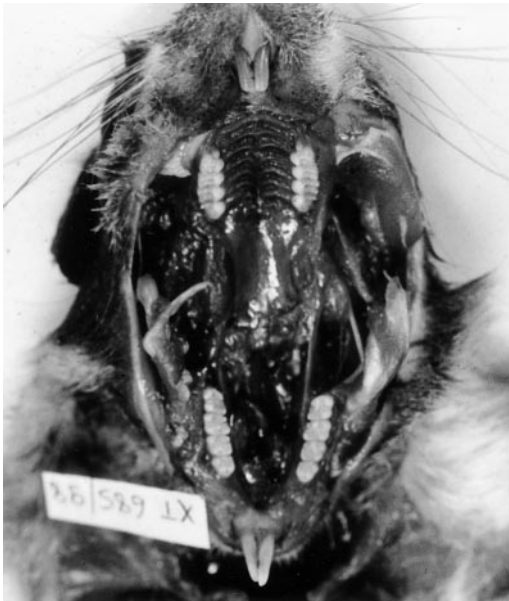

FIGURE 2. The oral cavity of a “normal” young adult red squirrel. Note the cusps and ridges of the cheek teeth and the chisel shaped incisors.

crowns of the lower incisors were 11–13 mm long at the labial surface and 5–6 mm long at the lingual surface (measured from the gingival margin to the coronal tip); the sulcus depth of the lower incisors was approximately 1 mm. Cheek teeth were classified in two groups: those with a bunodont pattern with prominent cusps and ridges belonging to younger animals, and those with well-worn occlusal surfaces belonging to older animals (Fig. 2).

Descriptions of the cases of oral disease follow (Table 1; Figs. 2–8). Gingival tissue was often autolyzed, which made probing of the periodontal tissues impossible. No cases of periodontal disease were observed, but it was evident that only very advanced cases of periodontal disease could have been identified accurately. Plaque and calculus deposition, ulcerations, purulent exudate, and caries were not observed in the carcasses examined. No abnormalities in number, size, shape, position, and eruption of the teeth were observed.

In case 1, the clinical crowns of the lower incisors were approximately 17 mm long

at the labial surface. There were associated traumatic lesions on the upper palate. Cheek teeth had increased mobility, probably because the carcass was decomposed, and worn occlusal surfaces, probably indicating an aged animal. On the radiograph the last but one lumbar disc space was narrowed and there was osteophyte formation adjacent to it cranially. There was a possible fracture of the upper incisors. Malocclusion of the incisors and subsequent starvation were believed to be the cause of death in this thin animal.

In case 2, the clinical crown of the left upper incisor was overgrown (11 mm in length at the labial surface) and met the lower gum surrounding the lower incisor. The left, lower incisor was deflected medially to accommodate the overgrown upper incisor. The gingivae surrounding both upper incisors were necrotic (black colored tissue, which was easily removed). The clinical crown of the right, lower incisor was 14 mm long at the labial surface (probably overgrown). The cheek teeth appeared normal and were immobile. The radiograph of case 2 indicated that the pelvis was asymmetrical, possibly due to injury. The left, upper incisor was overgrown. The left, upper premolars and molars possibly had a thickened periodontal membrane. Although the incisors were overgrown in case 2, it was unclear whether the malocclusion was sufficiently severe to have caused death.

Gross postmortem examination of case 3 revealed exudative erythematous dermatitis at multiple sites and parapoxvirus particles were found on electromicroscopy of the skin lesions: parapoxvirus infection was believed to be the cause of death. On oral examination no upper or lower cheek teeth were present, just a hard pad of cartilaginous tissue (partial anodontia). The alveolar bone of the absent cheek teeth was probably resorbed because the bone was less elevated than normal (Fig. 3). The upper incisors were mildly mobile, probably the result of postmortem change, but otherwise appeared normal. On radio-

TABLE 1. Postmortem findings from red squirrels with oral disease.^a

Case number and postmortem number	Age	Sex	Weight (g)	SL ^b (mm)	Body condition	Carcass	Summary of findings ^c	Cause of death
1 H30/94	A	M	211	58	Thin	m.dec	Malocclusion of the incisors	Overgrown lower incisors
2 XT047/95	A	F	220	69	Thin	fr/m.dec	Malocclusion from overgrown incisors	Unclear
3 XT056/95	A	F	305	73	Normal	ref/fr	Partial anodontia	Probable parapoxvirus infection
4 XT631/95	A	F	340	69	Normal	m.dec	Mandibular osteomyelitis associated with periapical infection	Trauma; probable road casualty
5 XT617/98	A	M	280	69	Emaciated	fro/fr	Malocclusion and attrition of the cheek teeth; geriatric animal	Associated with dental disease
6 XT636/98	A	F	205	61	Thin	fro/fr	Attrition of the cheek teeth (geriatric) and malocclusion of the incisors (resorption and ankylosis of the right lower incisor's pseudo-root associated with a dento-alveolar abscess and osteolysis)	Associated with debility following capture from the wild, anaesthesia, and surgery to drain on orbital abscess and carry out enucleation of the right eye
7 XT678/98	A	F	290	68	Normal	fr	Attrition of the cheek teeth (geriatric) and sclerosis/necrosis of the left lower incisor's pseudo-root associated with chronic infection	Died shortly after anaesthesia for removal of a skin tumour; recently caught from the wild

^a A = adult; M = male; F = female; m.dec = moderately decomposed; fr = fresh; ref = refrigerated; fro = frozen.^b SL = shin length.^c Summary of findings from oral examination.

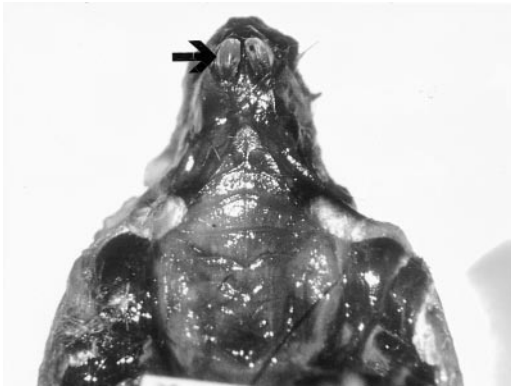


FIGURE 3. Case 3. Note the absence of cheek teeth and the shortened alveolus where the teeth would normally be. The incisors (arrow) had normal appearance.

graph the bones had a normal appearance. No upper or lower molars were present, which may have been due to the ossification of vacated alveoli (possibly a geriatric squirrel that had lost all of its cheek teeth) or due to a developmental defect. The incisors were normal (Fig. 4).

In case 4, the left mandible was enlarged and porous, probably the result of osteomyelitis. The clinical crown of the left, lower incisor was shortened (6 mm long at the labial surface), and when extracted it was seen to be resorbed and irregular in shape, and a mass of tissue (diameter 3 mm) with the consistency of

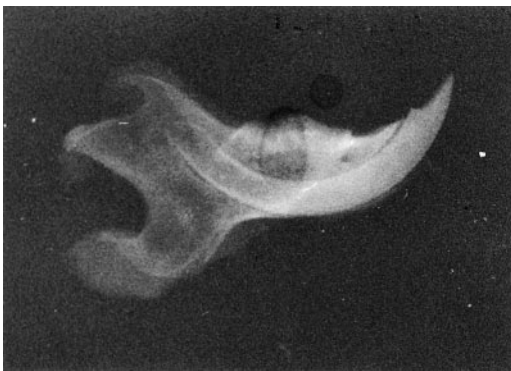

FIGURE 4. Case 3. Lateral view of the left mandible. The cheek teeth were absent and the alveolus appeared radio-dense (probably ossified). The incisor had normal structure with a visible lamina dura surrounding it.

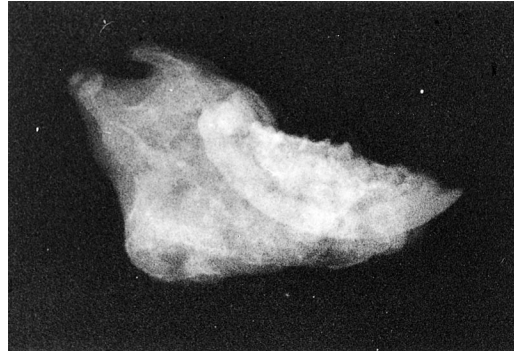

FIGURE 5. Case 4. Lateral view of the left mandible showing a mixture of sclerotic and poorly mineralized bone. The incisor was resorbed. The appearance suggested chronic osteomyelitis. The rest of the skull was unaffected.

bone was found attached to its apex. The cheek teeth of the left mandible were mobile and discolored. The cheek teeth of the left maxilla were less mobile, but were also discolored. On the radiograph of case 4, the left mandible was enlarged and was comprised of a mixture of moderately sclerotic and less mineralized bone. The ventral surface of the body of the left mandible was irregular, and the bone had evidently grown so that the also resorbed incisor was a long way from the ventral surface of the mandible. The appearance suggested chronic mandibular osteomyeli-

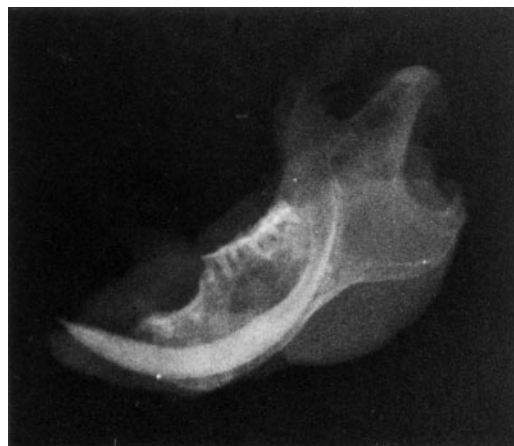

FIGURE 6. Case 5. Lateral view of the right mandible. The incisor was shortened with osteolysis particularly at the rostral or labial end of the alveolus. The pulp cavity appears constricted at the labial end.

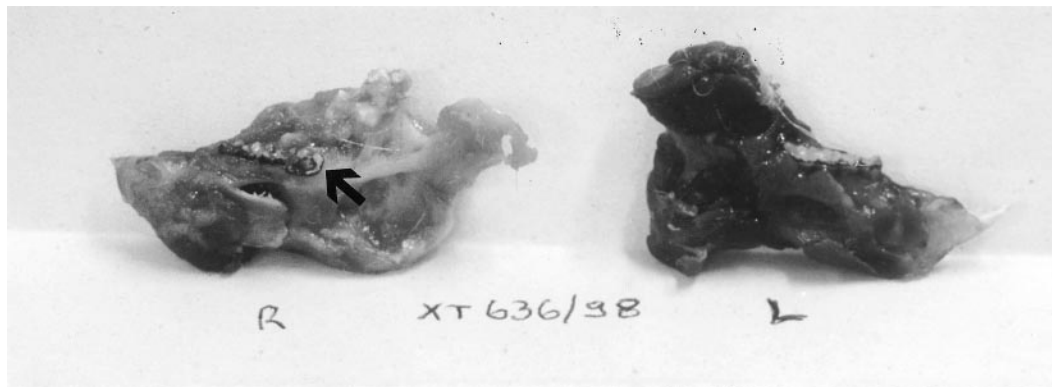

FIGURE 7. Case 6. The two hemi-mandibles after dislocation at the symphysis. Note the shorter than normal right lower incisor and the third molar of the right mandible (arrow) showing an 80° tilt toward the lingual surface. The cheek teeth were discolored and had enamel points.

tis, probably associated with periapical infection (Fig. 5).

Case 5 had worn occlusal surfaces of the cheek teeth with enamel points and attrition, especially on the left maxilla. The right, lower incisor was loose in the alveolus. On extraction, this incisor was constricted at a point approximately 5 mm from its apex and its pulp cavity appeared constricted at the corresponding point, but the apical foramen was as dilated as normal. The squirrel was emaciated. Contents of the digestive tract appeared rough with large pieces of undigested food indicating that the squirrel was not able to masticate effectively. On the radiograph of case 5 the

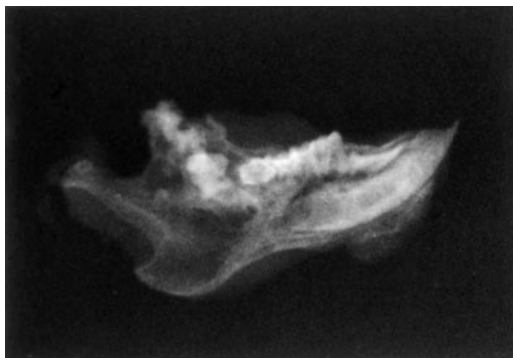


FIGURE 8. Case 6. Lateral view of the right mandible. Note the abnormal and resorbed incisor. The bone of the ramus of the mandible showed disorganized dense mineralization and osteolysis extending into the coronoid process.

lamina dura surrounding the upper molars was not visible, although it was clearly seen surrounding the upper incisors. The significance of this finding was unclear. The alveolus of the right lower incisor was resorbed particularly at its rostral and labial end. This tooth appeared to have a constricted pseudo-root with a narrowed pulp cavity (Fig. 6). In summary, case 5 had malocclusion with attrition of the cheek teeth, probably as a consequence of age.

Case 6 had malocclusion of the incisors. The clinical crown of the right, upper incisor was overgrown with a rounded edge (8.5 mm long). The clinical crown of the right, lower incisor was 5 mm long (smaller than normal). The clinical crown of the left upper incisor was overgrown (7.5 mm long) and the clinical crown of the left lower incisor was 8 mm long. These measurements of the clinical crown were taken at the labial surface. The right, lower incisor was extracted and had a normal pulp cavity diameter, but an irregular mass (diameter 4 mm) of similar consistency to enamel was attached to the apex of the incisor. The cheek teeth of the right mandible were mobile, discolored, and had enamel points. The lower, right, third molar showed an 80° tilt toward the lingual surface (Fig. 7). The cheek teeth of the right maxilla were less mobile but also discolored. On the radiograph of case 6 the lam-

ina dura of the alveoli were not visible. The right, lower incisor was abnormal with a wide periodontal space and there was resorption of the pseudo-root and associated osteolysis. The mandible dorsal to the right, lower incisor had disorganized dense mineralization and osteolysis extended into the coronoid process (Fig. 8). The right, upper incisor had evidence of resorption, and the associated bone was lytic. The floor of the right orbit was represented by what appeared to be bone sequestra. The bone surrounding the right upper molars was resorbed. The right, upper, third molar in particular was loose and damaged. In summary, case 6 had attrition of the cheek teeth probably as a consequence of age and malocclusion of the incisors as a result of resorption of the right lower incisor's pseudo-root associated with a dento-alveolar abscess and osteolysis.

The occlusal surfaces of the cheek teeth of case 7 were worn with enamel points on the lingual surface of the mandibular teeth. The cheek teeth were not mobile. These worn surfaces probably were a sign of old age. The lower, left incisor was worn down to the gingival margin and on extraction was seen to be resorbed and irregular in shape, was attached firmly to the bone, and had an irregular hard mass (diameter 4 mm) at its apex. An attempt was made to insert a 27 G needle into the lower left incisor's pulp cavity, but there was no cavity, which was indicative of sclerosis of the pulp, probably due to a chronic infection. The opposing upper, left incisor was not overgrown. On the radiograph of case 7 the left lower incisor was shortened at the clinical crown and irregular in the alveolus. There was a dense bone structure in continuity with the pseudo-root of the tooth. There was evidence of a chronic infection surrounding the left, lower incisor with sclerosis, resorptive lesions, and bone reaction. The pulp of this incisor was probably necrotic.

DISCUSSION

All red squirrels with oral disease were adult, six of seven cases had chronic con-

ditions, and in only two or possibly three cases was oral disease associated with death. Hoff and Hoff (1996) remark that although dental abnormalities in wild mammals may have deleterious effects on an individual, they appear to have minimal effect upon the individual's survival and usually do not have any effect on the population. The effect of geographic location of origin on oral disease prevalence was not considered.

Oral diseases described in free-living red squirrels in this study were probably of degenerative, traumatic, or possibly nutritional origin. The most commonly encountered oral lesions were malocclusion of the incisors and attrition of the cheek teeth. Attrition of the cheek teeth was assumed to be a normal consequence of old age, as described in the reports on age determination of red squirrels (Naumov, 1934; Kyris, 1937; Shengkan and Mingshu, 1979; Shadrina, 1988). However, in one case attrition was severe enough to cause malocclusion leading to asymmetry of the left maxilla (case 5). The emaciated state of case 5 and the presence of undigested food in the gastro-intestinal tract led us to believe that attrition and malocclusion were the cause of death.

Malocclusion of the incisors was observed in four cases (2, 4, 6, and 7). In two instances it was associated with a degenerative process at the incisor's pseudo-root (dento-alveolar abscess in case 6; sclerosis and necrosis of the pulp probably associated with trauma and infection in case 7). From radiographic evidence in case 6, it seems that the bony orbit was also involved because there were bone sequestra in the floor of the orbit. There are two possible origins for the malocclusion. The abscess of the soft tissues surrounding the temporomandibular joint may have led to malocclusion of the incisors because pain, swelling, and subsequently fibrosis may have prevented mouth closure. Alternatively, it is possible that a dento-alveolar abscess at the pseudo-root of the incisor

caused malocclusion and the infection spread to the soft tissues surrounding it.

Case 4 had malocclusion that was associated with chronic mandibular osteomyelitis due to a periapical infection. Surprisingly, the squirrel was in good condition considering the extent of the infection. The cause of death was trauma, probably due to a road traffic collision. Miles and Grigson (1990) also found that free-living rodents can survive with malocclusion: overgrowth of the incisors was noted in a Townsend's ground squirrel (*Spermophilus townsendi*) and in a red squirrel (*Tamiasciurus hudsonicus*). The Townsend's ground squirrel managed to feed by placing one side of its open mouth over long blades of grass and biting them off with its cheek teeth (Miles and Grigson, 1990). Furthermore, in a recent paper by van der Merwe (1997), malocclusion of the incisors was studied in African greater cane rats (*Thryonomys swinderianus*). Van der Merwe (1997) examined 163 skulls from wild animals and carried out detailed radiographic examination of four cane rat pups at stages during growth and concluded that malocclusion in the cane rat does not necessarily reduce fitness because the overgrown incisors tend to break below the gum line before they impede feeding.

Malocclusion in the cases examined in this study appeared to be caused by mechanical factors affecting the pseudo-roots of the incisors. This finding is consistent with observations by Wiggs and Lobprise (1997) and Chaturvedi (1966) who stated that rodents with brachyodont molars, like squirrels, rarely present with atraumatic malocclusion, but traumatic malocclusion caused by mechanical factors or tooth fracture is common. A variety of factors have been implicated by Wiggs and Lobprise (1995) to predispose to malocclusion: genetics (heredity), trauma, diet, dental habits, and chewing exercise; however, they did not give evidence to support these possibilities.

Disorganized growths, which stimulate odontomes at the apex of injured teeth,

have been described (Miles and Grigson, 1990), and the irregular masses at the apex of the incisors of cases 4, 6, and 7 were probably similar.

The cheek teeth were completely absent (partial anodontia) in case 3. It was unclear whether the absence of cheek teeth was a developmental defect or whether it was due to old age. This squirrel was in good condition at the time of death, and therefore was probably feeding adequately. The authors are not aware of other reports of partial anodontia in rodents.

Periodontal disease was not observed, although there were problems associated with its assessment. The evaluation of normal tooth mobility was difficult, because in decomposed carcasses mobility was increased as the result of autolysis of periodontal tissues. Mobility was also increased in the recently erupted teeth of young squirrels, presumably because the periodontal tissues were still developing. In some radiographs the periodontal membrane of teeth appeared thickened and in some cases the lamina dura of the alveolus was not visible. Robinson and Gorrel (1995) state that widening of the periodontal space and reduced clarity of the lamina dura, particularly at the coronal portion of the teeth, may be seen in some cases of periodontal disease. Upon examination of these cases with radiographic evidence of periodontal disease, no mobility of the teeth was observed. It is possible that this radiographic evidence of periodontal disease may have been due to degenerative postmortem change.

Although the sample chosen for this study was selected by a form of convenience sampling and is probably not truly representative of the free-living red squirrel population, the calculated estimate of prevalence of 0.033 indicates that oral disease is probably uncommon in free-living red squirrels. In two of the red squirrels examined, oral disease was believed to be the primary cause of death.

ACKNOWLEDGMENTS

The authors would like to thank J. Robinson, D. Crossley, J. Gurnell, and F. Harcourt-Brown

for their advice, and T. Fitzgerald and T. Dennett for technical support.

LITERATURE CITED

- AMAND, W. B., AND C. L. TINKELMAN. 1985. Oral disease in captive wild animals. In *Veterinary dentistry*, C. E. Harvey (ed.), W. B. Saunders, London, UK, pp. 289–311.
- CHATURVEDI, Y. 1966. Malocclusion in rodent incisors. *Proceedings of the Zoological Society, Calcutta*, India 19: 87–103.
- CLARK, J. D., AND E. D. OLFERT. 1986. Rodents (*Rodentia*). In *Zoo and wild animal medicine*, 2nd Edition, M. E. Fowler (ed.), W.B. Saunders Co., London, UK, pp. 727–747.
- CROSSLEY, D. A. 1995. Aspects of rodent dental anatomy 1: Jaw movement in the rat. *Journal of the British Veterinary Dental Association* 4: 6–7.
- , R. R. DUBIELZIG, AND K. G. BENSON. 1997. Caries and odontoclastic resorptive lesions in a chinchilla (*Chinchilla lanigera*). *The Veterinary Record* 141: 337–339.
- EISELE, P. H. 1986. Dental problems in rabbits and rodents. In *Current veterinary therapy IX: Small animal practice*, R. W. Kirk (ed.), W. B. Saunders, London, UK, pp. 759–762.
- GURNELL, J. 1987. *The natural history of squirrels*. Christopher Helm, London, UK, 201 pp.
- . 1991. Red squirrel (*Sciurus vulgaris*). In *The handbook of British mammals*, G. B. Corbet and S. Harris (eds.), Mammal Society, Blackwell Scientific Publications, Oxford, UK, pp. 177–186.
- . 1993. The red squirrel (*Sciurus vulgaris*). In *A red data book for British mammals*, P. E. Morris (ed.), The Mammal Society, London, UK, pp. 56–58.
- , AND H. W. PEPPER. 1993. A critical look at conserving the British red squirrel *Sciurus vulgaris*. *Mammal Review* 23: 127–137.
- HOFF, G. L., AND D. M. HOFF. 1996. Dental anomalies in mammals. In *Noninfectious diseases of wildlife*, A. Fairbrother, L. N. Locke, and G. L. Hoff (eds.), Manson Publishing, London, UK, pp. 203–211.
- HOLM, J. 1987. *Squirrels*. Whittet Books, London, UK, 124 pp.
- KERTESZ, P. 1993. *A colour atlas of veterinary dentistry and oral surgery*. Wolfe Publishing, Aylesbury, UK, 224 pp.
- KYRIS, I. D. 1937. Méthode et technique pour la fixation de l'âge de l'écureuil et l'analyse des populations d'écureuils d'après l'âge. *Bulletin de la Societe Nationale de Moscou, S. Biologique T XLVI*: 36–42. [In French]
- LAIDLER, K. 1980. *Squirrels in Britain*. David and Charles, London, UK, 156 pp.
- MILES, A. E. W., AND C. GRIGSON. 1990. *Colyer's variation and diseases of the teeth of animals*. Cambridge University Press, Cambridge, UK, 672 pp.
- NAUMOV, N. P. 1934. Determining the age of the squirrel (*Sciurus vulgaris* L.). *Scientific Reports of Moscow State University* 2: 275–291.
- ROBINSON, J., AND C. GORREL. 1995. Oral examination and radiography. In *BSAVA manual of small animal dentistry*, 2nd Edition, D. A. Crossley and S. Penman (eds.), British Small Animal Veterinary Association, Gloucestershire, UK, pp. 35–49.
- ROBINSON, P. T. 1979a. A literature review of dental pathology and aging by dental means in nondomestic animals—Parts I. *Journal of Zoo Animal Medicine* 10: 57–65.
- . 1979b. A literature review of dental pathology and aging by dental means in nondomestic animals—Part II. *Journal of Zoo Animal Medicine* 10: 81–91.
- . 1986. Dentistry in zoo animals. In *Zoo and wild animal medicine*, 2nd Edition, M. E. Fowler, (ed.), W.B. Saunders Co., London, UK, pp. 533–547.
- SAINSBURY, A. W. 1997. Introduction to the veterinary care of squirrels. *UK Vet, Companion Animal* 2: 95–97.
- , AND J. GURNELL. 1995. An investigation into the health and welfare of red squirrels, *Sciurus vulgaris*, involved in reintroduction studies. *The Veterinary Record* 137: 367–370.
- , A. A. CUNNINGHAM, E. S. WARNS, S. MCGREGOR, P. DASZAK, AND S. J. BALL. 1995. Studies on the health and welfare of red squirrels in the UK. In *2nd NPI red alert forum for red squirrel conservation: Forum proceedings supplement*, D. G. Hughes and T. Tew (eds.), Federation of Zoological Gardens of Great Britain and Ireland, London, UK.
- , P. NETTLETON, J. GILRAY, AND J. GURNELL. 2000. Grey squirrels have high seroprevalence to a parapoxvirus associated with deaths in red squirrels. *Animal Conservation* 3: 229–233.
- SCOTT, J. H., AND N. B. B. SYMONS. 1977. *Introduction to dental anatomy*. Churchill Livingstone, London, UK, 345 pp.
- SHADRINA, E. G. 1988. On the technique of age estimation in red squirrel (*Sciurus vulgaris*). *Zoologicheskii Zhurnal* 67: 1229–1237.
- SHENGGAN, Z., AND L. MINGSHU. 1979. On the age determination and age structure in the population of the squirrel, *Sciurus vulgaris*, at Wuying, Lesser Khing-An Mountains. *Acta Zoologica Sinica* 25: 268–276.
- SHORTEN, M. 1954. *Squirrels*. Collins, London, UK, 189 pp.
- THRUSFIELD, M. 1995. *Veterinary epidemiology*, 2nd Edition. Blackwell Science Ltd., Oxford, UK, 483 pp.
- TITTENSOR, A. 1980. *The red squirrel*. Blandford Press, Poole, UK, 75 pp.

- VAN DER MERWE, M. 1997. Malocclusion in an African rodent. Is it necessarily fatal? *Journal of Zoology*, London 243: 689–694.
- VAN FOREEST, A. W. 1993. Veterinary dentistry in zoo and wild animals. *In* *Zoo and wild animal medicine, current therapy 3*. M. E. Fowler (ed.). W. B. Saunders Co., London, UK, pp. 263–268.
- WIGGS, R. B., AND H. B. LOBPRISE. 1995. Dental anatomy and physiology of pet rodents and lagomorphs, oral diagnosis in pet rodents and lagomorphs, prevention and treatment of dental problems in rodents and lagomorphs. *In* *BSAVA manual of small animal dentistry*, 2nd Edition, D. A. Crossley and S. Penman (eds.). British Small Animal Veterinary Association, Gloucestershire, UK, pp. 68–91.
- , ———. 1997. *Veterinary dentistry: Principles and practice*. Lippincott-Raven, New York, New York, 275 pp.
- YANKELL, S. L. 1985. Oral disease in laboratory animals: Animal models in human dental disease. *In* *Veterinary dentistry*, C. E. Harvey (ed.). W. B. Saunders, London, UK, pp. 281–288.

Received for publication 13 October 2003.