

Infectious Keratoconjunctivitis in Bighorn Sheep, Silver Bell Mountains, Arizona, USA

Authors: Jansen, Brian D., Heffelfinger, James R., Noon, Ted H., Krausman, Paul R., and deVos, James C..

Source: Journal of Wildlife Diseases, 42(2) : 407-411

Published By: Wildlife Disease Association

URL: <https://doi.org/10.7589/0090-3558-42.2.407>

BioOne Complete (complete.BioOne.org) is a full-text database of 200 subscribed and open-access titles in the biological, ecological, and environmental sciences published by nonprofit societies, associations, museums, institutions, and presses.

Your use of this PDF, the BioOne Complete website, and all posted and associated content indicates your acceptance of BioOne's Terms of Use, available at www.bioone.org/terms-of-use.

Usage of BioOne Complete content is strictly limited to personal, educational, and non - commercial use. Commercial inquiries or rights and permissions requests should be directed to the individual publisher as copyright holder.

BioOne sees sustainable scholarly publishing as an inherently collaborative enterprise connecting authors, nonprofit publishers, academic institutions, research libraries, and research funders in the common goal of maximizing access to critical research.

Infectious Keratoconjunctivitis in Bighorn Sheep, Silver Bell Mountains, Arizona, USA

Brian D. Jansen,^{1,5} James R. Heffelfinger,² Ted H. Noon,³ Paul R. Krausman,¹ and James C. deVos, Jr.⁴

¹ 325 Biological Sciences East Building, School of Natural Resources, University of Arizona, Tucson, Arizona 85721, USA; ² Arizona Game and Fish Department, 555 N. Greasewood, Tucson, Arizona 85745, USA; ³ Arizona Veterinary Diagnostics Laboratory, Department of Veterinary Science and Microbiology, University of Arizona, Tucson, Arizona 85721, USA; ⁴ Arizona Game and Fish Department, 2221 W. Greenway Road, Phoenix, Arizona 85023, USA; ⁵ Corresponding author (email: bighorns101@yahoo.com)

ABSTRACT: An infectious keratoconjunctivitis (IKC) epizootic in bighorn sheep (*Ovis canadensis*) occurred in the Silver Bell Mountains, Arizona, USA, from 1 December 2003 to 31 March 2004. We used standard culture methods and polymerase chain reaction (PCR) amplification of the 16S rRNA gene to test for the causative agents of IKC and other diseases reported to be associated with bighorn sheep populations. All bighorn sheep and domestic goat test results were negative except for *Mycoplasma* spp. and *Branhamella* spp. The culture and PCR results differed. Conjunctival swabs from four of 19 IKC-affected bighorn sheep tested by culture were positive for *Mycoplasma* spp., whereas 22 of 22 bighorn sheep samples tested by PCR were positive for *Mycoplasma* spp. None of 13 domestic goats tested positive by culture for *Mycoplasma* spp., whereas five of 16 tested positive by PCR. Three of 16 domestic goats and seven of 24 IKC-affected bighorn sheep tested positive for *Branhamella* spp. by culture. Bighorn sheep began showing clinical signs of IKC between 21 and 28 days following initial detection of domestic goats in bighorn sheep habitat. The IKC epizootic lasted 122 days, and individual bighorn sheep were blind for an average of 38.4 days. Given the clear potential for disease transmission to bighorn sheep, we recommend that land managers not allow the pasturing of domestic goats near occupied bighorn sheep habitat.

Key words: Arizona, bighorn sheep, disease, infectious keratoconjunctivitis, *Mycoplasma* spp., *Ovis Canadensis*, pinkeye, Silver Bell Mountains.

Infectious keratoconjunctivitis (IKC) caused by infection with *Mycoplasma conjunctivae* is an ocular disease that usually causes temporary blindness. The disease affects domestic livestock worldwide (Jones, 1991) and wild ruminants in Europe (Degiorgis et al., 2000) and in North America (Thorne, 1982; Meagher et

al., 1992). The primary etiologic agent appears to be *M. conjunctivae* (Belloy et al., 2003); however, *Branhamella ovis* may contribute to severity of the disease (Dagnall, 1994). In North America, IKC has been documented in mule deer (*Odocoileus hemionus*) (Taylor et al., 1996), white-tailed deer (*Odocoileus virginianus*) (Thorne, 1982), pronghorn (*Antilocapra americana*) (Thorne, 1982), moose (*Alces alces*) (Thorne, 1982), and bighorn sheep (*Ovis canadensis*) (Bear and Jones, 1973).

During October 2003, 4,800 domestic goats were released approximately 10 km from occupied bighorn sheep habitat in the Silver Bell Mountains, Pima County, Arizona, USA (32°24.5'N, 111°29.5'W), and by 31 October 2003, at least 100 goats had dispersed into bighorn sheep habitat. All domestic goats were removed from bighorn sheep habitat by 6 January 2004. Three to four weeks following this dispersal, bighorn sheep were observed with clinical symptoms of IKC (1 December 2003). The objectives of this study were to identify the pathogen or pathogens causing IKC in this population, to test domestic goats for the same etiologic agents, and to monitor the extent and duration of the epizootic in the bighorn sheep population.

Animals with IKC were captured by hand and restrained or immobilized with a 500-mg, intramuscular injection of tiletamine HCl and zolazepam HCl (Telazol®, Fort Dodge Animal Health, Fort Dodge, Iowa, USA) fired from a dart rifle. All nonclinical animals were captured with a net-gun fired from a helicopter (Kraus-

man et al., 1985). All animals were captured and handled by members of the Arizona Game and Fish Department according to approved department protocols. Field observation was approved by the University of Arizona Institutional Animal Care and Use Committee (protocol 03-104). All animals were treated with 8 ml of oxytetracycline hydrochloride (Liquamycin LA-200®, Pfizer Inc., New York, New York, USA) injected subcutaneously and 1 g of oxytetracycline hydrochloride ophthalmic ointment (Terramycin®, Pfizer) applied in the conjunctival sacs of both eyes.

Nine healthy bighorn sheep had been captured as part of a different research project in May 2003, of which three became infected at the onset of the epizootic. During the epizootic, we captured 31 additional bighorn sheep (22 clinical and nine nonclinical). Two of the nine nonclinical animals captured during the epizootic subsequently became clinical. In total, we monitored 27 clinical (14 male and 13 female) and 13 nonclinical (six male and seven female) bighorn sheep during the epizootic. We used radiocollars (Telonics, Mesa, Arizona, USA) and ear-tags (Duflex®, Digital Angel Corp., South St. Paul, Minnesota, USA) to aid our monitoring efforts. We located animals daily during the epizootic by radiotelemetry (White and Garrott, 1990) and observed them with 10× binoculars. We were unable to sample all the marked and clinically affected bighorn sheep, because some animals were not captured and some died before capture was possible. Additionally, we were unable to test all samples.

Conjunctival swabs, swabs of nasal sinuses, and approximately 20 ml of blood were collected from all captured bighorn sheep and from 16 domestic goats, which were killed in bighorn sheep habitat. Conjunctival swabs were cultured using standard culture methods (Quinn et al., 1994; Van Halderen et al., 1994; Whitford et al., 1994) for bacteria associated with

IKC (i.e., *Branhamella* spp., *Chlamydia* spp., and *Mycoplasma* spp.) in bighorn sheep. In addition to standard culture methods, polymerase chain reaction (PCR; 16S rRNA gene) was used to test conjunctival swabs for *Chlamydia* spp. (Everett et al., 1999), *Chlamydia psittaci* (Sheehy et al., 1996; Hewinson et al., 1997), and *Mycoplasma* spp. (Uemori et al., 1992; Baird et al., 1999). A *M. conjunctivae*-type culture (Sigma-Genosys, The Woodlands, Texas, USA) was used as a control to compare to 16S rRNA sequences derived from two bighorn sheep and to confirm the presence of *M. conjunctivae*. Sequences also were compared to those available from GenBank by using BLAST (Benson et al., 2004) and to one domestic goat sample from the Silver Bell Mountains by direct alignment.

Only *Mycoplasma* spp. and *Branhamella* spp. were cultured from conjunctival samples from bighorn sheep and domestic goats. *Mycoplasma* spp. was cultured from four of 19 bighorn sheep clinically affected with IKC; 13 domestic goats tested by culture were negative for *Mycoplasma* spp. *Branhamella* spp. was cultured from seven of 24 bighorn sheep clinically affected with IKC and from three of 16 domestic goats.

By PCR, 22 of 22 bighorn sheep clinically affected with IKC and five of 16 domestic goats were positive for *Mycoplasma* spp. The PCR sequences of *Mycoplasma* spp. (550+ base pairs) were 99% identical to the *M. conjunctivae* sequences (MCU44770) posted on GenBank. A *M. conjunctivae* sequence (MCU44770) from GenBank differed from bighorn sheep sequences of *M. conjunctivae* at one base pair. The *M. conjunctivae* (MCU44770) sequence from GenBank was derived from a domestic goat with keratoconjunctivitis (Johansson, 1996). Sequences derived from our type-culture of *M. conjunctivae* and one domestic goat were 100% identical to the sequence posted on GenBank

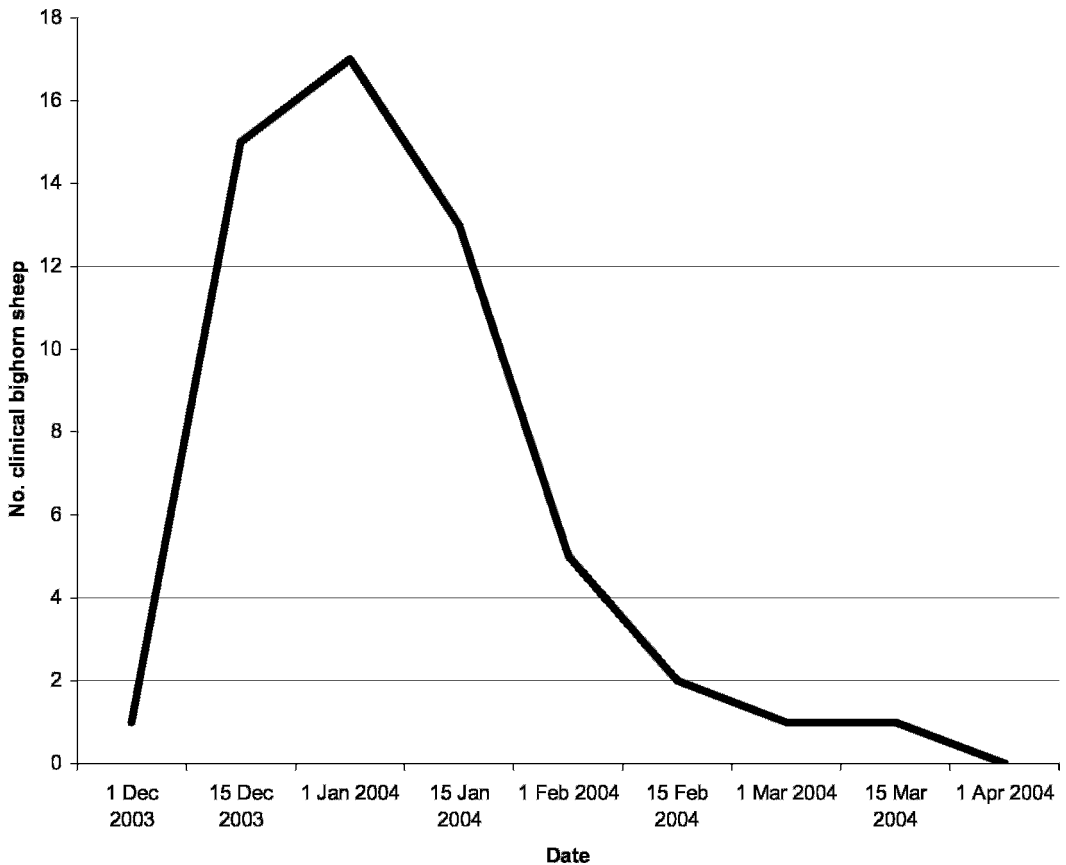


FIGURE 1. Bimonthly incidence of infectious keratoconjunctivitis in bighorn sheep of the Silver Bell Mountains, Pima County, Arizona, USA, from 1 December 2003 to 1 April 2004.

(MCU44770), but two of two bighorn sheep sequences differed from those sequences at three base positions. Sequences of *M. conjunctivae* derived from a domestic goat and bighorn sheep were submitted to GenBank (domestic goat, DQ156347; bighorn sheep, DQ156346).

During initial sampling, conjunctival samples from four of nine bighorn sheep not clinically affected with IKC tested positive by PCR for *Mycoplasma* spp. Two showed clinical signs at or before 7 days and between 6 and 19 days, respectively, following sampling. The remaining two nonclinical animals that tested positive for *Mycoplasma* spp. by PCR did not develop clinical IKC.

We observed the first IKC-affected bighorn sheep on 1 December 2003, and

the last known clinical animal died on 31 March 2004. The epizootic lasted 122 days, and all IKC-clinical bighorn sheep were found during the first 50 days (Fig. 1). We located blind bighorn sheep in varying stages of disease; however, those that were followed through all stages of IKC (Mayer et al., 1997) were blind for 38.4 days ($n=9$; 95% confidence interval [CI], 23.5–53.4 days) before recovering their eyesight or perishing. Bighorn sheep that regained their eyesight or perished were blind for 44 days ($n=3$; 95% CI, 39.7–48.3 days) and 35.7 days ($n=6$; 95% CI, 10.5–60.8 days), respectively. We treated all but three clinical animals of which we were aware. One female died before we could capture her, and two males that we administered antibiotic injections to

before clinical signs appeared subsequently became blind for 43 and 44 days, respectively.

The population of bighorn sheep in the Silver Bell Mountains has been monitored for several decades (Arizona Game and Fish Department, unpubl. data) and has been studied using clinical monitoring of field-captured animals and serology since 1992 (Bristow et al., 1996). To our knowledge, IKC has not been reported previously in this population.

The IKC epizootic in the Silver Bell Mountains was similar to other IKC epizootics reported in other species (Meagher et al., 1992; Loison et al., 1996; Taylor et al., 1996; Cransac et al., 1997; Mayer et al., 1997). Clinically affected bighorn sheep were observed following the first observation of domestic goats in bighorn sheep habitat. The number of days between the initial co-occurrence of domestic goats and bighorn sheep and the clinical symptoms of IKC in bighorn sheep (21–28 days) was similar to the amount of time elapsed for an alpine ibex (*Capra ibex*) to become clinical by contact with inoculated ibex (Giacometti et al., 1998).

The PCR sequences of *Mycoplasma* spp. and *M. conjunctivae* revealed minimal differences between sequences derived from bighorn sheep and those from domestic goats. Sequences of *Mycoplasma* spp. derived from bighorn sheep samples were 100% identical to each other and 99% identical to a sequence derived from a domestic goat. A sequence from a domestic goat sampled from the Silver Bell Mountains was 100% identical to the *M. conjunctivae* sequence posted on GenBank and differed from bighorn sheep sequences at three base positions.

None of the domestic goats removed from bighorn sheep habitat had lesions of active IKC or contagious ecthyma. We did, however, remove one domestic goat having healed lesions that were consistent with recovery from IKC.

Our data strongly suggest that domestic goats transmitted IKC to naïve bighorn

sheep. Belloy et al. (2003) demonstrated the possibility of disease transmission from domestic to wild Caprinae when they are sympatric. For this reason, we recommend that land managers not allow domestic goats near occupied bighorn sheep habitat, because co-occurrence is enough to result in the transmission of disease between domestic and wild Caprinae.

LITERATURE CITED

- BAIRD, S. C., J. CARMAN, R. P. DINSMORE, R. L. WALKER, AND J. K. COLLINS. 1999. Detection and identification of *Mycoplasma* from bovine mastitis infections using a nested polymerase chain reaction. *Journal of Veterinary Diagnostic Investigations* 11: 432–435.
- BEAR, G. D., AND G. W. JONES. 1973. History and distribution of bighorn sheep in Colorado. Colorado Division of Wildlife, Denver, Colorado, 232 pp.
- BELLO, L., M. JANOVSKY, E. M. VILEI, P. PILO, M. GIACOMETTI, AND J. FREY. 2003. Molecular epidemiology of *Mycoplasma conjunctivae* in Caprinae: Transmission across species in natural outbreaks. *Applied Environmental Microbiology* 69: 1913–1919.
- BENSON, D. A., I. KARSCH-MIZRACHI, D. J. LIPMAN, J. OSTELL, AND D. L. WHEELER. 2004. GenBank: Update. *Nucleic Acids Research* 32: D23–D26.
- BRISTOW, K. B., J. A. WENNERLUND, R. E. SCHWEINSBURG, R. J. OLDING, AND R. E. LEE. 1996. Habitat use and movements of desert bighorn sheep near the Silver Bell Mine, Arizona. Technical Report 25. Arizona Game and Fish Department, Phoenix, Arizona, 57 pp.
- CRANSAC, N., A. J. M. HEWISON, J. M. GAILLARD, J. M. CUGNASSE, AND M. L. MAUBLANC. 1997. Patterns of mouflon (*Ovis gmelini*) survival under moderate environmental conditions: effects of sex, age, and epizootics. *Canadian Journal of Zoology* 75: 1867–1875.
- DAGNALL, G. J. R. 1994. The role of *Branhamella ovis*, *Mycoplasma conjunctivae*, and *Chlamydia psittaci* in conjunctivitis of sheep. *British Veterinary Journal* 150: 65–71.
- DEGIORGIS, M. P., E. M. ABDO, J. NICOLET, J. FREY, D. MAYER, AND M. GIACOMETTI. 2000. Immune responses to *Mycoplasma conjunctivae* in alpine ibex, alpine chamois, and domestic sheep in Switzerland. *Journal of Wildlife Diseases* 36: 265–271.
- EVERETT, K. D., L. J. HORNUNG, AND A. A. ANDERSEN. 1999. Rapid detection of the *Chlamydiaceae* and other families in the order *Chlamydiales*: three PCR tests. *Journal of Clinical Microbiology* 37: 575–580.

- GIACOMETTI, M., J. NICOLET, J. FREY, M. KRAWINKLER, W. MEIER, M. WELLE, AND M. P. DEGIORGIS. 1998. Susceptibility of alpine ibex to conjunctivitis caused by inoculation of a sheep-strain of *Mycoplasma conjunctivae*. *Veterinary Microbiology* 61: 279–288.
- HEWINSON, R. G., P. C. GRIFFITHS, B. J. BEVAN, S. E. S. KIRWAN, M. E. FIELD, M. J. WOODWARD, AND M. DAWSON. 1997. Detection of *Chlamydia psittaci* DNA in avian clinical samples by PCR. *Veterinary Microbiology* 54: 155–166.
- JOHANSSON, K. 1996. Phylogeny of some mycoplasmas from ruminants based on 16S rRNA sequences and definition of a new cluster within hominis group. *International Journal of Systematic Bacteriology* 46: 1093–1098.
- JONES, G. E. 1991. Infectious keratoconjunctivitis. In *Diseases of sheep*, W. B. Martin and I. D. Aitken (eds.). Blackwell Scientific Publications, London, UK, pp. 280–283.
- KRAUSMAN, P. R., J. J. HERVERT, AND L. L. ORDWAY. 1985. Capturing deer and mountain sheep with a net-gun. *Wildlife Society Bulletin* 13: 71–73.
- LOISON, A., J. M. GAILLARD, AND J. M. JULLIEN. 1996. Demographic patterns after an epizootic of keratoconjunctivitis in a chamois population. *Journal of Wildlife Management* 60: 517–527.
- MAYER, D., M. P. DEGIORGIS, W. MEIER, J. NICOLET, AND M. GIACOMETTI. 1997. Lesions associated with infectious keratoconjunctivitis in alpine ibex. *Journal of Wildlife Diseases* 33: 413–419.
- MEAGHER, M., W. J. QUINN, AND L. STACKHOUSE. 1992. Chlamydial-caused infectious keratoconjunctivitis in bighorn sheep of Yellowstone National Park. *Journal of Wildlife Diseases* 28: 171–176.
- QUINN, P. J., M. E. CARTER, B. MARKEY, AND G. R. CARTER (eds.). 1994. *Clinical veterinary microbiology*. Mosby-Year Book Europe Limited, London, UK, 290 pp.
- SHEEHY, N., B. MARKEY, M. GLEESON, AND P. J. QUINN. 1996. Differentiation of *Chlamydia psittaci* and *C. pecorum* strains by species-specific PCR. *Journal of Clinical Microbiology* 34: 3175–3179.
- TAYLOR, S. K., V. G. VIEIRA, E. S. WILLIAMS, R. PILKINGTON, S. L. FEDORCHAK, K. W. MILLS, J. L. CAVENDER, A. M. BOERGER-FIELDS, AND R. E. MOORE. 1996. Infectious keratoconjunctivitis in free-ranging mule deer (*Odocoileus hemionus*) from Zion National Park, Utah. *Journal of Wildlife Diseases* 32: 326–330.
- THORNE, E. T. 1982. Infectious keratoconjunctivitis. In *Diseases of wildlife in Wyoming*, E. T. Thorne, N. Kingston, W. R. Jolley, and R. C. Bergstrom (eds.). Wyoming Game and Fish Department, Cheyenne, Wyoming, pp. 81–84.
- UEMORI, T., K. ASADA, I. KATO, AND R. HARASAWA. 1992. Amplification of the 16S–23S spacer region in the rRNA operons of *Mycoplasmas* by the polymerase chain reaction. *Systematic Applied Microbiology* 15: 181–186.
- VAN HALDEREN, A., W. J. J. VAN RENSBURG, A. GEYER, AND J. H. VORSTER. 1994. The identification of *Mycoplasma conjunctivae* as an aetiological agent of infectious keratoconjunctivitis of sheep in South Africa. *Onderstepoort Journal of Veterinary Research* 61: 231–237.
- WHITFORD, H. W., R. F. ROSENBUSCH, AND L. H. LAUERMAN (eds.). 1994. *Mycoplasmosis of animals: Laboratory diagnosis*. American Association of Laboratory Diagnosticians and Iowa State University Press, Ames, Iowa, pp. 90–91.
- WHITE, G. C., AND R. A. GARROTT. 1990. *Analysis of wildlife radiotracking data*. Academic Press, San Diego, California, USA, 383 pp.

Received for publication 21 February 2005.