

## **AVIAN VACUOLAR MYELINOPATHY OUTBREAKS AT A SOUTHEASTERN RESERVOIR**

Authors: Fischer, John R., Lewis-Weis, Lynn A., Tate, Cynthia M., Gaydos, Joseph K., Gerhold, Richard W., et al.

Source: Journal of Wildlife Diseases, 42(3) : 501-510

Published By: Wildlife Disease Association

URL: <https://doi.org/10.7589/0090-3558-42.3.501>

---

BioOne Complete ([complete.BioOne.org](https://complete.BioOne.org)) is a full-text database of 200 subscribed and open-access titles in the biological, ecological, and environmental sciences published by nonprofit societies, associations, museums, institutions, and presses.

Your use of this PDF, the BioOne Complete website, and all posted and associated content indicates your acceptance of BioOne's Terms of Use, available at [www.bioone.org/terms-of-use](https://www.bioone.org/terms-of-use).

Usage of BioOne Complete content is strictly limited to personal, educational, and non - commercial use. Commercial inquiries or rights and permissions requests should be directed to the individual publisher as copyright holder.

---

BioOne sees sustainable scholarly publishing as an inherently collaborative enterprise connecting authors, nonprofit publishers, academic institutions, research libraries, and research funders in the common goal of maximizing access to critical research.

## AVIAN VACUOLAR MYELINOPATHY OUTBREAKS AT A SOUTHEASTERN RESERVOIR

John R. Fischer,<sup>1,5</sup> Lynn A. Lewis-Weis,<sup>1</sup> Cynthia M. Tate,<sup>1,3</sup> Joseph K. Gaydos,<sup>1,4</sup> Richard W. Gerhold,<sup>1</sup> and Robert H. Poppenga<sup>2</sup>

<sup>1</sup> Southeastern Cooperative Wildlife Disease Study, College of Veterinary Medicine, The University of Georgia, Athens, Georgia 30602, USA

<sup>2</sup> California Animal Health and Food Safety Laboratory, University of California–Davis, PO Box 1770, Davis, California 95617, USA

<sup>3</sup> Current address: Wyoming Department of Game and Fish, 1174 Snowy Range Road, Laramie, Wyoming 82070, USA

<sup>4</sup> Current address: Marine Ecosystem Health Program, University of California–Davis Wildlife Health Center, 982 Deer Harbor Rd., Eastsound, Washington 98245, USA

<sup>5</sup> Corresponding author (email: jfischer@vet.uga.edu)

**ABSTRACT:** Avian vacuolar myelinopathy (AVM) is a neurologic disease of unknown etiology that affects bald eagles (*Haliaeetus leucocephalus*), American coots (*Fulica americana*), and several species of waterfowl. An unidentified neurotoxin is suspected as the cause of AVM, which has been documented at several reservoirs in the southeastern United States. We conducted diagnostic and epidemiologic studies annually during October–March from 1998–2004 at Clarks Hill/Strom Thurmond Lake on the Georgia/South Carolina border to better understand the disease. Avian vacuolar myelinopathy was confirmed or suspected as the cause of morbidity and mortality of 28 bald eagles, 16 Canada geese (*Branta canadensis*), six American coots, two great-horned owls (*Bubo virginianus*), and one killdeer (*Charadrius vociferus*). Active surveillance during the outbreaks yielded annual average prevalence of vacuolar lesions in 17–94% of coots, but not in 10 beavers (*Castor canadensis*), four raccoons (*Procyon lotor*), and one gray fox (*Urocyon cinereoargenteus*) collected for the study. Brain lesions were not apparent in 30 Canada geese collected and examined in June 2002. The outbreaks at this location from 1998–2004 represent the most significant AVM-related bald eagle mortality since the Arkansas epornitics of 1994–95 and 1996–97, as well as the first confirmation of the disease in members of Strigiformes and Charadriiformes.

**Key words:** American coot, bald eagle, brain lesion, Canada goose, great-horned owl, intramyelinic edema, killdeer, myelinopathy, neurologic disease.

### INTRODUCTION

Avian vacuolar myelinopathy (AVM) is a neurologic disease that was first recognized as a cause of bald eagle mortality in the winter of 1994–95 when 29 eagles (*Haliaeetus leucocephalus*) were found dead or dying at DeGray Lake in southwestern Arkansas. During a 1996–97 winter outbreak in southwestern Arkansas, AVM was confirmed or suspected in 26 dead bald eagles, as well as in numerous American coots (*Fulica americana*), and it was hypothesized that eagles acquire AVM via ingestion of affected coots (Thomas et al., 1998). In 1998, AVM was found in an eagle and numerous coots, as well as in low numbers of mallards (*Anas platyrhynchos*), buffleheads (*Bucephala albeola*), and ring-necked ducks (*Aythya*

*collaris*) at Lake Surf (Woodlake), North Carolina. Furthermore, a retrospective review yielded records of clinical signs and neurologic lesions consistent with AVM in coots at Lake Surf in 1990 and 1995 (Augspurger et al., 2003). Through 2002, birds with AVM had been found at reservoirs in Arkansas, Georgia, North Carolina, South Carolina, and Texas (Fischer, unpubl. data). All observations of AVM in wild birds have occurred during the migratory and wintering season from October through April (Thomas et al., 1998; Augspurger et al., 2003).

Clinically, AVM is characterized by ataxia, reluctance to fly or erratic flight, inability to perch, colliding with stationary objects, and swimming in circles. Larsen et al. (2002) demonstrated that some coots displaying signs of AVM recover with

supportive care; however, brain lesions remain present following resolution of clinical signs. Lesions of AVM consist of mild to marked vacuolation of white matter of the central nervous system with a predilection for the optic tectum (Thomas et al., 1998). Rare involvement of peripheral nervous system white matter has been reported (Augspurger et al., 2003). Ultrastructural changes are consistent with intramyelinic edema within axonal sheaths and are characterized by vacuoles delimited by myelin laminae split at the intraperiod lines (Thomas et al., 1998).

The cause of AVM remains undetermined despite extensive diagnostic and research investigations. A natural or man-made neurotoxin is suspected because the pathologic lesions, epidemiology of outbreaks, and the apparent absence of infectious agents are all consistent with acute toxicosis (Thomas et al., 1998; Augspurger et al., 2003). Environmental exposure of water birds (coots and waterfowl) is believed to be the initial event in an AVM outbreak followed by consumption of affected birds by raptors. These theories have been proven experimentally. Lesions developed in coots and mallards within days of release at a reservoir during an AVM outbreak indicating that exposure to the AVM agent occurs at the site where affected birds are found (Rocke et al., 2002), and red-tailed hawks (*Buteo jamaicensis*) developed brain lesions after ingesting tissues from AVM-affected coots (Fischer et al., 2003).

Better characterization of AVM epidemiology will enhance the likelihood of determining the cause of this fatal neurologic disease of eagles, coots, and ducks. The objective of this study was to investigate AVM outbreaks in wild birds from 1998 through early 2004 at Clarks Hill/J. Strom Thurmond Lake (CHSTL) in order to further elucidate the epidemiology of AVM, including the species susceptibility range, prevalence among coots, temporal aspects, and potential for mammalian involvement.

## MATERIALS AND METHODS

Clarks Hill Lake, also known as J. Strom Thurmond Lake (CHSTL), is a 28,000-ha (70,000-acre) man-made reservoir located on the Georgia/South Carolina border (33°42'N, 82°20'W) and is the headwaters of the Savannah River. The reservoir is managed by the US Army Corps of Engineers (COE) and the fish and wildlife resources are managed in partnership with the Georgia and South Carolina Departments of Natural Resources (GDNr, SCDNR). The reservoir was constructed between 1948 and 1958 and provides hydroelectric power, flood control, and water supplies, as well as recreation.

Sick and dead wild birds from CHSTL were submitted by GDNr, SCDNR, and COE to the Southeastern Cooperative Wildlife Disease Study (SCWDS) for diagnostic testing. In addition to this passive surveillance system, SCWDS, GDNr, and COE conducted active surveillance from October–March, 1998–2004, by periodically collecting 15–30 coots at the lake (US Fish and Wildlife Scientific Collection Permit #MB779238-4, GDNr Permit #29-WSF-00-6, SCDNR Permit #G-00-16). The intent of the active surveillance was to document the temporal course of AVM outbreaks at CHSTL and to gather additional epidemiologic data. Prior to collection, coots were observed for clinical signs of AVM. Coots with clinical signs of AVM were collected using hand net or shotgun with number 6 steel shot. Additionally, coots with no apparent clinical signs were randomly collected using a shotgun because AVM lesions have been found in the brains of birds without clinical signs (Larson et al., 2002; Fischer et al., 2003). From December 2000 through February 2001, several mammals from areas on the Georgia side of the reservoir were collected using box traps and snares. In June 2002, 30 resident Canada geese (*Branta canadensis*) at CHSTL were collected, euthanized, and examined for brain lesions because AVM was found in 16 Canada geese during the previous two winters and little AVM surveillance had been conducted previously on any species during summer.

All live animals were handled according to protocols approved by the University of Georgia Animal Care and Use Committee. Live-captured mammals were manually restrained or chemically immobilized with an intramuscular injection of 20 mg/kg ketamine (Fort Dodge Animal Health, Overland Park, KS) and 4 mg/kg xylazine (Butler Company, Columbus, OH) (Kreeger et al., 2002). All live animals were humanely euthanized by an intravenous overdose of pentobarbital solution

(Beuthanasia®-D, Schering-Plough Animal Health Corporation, Union, NJ) or by cervical dislocation. For animals from active surveillance efforts, we recorded gender, weight, age, and fixed brain tissue for histology. These same data were collected from all clinical submissions; these animals also underwent a full external and internal exam, and the following tissues were collected and fixed for microscopic examination: brain, sciatic nerve, trachea, lung, heart, liver, spleen, kidney, adrenal gland, reproductive organs, skeletal muscle, gastrointestinal tract, and pancreas. For all animals, brain tissue was fixed in 10% buffered formalin, embedded in paraffin, sectioned at 3  $\mu$ m, and stained with hematoxylin and eosin for light microscopy. Additional tissues from passive surveillance animals were processed identically. The diagnosis of AVM was based on the presence of vacuoles in white matter of the central nervous system (CNS), specifically the cerebrum, optic lobe, cerebellum, brainstem, or spinal cord, in the absence of diffuse vacuolization of CNS gray and white matter, which was interpreted as autolysis.

Vacuolar lesions observed by light microscopy of brain from species in which AVM had not previously been documented were confirmed with transmission electron microscopy (TEM) of white matter of the optic lobe. Findings of intramyelinic edema were regarded as diagnostic (Thomas et al., 1998). Specimens collected for TEM were fixed in 2% glutaraldehyde–2% (para) formaldehyde–0.2% picric acid. Tissues were stored in 0.1 M cacodylate–HCL buffer, postfixed in 1% osmium tetroxide, stained with 0.5% uranyl acetate, and infiltrated with Epon–Araldite mixture. Semithin 1  $\mu$ m sections were stained with toluidine blue and examined by light microscopy to determine specimen orientation for TEM. Ultrathin sections were stained with 5% methanolic uranyl acetate and Reynold's lead citrate and examined using a JEM-1210 transmission electron microscope (JOEL USA, Peabody, MA).

In addition to microscopic examination, testing for viral and bacterial infections, botulinum toxin, and contaminants, including heavy metals and pesticides, was conducted on all diagnostic case submissions, but not on animals collected during active surveillance. These tests were conducted to rule out causes of morbidity and mortality other than AVM, particularly in species in which AVM previously had not been diagnosed. Brain tissue samples from 50 diagnostic cases were submitted for West Nile virus isolation using African green monkey kidney cells (Lanciotti et al., 2000). Routine aerobic and anaerobic

cultures were performed on samples of liver, lung, and intestines from 16 cases. Samples were incubated at 42 C for 24 hours on a biplate of McConkey's agar and 5% bovine blood combined with an agar base (DISCO Laboratories, Sparks, MD), as well as a plate of 5% bovine blood agar incubated under anaerobic conditions. Heart blood was collected from 13 cases for assay in a mouse protection test for the toxins of botulism types C, D, and E (Quortrup and Sudheimer, 1943). Complete blood cell counts and standard serum chemistry panels were performed on six diagnostic cases that arrived at SCWDS alive: two great-horned owls, one killdeer, and three Canada geese. Blood cell counts were performed manually and serum chemistries were performed using 0.5 ml of serum placed into automated Hitachi 912 analyzer (Boehringer Mannheim Corporation, Mannheim, Germany).

Organic chemical and heavy metal toxicology screens were performed on frozen samples collected in aluminum foil from 27 diagnostic cases (two owls, one killdeer, 16 Canada geese, and eight bald eagles). Liver, fat, and gastrointestinal contents were screened for organophosphate insecticides; carbamates; organochlorine (OC) insecticides; and polychlorinated biphenyl (PCB) congeners 77, 123, 144, 105, 126, 156, 157, 167, 169, and 189; as well as a number of therapeutic and illicit drugs, euthanasia agents and environmental contaminants, in order to rule out agents previously associated with wildlife morbidity and mortality.

Analysis for OC and PCB were completed on gas chromatography equipped with two electron capture detectors (GC/ECD) (Holstege et al., 1994). Carbamate analysis was done by liquid chromatography/mass spectrometry (LC/MS), and all other organic screening was completed with gas chromatography/mass spectrometry (GC/MS). Tissue metal analyses were performed by inductively coupled plasma atomic emission spectrometry (ICP–AES). To ensure proper instrument operation and accuracy of the results, a standard reference material (1577b) with certified mineral values from a National Institute of Standards and Technology was analyzed prior to analysis of any tissue samples involved in this study. All samples were analyzed on tissue wet weight basis and positive results were reported in parts per million (ppm).

## RESULTS

Vacuolar lesions were found in the brains of coots collected for active surveil-

TABLE 1. Monthly distributions of AVM lesion prevalence in coots collected during active surveillance activities and submission of diagnostic accessions to the Southeastern Cooperative Wildlife Disease Study from Clarks Hill/J. Strom Thurmond Lake, October–March, 1998–2004.

Year	Month						Mean
	Oct	Nov	Dec	Jan	Feb	Mar	
1998–99							
Prevalence <sup>a</sup>	NC <sup>b</sup>	NC	NC	25%	18%	NC	19%
Accessions <sup>c</sup>			1E				
1999–2000							
Prevalence	NC	100%	100%	NC	86%	44%	79%
Accessions							
2000–01							
Prevalence	NC	94%	100%	100%	100%	90%	94%
Accessions		4E, 2G, 4C	9E, 1O, 1K	1E, 1O	1E	1E	
2001–02							
Prevalence	48%	68%	98%	96%	99%	64%	78%
Accessions	1G	2E, 13G, 2C	3E	1E	1E		
2002–03							
Prevalence	NC	6%	77%	75%	77%	55%	61%
Accessions			2E	1E			
2003–04							
Prevalence	0%	22%	7%	50%	NC	3%	17%
Accessions				1E			

<sup>a</sup> Prevalence is based on a sample size of 15–30 birds. Collection of coots was biased towards birds with clinical signs of AVM and these do not represent randomly collected samples.

<sup>b</sup> NC = Active surveillance not conducted.

<sup>c</sup> C = American Coot; E = Bald Eagle; G = Canada Goose; O = Great-horned Owl; K = Killdeer.

lance during AVM outbreaks at CHSTL. The prevalence of coots with observed AVM lesions ranged from 0% to 100% among individual collections of 15–30 birds during the months from October–March of 1998–2004 (Table 1). Brain lesions were not observed in 10 beavers, four raccoons (*Procyon lotor*), and one gray fox (*Urocyon cinereoargenteus*) collected and examined during AVM outbreaks. Consumption of coots by mammals at CHSTL during AVM outbreaks was confirmed by the presence of coot tissues in the gastrointestinal contents of one raccoon and one gray fox. Brain lesions were not apparent in 30 Canada geese collected for microscopic examination in June, 2002.

During October–March from 1998 through 2004, one beaver and 54 birds representing seven avian species were found sick or dead at CHSTL and were submitted to SCWDS for diagnostic eval-

uation. Avian vacuolar myelinopathy was confirmed (39) or suspected (14) as the cause of neurologic disease or death in 53 of these animals (Table 1 and Fig. 1). Confirmed AVM diagnoses in 15 bald eagles, six coots, 15 Canada geese, two great-horned owls (*Bubo virginianus*), and one killdeer (*Charadrius vociferus*) were based on the presence of vacuolar lesions in CNS of carcasses with little or no postmortem decomposition, and the absence of other apparent causes. Ultrastructural lesions of intramyelinic edema were observed in two bald eagles, two owls, two Canada geese, and one killdeer examined by TEM.

Suspected cases of AVM in 13 partially decomposed bald eagles and one Canada goose were based on the absence of other apparent causes of death, as well as on concurrent confirmation of AVM in eagles and geese at CHSTL. Although vacuolar lesions were present in the white matter of

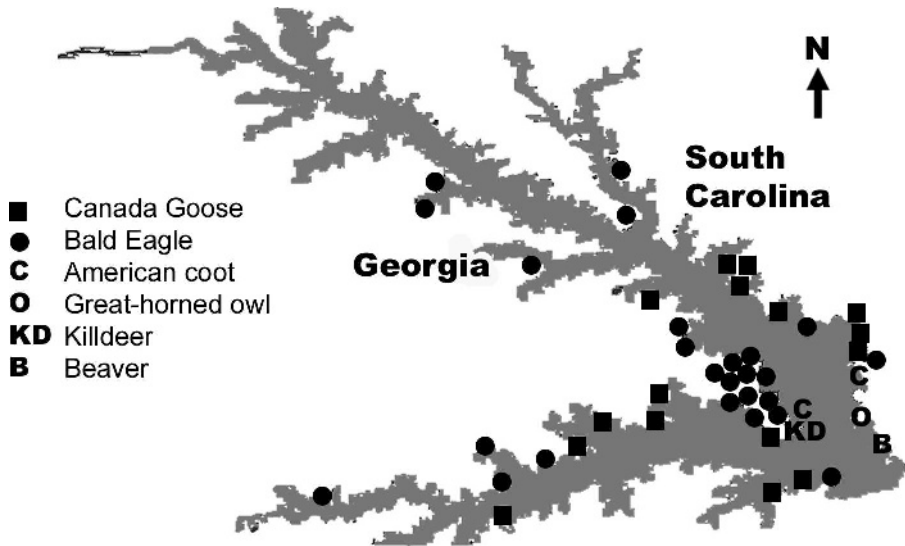


FIGURE 1. Approximate locations of diagnostic accessions submitted to the Southeastern Cooperative Wildlife Disease Study during avian vacuolar myelinopathy outbreaks at Clarks Hill/J. Strom Thurmond Lake, October–March, 1998–2004. Specific locations for four American coots and one bald eagle were not listed in the diagnostic case reports. One great-horned owl and two bald eagles were found seven, six, and twelve miles south of the lake on or near the Savannah River, respectively.

the brain and spinal cord of a beaver (*Castor canadensis*) found alive with CNS signs in November 2001, the cause of the signs could not be confirmed as vacuolar myelinopathy because of postmortem decomposition that occurred prior to submission of the carcass to SCWDS.

Diagnostic accessions with confirmed or suspected AVM were submitted in all months from October–March; however, the majority of birds (49) were submitted November–January, with 27 in November alone. In confirmed cases of AVM in which gender and age could be determined by examination of gonads and plumage; seven bald eagles were adults ( $\geq 5$  years old), nine were immature, seven were male, and six were female. Fourteen of the Canada geese were adult; seven were male, and seven were female. The two great-horned owls were adult females, and the killdeer was an adult male.

Nine birds were submitted alive and were evaluated clinically prior to euthanasia. Two great-horned owls showed severe clinical signs of CNS disease including

inability to perch, ambulate, or right themselves; anisocoria with rapid fluctuation in pupil diameter in the absence of changes in light stimuli; muscular rigidity; and opisthotonus (Fig. 2). Clinical signs observed in the Canada geese and the killdeer were milder and included inability to fly and difficulty or inability to swim, walk, or stand.

Consistent abnormalities were not apparent in results of complete blood cell counts and serum chemistry panels performed on two American coots, two great-horned owls, one Canada goose, and one killdeer with AVM. Although six bald eagles had elevated kidney mercury levels, consistent and significant levels of toxic compounds and metals were not found in the 16 eagles, eight Canada geese, two owls, and one killdeer that were analyzed.

## DISCUSSION

The loss of 28 bald eagles over a six year period at CHSTL represents the largest AVM-associated eagle mortality since the deaths of 55 eagles near DeGray Lake,



FIGURE 2. Great-horned owl with clinical signs of severe neurological disease associated with avian vacuolar myelinopathy.

Arkansas during the winters of 1994–95 and 1996–97. The outbreaks at CHSTL also are significant because AVM was confirmed in three new species (Canada goose, great-horned owl, and killdeer). Although the recognized range of species susceptible to vacuolar myelinopathy continues to expand, AVM was not confirmed in the small numbers of three species of mammals examined in this study. Although the severity of outbreaks varied from year to year, all confirmed or suspected AVM cases occurred from October through March in each year from 1998–2004.

Although the etiology of AVM remains unknown, it is believed that birds such as coots, ducks, and geese are exposed by ingesting a naturally occurring toxin associated with submerged vegetation. Brain lesions recently have been experimentally produced in chickens (Lewis-Weis et al., 2004) and mallards (Birrenkott et al., 2004) by feeding them aquatic vegetation collected from CHSTL during AVM events. At CHSTL, the predominant submerged plant is hydrilla (*Hydrilla verticillata*), an exotic aquatic plant that frequent-

ly is found in southeastern reservoirs. Hydrilla alone does not appear to be the cause of AVM because hydrilla was not present at DeGray Lake, Arkansas during the AVM events from 1994–97, nor did brain lesions develop in chickens that consumed hydrilla collected from a lake at which AVM never has been documented (Lewis-Weis et al., 2004). American coots typically feed on aquatic vegetation, and during the summer on aquatic insects and mollusks, but fly-catching, scavenging, and terrestrial grazing also have been reported (Alisauskas and Arnold, 1994; Yee, 2001). Consumption of hydrilla by coots at CHSTL was observed during our field investigations and hydrilla was recovered from their gastrointestinal tracts. Canada geese consume both terrestrial (Bell and Klimstra, 1970; Sedinger and Raveling, 1984; Conover and Kania, 1991) and aquatic vegetation (Reed, 1976; Erskine, 2000), and we believe they acquired AVM by ingesting the submerged vegetation at CHSTL.

Killdeer feed mainly on terrestrial invertebrates; however, vegetation is consumed on occasion (Jackson and Jackson, 2000). During the epornitics at CHSTL from 1998–2004, water levels were at times 0.6–4.3 m below full pool (US Army Corp of Engineers, lake level records). As water levels dropped, large surface mats of hydrilla were exposed in shallow bays and coves. Killdeer were observed on these mats and we believe they were exposed to the AVM agent via consumption of the plant as well as the materials associated with it.

In laboratory trials, AVM lesions developed following consumption of other birds with AVM or aquatic vegetation at lakes where AVM is occurring. Red-tailed hawks developed brain lesions after consuming tissues from coots with AVM (Fischer et al., 2003), and these findings explain a potential route of exposure to the AVM agent for raptors, such as great-horned owls and bald eagles. Both of these species feed on coots (Houston et al.,

1998; Sobkowiak and Titman, 1989), sick animals, and carrion (Smith, 1974; Johnsgard, 1990). We observed varying numbers of sick or dead coots and Canada geese at CHSTL, and small to large numbers of clinically affected and dead coots have been observed at other lakes during AVM events (Thomas et al., 1998; Augspurger et al., 2003).

Lesions of vacuolar myelinopathy were not confirmed in mammals at CHSTL, despite concurrent active surveillance among animals consuming aquatic vegetation (beavers), as well as mammals (raccoon and gray fox) that can consume sick or dead coots. In fact, we found undigested parts of coot carcasses in stomachs of two of the animals examined. Mammalian surveillance during an AVM outbreak at Woodlake, North Carolina also failed to detect lesions in muskrat (*Ondatra zibethicus*) and beaver (T. Rocke, pers. comm.). Additionally, recent laboratory trials attempting to produce vacuolar myelinopathy lesions in young pigs were unsuccessful (Lewis-Weis et al., 2004). However, the observation of neurologic signs and death in beavers during AVM outbreaks, including one beaver at CHSTL in November 2001, warrants continued surveillance and research regarding potential mammalian susceptibility.

Results of serum chemistry, metal, micronutrient, and contaminant analyses were inconsistent and did not suggest a cause for AVM or a target organ. Four birds had elevated LDH and/or AST levels, but microscopic lesions were not observed in liver or muscle from them, and elevated LDH and AST levels were not apparent in coots with AVM when compared to coots without brain lesions (Larsen et al., 2002), nor in red-tailed hawks with AVM (Fischer et al., 2003). The inconsistent findings in our study and others indicate that serum chemistries are not useful as a diagnostic tool for AVM.

Six of 16 bald eagles tested had elevated Hg and/or Se levels. Elevated Hg levels previously have been documented in

several bald eagles from CHSTL (Jagoe et al., 2002), as well as throughout the Southeast (Wood et al., 1996). Two eagles in our study had kidney Hg levels >40 ppm, and Hg toxicosis has been reported in red-tailed hawks with liver levels of 16.7–20.0 ppm (Fimreite and Karstad, 1971). Additionally, vacuolization of central and peripheral nervous system has been observed with Hg toxicosis in birds (Heinz, 1996). However, we believe that AVM, rather than Hg toxicosis, was the most probable cause of death in these birds, because of the inconsistency of elevated Hg levels in our study and others.

There was annual variation in the severity of AVM outbreaks at CHSTL, as indicated by the numbers of impaired and dead birds observed and submitted for diagnostic testing. Documented bald eagle mortality ranged from one bird per season to 16 eagles during the winter of 2000–01. This was the most severe AVM outbreak at CHSTL involving 25 diagnostic cases and the highest annual mean prevalence (94%) of AVM lesions in coots from active surveillance at CHSTL. There also were far more sick and dead coots seen on CHSTL in 2000–01 than were seen in previous or subsequent years (L. Lewis-Weis, unpubl. data).

Although annual severity of outbreaks varied, all cases of suspected or confirmed AVM at CHSTL were identified during the months of October through March, with the majority (49) of our AVM diagnostic accessions submitted from November–January. This temporal distribution of AVM has been observed previously in diagnostic investigations (Thomas et al., 1998; Augspurger et al., 2003), and field studies (Rocke et al., 2002). We found AVM lesions in actively collected coots as early as 30 October and as late as 25 April; additionally, we did not observe lesions in 30 Canada geese collected at CHSTL in June 2002 despite the diagnosis of AVM in 14 geese the previous winter. This seasonality could reflect the abundance of wintering migratory birds, including coots



and eagles, at CHSTL during the migratory and wintering season, but we believe it more likely is an indication of seasonal exposure to the cause of AVM. The absence of AVM in diagnostic accessions or actively collected birds from CHSTL during the remainder of the year and results of previous sentinel bird studies (Rocke et al., 2002), strongly suggest that exposure to the cause of AVM occurs during the autumn and winter.

We believe the spatial distribution of AVM cases at CHSTL more likely reflects the distribution of birds rather than locations at which they were exposed to the causative agent. Current evidence indicates exposure to the cause of AVM occurs at the same reservoir where affected birds are found (Rocke et al., 2002). However, at a large reservoir such as CHSTL (28,000 ha/70,000 acres), it is not possible to determine precise locations where exposure might occur, due to the mobility and uneven distribution of the affected species, potential variation in abundance of the cause of AVM throughout the lake, and uncertainty regarding potential dose-dependence and incubation times for development of clinical signs or death. Diagnostic cases submitted during the epornitics at CHSTL were relatively evenly dispersed at the lake (Fig. 1), as were coots with AVM that we actively collected. However, we did observe some clustering, particularly of bald eagle mortalities at Bussey Point, a peninsula jutting into the center of the lake. This location is a popular roosting site for eagles at the lake and finding several carcasses at this location more likely correlates with the amount of time the birds spend there rather than the proximity of coots or other birds with AVM that might have been consumed by the eagles. Although one great-horned owl and two bald eagles were found seven, twelve, and six miles south of the lake, respectively, we believe they were exposed by ingesting coots or other birds that acquired AVM at or near CHSTL.

Despite down-listing of bald eagles from endangered to threatened status in 1995, and the proposal to de-list in 2000 (USFWS, Federal Register, Vol. 60, No. 133), some local populations, including several in the southeastern United States, are still relatively low compared to other parts of North America. In these populations, an AVM epornitic could have significant population impacts, particularly when nesting eagles are affected. During the AVM epornitic documented in 1994–95 and 1996–97 at DeGray Lake, Arkansas, it is estimated that 30–65% of the wintering bald eagle population might have died (Thomas et al., 1998). Occupied bald eagle nesting territories have steadily increased from 13 to 181 in South Carolina and from one to 81 in Georgia from 1978–2003 (T. Murphy and J. Ozier, pers. comm.). The loss of 28 individuals from one lake can have considerable impacts on a local population, particularly if these are resident birds and this mortality rate continues for an extended period of time. These numbers emphasize the urgency of identifying the etiologic agent of AVM, its source, the mechanism of exposure, and any practices useful in limiting wildlife exposure.

#### ACKNOWLEDGMENTS

Primary funding for this work was provided by the U.S. Department of the Interior through Grant Agreement 01ERAGOO13 with the Biological Resources Division of the US Geological Survey and by the wildlife management agencies of Alabama, Arkansas, Florida, Georgia, Kansas, Kentucky, Louisiana, Maryland, Mississippi, Missouri, North Carolina, Puerto Rico, South Carolina, Tennessee, Virginia, and West Virginia. SCWDS support from the states was provided by the Federal Aid to Wildlife Restoration Act (50 Stat. 917). Additional financial support was received from the Arcadia Wildlife Preserve, Inc. and the Disney Wildlife Conservation Fund. We thank D. Brady, L. Brewster, A. Dean, D. Williamson, and S. Williard of the COE; D. Hoffman of USDA, APHIS, Wildlife Services; V. VanSant and H. Barnhill, GDNr; and R. Gooding, SCDNR for assistance with active surveillance and submission of diagnos-

tic cases. Numerous SCWDS personnel assisted with all aspects of this project and M. Ard provided expertise with transmission electron microscopy.

# LITERATURE CITED

- ALISAUSKAS, R. T., AND T. W. ARNOLD. 1994. American Coot. In *Migratory shore and upland gamebird management in North America*, T. C. Tacha and C. E. Braun (eds.). The International Association of Fish and Wildlife Agencies, Washington, D.C., pp. 127–143.
- AUGSPURGER, T., J. R. FISCHER, N. J. THOMAS, L. SILEO, R. E. BRANNIAN, K. J. G. MILLER, AND T. E. ROCKE. 2003. Vacuolar myelinopathy in waterfowl from a North Carolina impoundment. *Journal of Wildlife Diseases* 39: 412–417.
- BELL, R. Q., AND W. D. KLIMSTRA. 1970. Feeding activities of Canada geese in southern Illinois. *Transactions of the Illinois Academy of Science* 63: 295–304.
- BIRRENKOTT, A. H., S. B. WILDE, J. J. HAINS, J. R. FISCHER, T. M. MURPHY, C. P. HOPE, P. G. PARNELL, AND W. W. BOWERMAN. 2004. Establishing a food-chain linkage between aquatic plant material and avian vacuolar myelinopathy in mallard ducks (*Anas platyrhynchos*). *Journal of Wildlife Diseases* 40: 486–492.
- CONOVER, M. R., AND G. S. KANIA. 1991. Characteristics of feeding sites used by urban-suburban flocks of Canada geese in Connecticut. *Wildlife Society Bulletin* 19: 36–38.
- ERSKINE, A. J. 2000. Canada geese in the Maritime Provinces. In *Towards conservation of the diversity of Canada geese (Branta canadensis)*, K. M. Dickson (ed.). Canada Wildlife Service, Occasional Paper #103, pp. 85–89.
- FIMREITE, N., AND L. KARSTAD. 1971. Effects of dietary methyl mercury on red-tailed hawks. *Journal of Wildlife Management* 35: 292–300.
- FISCHER, J. R., L. A. LEWIS-WEIS, AND C. M. TATE. 2003. Experimental vacuolar myelinopathy in red-tailed hawks. *Journal of Wildlife Diseases* 39: 400–406.
- HEINZ, G. H. 1996. Mercury poisoning in wildlife. In *Noninfectious diseases of wildlife*, A. Fairbrother, L. Locke and G. Hoff (eds.). Iowa State University Press, Ames, Iowa, pp. 118–127.
- HOLSTEGE, D. M., D. L. SCHARBERG, E. R. TOR, L. C. HART, AND F. D. GALEY. 1994. A rapid multi-residue screen for organophosphorus, organochlorine, and N-methyl carbamate insecticides in plant and animal tissues. *Journal of Association of Analytical Communities International* 77: 1263–1274.
- HOUSTON, C. S., D. G. SMITH, AND C. ROHNER. 1998. Great-horned owl (*Bubo virginianus*). In *The birds of North America*, No. 372, A. Poole and F. Gill (eds.). The Birds of North America, Inc., Philadelphia, Pennsylvania, pp. 1–28.
- JACKSON, B. J. S., AND J. A. JACKSON. 2000. Killdeer (*Charadrius vociferus*). In *The birds of North America*, No. 517, A. Poole and F. Gill (eds.). The Birds of North America, Inc., Philadelphia, Pennsylvania, pp. 1–27.
- JAGOE, C. H., A. L. BRYAN, JR., H. A. BRANT, T. M. MURPHY, AND I. L. BRISBIN, JR. 2002. Mercury in bald eagle nestlings from South Carolina, USA. *Journal of Wildlife Diseases* 38: 706–712.
- JOHNSGARD, P. A. 1990. Hawks, eagles, and falcons of North America. Smithsonian Institution Press, Washington, D.C. and London, UK, 464 pp.
- KREEGER, T. J., J. M. ARNEMO, AND J. P. RAATH. 2002. Drug doses. In *Handbook of wildlife chemical immobilization*, T. J. Kreeger, J. M. Arnemo and J. P. Raath (eds.). Wildlife Pharmaceuticals, Inc., Fort Collins, Colorado, pp. 142–276.
- LANCIOTTI, R. S., A. J. KERST, R. S. NASCI, M. S. GODSEY, C. J. MITCHELL, H. M. SAVAGE, N. KOMAR, N. A. PANELLA, B. C. ALLEN, K. E. VOLPE, B. S. DAVIS, AND J. T. ROEHRIG. 2000. Rapid detection of West Nile virus from human clinical specimens, field-collected mosquitoes, and avian samples by a taqman reverse transcriptase-PCR assay. *Journal of Clinical Microbiology* 38 (11): 4066–4071.
- LARSON, R. S., F. B. NUTTER, T. AUGSPURGER, T. E. ROCKE, L. TOMLINSON, N. J. THOMAS, AND M. K. STOSKOPF. 2002. Clinical features of avian vacuolar myelinopathy in American coots. *Journal of American Veterinary Medical Association* 221: 80–85.
- LEWIS-WEIS, L. A., R. W. GERHOLD, AND J. R. FISCHER. 2004. Attempts to reproduce vacuolar myelinopathy in domestic swine and chickens. *Journal of Wildlife Diseases* 40: 476–484.
- QUORTRUP, E. R., AND R. L. SUDHEIMER. 1943. Detection of botulism toxin in the blood stream of wild ducks. *Journal of American Veterinary Medical Association* 102: 264–266.
- REED, A. A. 1976. Geese, nutrition, and farmland. *Wildfowl* 27: 153–156.
- ROCKE, T., N. J. THOMAS, T. AUGSPURGER, AND K. MILLER. 2002. Epizootologic studies of avian vacuolar myelinopathy in waterbirds. *Journal of Wildlife Diseases* 38: 678–684.
- SEDINGER, J. S., AND D. G. RAVELING. 1984. Dietary selectivity in relation to availability and quality of food for goslings of cackling geese. *Auk* 101: 295–306.
- SMITH, D. G. 1974. Great-horned owl feeding on a road kill. *Canadian Field Naturalist* 88: 96.
- SOBKOWIAK, S., AND R. D. TITMAN. 1989. Bald eagles killing American coots and stealing coot carcasses from greater black-backed gulls. *Wilson Bulletin* 101 (3): 494–496.
- THOMAS, N. J., C. U. METEYER, AND L. SILEO. 1998. Epizootic vacuolar myelinopathy of the central

- nervous system of bald eagles (*Haliaeetus leucocephalus*) and American coots (*Fulica americana*). *Veterinary Pathology* 35: 479–487.
- WOOD, P. B., J. H. WHITE, A. STEFFER, J. M. WOOD, C. F. FACEMIRE, AND H. FRANKLIN PERCIVAL. 1996. Mercury concentrations in tissues of Florida bald eagles. *Journal of Wildlife Management* 60: 178–185.
- YEE, C. G. 2001. Diet composition and changes in body components of American coots wintering in southwestern Arkansas. MS Thesis. Texas A&M University–Kingsville, Texas, 80 pp.

*Received for publication 21 July 2004.*