

SURVEILLANCE FOR BATRACHOCHYTRIUM DENDROBATIDIS USING MIXOPHYTES (ANURA: MYOBATRACHIDAE) LARVAE

Authors: Symonds, Emma P., Hines, Harry B., Bird, Philip S., Morton, John M., and Mills, Paul C.

Source: Journal of Wildlife Diseases, 43(1) : 48-60

Published By: Wildlife Disease Association

URL: <https://doi.org/10.7589/0090-3558-43.1.48>

BioOne Complete (complete.BioOne.org) is a full-text database of 200 subscribed and open-access titles in the biological, ecological, and environmental sciences published by nonprofit societies, associations, museums, institutions, and presses.

Your use of this PDF, the BioOne Complete website, and all posted and associated content indicates your acceptance of BioOne's Terms of Use, available at www.bioone.org/terms-of-use.

Usage of BioOne Complete content is strictly limited to personal, educational, and non - commercial use. Commercial inquiries or rights and permissions requests should be directed to the individual publisher as copyright holder.

BioOne sees sustainable scholarly publishing as an inherently collaborative enterprise connecting authors, nonprofit publishers, academic institutions, research libraries, and research funders in the common goal of maximizing access to critical research.

SURVEILLANCE FOR *BATRACHOCHYTRIUM DENDROBATIDIS* USING *MIXOPHYES* (ANURA: MYOBATRACHIDAE) LARVAE

Emma P. Symonds,^{1,4} Harry B. Hines,² Philip S. Bird,³ John M. Morton,¹ and Paul C. Mills¹

¹ School of Veterinary Science, The University of Queensland, St. Lucia 4072, Queensland, Australia

² Queensland Parks and Wildlife Service, PO Box 64, Bellbowrie 4070, Queensland, Australia

³ Oral Biology and Pathology, School of Dentistry, The University of Queensland, St. Lucia 4072, Queensland, Australia

⁴ Corresponding author (email: pearl66@bigpond.com.au)

ABSTRACT: Fourteen populations of anuran larvae (tadpoles), including three populations of the endangered Fleay's Barred Frog (*Mixophyes fleayi*) and 11 populations of the common Great Barred Frog (*Mixophyes fasciolatus*), in creek sites in the southeast region of Queensland were selected. Site selection was based on a history (within the district) of adult frog population declines and/or disappearances or records of infection of adult frogs or larvae by *Batrachochytrium dendrobatidis*. Larvae were collected once from each creek site between October 2002 and October 2004, and were between Gosner developmental stages 25 and 40. Total body length ranged from 18 mm to 100 mm. Mouthparts were examined under a dissecting microscope for grossly visible abnormalities, and then examined for histologic evidence of *B. dendrobatidis*. The most consistent mouthpart abnormalities found were multifocal depigmentation of the jaw sheaths and loss or shortening of the tooth rows. At the individual larva level, presence of mouthpart abnormalities was strongly associated with histologic diagnosis of *B. dendrobatidis* (93%). At least one larva with abnormal mouthparts was detected at 12 of the 14 sites and histologic evidence of *B. dendrobatidis* was detected at 13 of the 14 sites. These findings suggest that larvae of *Mixophyes* species are suitable for surveillance for *B. dendrobatidis*. We conclude that surveillance of *B. dendrobatidis* where individual larva prevalences of mouthpart abnormalities and histologic evidence of *B. dendrobatidis* are as high as those observed in this study (66% and 78%, respectively), relatively small numbers of larvae are required to detect these infections. Medium to large larvae (body length >30 mm) were much more likely to be affected than small larvae (body length ≤30 mm), suggesting that larger individuals should be targeted for surveillance.

Key words: Anuran larvae, *Batrachochytrium dendrobatidis*, chytridiomycosis, *Mixophyes fasciolatus*, *Mixophyes fleayi*, mouthparts, surveillance.

INTRODUCTION

Batrachochytrium dendrobatidis is a recently described zoosporic fungal pathogen (Longcore et al., 1999) that has been a causative factor in a number of post metamorphic frog mortality events since 1996 (Green et al., 2002). It has been detected in a wide range of captive and wild amphibian species in Central America, Australia (Berger et al., 1998), North America (Bradley et al., 2002; Muths et al., 2003; Oullett et al., 2005), South America (Bonaccorso and Guayasamin, 2003), Africa (Welden et al., 2004), Europe (Martinez-Solano et al., 2003; Cunningham et al., 2005), and more recently, New Zealand (Bell et al., 2004).

Batrachochytrium dendrobatidis is a member of the phylum Chytridiomycota,

a group of fungi characterized by the production of infective motile zoospores (Barr, 2001). Many species in this phylum are aquatic fungi that are waterborne or rely on moist surfaces to transfer between hosts or substrate of choice. Adult frogs and larvae have been infected through contact with contaminated water (Nichols et al., 2001), but to date, *B. dendrobatidis* zoospores or sporangia have not been detected in water (McCallum, 2005). Under laboratory conditions, zoospores travel an average of 2 cm and most have formed early stage sporangia by 24 hr (Piotrowski et al., 2004). The zoospores of *B. dendrobatidis* do not form a thick-walled or hardy resting phase (Longcore et al., 1999), but the sessile reproductive stage (the sporangia) can attach to a number of aquatic substrates, and remain infective up to

7 wk in sterilized lake water (Johnson and Speare, 2003) and up to 3 mo in sterilized river sand (Johnson and Speare, 2005). *Batrachochytrium dendrobatidis* typically forms localized colonies in host tissue and in the adult frog targets the outer layers of skin, with a predilection for the skin of the toes, inside the thighs and ventral abdomen. In anuran larvae, it is only found in the oral disc (Berger et al., 2000), which is comprised of a number of specialized mouthpart structures (McDiarmid and Altig, 1999). In the larval life stage, it grows in the epithelium of keratinized mouthparts, including tooth rows, jaw sheaths, buccal cavity, and occasionally the marginal papillae (Berger, 2001).

Among larval species from continents other than Australia, the extent of keratinization varies from elaborate keratinized suction discs on the body to no keratin at all as found in the larvae of *Xenopus* (McDiarmid and Altig, 1999). In contrast, most anuran larvae found in Australia possess keratinized mouthparts. The mouthparts of anuran larvae become keratinized at Gosner developmental stage 25 and are completely lost just before completion of metamorphosis at around stage 41 (Anstis, 2002). The larvae of most Australian frogs are usually confined to aquatic ecosystems and feed on a variety of substrates either as grazers or filter feeders. When this life stage is infected with *B. dendrobatidis*, the risk of mortality does not appear to be increased even though infection has been associated with smaller body size at metamorphosis and reduced adaptive behavior (Parris and Beaudoin, 2004). In contrast, disease caused by infection with *B. dendrobatidis* (chytridiomycosis) is reported to have caused up to 100% mortality within 30–40 days of metamorphosis in captive colonies (Berger, 2001; Mazzoni, 2003). During Gosner stages 41–43, when the keratinized mouthparts are lost naturally, larvae infected with *B. dendrobatidis* develop lesions on the toes and regressing tail bud; these are the first skin areas to

become newly keratinized (Berger, 2001). In both wild and captive populations, larvae have persisted when adults and subadults have died from chytridiomycosis (Berger et al., 1998; Lips, 1999; Bosch et al., 2001) and *B. dendrobatidis* has been cultured from the mouthparts of the surviving larvae (Fellers et al., 2001; Bradley et al., 2002).

The earliest record of *B. dendrobatidis* in Australia is from southeast Queensland in an adult *Litoria gracilentia* from the Conondale Ranges in 1978 (Speare and Berger, 2000). However, although adult mortality events in this region have been recorded (Berger et al., 2004), surveillance has not been conducted to describe the distribution of *B. dendrobatidis*. Understanding the geographical distribution of an infectious organism is essential when planning disease control strategies. Surveillance for *B. dendrobatidis* is of particular importance in this region because there are at least three species endemic to the bioregion that are recognized as potentially threatened by chytridiomycosis (Hero and Morrison, 2004).

Until recently, detection of *B. dendrobatidis* in amphibian adults has relied on post mortem examination or histologic examination of toes clipped from live or preserved adult specimens (Berger et al., 2000). For anuran larvae, histologic examination of sacrificed specimens (either serial sectioning of the entire oral disc region or examination of a single section) is a suitable method for detection of *B. dendrobatidis* (Rachowitz and Vrendenberg, 2004; Woodhams and Alford, 2005). The size, shape, and location of intracellular sporangia typical of *B. dendrobatidis* are highly specific. In larvae with low numbers of sporangia (as occurs in recently infected animals), an immunohistologic method using specific polyclonal or monoclonal antibodies can improve sensitivity (Berger et al., 2002). Molecular techniques have been described recently with reports of both a conventional polymerase chain reaction (PCR) assay (Annis

et al., 2004) and a quantitated/real-time PCR assay (Boyle et al., 2004). These methods are considered to have a higher sensitivity than histology and can be applied to live adult amphibians, although a satisfactory methodology for use on live anuran larvae is yet to be developed.

In some situations, larval sampling can have advantages over other methods. The larvae of the genus *Mixophyes* (Gunther, 1864: Anura, Myobatrachidae) are present in mountain streams in southeast Queensland throughout the year and Berger (2001) showed that *Mixophyes* larvae carry *B. dendrobatidis* in their mouthparts. They are large (maximum total length in excess of 80 mm; Anstis, 2002), easy to find and capture, and are typically many times more numerous than adults. These larvae have large, strongly-pigmented keratinized mouthparts that allow easy observation of morphological abnormalities. The presence of *B. dendrobatidis* in *Mixophyes* is of particular importance because post-metamorphic frogs of the genus *Mixophyes* are vulnerable to chytridiomycosis (Berger et al., 1998; Berger, 2001). Three species of *Mixophyes* in southeastern Australia are considered endangered and *B. dendrobatidis* has been implicated in their decline (Speare, 2006).

Direct visualization of larvae under magnification (i.e., to examine gross morphology) also can be of use as a surveillance tool. Researchers have noted abnormalities in the pigmentation of mouthparts of larvae at sites experiencing population decline associated with subsequent histologic evidence of *B. dendrobatidis* (Berger et al., 1998; Lips, 1999; Fellers et al., 2001; Rachowitz and Vrendenberg, 2004). Live and preserved larvae of the mountain yellow-legged frog (*Rana muscosa*) have been examined for abnormalities of the oral disc using a 10× hand lens (Fellers et al., 2001). Abnormalities reported included multifocal to complete depigmentation of jaw sheaths, missing tooth rows, and, in the case of live tadpoles, swollen and reddened marginal/labial papillae. Of 24

preserved larvae with these abnormalities, 16 had histologic evidence of *B. dendrobatidis* infection in the keratinized mouthparts.

The current study was designed to assess whether morphologic and subsequent histologic examination of the mouthparts of *Mixophyes* larvae are useful tools for determining whether *B. dendrobatidis* is present in anuran populations. Specific aims were: 1) to estimate the strength of association between mouthpart morphologic abnormalities and histologic evidence of *B. dendrobatidis*; 2) to estimate prevalence of both abnormal mouthparts and histologic evidence of *B. dendrobatidis* in *Mixophyes* larvae in districts previously affected by species decline and disappearance and/or infected adults in the southeast Queensland region; and 3) to assess associations between larval size and both the presence of abnormal mouthparts and histologic evidence of the presence of *B. dendrobatidis*.

MATERIALS AND METHODS

Fourteen creek sites were sampled; sites where selected based on the presence of *Mixophyes* species, a history (within the district) of adult frog population declines, and records of frog species disappearance and/or infected adults (Table 1). Thirteen sites were within the southeast Queensland bioregion (Sattler and Williams, 1999) in the montane districts of Main, McPherson, Conondale, and Blackall Ranges and Bunya Mountains. Altitudes ranged from 175 m to 990 m above sea level. An additional site at Eungella National Park, on the Clarke Range in mideast Queensland, is in the central Queensland coast bioregion (Sattler and Williams, 1999). Climate at all sites is typical of the subtropical climate zone (Bureau of Meteorology, 1989) and is characterized by mild winters and very warm to hot humid summers with moderate to high rainfall (over 1200 mm annually) falling predominantly in summer. Most sites support subtropical rainforests and/or wet sclerophyll forest communities.

Each site was visited once between October 2002 and October 2004 and between five and 11 larvae of either *Mixophyes fasciolatus* or *M. fleayi* were collected by dip netting in pools.

TABLE 1. Collection sites.

Reserve name ^a	Stream	Altitude (m)	Species of larvae collected	Latitude and longitude	Habitat code ^b	Species that have disappeared from district ^{c,d}	Species that are known or likely to have declined in district ^e	Species in district recorded with <i>B. dendrobatidis</i> ^f	No. of larvae collected	Number with grossly abnormal mouthparts	Number with histologic evidence of <i>B. dendrobatidis</i>
Bunya Mountains NP	Saddletree Ck	920	<i>M. fasciolatus</i>	26°52'S 151°36'E	STRF	<i>A. b.</i> , <i>M. fl.</i> , <i>M. it</i>	None	None	6	4	6
Bunya Mountains NP	Tim Shea Ck	990	<i>M. fasciolatus</i>	26°5'S 151°35'E	STRF	<i>A. b.</i> , <i>M. fl.</i> , <i>M. it</i>	None	None	10	10	8 ^f
Conondale NP	Bundaroo Ck	495	<i>M. fasciolatus</i>	26°42'S 152°37'E	STRF/WSF	<i>R. s.</i> , <i>T. d</i>	<i>M. fl.</i> , <i>M. it</i> , <i>L. p</i>	<i>L. p</i> , <i>L. w.</i> , <i>M. sp.</i> (larvae)	6	0	1
Conondale NP	East Kilcoy Ck	620	<i>M. fleayi</i>	26°43'S 152°34'E	STRF	<i>R. s.</i> , <i>T. d</i>	<i>M. fl.</i> , <i>M. it</i> , <i>L. p</i>	<i>L. p</i> , <i>L. w.</i> , <i>M. sp.</i> (larvae)	7	4	4
Delicia Rd CP	Gheerulla Ck	380	<i>M. fasciolatus</i>	26°36'S 152°50'E	WSF	<i>R. s.</i> , <i>T. d</i>	<i>L. p</i>	<i>L. w</i>	10	2	10
Eungella NP	Mt William Ck		<i>M. fasciolatus</i>	21°1'S 148°36'E	STRF	<i>R. v</i>	<i>A. b.</i> , <i>T. e.</i>	<i>T. e.</i> , <i>M. fas.</i> , <i>L. lsl</i>	5	0	5
Goomburra FR	Dalrymple Ck	690	<i>M. fasciolatus</i>	27°58'S 152°34'E	WSF	<i>A. b.</i> , <i>M. it</i>	<i>M. fl.</i> , <i>L. p</i>	<i>Le. f.</i> , <i>Lim. d.</i> , <i>M. fl.</i> , <i>L. c.</i> , <i>L. p.</i> , <i>L. w</i>	7	3	0
Kroombit FR	3 Moon Ck	784	<i>M. fasciolatus</i>	24°24'S 151°2'E	STRF	None	<i>T. p.</i> , <i>M. fl.</i> , <i>L. p</i> , <i>Ab</i>	<i>L. c.</i> , <i>L. p.</i> , <i>L. w</i>	10	9	10
Lamington NP	Bundoomba Ck	530	<i>M. fleayi</i>	28°13'S 153°8'E	STRF/WSF	None	<i>M. fl.</i> , <i>A. b.</i> , <i>L. p</i>	<i>A. b.</i> , <i>M. fl.</i> , <i>L. w</i>	11	6	6
Lamington NP	Stockyard Ck	780	<i>M. fasciolatus</i>	28°12'S 153°6'E	STRF	None	<i>as above</i>	<i>A. b.</i> , <i>M. fl.</i> , <i>L. w</i>	8	6	7
Maiala NP	Love Ck	550	<i>M. fasciolatus</i>	27°19'S 152°45'E	STRF/WSF	<i>T. d</i>	<i>L. p</i>	<i>M. fas</i>	10	7	7
Main Range NP	Gap Ck 1	710	<i>M. fleayi</i>	28°2'S 152°23'E	STRF/WSF	<i>A. b.</i> , <i>M. it</i>	<i>M. fl.</i> , <i>L. p</i>	<i>Le. f.</i> , <i>Lim. d.</i> , <i>M. fl.</i> , <i>L. c.</i> , <i>L. p.</i> , <i>L. w</i>	6	5	6
Main Range NP	Gap Ck 2	650	<i>M. fasciolatus</i>	28°3'S 152°21'E	DSF	<i>A. b.</i> , <i>M. it</i>	<i>M. fl.</i> , <i>L. p</i>	<i>Le. f.</i> , <i>Lim. d.</i> , <i>M. fl.</i> , <i>L. c.</i> , <i>L. p.</i> , <i>L. w</i>	10	10	10
Mount Mee FR	Byron Ck	275	<i>M. fasciolatus</i>	27°6'S 151°36'E	STRF/WSF	None	<i>M. it</i> , <i>L. p</i>	<i>A. b</i>	10	10	9 ^f

^a Reserve codes: CP = Conservation Park; FR = Forest Reserve; NP = National Park.

^b Habitat codes: DSF = dry sclerophyll forest; STRF = subtropical rainforest; WSF = wet sclerophyll forest.

^c Species codes: *A. b* = *Adelotus brevis*; *Le. f* = *Lechriodus Fletcheri*; *Lim. d* = *Limnodynastes dumerilii*; *L. c* = *Litoria chloris*; *L. lsl* = *Litoria lesueuri* sensu lato; *L. p* = *Litoria pearsoniana*; *L. w* = *Litoria wilcoxi*; *M. fas* = *Mixophyes fasciolatus*; *M. fl* = *Mixophyes fleayi*; *M. it* = *Mixophyes iteratus*; *M. sp.* = *Mixophyes* sp.; *T. d* = *Taudactylus diurnus*; *T. e* = *Taudactylus eungellensis*; *T. p* = *Taudactylus pleione*; *R. s* = *Rheobatrachus silus*; *R. v* = *Rheobatrachus vitellinus*.

^d Hines et al. (1999).

^e Berger (2001).

^f One sample was excluded as no mouthparts were sectioned for histologic examination.

All captured larvae appeared normal, based on swim strength and body condition, and gross mouthpart morphology was not considered when larvae were selected. Larvae were euthanized on site according to Australian and New Zealand Council and Care of Animals in Research and Teaching Guidelines with chloral hydrate and then fixed in 10% buffered formalin or 70% ethanol (Reilly, 1993). Confirmation of larvae species was based on body shape, tail fin profile, color and pattern, and mouthpart morphology (Anstis, 2002). Body size was assessed by taking a snout to tail-tip measurement; those with limb bud development were Gosner staged (Gosner, 1960).

Larval specimens were examined under a dissecting microscope in the laboratory and changes in the oral disc structures were drawn onto a chart. In order to be consistent with other researchers (Fellers et al., 2001; Rachowitz and Vrendenberg, 2004), the keratinized and nonkeratinized structures associated with the oral disc will be referred to as mouthparts. The oral disc structures of *M. fleayi* and *M. fasciolatus* larvae are almost identical and consist of a keratinized upper (or anterior) and a lower (or posterior) jaw sheath (sometimes called a "beak"). They possess up to nine tooth rows depending on stage, generally having three upper and lower tooth rows and three to six lateral tooth rows. The tooth rows most proximal to the jaw sheaths are often discontinuous in the center line and the oral disc is bordered completely by a marginal papilla (Anstis, 2002). Tooth rows consist of a multitude of tiny keratinized barbs or "labial teeth," the preferred nomenclature (McDiarmid and Altig, 1999). An example of mouthparts that are considered normal for the purpose of the study is shown in Figure 1a.

For histologic examination, tissue sections were cut at 5 μ m thickness and stained using a standard procedure for hematoxylin and eosin (HE) staining. Initially, sections from a small number of tadpoles were also stained with periodic acid Schiff (PAS), but because HE staining proved adequate for examination, the PAS stain was discontinued. The large larvae (>30 mm body length) were cut sagittally through the center of the oral disc so that two sections of the oral disc profile could be examined. Smaller larvae were embedded whole. The medial aspects of the eyes were used as landmarks when sectioning the mouthparts. Histologic diagnosis of *B. dendrobatidis* was based on the presence of spherical to ovoid 2–11 μ m diameter zoosporeangia, which were indistinguishable from those seen in adult epidermal lesions (Berger et al.,

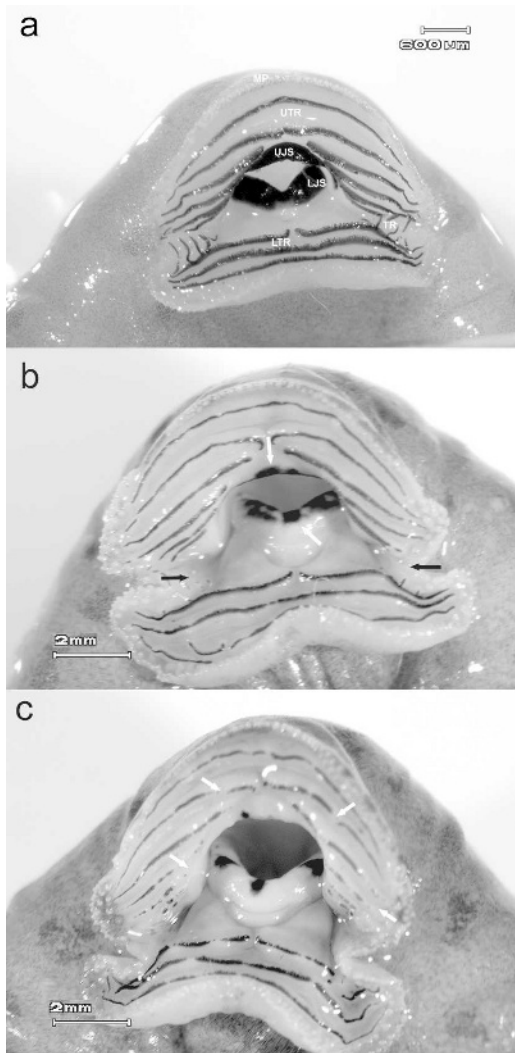


FIGURE 1. (a). Normal oral disc and mouthpart morphology of an *M. fasciolatus* larva. UJS: Upper jaw sheath, LJS: Lower jaw sheath, UTR: Upper tooth rows, LTR: Lower tooth rows, TR: Lateral tooth rows, MP: Marginal papilla. (b). Mouthpart abnormalities that represent those observed in the study (in a *M. fasciolatus* larvae). White arrows indicate where jaw sheath pigment has been lost. Most tooth rows appear intact but there is extensive blunting of the labial teeth which gives an irregular appearance to the comb-like margins. Closer inspection in a sample like this reveals complete loss of the lateral tooth rows (black arrows). (c). Abnormal mouthparts in a *M. fasciolatus* larvae similar to Fig. 1b. There is more extensive jaw sheath depigmentation and the tooth row changes are more visible. Most of the labial teeth are blunted/ shortened and there are nonpigmented sections indicating where the tooth rows have been lost completely (some are indicated by arrows).

2000). Sections were also examined for discharge papillae, colonial thalli, and septation of sporangia but these features were not considered essential for a diagnosis of *B. dendrobatidis* infection.

In order to compare results of mouthpart morphology and histologic examinations with PCR results, a further 30 *M. fleayi* larvae were collected from the Gap Creek site in September 2004. These were collected and handled in the same way as for all other samples in this study except that they were fixed in 70% ethanol. The left-hand half of the mouthparts was sent to the Australian Animal Health Laboratory for quantitative real-time PCR analysis as described by Boyle et al. (2004).

Prevalence of grossly visible changes in mouthpart morphology and of histologic evidence of *B. dendrobatidis* was calculated for each site and for pooled data. The 95% confidence interval (CI) for the pooled prevalence was calculated with robust standard errors to account for clustering by site, by back transforming β coefficients from a constant-only logistic regression model fitted using Stata Version 8.2 (Statacorp, 4905 Lakeway Drive, College Station, Texas, USA). Associations between larval size (≤ 30 mm or > 30 mm) and both presence of mouthpart changes and histologic evidence of *B. dendrobatidis* (both binary variables) at the individual larva level were assessed with exact conditional logistic regression models using only data from the four sites where larvae of both size categories were collected. The association between mouthpart changes and histologic evidence of *B. dendrobatidis* at the individual larva level was also assessed with exact conditional logistic regression models. Logistic regression models were conditional on site and were fitted using LogXact Version 6 (Cytel Software Corporation, 675 Massachusetts Avenue, Cambridge, Massachusetts, USA). Score tests with exact variances were used to calculate exact mid-*P* values for testing the significance of associations. Larvae of both *Mixophyes* species were pooled for statistical analyses unless stated otherwise.

RESULTS

The structure of the study populations are as follows: at three sites, all larvae collected were *M. fleayi*, and at 11 sites, all larvae collected were *M. fasciolatus*. Of 116 larvae collected, 104 (90%) were classified as medium- to large-sized (over 30 mm to 100 mm). Of the 24 *M. fleayi*

collected, 16 (67%) were medium- to large-sized and of the 92 *M. fasciolatus* collected, 88 (96%) were medium- to large-sized. Average sizes of *M. fleayi* and *M. fasciolatus* larvae were 39 mm and 59 mm, respectively.

Changes in mouthpart morphology were similar to those described by Fellers et al. (2001), most commonly multifocal pigment loss and absence of tooth rows. These were classified as gross morphologic abnormalities and ranged in extent and severity from complete absence of pigment and tooth rows on any oral disc structure to a subtle scalloped appearance to the jaw sheath pigment, or a blunted appearance of the jaw sheath cusps and labial teeth (Fig. 1b, c). Larvae that had only mild or subtle changes such as intact tooth rows that were blunted in appearance were considered normal for this study. The most consistent and obvious changes were varying degrees of multifocal depigmentation affecting the upper and lower jaw sheaths. Jaw sheath depigmentation and obvious loss or shortening of the tooth rows usually occurred concurrently.

Histologic lesions in larval mouthparts were confined to the keratinized tissue which also includes the roof of the buccal cavity (Berger, 2001). In the normal jaw sheath, the epidermal basal cells flatten and lengthen, forming an organized palisade-like structure as they reach the surface; at this point, in most species, they become keratinized and pigmented (Fig. 2a). Sporangia of *B. dendrobatidis* could be viewed readily at the base of the keratinized sheath or in areas of epithelial erosion. The sporangia in more superficial cells often looked empty and the deeper nucleated cell layers often contained sporangia full of developing zoospores. In more advanced lesions, all keratinized surface cells were absent and replaced with layers of flat amelanotic cells which often were heavily colonized with *B. dendrobatidis* (Fig. 2b). Tooth row infections had a similar appearance with *B.*

dendrobatidis infecting the base of the labial teeth. In severe cases, tooth rows were absent, and in a number of larvae, a mononuclear cellular infiltration resembling lymphocytes was observed in the dermis. This was often observed at the base of a *B. dendrobatidis* cluster. Some larvae without grossly visible changes to the mouthparts had sporangia detected microscopically within the buccal cavity at the epithelia margin of the upper jaw sheath, extending in the dorsal buccal epithelium.

At least one larva with grossly abnormal mouthparts was detected at 86% ($n=12$) of the 14 sites (Table 1). The median prevalence of abnormal mouthparts at these sites was 73% (range 20–100%). The pooled prevalence across all sites was 66% (76/116) and the associated 95% confidence interval (CI) was 47–80%. Across sites with at least one larva affected, the pooled prevalence was 73% (95% CI, 55–85%). The median prevalence in the three *M. fleayi* populations and the 11 *M. fasciolatus* populations was 57% (range 55–83%) and 70% (range 0–100%), respectively.

Histologic results were available for 114 of the 116 larvae. At least one larva with histologic evidence of *B. dendrobatidis* was detected at 93% ($n=13$) of the 14 sites. The median prevalence of histologic evidence of *B. dendrobatidis* at these sites was 100% (range 17–100%). The pooled prevalence across all sites was 78% (89/114) and the associated 95% confidence interval was 59–90%. Across sites with at least one larva affected, the pooled prevalence was 83% (95% CI, 67–92%). The median prevalence in the three *M. fleayi* populations and the eleven *M. fasciolatus* populations was 57% (range 55–100%) and 100% (range 0–100%), respectively.

There appeared to be no association of larval size with Gosner stage because size related more to species and site collected. Most larvae fell within stage 25, having fully developed oral discs but no detectable limb bud development, and these

ranged in size from 18 mm to 77 mm. A minority of samples (total 10) ranged between Gosner stages 26–40 and ranged in size from 62–100 mm. Relative to small larvae, medium to large larvae were much more likely to have grossly abnormal mouthparts (odds ratio 16.0, exact 95% CI, 1.7–826.7, $P=0.003$) and histologic evidence of *B. dendrobatidis* (odds ratio 6.3, exact 95% CI, 0.8–82.8, $P=0.046$). These odds ratios describe the odds of large larvae having the condition, relative to small larvae.

Mouthpart changes were strongly associated with histologic evidence of *B. dendrobatidis*. Among larvae with grossly abnormal mouthparts, the odds of histologic evidence of *B. dendrobatidis* were 51.5 times higher than for larvae with normal mouthparts (exact 95% CI, 5.5–2599.0; $P<0.001$). Of 89 larvae with histologic evidence of *B. dendrobatidis*, 69 had grossly abnormal mouthparts (relative sensitivity estimate, 78%). Of 25 larvae with no histologic evidence of *B. dendrobatidis*, 20 had grossly normal mouthparts (relative specificity estimate, 80%). Of 74 larvae with grossly abnormal mouthparts, 93% (69/74) had histologic evidence of *B. dendrobatidis* but only 50% (20/40) of larvae with grossly normal mouthparts had no histologic evidence of *B. dendrobatidis*.

Of the 13 sites with at least one larva with histologic evidence of *B. dendrobatidis*, 11 had at least one larva with grossly abnormal mouthparts (relative site-level sensitivity, 85%). At the site with no larvae with histologic evidence of *B. dendrobatidis*, three larvae had mild but grossly abnormal mouthparts. Of the 12 sites with at least one larva with grossly abnormal mouthparts, 11 sites (92%) had at least one larva with histologic evidence of *B. dendrobatidis*. Both sites with no larvae with grossly abnormal mouthparts had at least one larva with histologic evidence of *B. dendrobatidis*.

All 30 individuals collected for comparisons between diagnostic methodologies had grossly visible mouthpart abnormali-

ties. Histologic evidence of *B. dendrobatidis* was found in all except one and all had positive real-time PCR results.

DISCUSSION

The population, as defined by the site, is typically the unit of interest for *B. dendrobatidis* surveillance in anuran populations, and results from this study show that *Mixophyes* larvae are suitable for such surveillance. When the prevalence of histologic evidence of *B. dendrobatidis* in affected populations is high, as in southeast Queensland, assessment of larva for mouthpart abnormalities can be used as an initial step for *B. dendrobatidis* detection rather than routine sacrifice and histologic examination. This is important where endangered species are being examined.

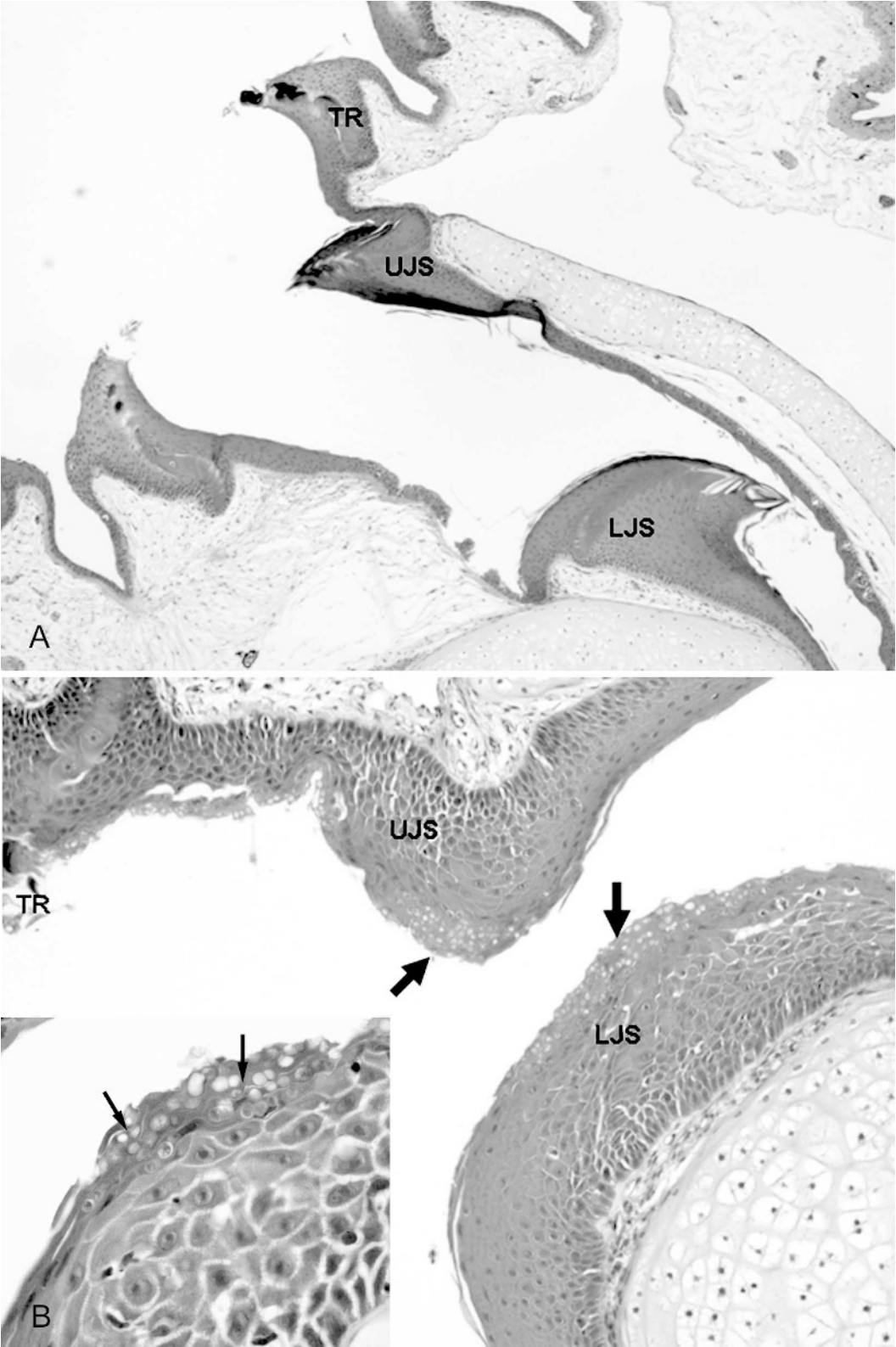
In our study, there was a strong association between mouthpart abnormalities (characterized by depigmentation of jaw sheaths and loss or shortening of tooth rows) and histologic evidence of *B. dendrobatidis*. Abnormal mouthpart morphology was highly predictive of histologic evidence of *B. dendrobatidis*. This contrasts with previous work (Fellers et al., 2001) in which 16 of 24 (67%) larvae with mouthpart abnormalities had histologic evidence of *B. dendrobatidis*. The higher positive predictive value in the current study (93%) could be due to a higher prevalence of histologic evidence of *B. dendrobatidis* in the study populations and/or higher sensitivity of detection of *B. dendrobatidis* histologically. To maximize sensitivity of histologic detection *B. dendrobatidis*, other researchers have examined multiple serial sections representing the entire mouth part region of each larva (Woodhams and Alford, 2005).

The higher positive predictive value might also relate to this population being exposed less frequently to other causes of mouthpart abnormalities. Seasonal differences in mouthpart morphology have been observed in larvae of *R. muscosa*. These changes occurred as larvae stopped feeding

and overwintered under the lake ice (Rachowicz and Vrendenberg, 2004). On gross examination, these changes could be confused with those associated with *B. dendrobatidis*. However, the histologic appearance differed from those lesions associated with *B. dendrobatidis* infection because the larvae lost the pigmentation of the keratinized mouthparts but maintained the normal histologic structure (Rachowicz and Vrendenberg, 2004). Therefore, histologic examinations are also warranted when investigating the presence of *B. dendrobatidis* in a larval species or region where the association between mouthpart morphology and histologic evidence of *B. dendrobatidis* has not been described.

In the current study, the observation that *B. dendrobatidis* was present and was associated with disrupted cells that form keratinized tissue strongly suggests that the grossly observable changes were caused by *B. dendrobatidis*. The histologic appearance of chytridiomycosis lesions is highly specific because the shape, distribution, and size of the sporangia are unique (Berger et al., 2000; Fellers et al., 2001). These lesions easily are recognized even in larva with low infection density or sparsely distributed lesions. The positive real-time PCR results further confirm that the mouthpart and/or histologic changes described in this study are associated with an infection with *B. dendrobatidis*.

Histologic observations made during this study demonstrate that *B. dendrobatidis* can be present in the absence of keratin. Although *B. dendrobatidis* is considered to be a digester of keratin and might have originated from a saprophytic form that existed in soil (Longcore et al., 1999), we observed sporangia not only in the nonliving keratinized structures but also in the deeper living cell layers that form keratin. Larvae were observed that had complete erosion of the mouthparts and had lost all keratinized tissue but still carried substantial numbers of sporangia. These lesions resembled those described by Fellers et al. (2001),



where pigmented cells were replaced by amelanotic or hypomelanotic flat squamous cells. In addition, *B. dendrobatidis* appears unattracted to the usual keratin baits used to collect these types of fungi in the field (Piotrowski et al., 2004). It is possible that *B. dendrobatidis* could be attracted to keratin surfaces but has adapted to invading the underlying “precursor” cells that form the final keratinized product.

The results of this study suggest that it is possible to design a surveillance system with high site level sensitivity. Of 89 larvae with histologic evidence of *B. dendrobatidis*, only 69 had grossly abnormal mouthparts (i.e., the relative sensitivity was 78%). False negative results might be due to observer error or inability to visually detect early mouthpart lesions associated with more subtle tooth row and pigment changes. We also observed histologic evidence of *B. dendrobatidis* associated with mouthpart changes that would not be grossly visible, such as those occurring entirely within the buccal cavity. Despite the 78% sensitivity at the individual larva level, site level sensitivity can be increased by sampling larger numbers of larvae. For example, assuming that mouthpart morphology has relative sensitivity for detection of histologic evidence of *B. dendrobatidis* of 78% (as observed in this study) and relative specificity of 100%, and that the prevalence of histologic evidence of *B. dendrobatidis* in affected populations is 17% (the minimum observed in this study), if only 5 representative larvae are selected and all are found to have normal mouthparts, the population can be considered to be unaffected with only about 50% confidence

(Cameron, 1998). However, if 22 representative larvae are selected and found to have normal mouthparts, the population can be considered to be unaffected with at least 95% confidence. In the current study, at the site level, two of the 13 sites with at least one larva with histologic evidence of *B. dendrobatidis* had no larvae with grossly abnormal mouthparts. However, only five and six larvae were sampled at these sites and it is possible that larger sample sizes would have resulted in detection of larvae with grossly abnormal mouthparts. To further increase site-level sensitivity, our results suggest that medium- to large-sized larvae are most likely to be affected and these should be targeted for surveillance. Additional increases in site-level sensitivity would also be achieved if histologic examinations and molecular tests such as PCR are applied to samples at sites where all larvae examined have grossly normal mouthparts.

Site-level sensitivity will be maximized when prevalence of infection in larvae is highest. Among adult frogs, higher frequencies of mortality associated with *B. dendrobatidis* have been observed in low-temperature regions (alpine and mountain stream habitats) compared with warmer lowland habitat, and peaks of mortalities have occurred during winter months (Berger et al., 2004), suggesting that prevalence in anuran larvae might be highest during and soon after cooler months. Species of larvae such as the *Mixophyes* that overwinter in southeast Queensland are not only exposed to *B. dendrobatidis* at temperatures suitable for the fungus to grow but have increased duration of exposure. In this study, medium to large larvae were more likely

←

FIGURE 2. (A). Sagittal section of the mouthparts of a normal *M. fasciolatus* larva (40×), HE stain. TR: tooth row, UJS: upper jaw sheath, LJS: lower jaw sheath. (B). Typical lesions indicated by wide arrows, affecting upper (UJS) and lower (LJS) jaw sheaths, and tooth row (TR) in an *M. fasciolatus* larva (200×). Note that there is almost complete loss of the keratinized jaw sheath and replacement with flat amelanotic cells that support growth of *B. dendrobatidis*. Chytrid sporangia in epithelium are indicated by thin arrows (inset 400×).

than small larvae to be affected, presumably because they were older and had been in the aquatic system longer. However a high prevalence might also be expected among small larvae if they are collected after overwintering in infected sites. Seasonal variation in prevalence of infection might also relate to other factors such as rainfall, stream flow, and host biology. Further ecologic research is required to determine the influence of variables such as dilution (water volume flow), breeding times, and temperature on prevalence of *B. dendrobatidis*.

The larvae of a number of anuran species have been found to be infected with *B. dendrobatidis*, including North American species *R. muscosa* (Fellers et al., 2001) and *Rana yavapaiensis* (Bradley et al., 2002), and in Australia, *M. fasciolatus* and *M. fleayi* (Berger, 2001), *Litoria rheocola* (Berger et al., 1998), the introduced *Bufo marinus* (Berger, 2001), and a range of tropical montane species (Woodhams and Alford, 2005). Of these, *Mixophyes* larvae appear to be a particularly suitable species for surveillance. Recent work by Woodhams and Alford (2005) demonstrated a higher prevalence of infection in *M. schevilli* larvae (76%) relative to five other sympatric species and the corresponding adult populations. Members of the *Mixophyes* genus are found in mountain stream habitats throughout most of the eastern coastal mountainous region of Australia. Their larval stage takes, on average, 6–9 mo (*M. fleayi*) and up to 12 mo (*M. fasciolatus*) to reach metamorphosis (Anstis, 2002). Therefore, many larvae overwinter in streams. This potentially provides a perennial reservoir of *B. dendrobatidis*, with cohorts from different breeding seasons overlapping and maintaining infection within the breeding sites for the frog population. The biologic behavior of anuran larvae and the observed high prevalence of histologic evidence of *B. dendrobatidis* at most affected sites examined in this study, as well as others

(Berger, 2001; Woodhams and Alford, 2005) suggests that *Mixophyes* larvae are sensitive indicators of the presence of *B. dendrobatidis* in aquatic environments. Use of nonthreatened populations of anuran larvae for surveillance of *B. dendrobatidis* can be an important tool in understanding the distribution of the disease agent. This information is critical for planning disease control strategies and mitigating declines of sympatric threatened and endangered anuran species.

Finally, these results demonstrate that *B. dendrobatidis* is present in sensitive frog populations in southeast Queensland. It is unclear whether *B. dendrobatidis* was the direct cause of the previous declines and disappearances at the 14 selected study sites (McCallum, 2005). However, under certain circumstances, post-metamorphic frogs die in significant numbers from chytridiomycosis (Green et al., 2002; Berger et al., 2004) and the anuran populations utilizing these creek sites could also be at increased risk of future decline due to *B. dendrobatidis*. Until we understand how *B. dendrobatidis* has been able to spread so rapidly and widely, these sites remain a potential source of infection for susceptible populations elsewhere in the region.

ACKNOWLEDGMENTS

We wish to thank T. Daley and A. Chan of Oral Biology and Pathology, School of Dentistry and C. Cazier of the Veterinary School Pathology Laboratory for their excellent technical assistance. Special thanks to the various staff of the Environment Protection Agency and Queensland Parks and Wildlife Service for supporting this work. Funding for this study provided by a grant from the Morris Animal Foundation (Grant D04ZO-118). Ethics approval no. DENT/605/04/MAF.

LITERATURE CITED

- ANNIS, S. L., F. P. DASTOOR, H. ZIEL, P. DASZAK, AND J. E. LONGCORE. 2004. A DNA-based assay identifies *Batrachochytrium dendrobatidis* in amphibians. *Journal of Wildlife Diseases* 40: 420–428.

- ANSTIS, M. 2002. Tadpoles of South-eastern Australia. New Holland, New South Wales, Australia, 281 pp.
- BARR, D. J. S. 2001. Chytridiomycota. In *The Mycota VII, Systematics and Evolution*, D. J. McLaughlin, E. G. McLaughlin and P. A. Lemke (eds.). Springer-Verlag, Berlin, Germany, pp. 93–112.
- BELL, B. D., S. CARVER, N. J. MITCHELL, AND S. PLEDGER. 2004. The recent decline of a New Zealand endemic: How and why did populations of Archey's frog *Leiopelma archeyi* crash over 1996–2001? *Biological Conservation* 120: 189–199.
- BERGER, L. 2001. Diseases of amphibians. PhD Thesis, School of Public Health and Tropical Medicine, James Cook University, Townsville Queensland, Australia, 331 pp.
- , R. SPEARE, P. DASZAK, D. E. GREEN, A. A. CUNNINGHAM, C. L. GOGGIN, R. SLOCOMBE, M. A. RAGAN, A. D. HYATT, K. R. McDONALD, H. B. HINES, K. R. LIPS, G. MARANTELLI, AND H. PARKES. 1998. Chytridiomycosis causes amphibian mortality associated with population declines in the rain forests of Australia and Central America. *Proceeding of the National Academy of Sciences, USA* 95: 9031–9036.
- , AND A. KENT. 2000. Diagnosis of chytridiomycosis in amphibians by histological examination. *Zoos' Print Journal* 15: 184–190.
- , A. D. HYATT, V. OLSEN, S. G. HENGSTBERGER, D. BOYLE, G. MARANTELLI, K. HUMPHREYS, AND J. E. LONGCORE. 2002. Production of polyclonal antibodies to *Batrachochytrium dendrobatidis* and their use in an immunoperoxidase test for chytridiomycosis in amphibians. *Diseases of Aquatic Organisms* 48: 213–220.
- , H. B. HINES, G. MARANTELLI, A. D. HYATT, K. R. McDONALD, L. F. SKERRATT, V. OLSEN, J. M. CLARKE, G. GILLESPIE, M. MAHONY, N. SHEPPARD, C. WILLIAM, AND M. J. TYLER. 2004. Effect of season and temperature on mortality in amphibians due to chytridiomycosis. *Australian Veterinary Journal* 82: 434–439.
- BONACCORSO, E., AND J. M. GUAYASAMIN. 2003. Chytridiomycosis as a possible cause of population declines in *Atelopus cruciger* (Anura: Bufonidae). *Herpetological Review* 34: 331–334.
- BOSCH, J., I. MARTINEZ-SOLANO, AND M. GARCIA-PARIS. 2001. Evidence of a chytrid fungus infection involved in the decline of the common midwife toad (*Alytes obstetricians*) in protected areas of central Spain. *Biological Conservation* 97: 331–337.
- BOYLE, D. G., D. B. BOYLE, V. OLSEN, J. A. T. MORGAN, AND A. D. HYATT. 2004. Rapid quantitative detection of Chytridiomycosis (*Batrachochytrium dendrobatidis*) in amphibian samples using real-time Taqman PCR assay. *Diseases of Aquatic Organisms* 60: 141–148.
- BRADLEY, G. A., P. C. ROSEN, M. J. SREDL, T. R. JONES, AND J. E. LONGCORE. 2002. Chytridiomycosis in native Arizona frogs. *Journal of Wildlife Diseases* 38: 206–212.
- BUREAU OF METEOROLOGY. 1989. *Climate of Australia*. Australian Government Publishing Service, Canberra, Australian Capital Territory, Australia, 49 pp.
- CAMERON, A. 1998. FreeCalc, Version 2.0. http://www.ausvet.com.au/content.php?page=res_software.
- CUNNINGHAM, A. A., T. W. J. GARNER, V. AGUILAR-SANCHEZ, B. BANKS, J. FOSTER, A. W. SAINSBURY, M. PERKINS, S. F. WALKER, A. D. HYATT, AND M. C. FISHER. 2005. Emergence of amphibian chytridiomycosis in Britain. *Veterinary Record* 157: 386–387.
- FELLERS, G. M., D. E. GREEN, AND J. E. LONGCORE. 2001. Oral chytridiomycosis in the mountain yellow legged frog (*Rana muscosa*). *Copeia* 4: 945–953.
- GOSNER, K. L. 1960. A simplified table for staging anuran embryos and larvae with notes on identification. *Herpetologica* 16: 183–190.
- GREEN, D. E., K. A. CONVERSE, AND A. K. SCHRADER. 2002. Epizootiology of sixty-four amphibian mortality events in the USA, 1996–2001. *Annals of the New York Academy of Science* 969: 323–339.
- HERO, J. M., AND C. MORRISON. 2004. Frog declines in Australia: Global implications. *Herpetological Journal* 14: 175–186.
- HINES, H. B., M. MAHONY, AND K. R. McDONALD. 1999. An assessment of frog declines in wet subtropical Australia. In *Declines and disappearances of Australian frogs*, A. Campbell (ed.). Environment Australia, Canberra, Australian Capital Territory, Australia, pp. 44–65.
- JOHNSON, M. L., AND R. SPEARE. 2003. Survival of *Batrachochytrium dendrobatidis* in water: Quarantine and disease control implications. *Emerging Infectious Diseases* 9: 922–925.
- , AND ———. 2005. Possible modes of dissemination of the amphibian chytrid *Batrachochytrium dendrobatidis* in the environment. *Diseases of Aquatic Organisms* 65: 181–186.
- LIPS, K. R. 1999. Mass mortality and population declines of anurans at an upland site in western Panama. *Conservation Biology* 13: 117–130.
- LONGCORE, J. E., A. P. PESSIER, AND D. K. NICHOLS. 1999. *Batrachochytrium dendrobatidis* gen.et sp.nov., a chytrid pathogenic to amphibians. *Mycologia* 91: 219–227.
- MARTINEZ-SOLANO, I., J. BOSCH, AND M. GARCIA-PARIS. 2003. Demographic trends and community stability in a montane amphibian assemblage. *Conservation Biology* 17: 238–244.
- MAZZONI, R. 2003. Emerging pathogen of wild amphibians in frogs (*Rana catesbeiana*) farmed for international trade. *Emerging Infectious Diseases* 9: 995–998.
- MCCALLUM, H. 2005. Inconclusiveness of chytridiomycosis as the agent in widespread frog declines. *Conservation Biology* 19: 1421–1430.

- McDIARMID, R. W., AND R. ALTIG. 1999. Chapter 3: Body Plan. In *The biology of anuran larvae*, R. Altig and R. W. McDiarmid (eds.). The University of Chicago Press, Chicago, Illinois, pp. 24–51.
- MUTHS, E., P. S. CORN, A. P. PESSIER, AND D. E. GREEN. 2003. Evidence for disease related amphibian decline in Colorado. *Biological Conservation* 110: 357–365.
- NICHOLS, D. K., E. W. LAMIRANDE, A. P. PESSIER, AND J. E. LONGCORE. 2001. Experimental transmission of cutaneous chytridiomycosis in dendrobatid frogs. *Journal of Wildlife Diseases* 37: 1–11.
- OULLETT, M., I. MIKAELIAN, B. D. PAULI, J. RODRIGUE, AND D. M. GREEN. 2005. Historical evidence of widespread chytrid infection in North American amphibian populations. *Conservation Biology* 19: 1431–1440.
- PARRIS, M. J., AND J. G. BEAUDOIN. 2004. Chytridiomycosis impacts predator–prey interactions in larval amphibian communities. *Oecologia* 140: 626–632.
- PIOTROWSKI, J. S., S. L. ANNIS, AND J. E. LONGCORE. 2004. Physiology of *Batrachochytrium dendrobatidis*, a chytrid pathogen of amphibians. *Mycologia* 96: 9–15.
- RACHOWITZ, L. J., AND V. T. VRENDENBERG. 2004. Transmission of *Batrachochytrium dendrobatidis* within and between amphibian lifestages. *Diseases of Aquatic Organisms* 61: 75–83.
- REILLY, J. S. 1993. Euthanasia of animals used for scientific purposes. University of Queensland, Brisbane, Queensland, Australia, 73 pp.
- SATTLER, P., AND R. WILLIAMS. 1999. The conservation status of Queensland's bioregional ecosystem. Environmental Protection Agency, Brisbane, Australia, 620 pp.
- SPEARE, R. 2006. Threat abatement plan for infection of amphibians with chytrid fungus resulting in chytridiomycosis. Department of Environment and Heritage, Canberra, Australian Capital Territory, Australia, 29 pp.
- , AND L. BERGER. 2000. Chytridiomycosis in amphibians in Australia <http://www.jcu.edu.au/school/phtm/PHTM/frogs/chyspec.htm>. Accessed September 2001.
- WELDEN, C., L. H. DUPREEZ, A. D. HYATT, R. MULLER, AND R. SPEARE. 2004. Origin of the amphibian chytrid fungus. *Emerging Infectious Disease* 10: 2100–2106.
- WOODHAMS, D. C., AND R. A. ALFORD. 2005. Ecology of chytridiomycosis in rainforest stream frog assemblages of tropical Queensland. *Conservation Biology* 19: 1449–1459.

Received for publication 20 February 2006.