

Infection of Spotted Salamanders (*Ambystoma maculatum*) with Ichthyophonus-like Organisms in Virginia

Authors: Ware, Joy L., Viverette, Cathy, Kleopfer, John D., Pletcher, Leeanna, Massey, Davis, et al.

Source: Journal of Wildlife Diseases, 44(1) : 174-176

Published By: Wildlife Disease Association

URL: <https://doi.org/10.7589/0090-3558-44.1.174>

BioOne Complete (complete.BioOne.org) is a full-text database of 200 subscribed and open-access titles in the biological, ecological, and environmental sciences published by nonprofit societies, associations, museums, institutions, and presses.

Your use of this PDF, the BioOne Complete website, and all posted and associated content indicates your acceptance of BioOne's Terms of Use, available at www.bioone.org/terms-of-use.

Usage of BioOne Complete content is strictly limited to personal, educational, and non - commercial use. Commercial inquiries or rights and permissions requests should be directed to the individual publisher as copyright holder.

BioOne sees sustainable scholarly publishing as an inherently collaborative enterprise connecting authors, nonprofit publishers, academic institutions, research libraries, and research funders in the common goal of maximizing access to critical research.

Infection of Spotted Salamanders (*Ambystoma maculatum*) with Ichthyophonus-like Organisms in Virginia

Joy L. Ware,^{1,5} Cathy Viverette,² John D. Kleopfer,³ Leeanna Pletcher,⁴ Davis Massey,¹ and Anne Wright⁴

¹Department of Pathology, Virginia Commonwealth University School of Medicine, Richmond, Virginia 23298, USA; ²Center for Environmental Studies, Virginia Commonwealth University, Richmond, Virginia 23298, USA;

³Virginia Department of Game and Inland Fisheries, 3801 John Tyler Memorial Hwy, Charles City, Virginia 23032, USA; ⁴Department of Biology, Virginia Commonwealth University, Richmond, Virginia 23298, USA;

⁵Corresponding author (email: jware@mcvh-vcu.edu)

ABSTRACT: Ichthyophonus-like organisms were found in two free-ranging adult spotted salamanders (*Ambystoma maculatum*) captured within two different vernal ponds in the Virginia Commonwealth University Rice Center for Environmental Life Sciences in Charles City County, Virginia. Histopathologic examination of necropsied specimens revealed large spores, often enclosed by granulomas. These enclosed spores resembled those caused by the fish pathogen *Ichthyophonus hoferi*. One salamander displayed an externally visible large swelling beneath the jaws. The other lacked macroscopic abnormalities, but histologic sections of ventral muscle revealed early-stage Ichthyophonus-like organisms and minimal granulomatous reactions. This is the first report of Ichthyophonus-like infection of *Ambystoma maculatum* in Virginia.

Key words: *Ambystoma maculatum*, Ichthyophonus-like organisms, salamander disease.

On 5 February 2006, 85 adult Spotted Salamanders (*Ambystoma maculatum*) were captured overnight in vernal pools (N 37.32837°, W 77.19576°) located at Virginia Commonwealth University's Rice Center for Environmental Life Sciences in Charles City County, Virginia, as part of an initial survey of the amphibian population in these vernal pools. The salamanders were measured, photographed, and released as part of an ongoing population survey. One of the specimens was moribund and displayed a swelling beneath the throat and jaws. Following euthanasia, the skin was opened, and gross examination revealed the swelling measured 11 mm by 5 mm. Histologic examination of this tissue swelling revealed numerous and often confluent granulomas. Approximate-

ly 50% of the swelling was due to granulomatous inflammation, with the Ichthyophonus-like organisms at the centers. Many of these granulomas surrounded intact or fragmented spores (Fig. 1) that appeared similar to *Ichthyophonus hoferi*, a pathogen responsible for significant mortality among both freshwater and marine fish (Kocan et al., 1999). Ichthyophonus-like organisms are members of the Class Mesomycetozoa, at the interface of fungi and protozoa (Mendoza et al., 2002). The spores ranged from 140 to 240 µm in diameter. In addition, some granulomas contained fragments of the spore walls phagocytized by foreign body giant cells. The entire area of each spore stained strongly positive with Periodic acid-Schiff reaction. Spore walls also were stained. The wall of each spore stained intensely positive with Gomori methenamine silver stain, as did portions of the interior of the spore. The liver was completely black on gross examination; based on histopathology, this was probably due to increased numbers of melanomacrophages interspersed with the hepatocytes. Eyes, lungs, heart, dorsal and ventral skin, ventral muscle, tail muscle, and liver were grossly and microscopically normal.

Gross lesions were not observed in three other adult salamanders that died in traps, and these probably died from suffocation, due to the large numbers of salamanders within the trap. However, one of these three also displayed an early-stage Ichthyophonus-like infection in the muscles lining its ventral side (Fig. 2); no

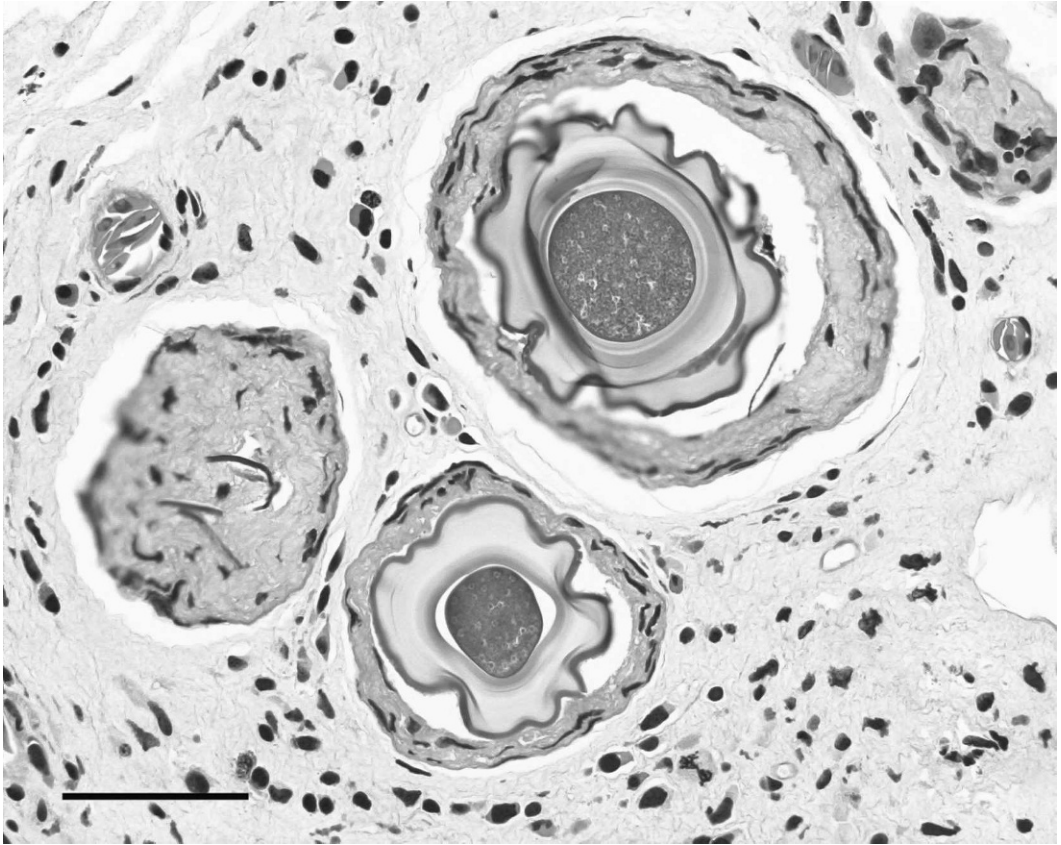


FIGURE 1. Three *Ichthyophonus*-like spores surrounded by granulomatous inflammation. Throat and lower jaws of this *Ambystoma maculatum* (specimen no. 1, 28 g, 11 mm SVL, 21 mm total length) were significantly swollen due to the granulomatous reaction. The leftmost of the three *Ichthyophonus*-like spores was partially collapsed and disintegrated. Measurement bar = 100 μ m (H&E, 200 \times).

organisms were observed in eyes, lungs, heart, dorsal and ventral skin, tail muscle, leg muscle, and liver of this animal. The granulomatous reaction was minimal at the time of the death, and this early-stage *Ichthyophonus*-like infection was not the cause of death. No *Ichthyophonus*-like organisms were observed in histologic sections of the ventral muscle, tail muscle, leg muscle, liver, heart, or lungs of the two other salamanders. Thus two of four salamanders examined exhibited evidence of the *Ichthyophonus*-like spores in muscle.

Ichthyophonus-like organisms have been reported in red-spotted newts (*Notophthalmus viridescens*) in West Virginia (Herman, 1984) and in Vermont (Green et al., 1995). Furthermore, *Ichthyophonus*

appears to be enzootic in Quebec, Canada, where a variety of frogs and one red-spotted newt displayed infection with this organism (Mikaelian et al., 2000). To our knowledge, this is the first report of the infection of adult *Ambystoma maculata* by *Ichthyophonus*-like organisms in Virginia. As noted by other investigators (Green et al., 2002), information on the presence of these organisms in clinically normal amphibians in the USA is not available. Thus it is not known whether these *Ichthyophonus*-like organisms are endemic or new to Virginia and surrounding areas, or whether they could exert a significant effect on amphibian populations.

We thank Davis Massey for assistance with photographing the histopathology slides, and

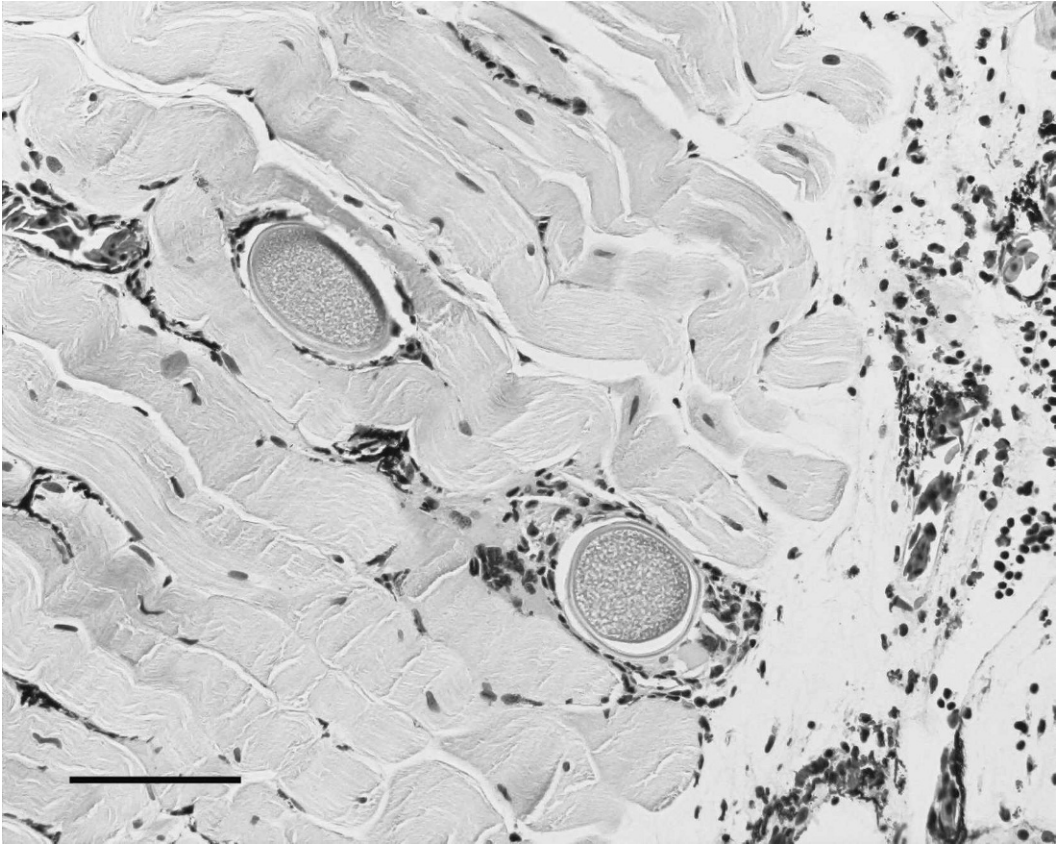


FIGURE 2. Ventral muscles of *Ambystoma maculatum* specimen number 85 (25 g, 10.5 mm SVL, 20.5 mm total length) contained *Ichthyophonus*-like organisms less mature than those illustrated in Figure 1. The granulomatous reaction was minimal. No macroscopic abnormalities observed. Measurement bar = 200 μ m (H&E, 100 \times).

the Histopathology Laboratory, Department of Pathology, VCU School of Medicine, for preparation of the histologic specimens.

LITERATURE CITED

- GREEN, D. E., J. ANDREWS, AND J. M. ABELL. 1995. Preliminary investigation on mycotic myositis in red-spotted newts (*Notophthalmus viridescens*) from Vermont. *Herpetopathologia. In* Proceedings of 5th International Colloquium on Pathology of Reptiles & Amphibians 1995, pp. 49–62.
- , K. A. CONVERSE, AND A. K. SCHRADER. 2002. Epizootiology of sixty-four amphibian morbidity and mortality events in the USA, 1996–2001. *Annals of the New York Academy of Sciences* 969: 323–339.
- HERMAN, R. 1984. *Ichthyophonus*-like infection in newts (*Notophthalmus viridescens* Rafinesque). *Journal of Wildlife Diseases* 20: 55–56.
- KOCAN, R. M., P. HERSHBERGER, T. MEHL, M. BRADLEY, D. WILDERMUTH, AND K. STICK. 1999. Pathogenicity of *Ichthyophonus hoferi* for laboratory-reared Pacific herring *Clupea pallasii* and its early appearance in wild Puget Sound herring. *Diseases of Aquatic Organisms* 35: 23–29.
- MENDOZA, L., J. W. TAYLOR, AND L. AJELLO. 2002. The class mesomycetozoa: A heterogeneous group of microorganisms at the animal-fungal boundary. *Annual Review of Microbiology* 56: 315–344.
- MIKAELIAN, I., M. OUELLET, B. PAULI, J. RODRIGUE, J. C. HARSHBARGER, AND D. M. GREEN. 2000. *Ichthyophonus*-like infection in wild amphibians from Quebec, Canada. *Diseases of Aquatic Organisms* 40: 195–201.

Received for publication 16 July 2007.