

A HEPATOOZON SPECIES GENETICALLY DISTINCT FROM H. CANIS INFECTING SPOTTED HYENAS IN THE SERENGETI ECOSYSTEM, TANZANIA

Authors: East, Marion L., Wibbelt, Gudrun, Lieckfeldt, Dietmar, Ludwig, Arne, Goller, Katja, et al.

Source: Journal of Wildlife Diseases, 44(1) : 45-52

Published By: Wildlife Disease Association

URL: <https://doi.org/10.7589/0090-3558-44.1.45>

BioOne Complete (complete.BioOne.org) is a full-text database of 200 subscribed and open-access titles in the biological, ecological, and environmental sciences published by nonprofit societies, associations, museums, institutions, and presses.

Your use of this PDF, the BioOne Complete website, and all posted and associated content indicates your acceptance of BioOne's Terms of Use, available at www.bioone.org/terms-of-use.

Usage of BioOne Complete content is strictly limited to personal, educational, and non - commercial use. Commercial inquiries or rights and permissions requests should be directed to the individual publisher as copyright holder.

BioOne sees sustainable scholarly publishing as an inherently collaborative enterprise connecting authors, nonprofit publishers, academic institutions, research libraries, and research funders in the common goal of maximizing access to critical research.

A *HEPATOZOON* SPECIES GENETICALLY DISTINCT FROM *H. CANIS* INFECTING SPOTTED HYENAS IN THE SERENGETI ECOSYSTEM, TANZANIA

Marion L. East,^{1,3} Gudrun Wibbelt,¹ Dietmar Lieckfeldt,¹ Arne Ludwig,¹ Katja Goller,¹ Kerstin Wilhelm,¹ Gereon Schares,² Dagmar Thierer,¹ and Heribert Hofer¹

¹ Leibniz-Institute for Zoo and Wildlife Research, Alfred-Kowalke-Str. 17, D-10315 Berlin, Germany

² Institute of Epidemiology, Federal Research Institute for Animal Health–Friedrich Loeffler-Institute, Seestr. 55, D-16868 Wusterhausen/Dosse, Germany

³ Corresponding author (email: east@izw-berlin.de)

ABSTRACT: Health monitoring of spotted hyenas (*Crocuta crocuta*) in the Serengeti ecosystem, Tanzania, revealed *Hepatozoon* infection in all of 11 immature individuals examined following death from natural causes. *Hepatozoon* infection was probably an important factor contributing to mortality in two cases that exhibited clinical signs of ataxia, lethargy, ocular discharge, retching, and labored breathing before death. Whether *Hepatozoon* infection contributed to six deaths from fire, probable lion predation and unknown causes could not be determined. Four deaths from infanticide and starvation were unlikely to be associated with *Hepatozoon* infection. Histologic examination revealed lung tissue infected with cyst-like structures containing protozoan stages in all eight cases examined and interstitial pneumonia in most cases. Systemic spread of infection to several organs was found in three cases. Alignment of a 426 bp sequence from the parasite's 18S rRNA gene revealed a *Hepatozoon* species identical to that recently described from two domestic cats in Spain and only 7 bp substitutions when a 853 bp sequence was aligned to this cat *Hepatozoon* species. Previous reports of infection of wild carnivores in eastern and southern Africa with an unspecified *Hepatozoon* species similar in appearance to *H. canis* may have involved the species described in this study.

Key words: *Hepatozoon canis*, Serengeti ecosystem, spotted hyena, wild carnivore.

INTRODUCTION

Apicomplexan hemogregarine *Hepatozoon* species are intracellular parasites with a life cycle that typically involves gametogenesis, fertilization, and sporogony in a hematophagous invertebrate, and merogony followed by gamontogony in a vertebrate intermediate host. Infection of the vertebrate host normally occurs by ingestion of an infected invertebrate host such as a tick (Smith, 1996). *Hepatozoon* species are classified on the basis of morphologic characteristics, life history and host taxon, and molecular phylogenetic techniques are used to establish the evolutionary relationships among species (Vincent-Johnson et al., 1997; Mathew et al., 2000; Perkins and Keller, 2001; Simpson et al., 2006a, 2006b; Criado-Fornelio et al., 2006).

Globally, *Hepatozoon* infections in domestic and wild carnivore species have been attributed to *Hepatozoon canis* or closely related undetermined species

(Brocklesby and Vidler, 1965; McCully et al., 1975; Conceição-Silva et al., 1988; Averbeck et al., 1990; Van Heerden et al., 1995), with the exception of the USA, where *Hepatozoon americanum* infects both domestic dogs (Vincent-Johnson et al., 1997) and wild carnivores (Kocan et al., 2000). Recent phylogenetic studies of unnamed *Hepatozoon* species in carnivores, including pine martens (*Martes martes*) in Scotland (Simpson et al., 2006a) and domestic cats in Spain (Criado-Fornelio et al., 2006), suggested that these *Hepatozoon* species were sufficiently genetically distinct from *H. canis* (96% sequence homology over a 656 bp sequence and a 908 bp sequence, respectively) to be considered distinct species.

Long-term monitoring of a population of several hundred individually known spotted hyenas (*Crocuta crocuta*) in the Serengeti ecosystem, Tanzania, has aimed to identify key pathogens infecting this population, to assess the impact of in-

fection at an individual and population level and to compare the phylogenetic relationship of hyena pathogens to pathogens isolated from other species in the ecosystem (Haas et al., 1996; East et al., 2001, 2004; Höner et al., 2006). This study reports clinical signs and pathologic changes associated with *Hepatozoon* infection in immature spotted hyenas following their death from various natural causes and the phylogenetic relationship of a potentially new *Hepatozoon* species to genetic sequence data from other *Hepatozoon* species archived in GenBank.

METHODS

Sample collection

This study reports information from 11 spotted hyenas from a population of known individuals (see East et al., 2001, 2004) that died from natural causes in the Serengeti National Park, Tanzania, 2°25'S, 34°50', between 1997 and 2004. All individuals were juveniles, that is, they were less than 2 yr of age (East et al., 2004). The probable causes of death included disease (see below); observed fatal attacks by an adult or yearling member of the individual's social group (infanticide); predation most likely by lion (*Panthera leo*); burns caused by an extensive "bush" fire; starvation following the disappearance of the mother of a dependent offspring; and unknown causes (Table 1). In some cases only a limited number of suitable samples for analysis were obtained from different organs because of partial consumption of carcasses by scavengers and autolytic changes of tissue caused by high temperatures.

Histologic examination

Tissues sampled from 9 of 11 carcasses were first fixed in 10% neutral buffered formalin, embedded in paraffin, routinely processed, sectioned at 4 µm, and stained with hematoxylin eosin as well as Giemsa stain. The level of infection observed in examined tissue was visually determined

using the number of protozoal cysts per vision field and the degree of the associated inflammatory reaction (Table 1).

Parasite identification and genetic phylogeny

Tissues from 6 individuals were used for the genetic identification of the parasite (Table 1). Initially to detect the hemogregarine by PCR, DNA was extracted from frozen (−80 C) tissue from three infected individuals using a commercial kit (NucleoSpin C + T; Macherey & Nagel, Düren, Germany). HPLC-purified primers HEMO1 and HEMO2 (Perkins and Keller, 2001) targeting the hemogregarine 18S rRNA gene fragment were used at a final concentration of 0.5 µM. The dNTPs were in a final concentration of 250 µM each (BioLine, Luckenwalde, Germany). Dynazyme II F-501L served as a DNA polymerase at a final concentration of 1 U/25 µl including the buffer system supplied with the enzyme (Finzyme, Espoo, Finland). The PCR cycling conditions (using a Biometra UNO II thermocycler, Biometra, Göttingen, Germany) were 94 C for 5 min, followed by 10 cycles of 56 C (including a 0.5 C decrement per cycle after the first) for 1 min, 72 C for 1 min, and 94 C for 1 min, followed by 40 cycles of 51 C for 1 min, 72 C for 1 min, and 94 C for 1 min. The PCR ended with 51 C for 1 min and a final extension at 72 C for 5 min. The amplicons were analysed in 1.5% agarose gels using a 100 bp DNA ladder (Invitrogen, Carlsbad, California) as reference.

A PCR fragment generated with primers HEMO1 and HEMO2 from one parasite isolate was cloned using the TA Cloning Kit (Invitrogen) according to manufacturer's instructions followed by cycle sequencing. The sequence contained 853 nucleotides, and BLAST search identified it as a *Hepatozoon* sp. 18S rRNA gene fragment. We then designed the following two nested primers: HEMO3 5'-TGT GTA CAA AGG GCA GGG ACG-3' and HEMO4 5'-GCG GCT TAA TTT GAC TCA ACA C-3' that amplified a PCR fragment of 462 bp length.

TABLE 1. *Hepatizoon* infection found in different organs in 11 juvenile spotted hyenas: (–) no evidence of infection observed; (+) low level of infection; (++) moderate level of infection; (n.e.) tissue not examined.

Likely cause of death:	Individual cases										
	Case 1	Case 2	Case 3	Case 4	Case 5	Case 6	Case 7	Case 8	Case 9	Case 10	Case 11
	Not known	Lion	Infanticide	Disease	Infanticide	Disease	Not known	Starvation	Fire	Lion	Not known
Age at death (mo)	2.2	8.1	4.1	1.3	2.2	2.2	2.3	6.1	23.3	12.9	5.7
Histological examination											
Lung	++	++	++	++	++	n.e.	++	++	+	n.e.	n.e.
Heart	++	n.e.	++	n.e.	++	n.e.	n.e.	++	+	n.e.	n.e.
Spleen	n.e.	n.e.	++	++	n.e.	n.e.	–	–	n.e.	n.e.	–
Lymph node	++	–	n.e.	–	–	n.e.	n.e.	–	–	n.e.	n.e.
Liver	–	–	+	n.e.	–	n.e.	–	–	–	n.e.	n.e.
Stomach	++	n.e.	n.e.	+	n.e.	n.e.	n.e.	n.e.	n.e.	n.e.	n.e.
Pancreas	++	n.e.	n.e.	n.e.	–	n.e.	n.e.	n.e.	n.e.	n.e.	n.e.
Kidney	n.e.	n.e.	+	n.e.	–	n.e.	n.e.	–	–	n.e.	+
Adrenal gland	+	n.e.	n.e.	n.e.	–	n.e.	n.e.	n.e.	n.e.	n.e.	n.e.
Skeletal muscle	n.e.	–	++	n.e.	n.e.	n.e.	–	n.e.	n.e.	n.e.	n.e.
Micrograph tissue				Lung	Lung						
Genetic analysis											
PCR HEMO1		Lung	Lung							Lung	
PCR HEMO2											
PCR HEMO3											
PCR HEMO4	Heart					Muscle					

Parasite DNA was extracted from tissue preserved in 96% ethanol from four individuals with the DNeasy Tissue Kit (Qiagen, Valencia, California). Amplification with primers HEMO3 and HEMO4 was carried out on a GeneAmp 2400 machine (Perkin Elmer, Waltham, Massachusetts) in 25 µl reaction volumes containing 50–100 ng of DNA, 1.5 mM MgCl₂, 10 mM Tris-HCl (pH 8.3), 50 mM KCl, 200 µM of each dNTP, 10 pmol of each primer, and 0.5 units of AmpliTaq DNA polymerase (Applied Biosystems Inc. [ABI], Foster City, California). Reaction mixtures were subjected to the following cycling protocol: initial denaturation (94 C: 3 min), 35 cycles (94 C: 15 sec; 60 C: 20 sec; 72 C: 45 sec) and final extension (72 C: 7 min).

PCR products were purified by treatment with ExoSAP-IT™ (USB, Cleveland, Ohio), and directly sequenced using the fluorescent BigDye Terminator Cycle Sequencing Kit v. 3.1 (ABI) and a 3100 Genetic Analyzer (ABI).

Sequences were aligned with Clustal X (Thompson et al., 1997). Our phylogenetic analysis considered a 419 bp segment and compared the “hyena” isolates with 19 *Hepatozoon* sp. isolates, and included two *Adelina* sp. isolates that served as an outgroup (complete names and accession numbers are shown in Fig. 2). A neighbor-joining tree was generated with Kimura 2-parameter distances as implemented in Mega 2.1 (Kumar et al., 2001).

RESULTS

Clinical signs

Two of 11 infected animals (case 4 and case 6, Table 1) had clinical signs of disease including ataxia, occasional retching, ocular discharge, and labored breathing for several days before both cubs died at an age of 1.3 and 2.2 mo, respectively. Although the mother of each cub tried to encourage her offspring to suck, both cubs stopped drinking milk within days of ataxia first being noted.

Case 4 also occasionally whined when it moved, suggesting that movement caused pain. On the day of death, both cubs showed little response to social stimuli and were severely dehydrated.

Histopathology

The level of *Hepatozoon* infection detected by histologic examination of various tissues from eight individuals is shown in Table 1. All examined lung tissues contained either cyst-like structures containing protozoan stages and/or single or multiple parasite stages within the alveolar walls and most cases showed mild to severe interstitial pneumonia (Fig. 1). In some cases pneumonia was not clearly associated with protozoal infection. Heart muscle from five individuals contained encysted parasitic stages, sometimes in association with a focal mild necrotizing myocarditis with neutrophilic infiltrates. Three individuals (cases 1, 3, 4) showed evidence of systemic spread of infection with protozoal cysts to several organs including the liver, spleen, kidney, lymph node, stomach, and skeletal muscle. Case 3 had diffuse mild sinusoidal infiltration by neutrophils, lymphocytes, and plasma cells within the liver and multifocal mild to moderate interstitial nephritis with follicular aggregations of lymphocytes and plasma cells. Pathologic examination of one animal with clinical signs (case 4) revealed disseminated protozoal organisms in various organs. The lungs had moderate interstitial pneumonia with infiltration by neutrophils, lymphocytes, plasma cells, and macrophages as well as multiple protozoal cysts within the alveolar walls. Multiple protozoal cysts were also found within the spleen, and a single protozoal cyst was noted within the lamina propria of the stomach. Additionally, lymph nodes had moderate purulent lymphadenitis.

Molecular genetic analysis

We sequenced a portion of the 18S rRNA gene from six different isolates obtained from six infected spotted hyenas, including tissue from both cubs that

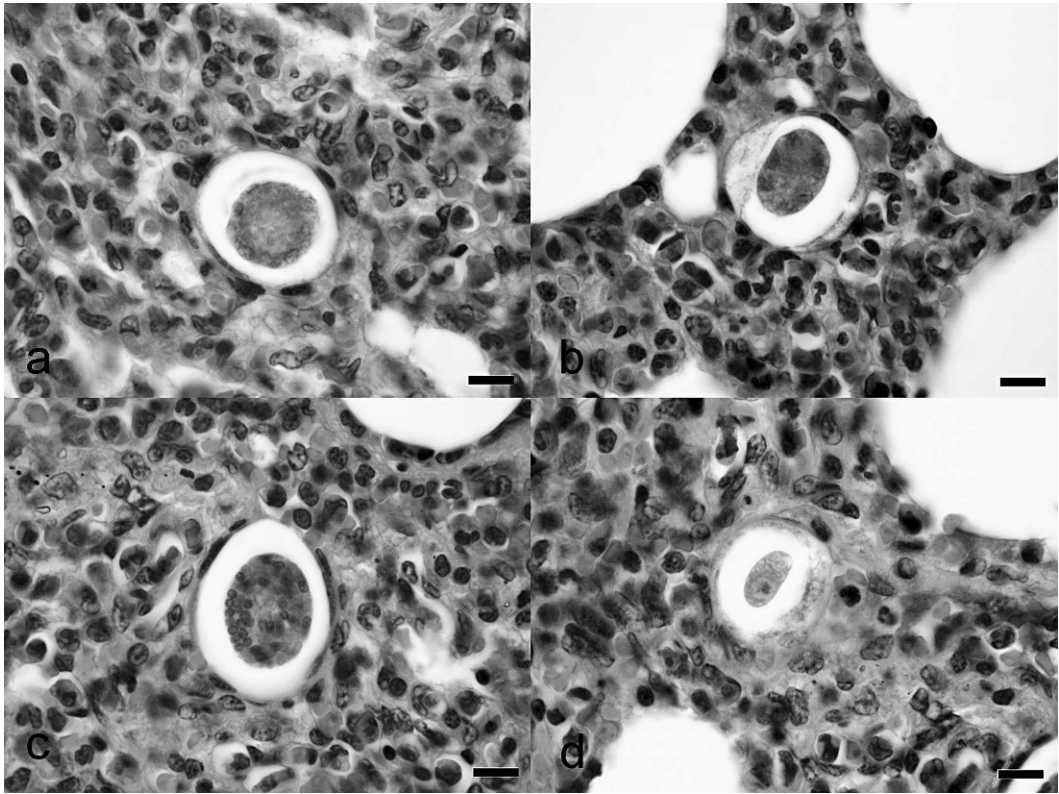


FIGURE 1. Light photomicrograph of *Hepatozoon* sp. infection in spotted hyena lung tissue: (a and b) immature meront with marginal nuclei; (c) mature meront with merozoites; (d) parasitized cells. Bar=10 μ m.

displayed clinical signs. All sequences were identical (*Hepatozoon* sp. “hyena”; Fig. 2). BLAST searches in the GenBank database resulted in best matches (100% identity) with 18S rRNA genes from a *Hepatozoon* sp. recently detected in domestic cats in Spain (Criado-Fornelio et al., 2006; termed *Hepatozoon* sp. “felis” in GenBank). The complete alignment included 21 archived isolates in addition to the “hyena” isolates from this study. In the phylogenetic analysis, the *Hepatozoon* sp. from Spanish cats and the *Hepatozoon* sp. isolated from Serengeti spotted hyenas formed a sister cluster with the *H. canis* group (Fig. 2). Comparison of sequence data from the longer clone fragment (853 bp) of the *Hepatozoon* sp. with the same fragment from the *Hepatozoon* sp. in Spanish cats revealed seven substitutions at positions 18, 20, 32, 35, 692, 754, and

843. Nucleotide identity among these sequences was therefore 99.2%.

DISCUSSION

Hepatozoon infections in wildlife are normally subclinical (McCully et al., 1975; Averbeck et al., 1990; Kocan et al., 2000; Simpson et al., 2006a, 2006b), and in this study, the majority of parasitized spotted hyenas did not show obvious clinical signs consistent with *Hepatozoon* infection before they died. Clinical signs consistent with those reported for *Hepatozoon* infections in domestic dogs (Hervas et al., 1995; Baneth et al., 1997; Vincent-Johnson et al., 1997) and experimentally infected coyote (*Canis latrans*) pups (Kocan et al., 2000) were observed in two young spotted hyena cubs. The death of both these young hyena cubs may indicate that *Hepatozoon*

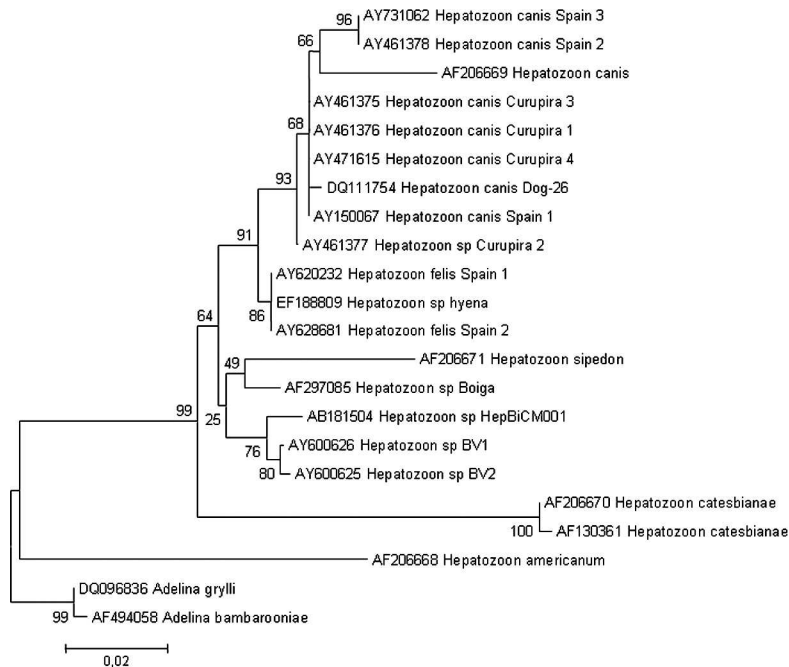


FIGURE 2. Phylogenetic relationship of *Hepatozoon* species isolated from spotted hyenas in Tanzania, East Africa, in relation to *Hepatozoon* species isolated from other domestic and wild carnivores based on a segment of the 18S rRNA gene.

infection is mostly associated with mortality in young spotted hyenas, and if so, the effect of *Hepatozoon* infection on wild carnivore populations may be underestimated.

Our results showed mild to severe pathogenic changes associated with *Hepatozoon* sp. infection in a variety of tissue including necrotizing myocarditis and interstitial pneumonia. Where interstitial pneumonia was not clearly associated with protozoal infection it may have been caused by the spread of small undetected stages (merozoites) in areas of increased cellularity or other undetermined infectious agents. We found *Hepatozoon* sp. infection in a variety of tissues, indicating systemic infection in some individuals (Table 1). McCully et al. (1975) also reported *Hepatozoon* sp. infection in similar tissues from eight adult spotted hyenas that were shot or died naturally in the Kruger National Park, South Africa. As *Hepatozoon* infections may compromise immune status, spotted hyenas infected

with *Hepatozoon* sp. may be more susceptible to other pathogens (Simpson et al., 2006b) and individuals with compromised immunity may be prone to higher levels of *Hepatozoon* parasitemia (Hervas et al., 1995; Baneth et al., 1997, 2001). Although *Hepatozoon* sp. infections in adult wild African carnivores have mostly been considered subclinical (Averbeck et al., 1990), we found that infections in young spotted hyenas were occasionally associated with mortality.

Our phylogenetic analysis demonstrated that the *Hepatozoon* species infecting spotted hyenas in the Serengeti National Park was identical to two isolates from domestic cats in Spain, and that the longer 853 bp fragment from the "hyena" *Hepatozoon* isolate showed only a few substitutions when compared to the Spanish cat isolates. The *Hepatozoon* sp. in spotted hyenas and domestic cats in Spain, although closely related to *H. canis*, showed sufficient genetic divergence from *H. canis* to propose that this "cat/hyena"

infecting *Hepatozoon* should be classified as a distinct species. Our results and those from other studies (Vincent-Johnson et al., 1997; Mathew et al., 2000; Perkins and Keller, 2001; Simpson et al., 2006b; Criado-Fornelio et al., 2006) demonstrate the value of molecular techniques to reveal the evolutionary relationship between morphologically similar *Hepatozoon* species.

The tick *Rhipicephalus sanguineus* is an important vector of *H. canis* worldwide (Baneth et al., 2001) and oocysts of *Hepatozoon* sp. have been reported in other tick species found on carnivores in Africa, including *Rhipicephalus simus* (McCully et al., 1975). Although the vector of the “hyena” *Hepatozoon* species described in this study is unknown, it is interesting to note that McCully et al. (1975) found the sporogenous phase of *Hepatozoon* sp. in *R. simus* ticks, but not in *R. sanguineus* ticks collected from infected spotted hyenas. Immature spotted hyenas often groom members of their social group to remove ticks; a social behavior that would facilitate transmission of *Hepatozoon* infection. Vertical intra-uterine transmission of the parasite may also occur, as demonstrated for *H. canis* infection in domestic dogs (Murata et al., 1993).

Although it is not known whether the “hyena” *Hepatozoon* species we describe infects other wild carnivore species in Africa and Europe, it is tempting to speculate that this may be so. Several African carnivores have been described with *Hepatozoon* infections. For example, Averbeck et al. (1990) reported *Hepatozoon* sp. infection in blood smears from all of 123 lions and all eight cheetahs (*Acinonyx jubatus*) screened in the Serengeti National Park, and Brocklesby and Vidler (1965) reported seven wild carnivore species in East Africa infected with an unspecified *Hepatozoon* infection. In South Africa, McCully et al. (1975) reported a high incidence of *Hepatozoon* schizonts in the tissues of spotted hyenas,

black-backed jackals (*Canis mesomelas*), cheetahs and leopards (*Panthera pardus*) in the Kruger National Park, and Van Heerden et al. (1995) found that 93% of 29 blood samples from African wild dogs (*Lycaon pictus*) contained gametocytes of *Hepatozoon* sp. that were presumed to be *H. canis*.

Our study found that although spotted hyenas in the Serengeti ecosystem are infected with a *Hepatozoon* species that is morphologically similar to *H. canis*, genetic differences between this “hyena” *Hepatozoon* variant and *H. canis* suggests that it may be a distinct species. Although *Hepatozoon* infection in adult spotted hyenas is thought to have little influence on survival, we observed mortality in young spotted hyenas that displayed clinical signs associated with *Hepatozoon* infections.

ACKNOWLEDGMENTS

We are grateful to the Tanzania Commission of Science and Technology, the Tanzania Wildlife Research Institute, and the Tanzania National Parks for permission to conduct this study. We thank A. Francis, C. Greulich, G. Orio, B. Peters, T. Shabani, D. Krumnow, and D. Viertel for assistance, and the Fritz-Thyssen-Stiftung, the Stifterverband der deutschen Wissenschaft, the Max-Planck-Gesellschaft, and the Leibniz-Institute for Zoo and Wildlife Research Berlin for financial support.

LITERATURE CITED

- AVERBECK, G. A., K. E. BJORK, C. PACKER, AND L. HERBST. 1990. Prevalence of hematozoans in lions (*Panthera leo*) and cheetahs (*Acinonyx jubatus*). *Journal of Wildlife Diseases* 26: 392–394.
- BANETH, G., I. AROCH, AND B. Z. PRESENTEY. 1997. *Hepatozoon canis* infection in a litter of Dalmatians. *Veterinary Pathology* 70: 201–206.
- , M. SAMISH, E. ALEKSEEV, I. AROCH, AND V. SHKAP. 2001. Transmission of *Hepatozoon canis* to dogs by naturally-fed or percutaneously-injected *Rhipicephalus sanguineus* ticks. *Journal of Parasitology* 87: 606–611.
- BROCKLESBY, D. W., AND B. O. VIDLER. 1965. Some parasites of East African wild animals. *East African Wildlife Journal* 3: 120–122.
- CONCEIÇÃO-SILVA, F. M., P. ABRANCHES, M. C. D.

- SILVA-PEREIRA, AND J. G. JANZ. 1988. Hepatozoonosis in foxes from Portugal. *Journal of Wildlife Diseases* 24: 344–347.
- CRÍADO-FORNELIO, A., J. L. RUAS, N. CRASADO, N. A. R. FARIAS, M. P. SOARES, G. MÜLLER, J. G. W. BRUM, M. E. A. BERNE, A. BULING-SARAÑA, AND J. C. BARBA-CARRETERO. 2006. New molecular data on mammalian *Hepatozoon* species (Apicomplexa: Adeleorina) from Brazil and Spain. *Journal of Parasitology* 92: 93–99.
- EAST, M. L., H. HOFER, J. H. COX, U. WULLE, H. WIJK, AND C. PITRA. 2001. Regular exposure to rabies virus and lack of symptomatic disease in Serengeti spotted hyenas. *Proceedings of the National Academy of Science U.S.A.* 98: 15026–15031.
- , K. MOESTL, V. BENETKA, C. PITRA, O. P. HÖNER, B. WACHTER, AND H. HOFER. 2004. Coronavirus infection of spotted hyenas in the Serengeti ecosystem. *Veterinary Microbiology* 102: 1–9.
- HAAS, L., H. HOFER, M. EAST, P. WOHLSEIN, B. LIESS, AND T. BARRETT. 1996. Canine distemper virus infection in Serengeti spotted hyenas. *Veterinary Microbiology* 49: 147–152.
- HERVAS, J., L. CARRASO, J. C. GOMEZ-VILLAMANDOS, A. MENDEZ, AND A. M. SIERRA. 1995. Acute fatal hepatozoonosis in a puppy: Histopathological and ultrastructural study. *Veterinary Record* 137: 518–519.
- HÖNER, O. P., B. WACHTER, S. SPECK, G. WIBBELT, A. LUDWIG, R. FYUMAGWA, P. WOHLSEIN, D. LIECKFELDT, H. HOFER, AND M. L. EAST. 2006. Severe *Streptococcus* infection in spotted hyenas in the Ngorongoro Crater, Tanzania. *Veterinary Microbiology* 115: 223–228.
- KOCAN, A. A., C. A. CUMMINGS, R. J. PANCIERA, J. S. MATHEW, S. A. EWING, AND R. W. BARKER. 2000. Naturally occurring and experimentally transmitted *Hepatozoon americanum* in coyotes from Oklahoma. *Journal of Wildlife Disease* 36: 149–153.
- KUMAR, S., K. TAMURA, I. B. JAKOBSEN, AND M. NEI. 2001. MEGA 2: Molecular evolutionary genetics analysis software. Arizona State University, Tempe, Arizona.
- MATHEW, J. S., R. A. VAN DEN BUSSCHE, S. A. EWINGS, J. R. MALAYER, B. R. LATHA, AND R. J. PANCIERA. 2000. Phylogenetic relationships of *Hepatozoon* (Apicomplexa: Adeleorina) based on molecular, morphology, and life-cycle characters. *Journal of Parasitology* 86: 366–372.
- McCULLY, R. M., P. A. BASSON, R. D. BIGALKE, V. DE VOS, AND E. YOUNG. 1975. Observations on naturally acquired natural hepatozoonosis of wild carnivores and dogs in the Republic of South Africa. Onderstepoort *Journal of Veterinary Research* 42: 117–134.
- MURATA, T., M. INOUE, S. TATEYAMA, Y. TAURA, AND S. NAKAMA. 1993. Vertical transmission of *Hepatozoon canis* in domestic dogs. *Journal of Veterinary Medical Science* 55: 867–868.
- PERKINS, S. L., AND A. K. KELLER. 2001. Phylogeny of nuclear small subunit rRNA genes of hemogregarines amplified with specific primers. *Journal of Parasitology* 87: 870–876.
- SIMPSON, V. R., R. J. PANCIERA, J. HARGREAVES, J. W. MCGARRY, S. F. E. SCHOLES, K. J. BROWN, AND R. J. BIRTLES. 2006a. Myocarditis and myositis due to infection with *Hepatozoon* species in pine martens (*Martes martes*) in Scotland. *Veterinary Record* 156: 442–446.
- , R. J. BIRTLES, K. J. BROWN, R. J. PANCIERA, H. BUTLER, AND N. DAVISON. 2006b. *Hepatozoon* species infection in wild red squirrels (*Sciurus vulgaris*) on the Isle of Wight. *Veterinary Record* 159: 202–205.
- SMITH, T. G. 1996. The genus *Hepatozoon* (Apicomplexa: Adeleina). *Journal of Parasitology* 82: 565–585.
- THOMPSON, J. D., T. J. GIBSON, F. PLEWNIK, F. JEANMOUGIN, AND D. G. HIGGINS. 1997. The Clustal X windows interphase: Flexible strategies for multiple sequence alignment aided by quality analysis tool. *Nucleic Acids Research* 25: 4876–4882.
- VAN HEERDEN, J., M. G. L. MILLS, M. J. VAN VUUREN, P. J. KELLY, AND M. J. DREYER. 1995. An investigation into the health status and diseases of wild dogs (*Lycaon pictus*) in the Kruger National Park. *Journal of the South African Veterinary Association* 66: 18–27.
- VINCENT-JOHNSON, N. A., D. K. MACINTIRE, D. S. LINDSAY, S. D. LENZ, G. BANETH, V. SHKAP, AND B. L. BLAGBURN. 1997. A new *Hepatozoon* species from dogs: Description of the causative agent of canine hepatozoonosis in North America. *Journal of Parasitology* 83: 1165–1172.

Received for publication 14 February 2007.