

## **OCCURRENCE OF VERTEBRAL OSTEOPHYTOSIS IN A MUSEUM SAMPLE OF WHITE-BEAKED DOLPHINS (LAGENORHYNCHUS ALBIROSTRIS) FROM DANISH WATERS**

Authors: Galatius, Anders, Sonne, Christian, Kinze, CarlChristian, Dietz, Rune, and Jensen, Jens-Erik Beck

Source: Journal of Wildlife Diseases, 45(1) : 19-28

Published By: Wildlife Disease Association

URL: <https://doi.org/10.7589/0090-3558-45.1.19>

---

BioOne Complete ([complete.BioOne.org](https://complete.BioOne.org)) is a full-text database of 200 subscribed and open-access titles in the biological, ecological, and environmental sciences published by nonprofit societies, associations, museums, institutions, and presses.

Your use of this PDF, the BioOne Complete website, and all posted and associated content indicates your acceptance of BioOne's Terms of Use, available at [www.bioone.org/terms-of-use](https://www.bioone.org/terms-of-use).

Usage of BioOne Complete content is strictly limited to personal, educational, and non - commercial use. Commercial inquiries or rights and permissions requests should be directed to the individual publisher as copyright holder.

---

BioOne sees sustainable scholarly publishing as an inherently collaborative enterprise connecting authors, nonprofit publishers, academic institutions, research libraries, and research funders in the common goal of maximizing access to critical research.

# OCCURRENCE OF VERTEBRAL OSTEOPHYTOSIS IN A MUSEUM SAMPLE OF WHITE-BEAKED DOLPHINS (*LAGENORHYNCHUS ALBIROSTRIS*) FROM DANISH WATERS

Anders Galatius,<sup>1,5</sup> Christian Sonne,<sup>2</sup> Carl Christian Kinze,<sup>3</sup> Rune Dietz,<sup>2</sup> and Jens-Erik Beck Jensen<sup>4</sup>

<sup>1</sup> Research Group for Comparative Zoology, Institute of Biology, University of Copenhagen, Universitetsparken 15, DK-2100 Copenhagen Ø, Denmark

<sup>2</sup> Department of Arctic Environment, National Environmental Research Institute, Frederiksborgvej 399, DK-4000 Roskilde, Denmark

<sup>3</sup> Falkoner Allé 35 1. th., DK-2000 Frederiksberg, Denmark

<sup>4</sup> University Hospital of Hvidovre, Kettegaards Allé 30, DK-2650 Hvidovre, Denmark

<sup>5</sup> Corresponding author (email: agjorgensen@bio.ku.dk)

**ABSTRACT:** The occurrence of pathologic new bone formation in the vertebral column was studied in 46 skeletons of the white-beaked dolphin (*Lagenorhynchus albirostris*) stranded in Denmark between 1903 and 2002 and held in the collections of the Zoological Museum, University of Copenhagen. New bone formation was evident in 18 (72%) of 25 physically mature specimens and in one of 21 physically immature specimens. This pattern of occurrence is consistent with spondylosis deformans, which is caused by degeneration of the intervertebral disk. In general, females seemed to be more susceptible, exhibiting a higher number of affected vertebrae and more severe cases. Lesions were predominantly detected in the lumbar and cranial caudal vertebra. Data on blubber thickness were available for part of the sample; one of the most heavily afflicted specimens had the thickest recorded blubber, indicating that secondary bone formation leading to blocks of fused vertebrae had not necessarily impaired the body condition of afflicted specimens. However, age determinations conducted on the sample revealed that none of the most severe cases occurred among the oldest animals, implying that these severe cases may cause premature fatality.

**Key words:** Age, gender, osteophytosis, spondylosis deformans, vertebral lesions, white-beaked dolphin.

## INTRODUCTION

Pathologic new bone formation in the vertebral column has been reported in many cetacean species including harbour porpoise (*Phocoena phocoena*; Kinze, 1986; Baker and Martin, 1992; Kompanje, 1995a), bottlenose dolphin (*Tursiops truncatus*; Kompanje, 1995a), white-beaked dolphin (*Lagenorhynchus albirostris*; van Bree and Nijssen, 1964; van Bree and Duguy, 1970; Kompanje, 1995a,b), long-finned pilot whales (*Globicephala melas*; Cowan, 1966), belugas (*Delphinapterus leucas*; Martineau et al., 1988), Bryde's whale (*Balaenoptera edeni*; Paterson, 1984), and undetermined species (Lagier, 1977) under diverse diagnoses. The most common diagnosis is spondylosis deformans (discarthrosis), a degeneration of the annulus fibrosis of the intervertebral disk leading to secondary bone formation. Other authors have attributed the ob-

served conditions to infection (Cowan, 1966; Morton, 1978; Paterson, 1984; Alexander et al., 1989; Kompanje, 1995b; Kompanje, 1999; Sweeny et al., 2005) or noninfectious inflammation (Kompanje, 1999).

In a study like the present (and most of those listed above), which employs museum material, many diagnostic characters are not available (e.g., microscopy of fresh specimens and genetic and longitudinal data for the specimens). Also, cetacean equivalents of human or other mammalian pathologies may not share identical expressions in the observed chronic lesions of the bones. Therefore, classification and firm diagnosis of the observed lesions, based on human medicine, are contentious.

In more extreme cases, proliferation of secondary bone growth leads to ankylosis of two or more vertebrae, limiting the range of movement in the vertebral

TABLE 1. Frequencies and number of specimens with osteophytosis and ankylosis of vertebrae due to osteophytosis among 46 white-beaked dolphins collected from Danish waters between 1903 and 2002. The ages of the specimens in the relevant category are listed. Specimens with lesions in the relevant category are typed in bold.

Groups	Physically immature	Physically mature
Females, osteophytosis	11% (1/9) 6,6,8,8,8,9,11,11, <b>12</b>	69% (9/13) <b>12,13,14,16,21,21,22,23,28,30,31,33,34</b>
Females, ankylosis	0% (0/9) 6,6,8,8,8,9,11,11,12	62% (8/13) <b>12,13,14,16,21,21,22,23,28,30,31,33,34</b>
Males, osteophytosis	0% (0/12) 0,3,7,7,7,7,8,10,10,12,12,14	75% (9/12) 12,12, <b>13,14,14,16,18,19,20,20,28,39</b>
Males, ankylosis	0% (0/12) 0,3,7,7,7,7,8,10,10,12,12,14	25% (3/12) 12,12,13,14, <b>14,16,18,19,20,20,28,39</b>

column and, for a cetacean, potentially causing deficits in swimming performance and hence the ability to feed and survive. Sweeny et al. (2005) speculated that mass strandings in the highly social long-finned pilot whale may be attributable to intervertebral ankylosis and pain caused by ankylosing spondylitis (spondylitis ankylopoetica). It was theorized that healthy animals of this highly social species would follow afflicted whales onto the beach.

The white-beaked dolphin seems to be particularly susceptible to vertebral lesions. Kompanje (1995a) found osteophytosis in 52% (15 out of 29) of the adult specimens, a much-higher proportion than what has been reported in other species. This high prevalence was also seen in our sample, along with a high incidence of intervertebral ankylosis caused by the secondary bone growth. By comparing occurrence and severity of pathologic deformations in white-beaked dolphins with health status as gleaned from necropsy records, we attempted to evaluate whether the condition can induce live strandings, as hypothesized by Sweeny et al. (2005). Furthermore, this is the first comprehensive study of vertebral lesions in which age estimates from dental growth layer groups were available to assess timing of onset and development in a cetacean species.

MATERIALS AND METHODS

Vertebral columns of 46 white-beaked dolphin skeletons (22 females and 24 males)

from Danish waters collected between 1903 and 2002, all held in the collection of the Zoological Museum of Copenhagen, were examined for vertebral lesions and pathologic new bone formation. Lesions were categorized by severity after Nathan (1962); the same categorization was used by Kompanje (1995a). The categorization is as follows: Grade 1 = only small hyperostosis evident; Grade 2 = protrusion of bone into the orthogonal plane to the vertebral column; Grade 3 = the osteophytes have a characteristic “parrot-beak” appearance; Grade 4 = ankylosis between osteophytes of adjacent vertebrae (Figs. 1–4).

Unlike Kompanje (1995a), we also recorded lesions in the cervical vertebrae. Kompanje opted not to include the cervicals because of their irregular surface, which may hinder observation of minor osteophytes and the nonpathologic ankylosis that occurs between these vertebrae in cetaceans. In this region, we recorded cases of certain osteophytosis and categorized cases as severity Grade 4 when osteophytes covered more than one vertebral body.

Specimens were deemed physically mature when all epiphyses of the vertebral column showed full ankylosis. The mean age at full vertebral maturity is consistent with the age at termination of growth in this species (Galatius and Kinze, 2007). Afflicted specimens were not found to show any inconsistencies relative to nonafflicted specimens, with regard to vertebral maturation.

Age determinations were made by decalcifying teeth in 5% HNO<sub>3</sub> and cutting 25-μm central longitudinal sections on a Leica CM 1510 cryostat (Leica Microsystems, Wetzlar, Germany) by the method previously described by Dietz et al. (1991). Sections were stained in hematoxylin and mounted on microscope slides. Examination was performed using transmitted light in a Leica DMLB microscope (Leica Microsystems) with 50× magni-

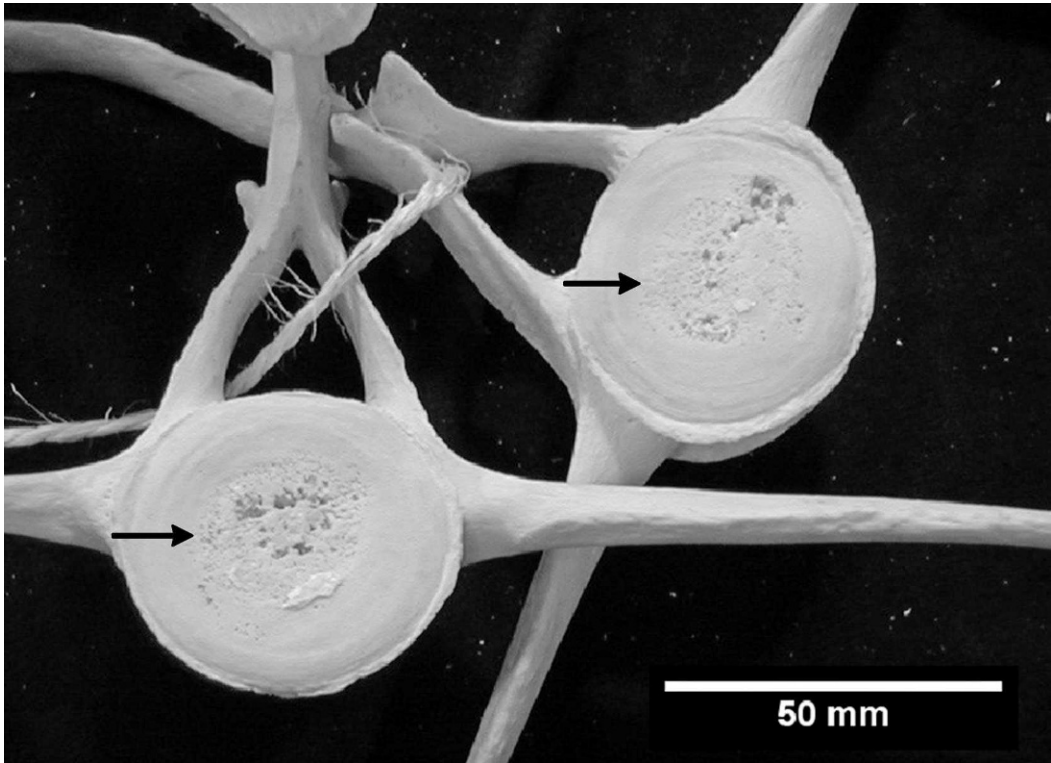


FIGURE 1. White-beaked dolphin. Lumbar 2 in caudal aspect and lumbar 3 in cranial aspect. Note marginal osteophytosis, severity Grade 2, and commencing degeneration of the epiphyseal disks. 22-yr-old female (CN604) collected in 1989.

fication using filters (green, blue, and grey). Digital photographs were taken using a Leica DC 300 camera (Leica Microsystems). Ages were inferred from the number of dentinal or cemental growth layer groups (GLGs); each GLG was counted as 1 yr. A GLG was defined as consisting of a relatively broad band of light-stained cementum or dentine and a narrow band of darker-stained cementum or dentine.

Blubber thickness measurements were extracted from necropsy records. Blubber thickness, measured ventrally in a position between the posterior margins of the flipper bases, was selected as a rough estimate of the body condition.

## RESULTS

### Diagnosis

Vertebral columns had classic degenerative changes in agreement with spondylosis; a narrow space between adjacent vertebral bodies indicating degenerative changes of the intervertebral disks and

bony overgrowths with osteophytes predominantly at the ventral, lateral, and, less commonly, dorsal aspects of the cranial and caudal margins of vertebral bodies. In some regions the affliction was very severe, producing a conglomerate of several vertebral bodies. X-ray examination (Fig. 5) supported this interpretation, and there were no signs of infectious spondylitis, which causes lesions with bone loss in humans (Fernandez et al., 2000; Mulleman et al., 2006). Without microscopy of the fresh specimens, however, it was not possible to reliably distinguish degeneration and inflammation as causes for the observed conditions.

### Occurrence

Secondary bone growth was only evident in one physically immature specimen; a 12-yr-old female showing Grade 2




FIGURE 2. White-beaked dolphin. Lumbars 14–17 in lateral–ventral aspect. Note ‘parrot-beak’ osteophytes, severity Grade 3. 2-yr-old male (CN258) collected in 1984.

osteophytes in three vertebrae in the lumbar region. This specimen measured 258 cm, more than the mean length of physically mature females. The youngest specimens showing osteophytosis, beside the physically immature female, were two physically mature 12-yr-old females.

Of 13 physically mature females, nine (69%) showed osteophytosis, while nine of 12 (75%) physically mature males showed osteophytosis. The severity of the observed osteophytosis varied greatly. Least affected was a 20-yr-old male with Grade 2 osteophytes in two caudal vertebrae, while the most affected specimen, a 16-yr-old female, had Grade 3 osteophytes in five caudal vertebrae and pathologic ankylosis of 15 lumbar vertebrae. Eleven of 25 physically mature specimens had ankylosed vertebrae due to new bone formation. Overall, there was a tendency for the severity to be greater in females, with more individuals showing

ankylosis of individual vertebrae (Fig. 6). On average, physically mature females had 3.8 ankylosed vertebrae (mean age: 20.8 yr). In males, this average was 1.6 (mean age: 19.5 yr). The two most heavily afflicted specimens, females of 21 yr and 16 yr, had 10 and 15 fused vertebrae, respectively. The tendency for physically mature females to have more ankylosed vertebrae than males was not statistically significant  $\alpha=0.05$  (Mann–Whitney  $U=108.5$ ;  $P=0.07$ ; Mann and Whitney, 1947). Occurrence of osteophytosis and intervertebral ankylosis in the entire sample, along with the ages of the specimens, are given in Table 1.

The four most heavily afflicted individuals were all below 25 yr of age, while eight specimens older than 25 yr had less severe conditions, suggesting that severe cases of the disease may cause premature mortality (see Fig. 7).



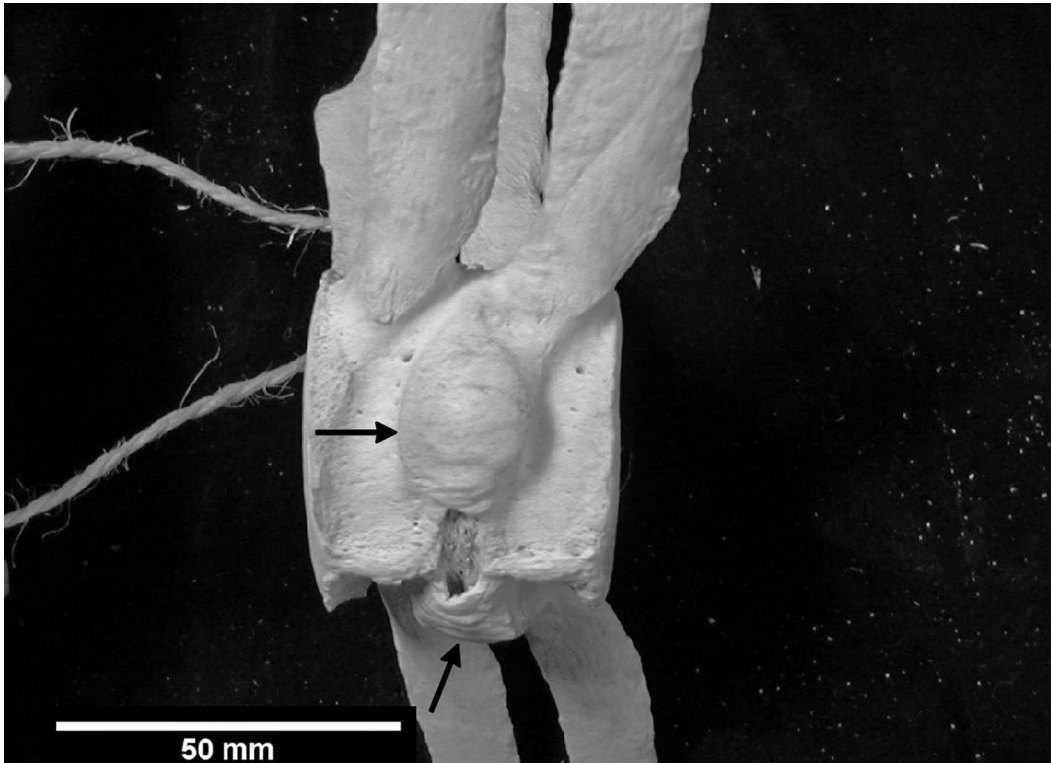


FIGURE 3. White-beaked dolphin. Lumbars 19 and 20 in lateral-ventral aspect. Note ankylosed 'parrot-beak' osteophytes, severity Grade 4. 16-yr-old female (CN 740) collected in 1990.

Osteophytes were found in the entire vertebral column except for the posterior caudal segments, with a tendency for a higher prevalence in lumbar and anterior caudal segments (Fig. 8). There was only one case of osteophytosis caudal to the 24th caudal segment. At this location, the spinous and transverse processes are much reduced, implying a much smaller biomechanical loading on these vertebrae.

Data on blubber thickness were available for 12 of the physically mature specimens. No data on blubber thickness are available from other studies of white-beaked dolphins. Blubber thickness in harbour porpoises in Danish waters exhibits a pronounced seasonal fluctuation with minima in the summer (Lockyer et al., 2003). Similar fluctuations would be expected from other small cetaceans inhabiting the same waters. Other causes

of variation in harbour porpoises are total length (large adult animals have thinner blubber), sex (adult males have thicker blubber than adult females that are not pregnant or lactating), and reproductive status (lactating females having thinner blubber than pregnant females; Lockyer, 1995). The specimens used in this analysis were all adult, and only one was reproductively active, a pregnant animal without osteophytosis and 28 mm of blubber, the thickest recorded in the sample. Apart from this, sex and season should be taken into account as sources of variation. The data are presented in Figure 8. Of the 12 specimens from which data were available, three showed osteophytosis of Grade 4, having 15, 10, and six ankylosed vertebrae, respectively. The most heavily afflicted specimen, with 15 fused vertebrae, had the thickest blubber layer in the sample (28 mm). The

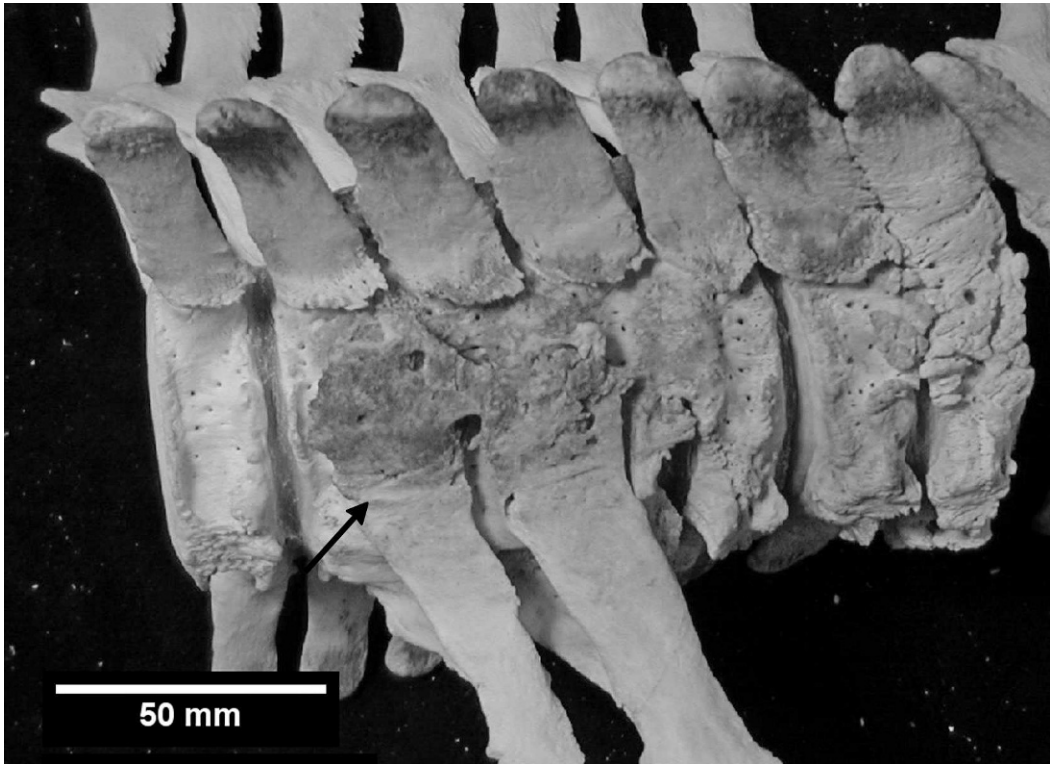


FIGURE 4. White-beaked dolphin. Caudals 10–17 lateral–ventral aspect. Note progressed ankylosis fusing a block of four vertebrae. 16-yr-old female (CN740) collected in 1990.

other two specimens had thinner blubber; this was not unusual for the month in which they were collected (Fig. 8).

#### DISCUSSION

Because osteophytosis was exclusively observed in specimens that were physically mature (except for one specimen of adult size), it seems most probable that degeneration, and hence spondylosis deformans, is the most common cause of the vertebral lesions seen in white-beaked dolphins. This is also in agreement with the available diagnostic criteria. There was a tendency towards a higher frequency in the lumbar and cranial caudal vertebrae. This may correlate to a high level of mechanical stress in this area due to the combination of a high degree of dorso–ventral flexion and higher biomechanical loading of these segments. The occurrences of osteophytosis in the

cervical series of two specimens, however, are at odds with the general explanation of degeneration as a cause, as movement between these vertebrae should be minimal.

In general, it is not possible from X rays to distinguish between bone changes caused by degenerative or inflammatory disease. However, infectious disease affecting the disks or the bone would cause loss of bone in limited lesions (Fernandez et al., 2000; Mulleman et al., 2006); this was not detected in our material. The observed patterns of the affected individuals in accordance with age, mechanical force, and development of lesions involving degenerative changes of the intervertebral disks all point towards degeneration, and hence, spondylosis deformans as the primary cause of the observed conditions. We are not aware of a specific inflammatory disease entity that should mimic these changes.

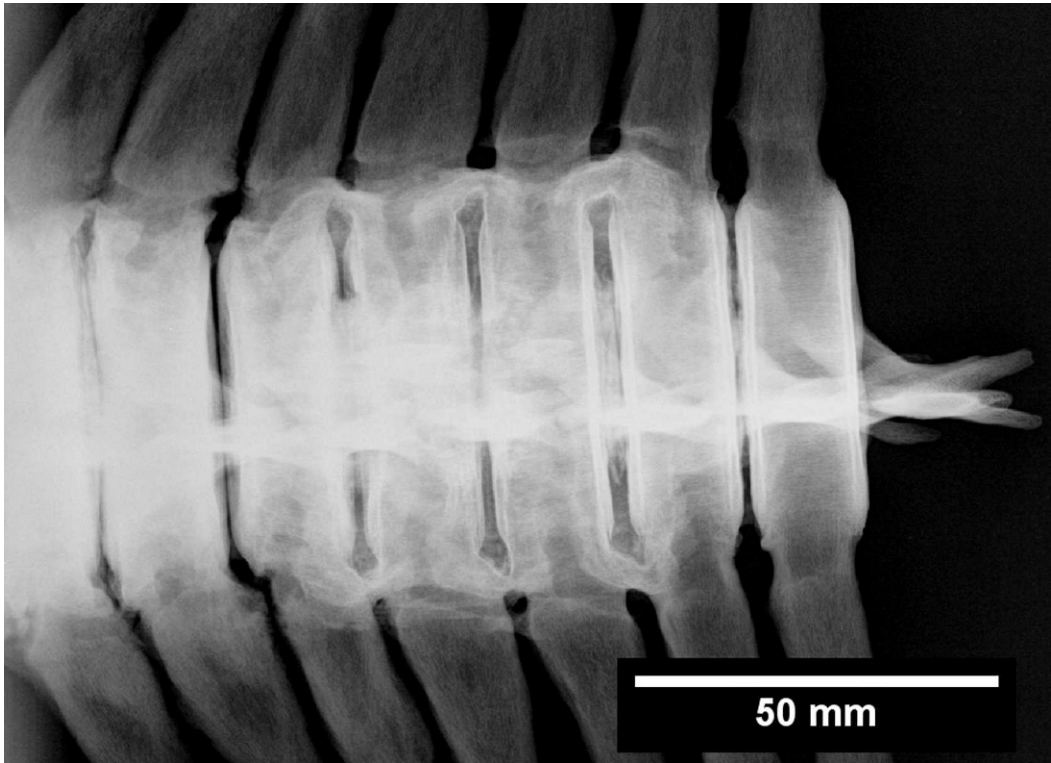


FIGURE 5. White-beaked dolphin. Radiograph of caudals 10–16 in ventral aspect, same block and animal as shown in Figure 4. Osteophytes are more X-ray dense (lighter shades).

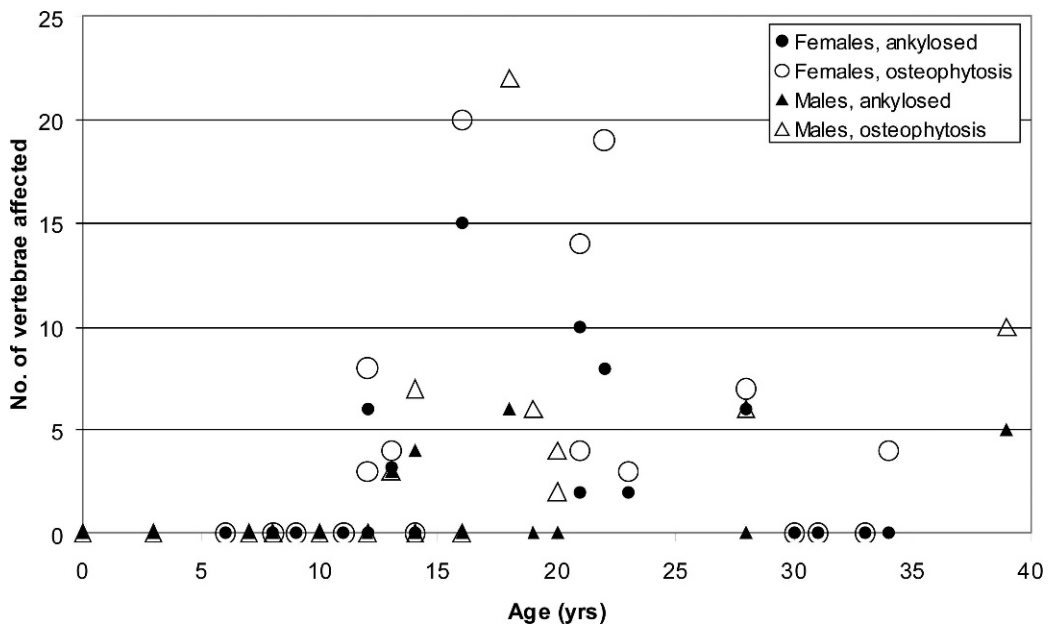


FIGURE 6. Number of vertebrae with osteophytosis and number of ankylosed vertebrae vs. age from 46 white-beaked dolphins from Danish waters collected between 1903 and 2002.



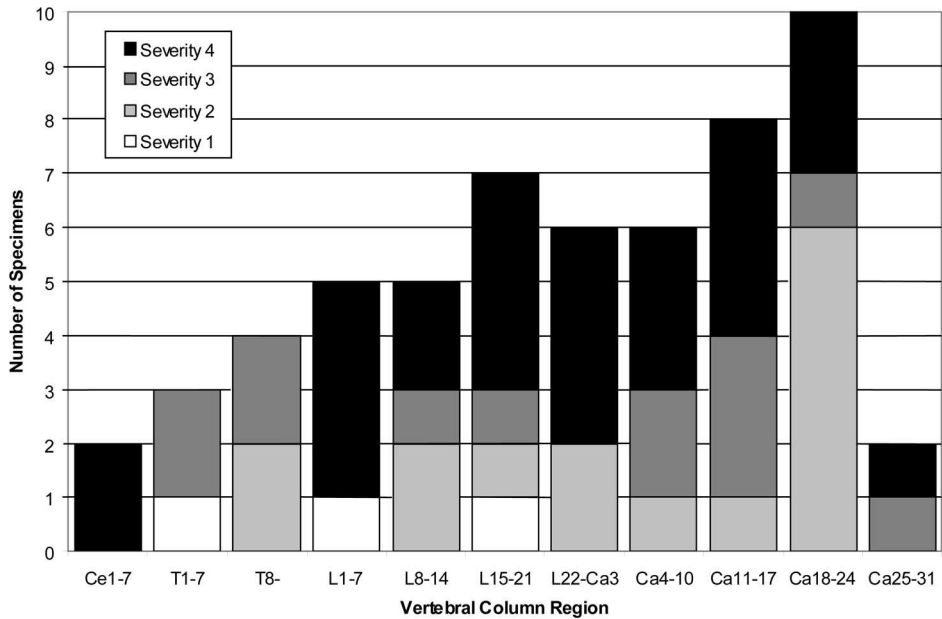


FIGURE 7. Distribution of osteophytosis along the vertebral column of 46 white-beaked dolphins from Danish waters collected between 1903 and 2002. The number of specimens afflicted with osteophytosis is given. The highest severity grade found in the region was recorded. Ce=Cervical, T=Thoracic, L=Lumbar, Ca=Caudal.

The present investigation confirms the findings of Kompanje (1995a) that osteophytosis is common in white-beaked dolphins in the North Sea. Furthermore, like Kompanje (1995a), we also found a higher prevalence and severity in females compared to males. In human populations, there is usually a preponderance of

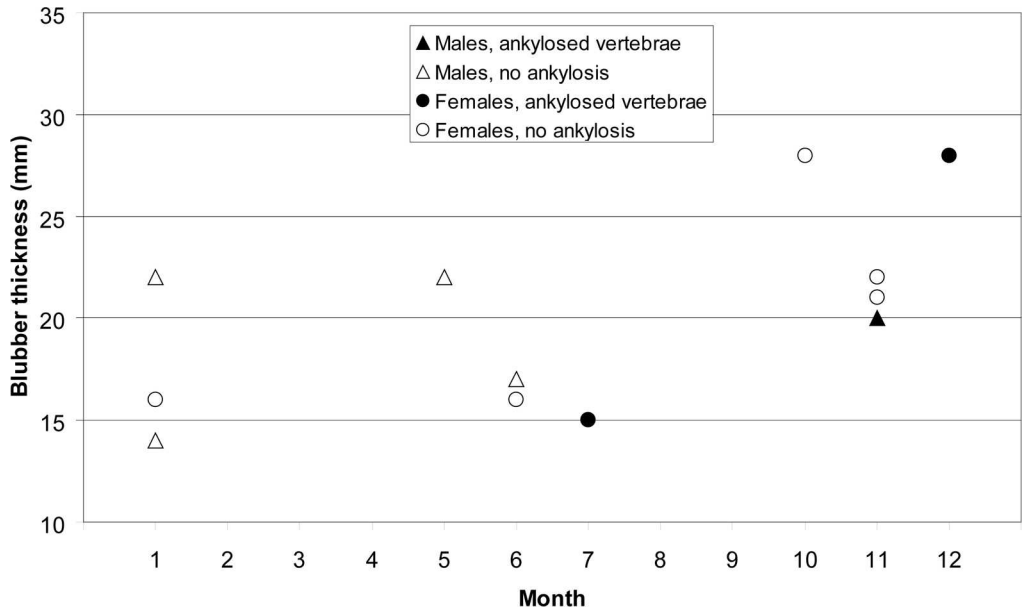


FIGURE 8. Blubber thickness vs. month of year for 12 physically mature specimens of white-beaked dolphin from Danish waters, with and without vertebrae ankylosed due to osteophytosis.

males among individuals affected by vertebral osteophytosis. (Taitz, 1999; Van der Merwe et al., 2006). In archaeological samples, this pattern (to some extent) varies with the type of labor predominately performed by the sexes of the culture in question (Bridges, 1992). As in humans, in white-beaked dolphins there is sexual dimorphism with the larger, and presumably stronger, males (Kinze, 2002), but we do not know of any disparities in physical activities, such as those found in humans, that might explain this difference. Without behavioral disparity, the most obvious factors behind this pattern would be sexual differences in endocrinology or metabolism.

Contrary to the almost exclusive occurrence of vertebral lesions in mature specimens in this study, Sweeny et al. (2005) found that 46% of the specimens with vertebral osteophytosis in their sample of western Atlantic long-finned pilot whales were immature. This suggests that vertebral lesions in these two species generally have different etiologies; where degeneration seems to be the most common cause in white-beaked dolphins, inflammation, infection, or both seems to be much more prevalent in the pilot whales.

The youngest specimen to show osteophytosis was 12 yr old, while 21 specimens younger than 12 yr old were without lesions. Only four of 17 specimens older than 15 yr did not show any sign of the disease, indicating that most specimens develop some degree of osteophytosis in their lifetime.

Almost half of the physically mature specimens in the sample had vertebrae fused due to osteophytosis, probably interfering with swimming efficiency. Among the specimens for which data on blubber thickness was available, one of the most heavily afflicted animals showed the highest recorded blubber thickness, while two other specimens with ankylosis fell within the general pattern. This indicates that they were in good health, although it

is hard to deduce from a sample of stranded animals what constitutes a healthy blubber layer. There is some indication that very severe cases can be fatal, because none of the specimens more than 25 yr old exhibited cases of very high severity. Still, the fact that the very severe cases observed in some specimens (up to 15 fused vertebrae) can be developed at all implies that the dolphins can live with a considerable amount of fusion between vertebrae.

The tolerance of ankylosed vertebrae shown by white-beaked dolphins challenge the hypothesis of Sweeny et al. (2005) that spondylitis ankylopoetica should be a contributing factor to stranding in long-finned pilot whales. However, pilot whales may be less tolerant to the presence of blocks of fused vertebrae, and it is also possible that the different age susceptibility for osteophytosis in this species may impact its clinical significance.

#### ACKNOWLEDGMENTS

The Natural History Museum of Denmark (Zoological Museum) is thanked for access to the cetacean collection and, in particular, M. Andersen for his assistance during our work in the collections. We thank H. Andreasen, K. V. Petersen, P. B. Jørgensen, and S. R. Sørensen for their participation in the age determinations. The National Environmental Research Institute, Department of Arctic Environment, provided the equipment for the age determination. Two anonymous reviewers are thanked for their helpful comments on earlier drafts of this paper.

#### LITERATURE CITED

- ALEXANDER, J. W., M. A. SOLANGI, AND L. S. RIEGEL. 1989. Vertebral osteomyelitis and suspected diskospondylitis in an Atlantic bottlenose dolphin (*Tursiops truncatus*). *Journal of Wildlife Diseases* 25: 118–121.
- BAKER, J. R., AND A. R. MARTIN. 1992. Causes of mortality and parasites and incidental lesions in harbour porpoises (*Phocoena phocoena*) from British waters. *Veterinarian Record* 130: 554–558.
- BRIDGES, P. S. 1992. Prehistoric arthritis in the Americas. *Annual Review of Anthropology* 21: 67–91.

- COWAN, D. F. 1966. Pathology of the pilot whale. *Archaeological Pathology* 82: 178–189.
- DIETZ, R., M. P. HEIDE-JØRGENSEN, J. TEILMANN, N. VALENTIN, AND T. HÄRKÖNEN. 1991. Age determination in European harbour seals *Phoca vitulina* L. *Sarsia* 76: 17–21.
- FERNANDEZ, M., C. L. CARROL, AND C. J. BAKER. 2000. Discitis and vertebral osteomyelitis in children: An 18-year review. *Pediatrics* 105: 1299–1304.
- GALATIUS, A., AND C. C. KINZE. 2007. Aspects of life history of white-beaked dolphins from Danish waters. *European Research on Cetaceans* 21: 1 p. [abstract]
- KINZE, C. C. 1986. On the occurrence of spondylitis deformans in a sample of harbour porpoises (*Phocoena phocoena*) taken in Danish waters. *Aquatic Mammals* 12: 25–27.
- . 2002. White-beaked dolphin. In *Encyclopedia of marine mammals*, W. F. Perrin, B. Würsig and J. G. M. Thewissen (eds.). Academic Press, London, UK, pp. 1332–1334.
- KOMPANJE, E. J. O. 1995a. On the occurrence of spondylosis deformans in white-beaked dolphins *Lagenorhynchus albirostris* (Gray, 1846) stranded on the Dutch coast. *Zoologische Mededelingen Leiden* 69: 231–250.
- . 1995b. Differences between spondylo-osteomyelitis and spondylosis deformans based on museum material. *Aquatic Mammals* 21: 199–203.
- . 1999. Considerations of the comparative pathology of the vertebrae in Mysticeti and Odontoceti: Evidence for the occurrence of discarthrosis, zygarthrosis, infectious spondylitis and spondyloarthritis. *Zoologische Mededelingen Leiden* 73: 99–130.
- LAGIER, R. 1977. Spondylosis in the whale—An anatomicoradiologic study of an osteophytes. *Scandinavian Journal of Rheumatology* 6: 245–249.
- LOCKYER, C. 1995. Aspects of the morphology, body fat condition and biology of the harbour porpoise, *Phocoena phocoena*, in British waters. Reports of the International Whaling Commission, Special Issue 16: 199–209.
- , G. DESPORTES, K. HANSEN, S. LABBERTÉ, AND U. SIEBERT. 2003. Monitoring growth and energy utilisation of the harbour porpoise (*Phocoena phocoena*) in human care. *NAMMCO Scientific Publications* 5: 107–120.
- MANN, H. B., AND D. R. WHITNEY. 1947. On a test of whether one of two random variables is stochastically larger than the other. *Annals of Mathematical Statistics* 18: 50–60.
- MARTINEAU, D., A. LAGACE, P. BELAND, R. HIGGINS, D. ARMSTRONG, AND L. R. SHUGART. 1988. Pathology of stranded beluga whales (*Delphinapterus leucas*) from the St. Lawrence estuary, Quebec, Canada. *Journal of Comparative Pathology* 98: 287–311.
- MORTON, B. 1978. Osteomyelitis of the spine of a dolphin. *Journal of the American Veterinary Medical Association* 173: 1109–1110.
- MULLEMAN, D., P. PHILIPPE, E. SENNEVILLE, C. COSTES, L. FAGES, X. DEPREZ, R. M. FLIPO, AND B. DUQUESNOY. 2006. Streptococcal and enterococcal spondylodiscitis (vertebral osteomyelitis). High incidence of infective endocarditis in 50 cases. *Journal of Rheumatology* 33: 91–97.
- NATHAN, H. 1962. Osteophytes of the vertebral column. *Journal of Bone and Joint Surgery* 44: 243–268.
- PATERSON, R. A. 1984. Spondylitis deformans in a Bryde's whale (*Balaenoptera edeni* Anderson) stranded on the southern coast of Queensland. *Journal of Wildlife Diseases* 20: 250–252.
- SWEENEY, M. M., J. M. PRICE, G. S. JONES, T. W. FRENCH, G. A. EARLY, AND M. J. MOORE. 2005. Spondylitic changes in long-finned pilot whales (*Globicephala melas*) stranded on Cape Cod, Massachusetts, USA, between 1982 and 2000. *Journal of Wildlife Diseases* 41: 717–727.
- TAITZ, C. 1999. Osteophytosis of the cervical spine in South African blacks and whites. *Clinical Anatomy* 12: 103–109.
- VAN BREE, P. J. H., AND R. DUGUY. 1970. Sur quelques aberrations pathologiques chez les petits cétacés. *Der Zoologische Garten* 39: 11–15.
- , AND H. NIJSSEN. 1964. On three specimens of *Lagenorhynchus albirostris* Gray, 1846 (Mammalia, Cetacea). *Beaufortia* 11: 85–93.
- VAN DER MERWE A. E., M. Y. IŞCAN, AND E. N. L'ABBÈ. 2006. The pattern of vertebral osteophyte development in a South African population. *International Journal of Osteoarchaeology* 16: 459–464.

Received for publication 25 June 2007.