

Sheep-associated Malignant Catarrhal Fever in Free-ranging Moose (*Alces alces*) in Saskatchewan, Canada

Authors: Neimanis, Aleksija S., Hill, Janet E., Jardine, Claire M., and Bollinger, Trent K.

Source: Journal of Wildlife Diseases, 45(1) : 213-217

Published By: Wildlife Disease Association

URL: <https://doi.org/10.7589/0090-3558-45.1.213>

BioOne Complete (complete.BioOne.org) is a full-text database of 200 subscribed and open-access titles in the biological, ecological, and environmental sciences published by nonprofit societies, associations, museums, institutions, and presses.

Your use of this PDF, the BioOne Complete website, and all posted and associated content indicates your acceptance of BioOne's Terms of Use, available at www.bioone.org/terms-of-use.

Usage of BioOne Complete content is strictly limited to personal, educational, and non - commercial use. Commercial inquiries or rights and permissions requests should be directed to the individual publisher as copyright holder.

BioOne sees sustainable scholarly publishing as an inherently collaborative enterprise connecting authors, nonprofit publishers, academic institutions, research libraries, and research funders in the common goal of maximizing access to critical research.

Sheep-associated Malignant Catarrhal Fever in Free-ranging Moose (*Alces alces*) in Saskatchewan, Canada

Aleksija S. Neimanis,^{1,4,5} Janet E. Hill,² Claire M. Jardine,³ and Trent K. Bollinger¹ ¹ Canadian Cooperative Wildlife Health Centre, Department of Veterinary Pathology, Western College of Veterinary Medicine, 52 Campus Dr., University of Saskatchewan, Saskatoon, Saskatchewan S7N 5B4, Canada; ² Department of Veterinary Microbiology, Western College of Veterinary Medicine, 52 Campus Dr., University of Saskatchewan, Saskatoon, Saskatchewan S7N 5B4, Canada; ³ Department of Pathobiology, Ontario Veterinary College, Guelph, Ontario, Canada; ⁴ Current address: National Veterinary Institute, SE-75189 Uppsala, Sweden; ⁵ Corresponding author (email: aleksija.neimane@sva.se)

ABSTRACT: Malignant catarrhal fever (MCF) is a sporadic disease of artiodactyls caused by several viruses in the Gammaherpesvirinae. We report two cases of MCF in free-living moose (*Alces alces*) from Saskatchewan. One was a thin, dehydrated, adult male found recumbent in 2006. At necropsy, ulcers were found in the intestine, bladder, and corneas. Microscopically, there was lymphocytic vasculitis and perivasculitis in many organs with infrequent fibrinoid necrosis. Ovine herpes virus-2 (OHV-2) was identified by polymerase chain reaction. A segment of the herpesviral DNA polymerase gene was 99% identical to published OHV-2 sequences. During a retrospective search of earlier cases, a female moose with lymphoplasmacytic meningoencephalitis examined in 2003 was identified and OHV-2 was amplified from paraffin-embedded tissues from this animal. We believe this to be the first description of MCF in free-ranging moose in North America. Infection requires contact with infected sheep or goats, and MCF in moose may become more prevalent as moose distribution continues to expand into agricultural prairie.

Key words: *Alces alces*, Canada, malignant catarrh, MCF, moose, ovine herpesvirus-2, Saskatchewan, vasculitis.

Malignant catarrhal fever (MCF) is a disease of artiodactyls caused by several viruses in the Gammaherpesvirinae. These viruses are maintained in specific hosts, and although clinical disease usually does not occur in the natural host, systemic disease can result when other species are infected (Heuschele and Reid, 2001; Li et al., 2005). Cervids are susceptible to numerous strains, and ovine herpesvirus-2 (OHV-2) and caprine herpesvirus-2 (CpHV-2) have caused disease in moose (*Alces alces*) in Scandinavia (Warsame and Steen, 1989; Vikoren et al., 2006). Sero-

logic evidence of exposure MCF viruses was documented in 1% (three of 219) of moose in Alaska, USA (Zarnke et al., 2002). In North America, the only report of MCF in a moose was from a captive animal in Wyoming, USA (Williams et al., 1984). We present two cases of MCF in wild moose in North America.

On 21 August 2006, a free-ranging adult male moose found near Brownlee, Saskatchewan (50°46'N, 106°2'W) was euthanized after it had been observed in sternal recumbency for 3 days and transported to the Canadian Cooperative Wildlife Health Centre (CCWHC) in Saskatoon, Saskatchewan, for necropsy. It was in poor nutritional condition and severely dehydrated. There were bilateral corneal ulcers and opacity and multiple erosions and ulcers on the mucosa of the small intestine and urinary bladder. Several intestinal ulcers had perforated, resulting in fibrinous peritonitis.

Tissues collected at necropsy were fixed in 10% neutral-buffered formalin, dehydrated in graded alcohol, cleared in xylene, and embedded in paraffin. Seven-micrometer sections were stained using Mayer's hematoxylin and eosin (Luna, 1968). Microscopically, blood vessels in the urinary bladder, intestine, mesentery, adrenal gland, lung, primary bronchus, uvea, retina, and conjunctiva were cuffed by lymphocytes and occasional plasma cells, numerous vessel walls were expanded by lymphocytes, and variable lymphocytic infiltrates were seen within the surrounding parenchyma (Fig. 1). The tunica media of scattered arterioles and

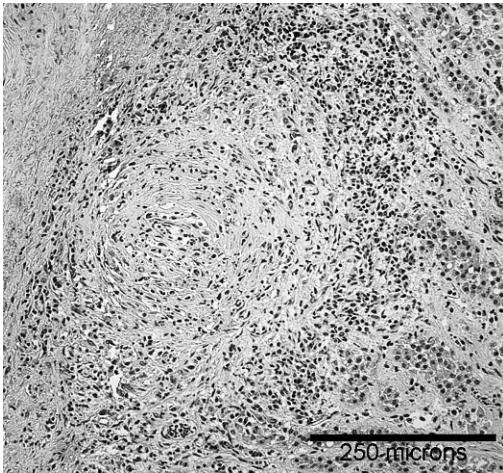


FIGURE 1. Lymphocytic vasculitis and perivasculitis in a subcapsular arteriole in the adrenal gland of a male moose (*Alces alces*) from Saskatchewan, Canada. Hematoxylin and eosin.

arteries in the mesentery, adrenal gland, primary bronchus, and retina was hyper-eosinophilic and amorphous, indicative of fibrinoid necrosis (Fig. 2). Mild lymphocytic infiltrates were seen within the rumen and kidney. Lymphocytes admixed with neutrophils and fewer plasma cells, necrotic debris, and fibrin extended partially or transmurally through the ulcerated areas of the small intestine and primary bronchus. Small vessels at the margins of the ulcers were thrombosed. Corneal lesions included ulceration, neutrophilic and lymphocytic inflammation, neovascularization, and edema, and lymphocytes and neutrophils were adhered to and infiltrated the corneal endothelium. Fibrin admixed with occasional lymphocytes and neutrophils were observed in the anterior and posterior chambers of both eyes.

Ancillary tests including bacteriology, immunohistochemistry, and polymerase chain reaction (PCR) were done by the Prairie Diagnostic Services (PDS), Western College of Veterinary Medicine. The urinary bladder and small intestine were submitted for routine aerobic and anaerobic bacterial culture. Samples for aerobic culture were inoculated onto tryptic soy

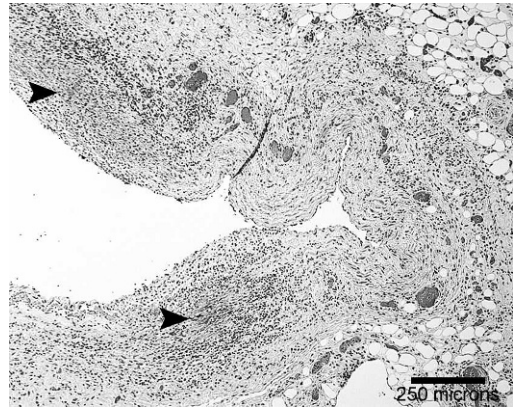


FIGURE 2. Lymphocytic vasculitis and fibrinoid necrosis (arrowheads) of a mesenteric artery of a male moose (*Alces alces*) from Saskatchewan, Canada. Hematoxylin and eosin.

agar (TSA) plates containing sheep blood and MacConkey agar plates. Plates were inspected at 24 and 48 hr for bacterial growth. Anaerobic culture was performed in an anaerobic container using TSA-based plates with sheep blood, and plates were inspected once at 48 hr. No significant bacteria were cultured.

Immunohistochemical examination of the small intestine for bovine virus diarrhea virus (BVDV) was carried out by PDS, Saskatoon, Saskatchewan, following methods outlined in Haines et al. (1992). Monoclonal antibody 15CS (Syracuse Bioanalytical, Inc., East Syracuse, New York, USA) was used at dilutions of 1:1,000 and 1:2,000, and a positive control was included in the test. Bovine virus diarrhea virus antigen was not detected.

To confirm the diagnosis of MCF, sections of frozen urinary bladder and small intestine were submitted for PCR and DNA sequencing. For DNA extraction, tissue (50 mg) was homogenized in 500 μ l of lysis buffer (100 mM NaCl, 500 mM Tris pH 8.0, 10% [w/v] sodium dodecyl sulfate) with proteinase K (0.2 mg/ml final concentration) and then mixed by vortexing. Tissue homogenates were incubated for 2 hr at 65 C and then extracted twice with phenol:chloroform (1:1). Nucleic acids were precipitated with

2.5 volumes of cold ethanol, and pellets were washed twice in 80% ethanol before resuspension in 50 µl of sterile water. Initial screening for the presence of OHV-2 was done using a seminested diagnostic PCR protocol (Baxter et al., 1993) as modified by Li et al. (1995) in which a 238 base pair (bp) region of a gene encoding a tegument protein of OHV-2 is amplified. Five microliters and 0.5 µl of extracted nucleic acids were used in the first and second reactions, respectively. Nucleic acids extracted from tissues from a bison (*Bison bison*) with sheep-associated malignant catarrhal fever were used as a positive control, and sterile water replaced nucleic acids as a negative control for all reactions. Polymerase chain reaction products were visualized on 1.25% agarose gel stained with ethidium bromide. Ovine herpes virus-2 DNA was detected in the tissue.

To verify the PCR result, a consensus primer PCR method based on VanDevanter et al. (1996) was used to amplify a segment of the herpesviral DNA polymerase gene for sequencing. Five microliters of extracted DNA were used as template in a PCR reaction containing 5 U Taq DNA polymerase, 2 mM MgCl₂, 50 mM KCl, 10 mM Tris/HCl pH 8.3, 250 µM each of the dNTPs, and 20 pmol each of primers ILK (5'-TCC TGG ACA AGC AGC ARN YSG CNM TNA A-3') and KG1 (5'-GTC TTG CTC ACC AGN TCN ACN CCY TT-3'). Reactions were incubated at 94 C for 5 min followed by 45 cycles of 30 sec at 94 C, 60 sec at 46 C, 60 sec at 72 C, and a final extension of 10 min at 72 C. Polymerase chain reaction products were visualized on a 1.25% agarose gel stained with ethidium bromide.

Sequencing of DNA was performed at the National Research Council Plant Biotechnology Institute, Saskatoon, Canada. Raw data were assembled and edited using programs pregap4 and gap4 of the Staden Package (Staden et al., 2000). Finished sequence data were compared

to the NCBI Genbank nucleotide database using BLASTn (Altschul et al., 1990).

Sequencing of PCR product produced with primers ILK and KG1 resulted in 414 nucleotides of high-quality sequence data (deposited in Genbank, accession number EU078708). This sequence shares 99% nucleotide sequence identity with the OHV-2 strain BJ1035 (AY839756), for which the entire genome sequence has been determined. The sequence is only 83% identical to the white-tailed deer MCF virus DNA polymerase gene (AF387516), 78% identical to caprine herpesvirus-2 (AF283477), and 74% identical to alcelaphine herpesvirus-1 (AF005370).

Records of 288 moose submitted to the CCWHC from 1983 to 2006 were examined retrospectively. Six moose had lymphocytic vasculitis or perivasculitis, or multisystemic lymphocytic infiltrates. Paraffin-embedded, formalin-fixed tissues containing these lesions were submitted for PCR analysis to investigate the presence of OHV-2 DNA. For DNA extraction, five 20-µm sections from the sample block were placed in 1 ml of xylene and centrifuged at 15,000 × G for 5 min. The supernatant was removed, and the xylene treatment was repeated until the paraffin was completely removed. Tissue was washed twice in 80% ethanol and dried before resuspension in 500 µl of lysis buffer. The remainder of the extraction process was as described for fresh tissue samples. Initial screening for OHV-2 was carried out as previously described.

Ovine herpes virus-2 DNA was detected in the brainstem of a single animal. This adult, female moose was collected on 29 November 2003 near Kinley, Saskatchewan (52°2'N, 107°22'W). At necropsy, this moose was thin and had hair loss over the rump and shoulders. Autolysis precluded microscopic examination of most organs, but there were multifocal perivascular accumulations of lymphocytes and few plasma cells in Virchow-Robin space and the meninges of the brain (Fig. 3). Endothelium of these vessels often was

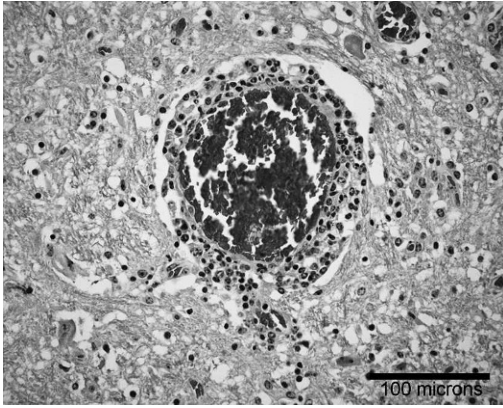


FIGURE 3. Lymphocytic vasculitis in the brain of a female moose (*Alces alces*) from Saskatchewan, Canada. Hematoxylin and eosin.

swollen, there was occasional gliosis, and mild, scattered perivascular hemorrhage was observed around severely affected vessels. There was moderate orthokeratotic hyperkeratosis of affected skin but no sign of inflammation. Attempts to amplify a portion of the herpesviral polymerase gene for sequencing from the brainstem were unsuccessful.

To our knowledge, these represent the first two confirmed reports of MCF in free-ranging moose in North America. Polymerase chain reaction analysis and DNA sequencing verified that they had the sheep-associated form of MCF. The DNA from the herpesviral polymerase gene could not be amplified and sequenced from the second moose, which is not surprising, given that formalin-fixed, paraffin-embedded tissues were used. The PCR product for the polymerase gene is almost twice as long as the product generated from primers for the OHV-2 tegument gene. Greer et al. (1991) demonstrated that the larger the PCR product, the more sensitive it is to destruction by formalin fixation. Alternately, differing sensitivities of the two PCR assays may have been responsible.

Gross and microscopic findings differed between the two moose, but lymphocytic vasculitis and perivascularitis, the hallmark of

MCF, were present in both cases. Disease in moose likely is similar to disease in cattle, where various clinical manifestations of MCF have been described (Barker et al., 1993). Vikoren et al. (2006) found different presentations of disease in free-ranging moose with MCF in Norway. Brain inflammation was not a feature of MCF in the first moose presented here. This differs from findings by Vikoren et al. (2006). In Norway, brain inflammation was detected in all affected moose for which brain was available. In the Saskatchewan moose, mucosal surfaces primarily were targeted, although the eyes were also affected. Although skin lesions are common in cattle with MCF (Barker et al., 1993), the skin lesions described in the second moose were not typical for MCF and likely represented another condition.

With new diagnostic tools, MCF may be more readily recognized in North American cervids. Different cervid species have differing susceptibility to clinical infection (Heuschele and Reid, 2001). Moose may be particularly susceptible to disease. In surveys for antibodies against MCF virus, moose had the lowest reported prevalence for those cervids examined, ranging from 0.4% to 1% (Zarnke et al., 2002; Vikoren et al., 2006). This might suggest that exposure in moose tends to result in fatal disease, or that moose are not exposed to the virus as often as other cervids (Zarnke et al., 2002).

Malignant catarrhal fever is a sporadic disease and requires close contact with the endemic host species. Clinically affected animals cannot pass the virus to conspecifics, presumably because they do not shed cell-free virus (Heuschele and Reid, 2001). These cases of sheep-associated MCF therefore indicate contact between moose and sheep. Both moose were found in cultivated agricultural areas of southern Saskatchewan. The number of moose in the south of the province has been steadily increasing over the past two decades (R. Beaulieu, Saskatchewan Ministry of Environment, pers. comm.). Saskatchewan is

the fourth largest sheep-producing province in Canada (Statistics Canada, 2007), and agriculture is confined to the southern half of the province. As moose continue to become more numerous in these areas, the prevalence of MCF and other agriculture-related diseases in moose may increase.

The authors thank the conservation officers from Saskatchewan Ministry of Environment for submitting the moose, A. Tumber of Prairie Diagnostic Services for conducting the PCR analysis, and G. Wobeser for his helpful comments on the manuscript.

LITERATURE CITED

- ALTSCHUL, S. F., W. GISH, W. MILLER, E. W. MYERS, AND D. J. LIPMAN. 1990. Basic local alignment search tool. *Journal of Molecular Biology* 215: 403–410.
- BARKER, I. K., A. A. VAN DREUMEL, AND N. PALMER. 1993. The alimentary system. *In Pathology of Domestic Animals*, Volume 2, K. V. F. Jubb, P. C. Kennedy and N. Palmer (eds.). Academic Press, Inc., Toronto, Ontario, Canada, pp. 1–317.
- BAXTER, S. I., I. POW, A. BRIDGEN, AND H. W. REID. 1993. PCR detection of the sheep-associated agent of malignant catarrhal fever. *Archives of Virology* 132: 145–159.
- GREER, C. E., S. L. PETERSON, N. B. KIVIAT, AND M. M. MANOS. 1991. PCR amplification from paraffin-embedded tissues. Effects of fixative and fixation time. *American Journal of Clinical Pathology* 95: 117–124.
- HAINES, D. M., E. G. CLARK, AND E. J. DUBOVI. 1992. Monoclonal antibody-based immunohistochemical detection of bovine viral diarrhea virus in formalin-fixed, paraffin-embedded tissues. *Veterinary Pathology* 29: 27–32.
- HEUSCHELE, W. P., AND H. W. REID. 2001. Malignant catarrhal fever. *In Infectious diseases of wild mammals*, E. S. Williams and I. K. Barker (eds.). Iowa State University Press, Ames, Iowa, pp. 157–164.
- LI, H., D. T. SHEN, D. O'TOOLE, D. P. KNOWLES, J. R. GORHAM, AND T. B. CRAWFORD. 1995. Investigation of sheep-associated malignant catarrhal fever virus infection in ruminants by PCR and competitive inhibition enzyme-linked immunosorbent assay. *Journal of Clinical Microbiology* 33: 2048–2053.
- , K. GAILBREATH, E. J. FLACH, N. S. TAUS, J. COOLEY, J. KELLER, G. C. RUSSELL, D. P. KNOWLES, D. M. HAIG, J. L. OAKS, D. L. TRAU, AND T. B. CRAWFORD. 2005. A novel subgroup of rhadinoviruses in ruminants. *Journal of General Virology* 86: 3021–3026.
- LUNA, L. G. (ed.). 1968. *Manual of histologic staining methods of the Armed Forces Institute of Pathology*, 3rd edition. The Blakiston Division, McGraw-Hill Inc., Toronto, Ontario, Canada. 258 pp.
- STADEN, R., K. F. BEAL, AND J. K. BONFIELD. 2000. The Staden package, 1998. *Methods in Molecular Biology* 132: 115–130.
- STATISTICS CANADA. 2007. Sheep statistics. Catalogue no. 23-011-XIE. Government of Canada, Ottawa, Ontario, Canada. 27 pp.
- VANDEVANter, D. R., P. WARRENER, L. BENNETT, E. R. SCHULTZ, S. COULTER, R. L. GARBER, AND T. M. ROSE. 1996. Detection and analysis of diverse herpesviral species by consensus primer PCR. *Journal of Clinical Microbiology* 34: 1666–1671.
- VIKOREN, T., H. LI, A. LILLEHAUG, C. M. JONASSEN, I. BOCKERMAN, AND K. HANDELAND. 2006. Malignant catarrhal fever in free-ranging cervids associated with ovhv-2 and cphv-2 DNA. *Journal of Wildlife Diseases* 42: 797–807.
- WARSAME, I. Y., AND M. STEEN. 1989. Malignant catarrhal fever in wild Swedish moose (*Alces alces* L.). *Rangifer* 9: 51–57.
- WILLIAMS, E. S., E. T. THORNE, AND H. A. DAWSON. 1984. Malignant catarrhal fever in a Shira's moose (*Alces alces shirasi* Nelson). *Journal of Wildlife Diseases* 20: 230–232.
- ZARNKE, R. L., H. LI, AND T. B. CRAWFORD. 2002. Serum antibody prevalence of malignant catarrhal fever viruses in seven wildlife species from Alaska. *Journal of Wildlife Diseases* 38: 500–504.

Received for publication 20 December 2007.