

INVESTIGATION OF SHELL DISEASE IN MAP TURTLES (GRAPTEMYS SPP.)

Authors: Hernandez-Divers, Stephen J., Hensel, Patrick, Gladden, Juliet, Hernandez-Divers, Sonia M., Buhlmann, Kurt A., et al.

Source: Journal of Wildlife Diseases, 45(3) : 637-652

Published By: Wildlife Disease Association

URL: <https://doi.org/10.7589/0090-3558-45.3.637>

BioOne Complete (complete.BioOne.org) is a full-text database of 200 subscribed and open-access titles in the biological, ecological, and environmental sciences published by nonprofit societies, associations, museums, institutions, and presses.

Your use of this PDF, the BioOne Complete website, and all posted and associated content indicates your acceptance of BioOne's Terms of Use, available at www.bioone.org/terms-of-use.

Usage of BioOne Complete content is strictly limited to personal, educational, and non - commercial use. Commercial inquiries or rights and permissions requests should be directed to the individual publisher as copyright holder.

BioOne sees sustainable scholarly publishing as an inherently collaborative enterprise connecting authors, nonprofit publishers, academic institutions, research libraries, and research funders in the common goal of maximizing access to critical research.

INVESTIGATION OF SHELL DISEASE IN MAP TURTLES (*GRAPTEMYS* SPP.)

Stephen J. Hernandez-Divers,^{1,7} Patrick Hensel,¹ Juliet Gladden,¹ Sonia M. Hernandez-Divers,¹ Kurt A. Buhlmann,² Chris Hagen,² Susan Sanchez,^{3,4} Kenneth S. Latimer,^{5,6} Mary Ard,⁵ and Alvin C. Camus⁵

¹ Department of Small Animal Medicine and Surgery, College of Veterinary Medicine, University of Georgia, Athens, Georgia 30602-7390, USA

² Savannah River Ecology Laboratory, Odum School of Ecology, University of Georgia, Aiken, South Carolina 29802, USA

³ Department of Infectious Diseases, College of Veterinary Medicine, University of Georgia, Athens, Georgia 30602-7390, USA

⁴ Athens Diagnostic Laboratory, College of Veterinary Medicine, University of Georgia, Athens, Georgia 30602-7390, USA

⁵ Department of Pathology, College of Veterinary Medicine, University of Georgia, Athens, Georgia 30602-7390, USA

⁶ Current address: Covance Laboratories Inc, 9200 Leesburg Pike, Vienna, Virginia 22182, USA

⁷ Corresponding author (email: shdivers@uga.edu)

ABSTRACT: Nineteen map turtles (*Graptemys* spp.) maintained under natural conditions were investigated because of chronic shell abnormalities. Animals were evaluated using a novel shell scoring system that divided the 54 scutes into six regions, with each region scored for lesion extent and severity, and summated to produce a total shell disease score (TSDS). Complete blood counts and various biochemistry analytes (total protein, albumin, globulin, urea, uric acid, 25-hydroxycholecalciferol, phosphorus, and ionized and total calcium) were measured. Under ketamine-medetomidine-morphine anesthesia, cytology tape strips and full thickness shell biopsies were collected aseptically for microbiologic, histologic (including scoring of biopsy quality), and ultrastructural evaluations. The TSDSs were low and ranged from 4 to 22 (median=9) out of a possible score of 54. There were no correlations between TSDS and any hematologic or biochemistry parameter. The histologic quality of shell biopsies was good, and normal shell structure, by both light and electron microscopy, is described. Small clefts and pitting lesions were noted in 8/19 sections. There was no evidence of erosion, ulceration, inflammation, or infectious agents, but algae and diatoms were observed. Six biopsies yielded aerobic isolates (*Chryseobacterium indologenes*, *Aeromonas hydrophila*, *Ralstonia pickettii*, and *Morganella morganii*), whereas 11 shell samples grew various clostridial anaerobes. No fungal organisms were cultured. Although the etiology of the lesions described remains unknown, the use of a scoring system in conjunction with full thickness biopsies is suggested to help standardize investigations into chelonian shell disease in the future.

Key words: Biopsy, histopathology, *Graptemys*, map turtle, microbiology, shell disease.

INTRODUCTION

Turtles are reptiles of the Order Testudines, and nearly half of the extant 300 species are considered threatened or endangered (IUCN/SSC, 2007). *Graptemys* is a genus composed of 12–13 species commonly known as map turtles or sawbacks. They are aquatic, freshwater turtles that are found in riverine ecosystems from southeastern United States to southeastern Canada.

The testudinian shell, composed of a dorsal carapace and ventral plastron joined together by two lateral bridges, is arranged into distinct bony and kerati-

nized epidermal layers (Bojanus, 1819; McArthur et al., 2004; Barten, 2006; Boyer and Boyer, 2006). About 60 bones make up the carapace and plastron, and are derived from ribs, vertebrae, clavicles, interclavicles, gastralia (abdominal ribs), and dermal skin elements. The bones of the shell are covered by a staggered layer of keratinized superficial epidermal lamellae (scutes), such that the connections between neighboring bones and scutes do not overlap. Anatomic nomenclature has been developed for naming the scutes of both plastron and carapace (McArthur et al., 2004; Boyer and Boyer, 2006).

Shell disease has been reported from a

variety of captive and free-ranging turtles; unfortunately, lack of standardization has hindered comparisons between published reports. Shell disease has been most frequently reported due to trauma (fractures and burns), malnutrition (especially inadequacies relating to calcium, vitamin D₃, and environmental lighting), and a variety of bacterial and fungal infections (Keymer 1978a, b; Frye, 1991; Homer et al., 1998; LaFortune et al., 2005a, b; Barten, 2006; Mader, 2006; Adkesson et al., 2007). Most of these infections appear attributable to gram-negative commensals belonging to the Enterobacteriaceae (including *Escherichia*, *Klebsiella*, *Enterobacter*, *Serratia*, *Citrobacter*, *Proteus*, and *Pseudomonas* spp.) or environmental organisms (including *Paecilomyces lilacinus*). Poor management, particularly inappropriate temperature, humidity, lighting, and nutrition, is considered a predisposing factor for shell disease in many captive animals (Boyer 1998, Barten 2006, Mader 2006). In free-ranging species, shell necrosis and dyskeratosis have been specifically reported. Shell necrosis associated with high mortality rates has been observed in desert tortoises (*Gopherus agassizii*) from the Colorado and Mojave deserts in California, USA, since 1979. Lesions were present in both sexes and all size/age classes of tortoises, and were most severe on the plastron. Affected shells appeared gray-white and sometimes orange and had a roughened flaky appearance. The lesion commenced at seams between scutes and spread toward the middle of each scute in an irregular pattern as the keratin layer was disrupted by multiple crevices and fissures. In severe cases, dermal bone showed osteoclastic resorption, remodeling, and osteopenia. Histologic evaluation of shell biopsies failed to reveal inflammation or etiologic agents. The lesions were considered dyskeratotic in nature, suggestive of either a deficiency disease or toxicosis (Jacobson et al., 1994; Homer et al., 1998). Shell necrosis of free-ranging freshwater turtles

(*Pseudemys* and *Trachemys* spp.) from Lake Blackshear, Georgia, USA, has been reported with acute segmental necrosis of the epidermis, ulceration and necrosis of the underlying dermis and dermal bone, and extensive bone remodeling (Lovich et al., 1996; Garner et al., 1997). Despite visceral inflammatory lesions, and the isolation of various blood-borne bacteria (including *Bacteroides*, *Morganella*, and *Aeromonas* spp.) the cause of the shell lesions was not identified. Necrotic shell lesions have also been reported from Texas tortoises (*Gopherus berlandieri*) from southern Texas, USA, in which epidermal lamellae demonstrated various stages of necrosis, ranging from localized whitish blemishes to complete degradation of the external portion of the scute (Rose et al., 2001). *Fusarium semitectum* was consistently isolated from infected scutes, but was not isolated from asymptomatic tortoises. Experimental studies demonstrated the ability of the fungus to penetrate healthy keratin scutes of uninfected Texas tortoises and box turtles (*Terrapene ornata*). To the authors' knowledge this represents the only successful transmission study involving shell disease in any chelonian.

The present study describes the gross, clinicopathologic, histologic, electron microscopic, cytologic, and microbiologic investigations of suspected shell disease in 19 map turtles. The objectives were to develop the concept of regional and total shell disease scores in an effort to promote consistency for the gross description of shell lesions among veterinarians and wildlife biologists, and to evaluate a simple technique for collecting full-thickness shell biopsies.

MATERIALS AND METHODS

Seven Mississippi map turtles (*Graptemys pseudogeographica kohnii*), four northern map turtles (*Graptemys geographica*), five Ouachita map turtles (*Graptemys ouachitensis*), and three black-knobbed map turtles (*Graptemys nigrinoda*) were presented to the College

of Veterinary Medicine, University of Georgia, for evaluation of shell disease during December 2006. The animals originated from a government confiscation and were deposited with the Savannah River Ecology Laboratory in August 2006 for housing and care. The turtles were maintained year-round in large outdoor artificial, plastic-lined ponds, measuring 30×15 m and ranging in depth from 0.6 m to 2.4 m, and were exposed to natural temperatures and photoperiods. Supplemental food was provided in the form of live crayfish that were stocked and coexisted in the pond, as well as biweekly feedings of a pelleted ration (Mazuri freshwater turtle diet, Mazuri, Richmond, Indiana, USA). All methods and procedures were critically evaluated and approved by the University of Georgia's Institutional Animal Care and Use Committee (AUP A2004-10140-C2).

On admission to the Veterinary Teaching Hospital, all animals were kept in species-specific groups in large plastic tubs, fasted, and maintained at 27 C to 29 C for 24 hr before evaluation. All animals were washed with tap water, individually identified by a unique alphanumeric code on the carapace, and physically examined to determine gender and overt health. Total body weights and straight carapace lengths were recorded and used to calculate weight:length ratios as an aid to assessing body condition. High-resolution digital photographs were taken of the plastron and carapace.

To facilitate objective assessment the shell was separated into three dorsal and three ventral regions of approximately equal area (Fig. 1). For each region the extent of visible lesions was scored from 0 to 3 (0=absent; 1=minor, occupying <10% of the region; 2=moderate, occupying 10–50% of the region; 3=severe, occupying >50% of the region), and the severity of the lesions were also scored from 0 to 3 (0=no lesion present; 1=superficial, involving keratin scute only; 2=intermediate, involving keratin and partial bone; 3=deep, involving keratin and full thickness of bone). Regional shell disease scores were calculated by extent×severity, and an animal's total shell disease score (TSDS) was calculated from the addition of all six regional scores.

Each animal was anesthetized using a combination of 10 mg/kg ketamine (Ketaject, 100 mg/ml, Phoenix Pharmaceutical Inc, St. Joseph, Missouri, USA), 0.1 mg/kg medetomidine (Domitor, 1 mg/ml, Pfizer Animal Health, New York, New York, USA), and 1.5 mg/kg morphine (morphine sulfate, 15 mg/ml, Baxter Healthcare Corp., Deerfield, Illinois, USA), all delivered by a single

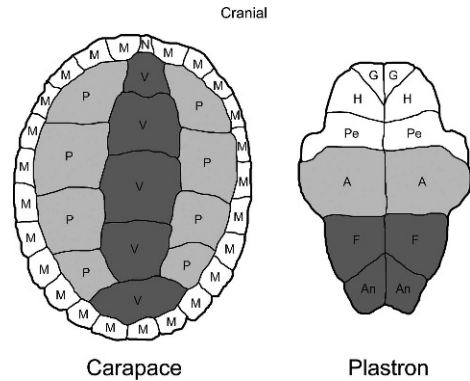


FIGURE 1. Division of plastron and carapace into six regions for scoring extent and severity of shell lesions: (1) marginal/nuchal region composed of a single nuchal (N) and 24 marginal (M) scutes; (2) pleural region composed of 8 pleural (P) scutes; (3) vertebral region composed of 5 vertebral (V) scutes; (4) gular/humeral/pectoral region composed of two gular (G), two humeral (H), and two pectoral (Pe) scutes (5) abdominal region composed of two abdominal (A) scutes; and (6) femoral/anal region composed of two femoral (F) and two anal (An) scutes.

deep intramuscular injection. As part of a separate study to evaluate this solely injectable anesthetic regime for field use, animals were not intubated, ventilated, or maintained on oxygen or volatile agents. Anesthesia and surgical areas were maintained at 24 C. Anesthetic depth was monitored by evaluating reflexes, heart rate, and spontaneous respiration.

Blood was collected from the postoccipital sinus (immediately posterior to the skull and adjacent to the supraoccipital region), with 0.4 ml placed into an ethylenediaminetetraacetic acid (EDTA) tube (Microtainer Tubes, Becton Dickinson, Franklin Lakes, New Jersey, USA), 1.2 ml placed into two heparin tubes (Microtainer Tubes, Becton Dickinson), and a fresh blood smear made from the last drop of blood in the syringe. Total blood collection did not exceed 0.5% body weight, and samples were analyzed immediately for hematologic and plasma biochemistry determinations. Hematologic evaluation included packed cell volume (PCV), total white blood cell count (WBC), and differential leukocyte counts using standard techniques (Martinez-Jimenez et al., 2007). Heparin blood tubes were centrifuged at 5,000 × G for 5 min to yield plasma for determination of albumin, total protein, urea, uric acid, phosphorus, and total calcium concentrations using a BM

Hitachi 912 chemistry analyzer (Hitachi Nissei Sangyo America Ltd., Indianapolis, Indiana, USA). Values for globulin were calculated from measured total protein and albumin. Ionized calcium concentration was determined using the NOVA CCX (Stat Profile Critical Care Xpress, Nova Biomedical Corp, Waltham, Massachusetts, USA). Assays for 25-hydroxycholecalciferol were determined by radioimmunoassay (Michigan State University, College of Veterinary Medicine, East Lansing, Michigan, USA).

Strips of a transparent acetate tape, 4 cm in length, were used to take impression smears from shell lesions. The samples were stained with a modified Wright's stain (Protocol, Fisher Scientific Company LLC, Middletown, Virginia, USA) and then applied directly onto a glass slide, and examined using light microscopy (Mendelsohn et al., 2006).

Biopsy sites were selected from the edge of lesions. Following gentle aseptic preparation of the shell using dilute chlorhexidine gluconate and surgical sponges (BD E-Z scrub, Becton Dickinson), a Michele trephine (6-mm internal diameter, 8-mm outer diameter) was used to collect three full-thickness shell biopsies from each turtle (Fig. 2). Biopsies for microbiology were placed inside sterile plastic bags (58-ml [2-ounce] Whirl-Paq bags, Nasco Inc., Fort Atkinson, Wisconsin, USA) and submitted for bacterial and fungal cultures. Biopsies for routine histology were placed in 10% neutral buffered formalin; those for electron microscopy were submitted in 2% glutaraldehyde. Biopsy sites were flushed with 0.9% sterile saline before being sealed with methylmethacrylate (Surgical Simplex P Bone Cement, Stryker Corp., Mahwah, New Jersey, USA).

Each turtle was given 20 ml/kg intracoelomic crystalloid fluids (Normosol-R, Abbott Animal Health, Abbott Park, Illinois, USA) and 0.2 mg/kg meloxicam (Metacam, 5 mg/ml, Boehringer Ingelheim Vetmedica Inc., St. Joseph, Missouri, USA) intramuscularly (IM). Anesthetic reversal was achieved by administering 0.5 mg/kg atipamezole (Antisedan, 5 mg/ml, Pfizer Animal Health) IM and 0.02 mg/kg naloxone (Narcan, 0.4 mg/ml, Endo Pharmaceuticals Inc., Chadds Ford, Pennsylvania, USA) IM and repeated as necessary. Animals were permitted to recover in an incubator at 27 C to 29 C, and were returned to their normal outside areas at the Savannah River Ecology Laboratory 4 days later.

Biopsies for histology were decalcified for 10 days in a commercial solution of HCl and EDTA (Fixation Decalcifying Solution, Rich-

ard-Allan Scientific, Kalamazoo, Michigan, USA) prior to processing. Specimens were bisected and embedded on cut edge. Tissue samples were processed routinely by dehydration in a graded series of ethanol solutions of increasing strength, followed by clearing in a series of xylenes, embedding in paraffin, and sectioning at 4 μ m. Prepared slides were stained with hematoxylin and eosin (H&E). Selected sections were stained by Giemsa, Lillie-Twort (gram-stain), Gomori's methenamine silver (GMS; fungus), and modified acid-fast methods (Luna, 1968). The diagnostic quality of histologic sections were subjectively scored from 1 to 4 (1=poor, 2=fair, 3=good, 4=excellent). A score of excellent was given to sections in which the keratin layer extended to both margins of the section and there was no disruption of the epidermis or fragmentation of bone. Good sections had >75% of their keratin layer intact, with minimal epidermal damage and fragmentation of bone at their tissue margins. A score of fair was given to sections with 50–75% of their keratin intact and mild to moderate epidermal damage and fragmentation at sections margins. Poor sections had <50% of their keratin layer remaining and severe damage to the underlying epidermal and bony layers.

Prior to electron microscopy, shell biopsies were fixed in 2% (para)formaldehyde, 2% glutaraldehyde, and 0.2% picric acid in 0.1 M cacodylate-HCl buffer (pH 7.3). Smaller specimens were prepared using an Isomet 11-1180 low-speed saw (Buehler Ltd., Lake Bluff, Illinois, USA) and allowed to fix further. Samples were prepared in accordance with previously published and accepted methodologies, and examined using a JEM-1210 transmission electron microscope (JEOL USA, Inc., Peabody, Massachusetts, USA) at 120 KeV (Reynolds, 1963; Spurr, 1969; Bozola, 1999).

Biopsies were divided into two samples for bacterial and fungal cultures. Tissue samples were placed in 50-ml conical tubes containing 25 ml thioglycollate broth, and incubated overnight at 30 C. Broth was then subcultured onto blood agar plates, and incubated at 30 C in both aerobic and anaerobic environments. Bacterial isolate identification was performed using BBL Crystal Identification systems (Becton Dickinson). Following thioglycollate enrichment, fungal samples were subcultured onto Sabouraud dextrose agar and Mycosel agar (Becton Dickinson), and incubated at room temperature for 30 days.

All analyses were performed using SAS version 9.1 (SAS Institute Inc., Cary, North Carolina, USA). Analysis of variance (ANOVA)

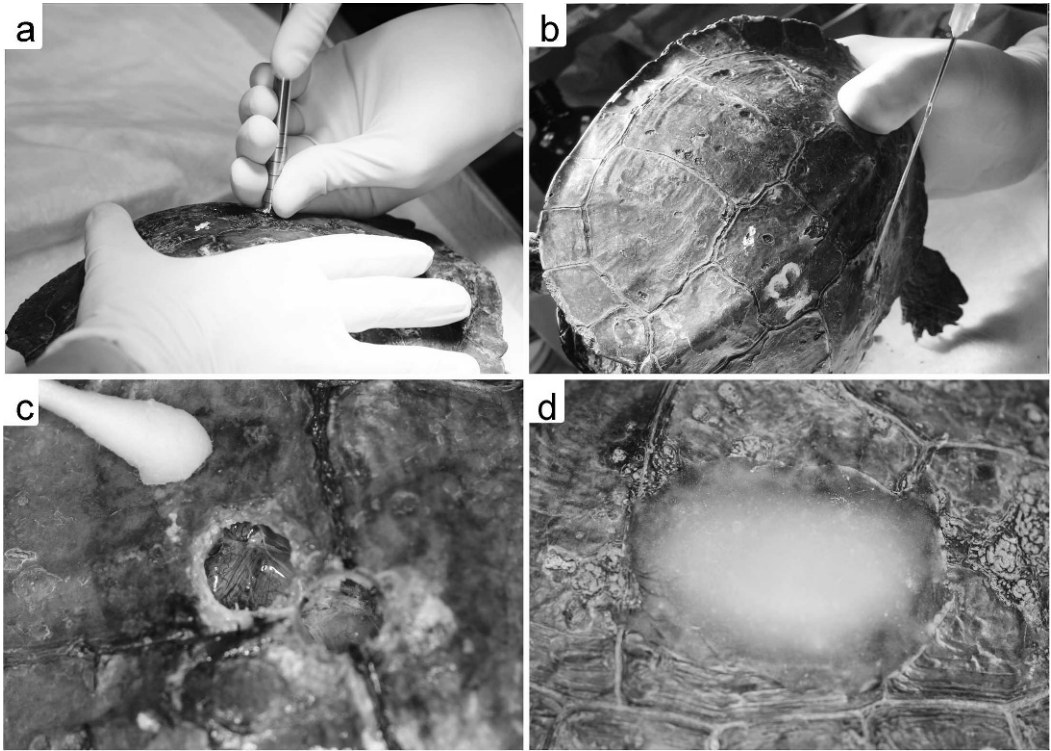


FIGURE 2. Shell biopsy technique in a map turtle. (a) A Michele trephine is used to collect a full thickness shell biopsy from the carapace. (b) The biopsy site is flushed with sterile saline to remove any debris. (c) Two 8-mm shell biopsy sites revealing the underlying pleuroperitoneal membrane. (d) The biopsy sites are covered and sealed using methylmethacrylate.

was used to make species comparisons for severity and extent for each region separately, and TSDS. A repeated measures model that recognized multiple observations as belonging to the same turtle was used to test for differences in extent and severity scores. First a model was run that included fixed factors of species and shell region and a species/region interaction effect and a random factor of turtle. Subsequent analyses were run separately for each species for extent and severity. Subsequent analysis included 1) a model with a fixed factor of region and a random factor of turtle to compare between the six shell regions and 2) a model with fixed factors of section (carapace or plastron) and region nested within section and a random factor of turtle to compare the two sections. An unstructured covariance structure was used in all repeated measures models. All hypothesis tests were two-sided and the significance level was $\alpha=0.05$. Multiple comparisons were made using Tukey's test. Simple linear correlation analysis was performed between TSDS and clinical pathology values for all animals pooled

and for each species separately. The repeated measures analysis was performed using PROC MIXED, ANOVA using PROC GLM, and correlation analysis using PROC CORR in SAS.

RESULTS

Morphometric measurements obtained from 19 turtles were summarized (Table 1). With the exception of a single male Mississippi map turtle, all turtles were female. ANOVA indicated significant differences in weight and length between species. Sixteen turtles were alert and responsive, but two Mississippi map turtles and a single Ouachita map turtle were considered lethargic. The two Mississippi map turtles had low weight:length ratios (2.22, 4.00) compared to the species mean (4.38) indicating reduced body condition; however, both recovered from anesthesia

TABLE 1. Weight, length and weight:length ratios obtained from 19 map turtles.

| | <i>Graptemys pseudogeographica kohnii</i> | | <i>Graptemys geographica</i> | <i>Graptemys ouachitensis</i> | <i>Graptemys nigrinoda</i> | <i>Graptemys</i> all species combined | |
|---------------------|---|------------------------|------------------------------|-------------------------------|----------------------------|---------------------------------------|-------------|
| | (Male, <i>n</i> = 1) | (Female, <i>n</i> = 6) | (Female, <i>n</i> = 4) | (Female, <i>n</i> = 5) | (Female, <i>n</i> = 3) | (<i>n</i> = 19) | |
| Weight (g) | Range | 300 | 640–1,660 | 380–820 | 260–740 | 260–1760 | |
| | Mean ±SD | 300 | 873 ± 391 | 1,345 ± 602 | 588 ± 200 | 487 ± 241 | 806 ± 478 |
| Length (mm) | Range | 135 | 160–225 | 155–237 | 147–180 | 110–170 | 110–237 |
| | Mean ±SD | 135 | 179 ± 23 | 209 ± 38 | 162 ± 14 | 138 ± 30 | 172 ± 34 |
| Weight:length ratio | Range | 2.22 | 3.66–7.38 | 2.97–7.49 | 2.45–4.56 | 2.36–4.35 | 2.22–7.49 |
| | Mean ±SD | 2.22 | 4.74 ± 1.34 | 6.15 ± 2.13 | 3.56 ± 0.92 | 3.37 ± 1.00 | 4.38 ± 1.70 |

and surgery. The Ouachita map turtle also had a low weight:length ratio (2.99) compared to the species mean (3.56), and was subsequently found dead the morning after surgery. Gross and histologic examinations indicated schistosomiasis, although severe hepatic lipidosis was considered the likely cause of death.

The extent, severity, and TSDS from 19 turtles were summarized (Table 2). The gross nature of the shell disease was similar among all turtles, and characterized by pitting and erosions, variable in both surface area (extent) and depth (severity). Although there was no obvious odor or exudate, the deeper lesions exhibited crumbling and flaking from their surface, especially at the periphery. Affected bone was significantly softer and easier to biopsy compared to normal healthy shell. There were no significant differences in TSDS between species (Fig. 3). There were significant differences in the severity of lesions between species in the femoral/anal region, and in the extent of lesions in the abdominal and femoral/anal regions. There was a significant effect of region on disease extent in Mississippi, northern, and Ouachita map turtles, but not black-knobbed map turtles. The extent of plastron disease was greater than for the carapace in Mississippi and black-knobbed map turtles, whereas carapacial disease was more extensive for northern map turtles. With all animals pooled, there was significantly greater severity of shell disease associated with the plastron than with the carapace.

The injectable anesthetic regime proved to be effective; however, seven turtles needed a second and two turtles needed a third dose of naloxone to fully recover. Biologic samples were successfully collected from every animal, and the methylmethacrylate repairs were easily applied and proved durable. Eighteen turtles recovered and were successfully returned to their outdoor enclosures. No deleterious effects were noted over the ensuing 16 mo. As of April 2008 (16 mo after the

TABLE 2. Minimum, maximum, and median scores for shell lesion extent, severity, and total shell disease scores in 19 map turtles.

| | <i>Graptemys pseudogeographica kohni</i> (n = 6) | | | <i>Graptemys geographica</i> (n = 4) | | | <i>Graptemys onachitensis</i> (n = 5) | | | <i>Graptemys nigrinoda</i> (n = 3) | | | <i>Graptemys</i> , all species combined (n = 19) | | |
|------------------------|--|---------------------|-----------------------|--------------------------------------|--------|--|---------------------------------------|--------|--|------------------------------------|--------|--|--|--------|--|
| | Minimum–maximum | Median ^a | | Minimum–maximum | Median | | Minimum–maximum | Median | | Minimum–maximum | Median | | Minimum–maximum | Median | |
| Marginal/nuchal | 0–2 | 1 | Extent ^b | 1–1 | 1 | | 0–1 | 1 | | 0–2 | 1 | | 0–2 | 1 | |
| | 1–1 | 1 | Severity ^c | 1–1 | 1 | | 1–1 | 1 | | 1–1 | 1 | | 1–1 | 1 | |
| | 0–3 | 1 | Extent | 1–2 | 1.5 | | 1–2 | 1 | | 0–2 | 1 | | 0–2 | 1 | |
| Pleural | 1–1 | 1 | Severity | 1–1 | 1 | | 1–1 | 1 | | 1–1 | 1 | | 1–1 | 1 | |
| | 1–2 | 1 | Extent | 1–2 | 1 | | 1–2 | 1 | | 0–3 | 1 | | 0–3 | 1 | |
| | 1–2 | 1 | Severity | 1–1 | 1 | | 1–1 | 1 | | 1–1 | 1 | | 1–2 | 1 | |
| Gular/humeral/pectoral | 1–2 | 2 | Extent | 0–1 | 1 | | 1–1 | 1 | | 1–2 | 1 | | 0–2 | 1 | |
| | 1–2 | 1 | Severity | 1–3 | 1 | | 1–1 | 1 | | 1–2 | 1 | | 1–3 | 1 | |
| | 2–3 | 2 | Extent | 1–2 | 1 | | 1–2 | 1 | | 1–2 | 2 | | 1–3 | 2 | |
| Abdominal | 2–2 | 2 | Severity | 1–3 | 1.5 | | 1–2 | 1 | | 1–2 | 1 | | 1–3 | 1 | |
| | 1–3 | 2 | Extent | 0–1 | 0 | | 1–2 | 1 | | 1–2 | 2 | | 0–3 | 1 | |
| | 1–2 | 1 | Severity | 0–3 | 0 | | 1–2 | 1 | | 1–1 | 1 | | 1–3 | 1 | |
| Femoral/Anal | 8–22 | 11 | | 4–17 | 6 | | 5–14 | 6 | | 5–14 | 8 | | 4–22 | 9 | |
| TSDS ^d | | | | | | | | | | | | | | | |

^a Median results reported because of nonnormal distribution.

^b Extent of lesions scored from 0 to 3 (0 = absent; 1 = minor, occupying <10% of the region; 2 = moderate, occupying 10–50% of the region; 3 = severe, occupying >50% of the region).

^c Severity of lesions scored from 0 to 3 (0 = absent; 1 = superficial, involving keratin only; 2 = intermediate, involving keratin and partial bone; 3 = deep, involving keratin and full thickness of bone).

^d TSDS = total shell disease score; sum of all regional (extent × severity) scores.

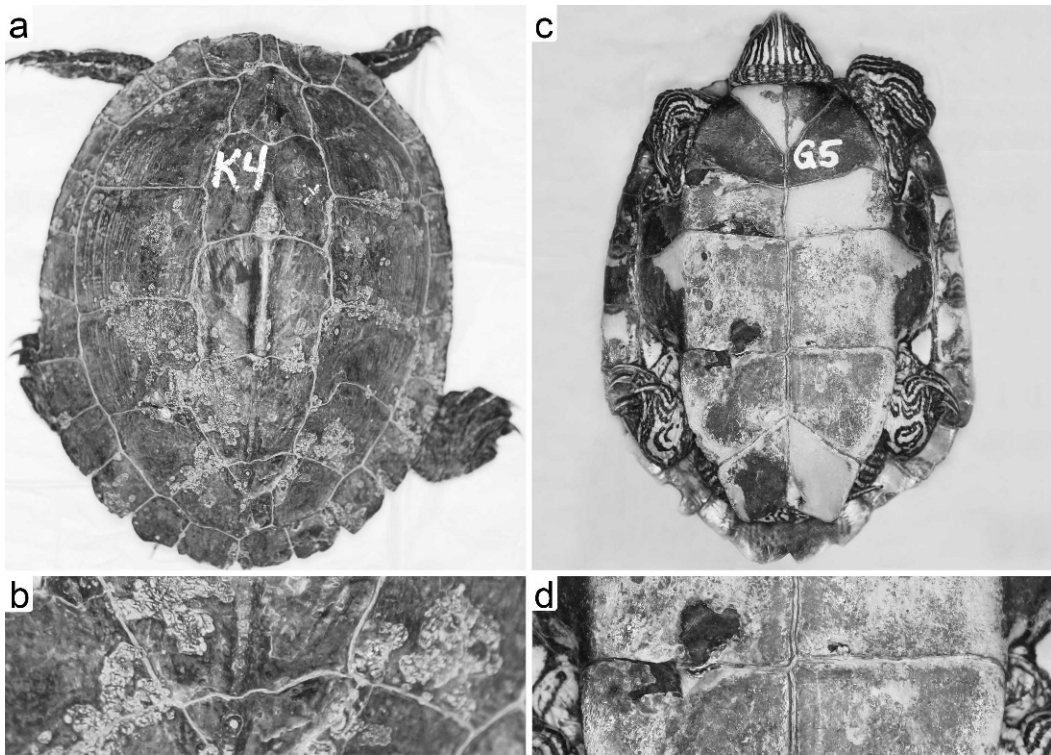


FIGURE 3. Gross appearance and scoring of shell lesions in two map turtles. (a) Carapace of a Mississippi map turtle that received lesion extent scores of 1 for nuchal/marginals, and 2 for pleural and vertebral regions. (b) Closer view of the same carapace indicating the superficial nature of the lesions that received a severity score of 1. (c) Plastron of a northern map turtle that received lesion extent scores of 1 for gular/humeral/pectoral, abdominal, and femoral/anal regions. (d) Closer view of the same plastron indicating the focal full-thickness lesions that received a severity score of 3.

biopsy procedures), visual reexaminations of the turtles in the outdoor ponds did not indicate any obvious morbidity or mortality. Several of the turtles that were recaptured had retained their methyl-methacrylate patches and where they had been lost, healing appeared complete.

Hematology and biochemistry results were obtained from 19 turtles, and summarized (Table 3). ANOVA indicated significant differences between species for total protein ($P=0.0014$), albumin ($P=0.0282$), and globulin ($P=0.0002$). There were no significant species-specific differences for the remaining parameters. There were no significant correlations between TSDS and any hematologic or biochemistry parameter for all animals pooled.

Cytologic evaluation of the shell lesions

from 19 turtles revealed similar findings. At low magnification ($100\times$) multiple conglomerates of packed cornified keratinocytes were found. The pigmentation of the cells varied from mild to marked and the color ranged from red to brown (Fig. 4a). High magnification ($1,000\times$, oil immersion) revealed large clusters of round-oval shaped, poorly stained organisms of pale green-yellowish color of 2–4 μm in diameter (Fig. 4b). These organisms were found in all turtles except one Mississippi map turtle and four Ouachita map turtles. In one Mississippi map turtle, large colonies of bacterial rods were found within two scales. Other consistent findings were occasional extracellular cocci and rods, yeast-like organisms, filamentous algae, and diatoms (Fig. 4c, d).

TABLE 3. Range, mean, and standard deviation for clinical pathology data obtained from 19 map turtles.

| | | <i>Graptemys pseudogeographica kohnii</i> (n=7) | <i>Graptemys geographica</i> (n=4) | <i>Graptemys ouachitensis</i> (n=5) | <i>Graptemys nigrinoda</i> (n=3) | <i>Graptemys</i> , all species combined (n=19) |
|--|----------|---|------------------------------------|-------------------------------------|----------------------------------|--|
| PCV ^a (%) | Range | 7.5–20.5 | 15.0–30.5 | 14.5–24.0 | 22.0–24.0 | 7.5–30.5 |
| | Mean ±SD | 15.9±4.2 | 19.9±7.1 | 18.6±4.1 | 22.7±1.2 | 18.5±4.9 |
| Total WBC ^a count (×10 ⁶ /l) | Range | 1.40–11.60 | 5.00–6.80 | 4.20–11.80 | 4.32–11.49 | 1.40–11.80 |
| | Mean ±SD | 6.90±3.66 | 5.90±0.84 | 7.76±3.31 | 8.55±3.76 | 7.18±3.06 |
| Heterophils (×10 ⁶ /l) | Range | 0.90–6.17 | 0.82–3.30 | 2.06–5.38 | 1.30–4.39 | 0.82–6.17 |
| | Mean ±SD | 3.52±1.93 | 2.06±1.20 | 4.01±1.71 | 3.29±1.73 | 3.31±1.72 |
| Basophils (×10 ⁶ /l) | Range | 0.06–2.55 | 0.00–1.43 | 0.08–3.54 | 1.33–1.89 | 0.00–3.54 |
| | Mean ±SD | 1.21±0.76 | 0.66±0.61 | 1.44±1.39 | 1.55±0.30 | 1.21±0.89 |
| Eosinophils (×10 ⁶ /l) | Range | 0.00–1.13 | 0.58–1.19 | 0.23–0.82 | 0.22–0.91 | 0.00–1.19 |
| | Mean ±SD | 0.44±0.44 | 0.92±0.26 | 0.57±0.21 | 0.66±0.39 | 0.61±0.37 |
| Lymphocytes (×10 ⁶ /l) | Range | 0.24–1.62 | 0.45–3.46 | 0.67–1.53 | 0.58–2.00 | 0.24–3.46 |
| | Mean ±SD | 0.83±0.05 | 1.95±1.59 | 1.16±0.39 | 1.49±0.79 | 1.26±0.91 |
| Monocytes ^b (×10 ⁶ /l) | Range | 0.22–1.13 | 0.20–0.48 | 0.21–1.18 | 0.18–1.21 | 0.18–1.21 |
| | Mean ±SD | 0.74±0.35 | 0.30±0.12 | 0.57±0.39 | 0.75±0.52 | 0.60±0.37 |
| Total protein ^c (g/dl) | Range | 1.7–2.9 | 3.1–5.9 | 2.1–3.4 | 1.9–3.9 | 1.7–5.9 |
| | Mean ±SD | 2.2±0.5 | 4.6±1.1 | 2.6±0.6 | 2.9±1.0 | 2.9±1.1 |
| Albumin ^c (g/dl) | Range | 0.5–0.8 | 0.8–1.3 | 0.6–1.1 | 0.6–1.0 | 0.5–1.3 |
| | Mean ±SD | 0.7±0.1 | 1.1±0.2 | 0.8±0.2 | 0.8±0.2 | 0.8±0.2 |
| Globulin ^c (g/dl) | Range | 1.2–2.1 | 2.3–4.6 | 1.5–2.3 | 1.3–2.9 | 1.2–4.6 |
| | Mean ±SD | 1.6±0.4 | 3.5±0.9 | 1.9±0.3 | 2.1±0.8 | 2.1±0.9 |
| Urea (mg/dl) | Range | 5.0–21.0 | 6.0–14.0 | 3.0–15.0 | 5.0–8.0 | 3.0–21.0 |
| | Mean ±SD | 10.0±5.4 | 10.5±3.7 | 7.6±4.4 | 6.7±1.5 | 8.9±4.4 |
| Uric acid (mg/dl) | Range | 0.6–2.1 | 0.6–0.9 | 0.6–1.10 | 0.6–1.8 | 0.6–4.3 |
| | Mean ±SD | 1.0±0.5 | 2.4±1.4 | 0.9±0.2 | 1.0±0.7 | 1.3±0.9 |
| Phosphorus (mg/dl) | Range | 1.8–3.3 | 2.1–3.1 | 2.0–3.2 | 2.1–3.6 | 1.8–3.6 |
| | Mean ±SD | 2.4±0.5 | 2.7±0.5 | 2.8±0.5 | 2.6±0.8 | 2.6±0.5 |
| Total calcium (mg/dl) | Range | 8.3–10.6 | 7.6–14.1 | 9.7–12.4 | 7.3–13.1 | 7.3–14.1 |
| | Mean ±SD | 9.3±0.8 | 11.8±2.9 | 11.1±1.0 | 10.9±3.2 | 10.5±2.0 |
| Ionized calcium (mmol/l) | Range | 1.06–1.16 | 1.06–1.11 | 0.98–1.19 | 0.99–1.08 | 0.98–1.19 |
| | Mean ±SD | 1.10±0.04 | 1.09±0.02 | 1.09±0.08 | 1.03±0.05 | 1.09±0.05 |
| 25-hydroxy-D ₃ (nmol/l) | Range | 9.0–24.0 | 14.0–27.0 | 13.0–22.0 | 15.0–24.0 | 9.0–27.0 |
| | Mean ±SD | 14.9±5.4 | 21.3±5.4 | 17.2±3.8 | 20.3±4.7 | 17.7±5.2 |

^a PCV = packed cell volume; WBC = white blood cells.^b Monocyte counts include azurophils.^c Statistical differences exist between one or more species.

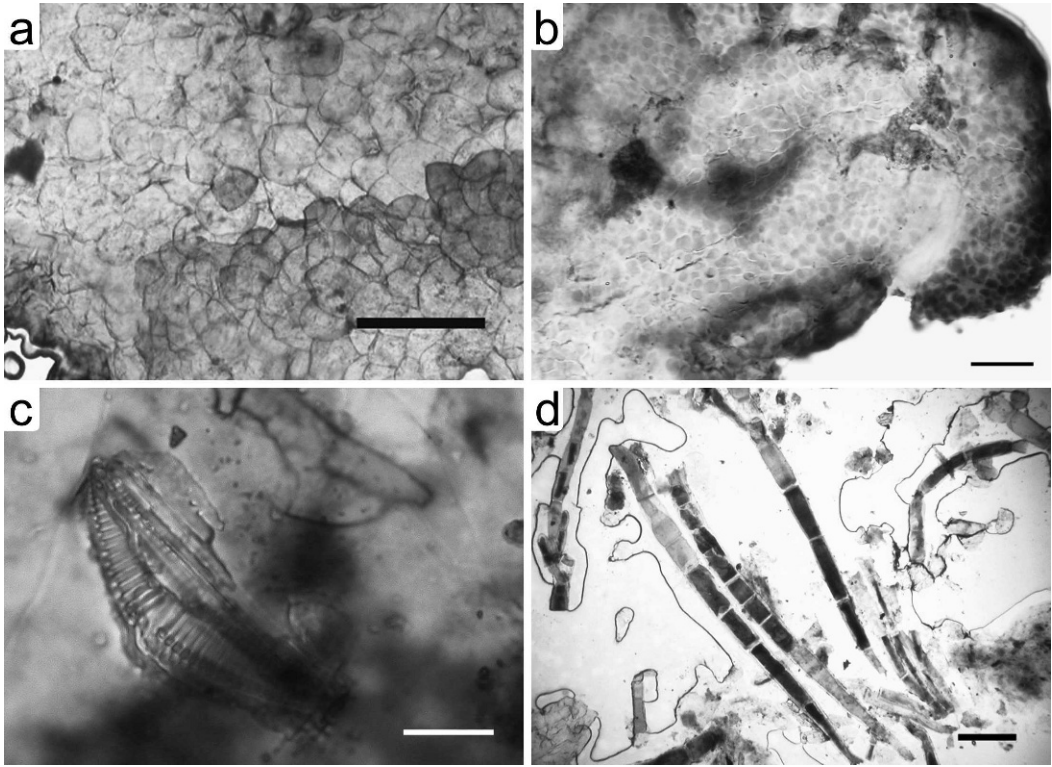


FIGURE 4. Shell cytology of map turtles. (a) Poorly stained cluster of densely packed cornified shell keratinocytes. 100X. Modified Wright's stain. Bar=100 µm. (b) Dense population of poorly stained round-oval fungal spores embedded between the cornified keratinocytes. 1,000X. Modified Wright's stain. Bar=10 µm. (c) Freshwater diatom removed from the surface of the shell using tape cytology. 1,000X. Modified Wright's stain. Bar=10 µm. (d) Unspecciated algae removed from the surface of the shell using tape cytology. 100X. Modified Wright's stain. Bar=100 µm.




FIGURE 5. Normal histology of a demineralized section of shell and epidermis. Arrows indicate the junction of the bony shell (B) and dermis (D). The epidermis (E) transitions immediately into a thick layer of keratin (K) that forms the scute. 1000X. H&E stain. Bar=50 µm.

Nineteen shell biopsies were evaluated histologically. Biopsy quality scores ranged from 1 to 4 with a median score of 3 (good). Sections of normal shell were predominated by compact bone with numerous lacunae-entrapped osteocytes (Fig. 5). There was no clear distinction between cortical and cancellous bone. However, the bone had a loculated appearance due to the frequent presence of irregular marrow spaces traversed by capillaries and occupied primarily by adipose and mature heterophils. Cement lines and ossification fronts were readily apparent. The collagenous matrix of the superficial bone blended inconspicuously with haphazardly arranged collagen bundles that composed the pigmented dense dermis. In some sections, dermal collagen

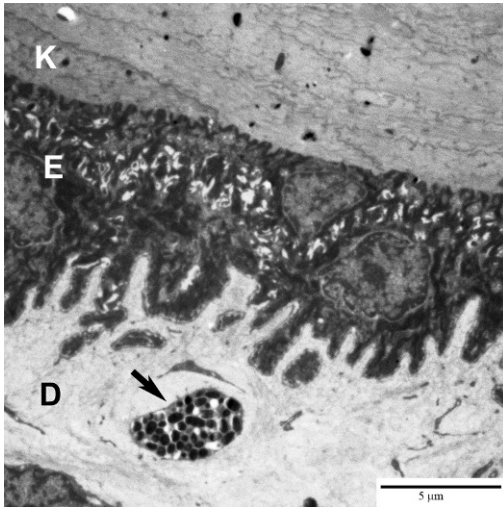


FIGURE 6. Electron micrograph of normal turtle epidermis. Arrow indicates a melanophore within the dermis (D). Note the interdigitation of epithelial cells (E) with the dermis and keratinized scute (K). 4,000 \times . Bar=5 μ m.

extended transmurally through the shell linking interdigitating plates of bone. The thin epidermis was composed of one to two cuboidal to low-columnar epithelial cells that interdigitated with the dermis (Fig. 6). Rete peg formation was completely absent. Epithelial cells had large round to oval nuclei, arranged in a regular to slightly pseudostratified pattern, typically with a single, small, centrally located nucleolus. The epithelium was overlaid by a layer of flaky, translucent keratin containing abundant melanin granules. The transition from epithelial cells to keratin was abrupt and lacked an intermediate zone of cornification. The thickness of the keratin layer varied markedly between sections.

The main abnormalities observed were related to iatrogenic trauma associated with biopsy collection (Fig. 7). Bone fragmentation or artifactual folding of keratin was evident in nine samples, and was generally restricted to the periphery of the section. Loss of epidermis was evident in 12 samples, and in five of these cases, the sections were completely devoid

of epithelium. Loss of dermis was seen in only a single section.

Small clefts and pitting lesions were noted in eight sections. These areas were associated with epidermal hyperpigmentation and hypereosinophilia (Fig. 8). Although overlying dermal and epidermal tissues were attenuated, there was no evidence of erosion, ulceration, or inflammation. Associated with these depressions, the superficial layers of laminated keratin were flaking and infiltrated by linear filaments of varying diameter. Filaments possessed smooth, translucent, pale basophilic, parallel walls and were composed of short blocks of regular lengths. Individual blocks contained homogenous pale eosinophilic cytoplasm, but nuclei were not visualized. Also present were small collections of individual round cells or cells arranged in packets of two to five. All had smooth translucent walls, as described above, abundant pale eosinophilic cytoplasm and a small centrally located basophilic nucleus. Failure to stain with GMS, indicated that these filaments were probably algal and not fungal (Fig. 8). Unidentified detritus and fragments of striated refractile structures suggestive of diatoms were also observed in a number of sections.

Six biopsies yielded three isolates of *Chryseobacterium indologenes* (from three Mississippi map turtles), a single isolate of *Aeromonas hydrophila* (from a northern map turtle), *Ralstonia pickettii* (from a Mississippi map turtle), and *Morganella morganii* (from a Mississippi map turtle). One biopsy from a northern map turtle produced very heavy growth of multiple organisms which were not isolated for identification. Eleven biopsies grew anaerobic spore-forming gram-positive bacilli of five distinct colony types, with each specimen growing at least two of the different morphologies: 1) mucoid colonies were isolated from three Ouachita map turtle, one Mississippi map turtle, and one northern map turtle; 2) runny colonies were isolated from two Ouachita

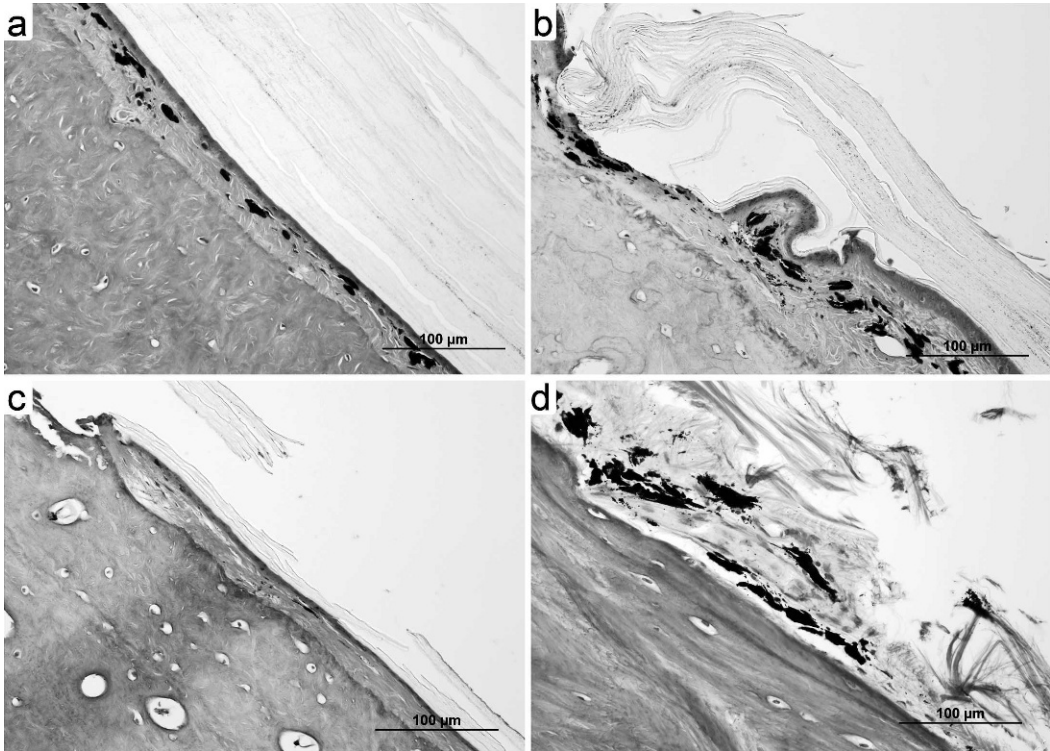


FIGURE 7. Histologic scoring of shell biopsy samples: (a) excellent, complete preservation of bone, epidermal, and keratin layers throughout section; (b) good, mild damage to epidermis at sample margin, with separation of keratin layer; (c) fair, moderate fragmentation of bone and epidermal damage at sample margin, with extensive loss of keratin; and (d) poor, severe damage to bone, epidermal, and keratin layers throughout section. 400 \times . H&E stain. Bar=100 μ m.

map turtles, three Mississippi map turtles, and one black-knobbed map turtle; 3) flat grey colonies were isolated from one Ouachita map turtle, two Mississippi map turtles, and one northern map turtle; 4) white colonies were isolated from three Mississippi map turtles, two Ouachita map turtles, and two northern map turtles; and 5) alpha hemolytic colonies were isolated from two Mississippi map turtles.

One colony type (isolated from two Mississippi map turtles) was identified as *Clostridium butyricum* with a 99.95% confidence factor. The remaining 11 isolates were also identified as members of the genus *Clostridium*, though the BBL Crystal Identification system was unable to speciate these isolates with a high degree of confidence. They were not identified as *Clostridium pefringens*, *Clos-*

tridium difficile or any of the other clostridial species usually associated with toxin production in the clinical setting.

DISCUSSION

All turtles examined in this study had evidence of shell disease, but the etiology and significance of the lesions reported remain unknown. Although it is unknown how long some of these turtles were in captivity before they were originally confiscated, several of the species have ranges restricted to single river systems, thus their shell problems may relate to specific environmental conditions.

There are 50 scutes on the map turtle shell, making individual scute evaluation and statistical computations cumbersome. Consolidation into six regions combined

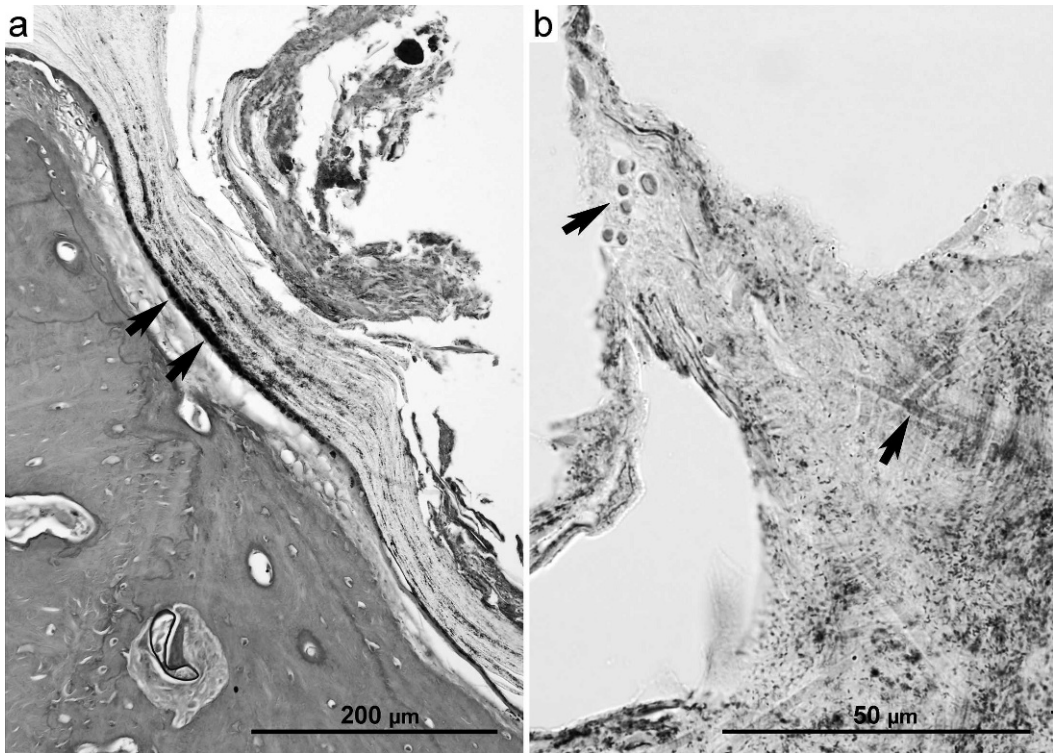


FIGURE 8. Histologic shell abnormalities. (a) Pitting lesion in shell is characterized by hyperpigmentation (arrows) and attenuation of the keratin layer, accompanied by a superficial crust formation. 20 \times . H&E stain. Bar=200 μ m. (b) Higher magnification of crusts composed of bacteria, detritus, and spherical and filamentous forms (arrows) interpreted as algae. 100 \times . Giemsa stain. Bar=50 μ m.

with a basic scoring system for extent and severity reduced the number of statistical calculations, while ensuring that the entire shell was evaluated and represented. The reasons for the species-specific differences in lesion location, extent, and severity as seen here are currently unknown. Nevertheless, a standardized scoring system may be helpful to evaluate disease predilection, and aid in the characterization of both infectious and noninfectious shell diseases in the future. The TSDS provides a single numeric value that enables shell disease to be compared to other animals and permits correlations between shell disease and other measured variables, whether they be animal or environmental. The authors suggest that TSDS would help standardize the gross descriptions of shell disease and promote comparisons. Comparing previous reports is currently difficult given the

varied descriptions of gross shell lesions found throughout the literature.

The injectable anesthetic regime proved to be safe and effective for the purpose of collecting biologic samples; however, incomplete morphine reversal resulted in prolonged recoveries in several animals. Subsequent investigations have indicated that higher doses of naloxone (0.2 mg/kg) are required to consistently and fully reverse the effects of morphine in turtles (Sladky et al., 2007). This regime has been successfully used for a variety of chelonian species and appears to have significant benefits for field use.

Three turtles were considered lethargic and clinically unwell, and all of these had low weight:length ratios and low hematocrits, compared to cohorts. Low weight:length ratio and hematocrit are considered useful indicators of overall health, and

may have indicated chronic ill health, unrelated to the study (Blakey and Kirkwood, 1995; Campbell, 2006). Although one turtle died due to hepatic lipidosis, the other two appeared to recover and have continued without further investigation or treatment. Mean hematocrits from the healthy turtles in this study (19.4%) were significantly lower than those reported for the yellow-blotched map turtle (*Graptemys flavimaculata*; 29.1%; Martinez-Jimenez et al., 2007). This difference could be species-specific or related to the presence of shell disease (although there was no statistical correlation between hematocrit and TSDS). Lymphatic dilution and EDTA-associated hemolysis were considered unlikely because methodologies, including venipuncture site and the use of EDTA, were identical between both studies.

Although mean total protein (2.9 g/dl) and albumin (0.8 g/dl) fall within observed ranges for some other testudinian species, it could be argued that mean globulin levels (2.1 g/dl) are elevated and albumin:globulin ratios decreased (0.4; Wilkinson, 2003; Campbell, 2006). However, without the benefits of a published reference range for these species, or protein electrophoresis to determine the true values of all protein fractions, any discussion is purely speculative. Ionized calcium and 25-hydroxycholecalciferol levels were determined because of the intimate relationship between nutrition and metabolic bone diseases that can affect the shell (Mader, 2006). The absence of metabolic bone disease was not surprising given the management of these animals and their exposure to natural light; however, the determined values for ionized calcium (1.09 ± 0.05 mmol/l) and 25-hydroxycholecalciferol (17.7 ± 5.2 nmol/l) may prove useful for evaluating other freshwater chelonians, especially those maintained under artificial lighting conditions.

No clear conclusions as to the etiology of the shell lesions could be drawn from

tape strip cytology or tissue sections examined by light or electron microscopy. Although the overall quality of the tissue sections was good (2.7/4), with minimal to mild tissue damage present at margins, several were completely stripped of epidermis. Keratin thickness also varied markedly between sections. Superficial damage to the biopsy during collection was due to initial slipping of the trephine during biopsy collection. Using an electrical trephine with finer teeth may help to reduce such trauma. Differences in keratin thickness probably relate to loss of superficial keratin associated with normal ecdysis; however, it is possible that superficial keratin, potentially containing organisms, was lost during collection and processing.

The small pitting lesions contained small conglomerates of multicellular filamentous and single-celled to multicellular spherical structures, a number of unidentified structures, and detritus. These elements, seen during both cytologic and histopathologic examinations of diseased areas, were not associated with an inflammatory response, and were largely absent from cytologic preparations taken from areas of normal shell. It is possible that damaged shell is more likely to be colonized by bacteria, fungi, algae, diatoms, and other debris that would not be able to attach to the smooth surface of normal shell. In previous reports a variety of fungal organisms, such as *Geotrichum* sp., *Penicillium* sp., *Scolecobasidium* sp., *Fusarium* sp., *Drechslera* sp., and other unidentified fungi have been cultured on superficial lesions in turtles (Wiles and Rand, 1987; Sison et al., 1990). All fungal cultures in this study were negative, but bacterial overgrowth may have prevented the identification of mycotic organisms. Although not undertaken in this study, further characterization of the unspiciated clostridial organisms can be undertaken by DNA sequencing. Bacteria, fungi, and viruses were conspicuously absent from all sections examined by light

and electron microscopy, and were considered unlikely causes for the lesions identified. It has been suggested that environmental affects (e.g., changes in water hardness and pH) may be a cause. Water and shell mineral studies were not evaluated in the present study but should be considered in the future.

Ecdysis would normally result in periodic shedding of outer keratin layers. However, damaged or scarred integument is likely to suffer from dysecdysis with retention of keratin and associated accumulation of biota. The possibility that the few keratin-associated changes represented healing and a process of sloughing of the diseased layer is purely speculative.

In conclusion, evaluation of shell disease in chelonians requires a multidisciplinary approach. Detailed evaluation of both the extent and severity of lesions is required, and the concept of TSDS is offered in the hope of creating standardization amongst herpetologists, wildlife biologists, and veterinarians. Full-thickness shell biopsy can be safely performed under injectable anesthesia with basic equipment, and could be performed in the field as well as the hospital environment.

ACKNOWLEDGMENTS

This project was funded by a Conservation and Research grant from the Association of Reptilian and Amphibian Veterinarians. The authors are grateful to J. Schuler, S. Danika, F. Waterman, S. Wyatt, and J. Norman for their assistance.

LITERATURE CITED

- ADKESSON, M. J., E. K. TRAVIS, M. A. WEBER, J. P. KIRBY, AND R. E. JUNGE. 2007. Vacuum-assisted closure for treatment of a deep shell abscess and osteomyelitis in a tortoise. *Journal of the American Veterinary Medical Association* 231: 1249–1254.
- BARTEN, S. L. 2006. Shell damage. *In* Reptile medicine and surgery, 2nd edition, D. R. Mader (ed.). Elsevier, St. Louis, Missouri, pp. 893–899.
- BLAKEY, C. S., AND J. K. KIRKWOOD. 1995. Body mass to length relationships in chelonians. *Veterinary Record* 136: 566–568.
- BOJANUS, L. H. 1819. *Anatome Testudinis Europaeae*. Tipographi Universitatis, Vilnae, Lithuania, 178 pp.
- BOYER, T. H. 1998. Turtles, tortoises, and terrapins. *In* Essentials of reptiles: A guide for practitioners, T. H. Boyer (ed.). American Animal Hospital Association Press, Lakewood, Colorado, pp. 23–72.
- , AND D. M. BOYER. 2006. Turtles, tortoises, and terrapins. *In* Reptile medicine and surgery, 2nd edition. Elsevier, St. Louis, Missouri, pp. 78–99.
- BOZZOLA, J. J. 1999. Specimen preparation for transmission electron microscopy. *In* Electron microscopy: principles and techniques for biologists, J. J. Bozzola (ed.). Jones and Bartlett, Sudbury, Massachusetts, pp. 49–71.
- CAMPBELL, T. W. 2006. Clinical pathology of reptiles. *In* Reptile medicine and surgery, 2nd edition, D. R. Mader (ed.). Elsevier, St. Louis, Missouri, pp. 453–470.
- FRYE, F. L. 1991. Biomedical and surgical aspects of captive reptile husbandry. 2nd edition. Krieger Publishing Co., Malabar, Florida, 637 pp.
- GARNER, M. M., R. HERRINGTON, E. W. HOWERTH, B. L. HOMER, V. F. NETTLES, R. ISAZA, E. B. SHOTTS, AND E. R. JACOBSON. 1997. Shell disease in river cooters (*Pseudemys concinna*) and yellow-bellied turtles (*Trachemys scripta*) in a Georgia (USA) lake. *Journal of Wildlife Diseases* 33: 78–86.
- HOMER, B. L., K. H. BERRY, M. B. BROWN, G. ELLIS, AND E. R. JACOBSON. 1998. Pathology of diseases in wild desert tortoises from California. *Journal of Wildlife Diseases* 34: 508–523.
- [IUCN/SSC] International Union for Conservation of Nature and Species Survival Commission. 2007. *Red List for Testudines*. <http://www.iucn-tfsg.org/red-list/>. Accessed 26 March 2009.
- JACOBSON, E. R., T. J. WRONSKI, J. SCHUMACHER, C. REGGIARDO, AND K. H. BERRY. 1994. Cutaneous dyskeratosis in free-ranging desert tortoises, *Gopherus agassizii*, in the Colorado desert of southern California. *Journal of Zoo and Wildlife Medicine* 25: 68–81.
- KEYMER, I. F. 1978a. Diseases of chelonians: (1) Necropsy survey of tortoises. *Veterinary Record* 103: 548–552.
- . 1978b. Diseases of chelonians: (2) Necropsy survey of terrapins and turtles. *Veterinary Record* 103: 577–582.
- LAFORTUNE, M., J. F. X. WELLEHAN, D. J. HEARD, D. E. ROONEY, C. V. FIORELLO, AND E. R. JACOBSON. 2005a. Vacuum assisted closure (Turtle VAC) in the management of traumatic shell defects in chelonians. *Journal of Herpetological Medicine and Surgery* 15: 4–8.
- , S. P. TERRELL, E. J. JACOBSON, D. J. HEARD, AND J. W. KIMBROUGH. 2005b. Shell and systemic hyalohyphomycosis in Fly River turtles (*Carettochelys insculpta*) caused by *Paecil-*

- myces lilacinus*. Journal of Herpetological Medicine and Surgery 15: 15–19.
- LOVICH, J. E., S. W. GOTTE, C. H. ERNST, J. C. HARSHBARGER, A. F. LAEMMERZAHN, AND J. W. GIBBONS. 1996. Prevalence and histopathology of shell disease in turtles from Lake Blackshear, Georgia. Journal of Wildlife Diseases 32: 259–265.
- LUNA, L. G. 1968. Histologic staining methods of the AFIP, 3rd edition. McGraw-Hill Book Co, New York, New York, 258 pp.
- MADER, D. R. 2006. Metabolic bone diseases. In Reptile medicine and surgery, D. R. Mader (ed.). Elsevier, St. Louis, Missouri, pp. 841–851.
- MARTINEZ-JIMENEZ, D., S. J. HERNANDEZ-DIVERS, T. M. FLOYD, S. BUSH, H. WILSON, AND K. S. LATIMER. 2007. Comparison of the effect of dipotassium ethylenediaminetetraacetic acid and lithium heparin on hematologic values in yellow-blotched map turtles (*Graptemys flavimaculata*). Journal of Herpetological Medicine and Surgery 17: 36–41.
- MCAARTHUR, S., J. MEYER, AND C. INNIS. 2004. Anatomy and physiology. In Medicine and surgery of tortoises and turtles, S. McArthur, R. Wilkinson, J. Meyer, C. Innis and S. Hernandez-Divers (eds.). Blackwell Publishing, Oxford, UK, pp. 35–72.
- MENDELSON, C., W. ROSENKRANTZ, AND C. E. GRIFFIN. 2006. Practical cytology for inflammatory skin diseases. Clinical Techniques in Small Animal Practice 21: 117–127.
- REYNOLDS, E. S. 1963. The use of lead citrate at high pH as an electron-opaque stain in electron microscopy. Journal of Cell Biology 17: 208–212.
- ROSE, F. L., J. KOKE, R. KOEHN, AND D. SMITH. 2001. Identification of the etiological agent for necrotizing scute disease in the Texas tortoise. Journal of Wildlife Diseases 37: 223–228.
- SISON, T. M., M. A. PADILLA, M. Z. VIZMANOS, AND M. FOLLOSCO. 1990. Isolation and identification of fungi found in necrotic skin lesions of captive marine turtles (*Eretmochelys imbricata*). Philippine Journal of Veterinary Medicine 27: 35–36.
- SLADKY, K. K., V. MILETIC, J. PAUL-MURPHY, M. E. KINNEY, R. K. DALLWIG, AND S. M. JOHNSON. 2007. Analgesic efficacy and respiratory effects of butorphanol and morphine in turtles. Journal of the American Veterinary Medical Association 230: 1356–1362.
- SPURR, A. R. 1969. A low-viscosity epoxy resin embedding medium for electron microscopy. Journal of Ultrastructure Research 26: 31–43.
- WILES, M., AND T. G. RAND. 1987. Integumental ulcerative disease in a loggerhead turtle *Caretta caretta* at the Bermuda Aquarium: Microbiology and histopathology. Diseases of Aquatic Organisms 3: 85–90.
- WILKINSON, R. 2003. Clinical pathology. In Medicine and surgery of tortoises and turtles, S. M. McArthur, R. Wilkinson and J. Meyer (eds.). Blackwell Publishing, Oxford, UK, pp. 141–186.

Received for publication 22 June 2008.