

## **EXPERIMENTAL INFECTION OF WHITE-TAILED DEER FAWNS (ODOCOILEUS VIRGINIANUS) WITH BOVINE VIRAL DIARRHEA VIRUS TYPE-1 ISOLATED FROM FREE-RANGING WHITE-TAILED DEER**

Authors: Raizman, E. A., Pogranichniy, R., Lévy, M., Negron, M., Langohr, I., et al.

Source: Journal of Wildlife Diseases, 45(3) : 653-660

Published By: Wildlife Disease Association

URL: <https://doi.org/10.7589/0090-3558-45.3.653>

---

BioOne Complete ([complete.BioOne.org](https://complete.BioOne.org)) is a full-text database of 200 subscribed and open-access titles in the biological, ecological, and environmental sciences published by nonprofit societies, associations, museums, institutions, and presses.

Your use of this PDF, the BioOne Complete website, and all posted and associated content indicates your acceptance of BioOne's Terms of Use, available at [www.bioone.org/terms-of-use](https://www.bioone.org/terms-of-use).

Usage of BioOne Complete content is strictly limited to personal, educational, and non - commercial use. Commercial inquiries or rights and permissions requests should be directed to the individual publisher as copyright holder.

---

BioOne sees sustainable scholarly publishing as an inherently collaborative enterprise connecting authors, nonprofit publishers, academic institutions, research libraries, and research funders in the common goal of maximizing access to critical research.

# EXPERIMENTAL INFECTION OF WHITE-TAILED DEER FAWNS (*ODOCOILEUS VIRGINIANUS*) WITH BOVINE VIRAL DIARRHEA VIRUS TYPE-1 ISOLATED FROM FREE-RANGING WHITE-TAILED DEER

E. A. Raizman,<sup>1,3</sup> R. Pogranichniy,<sup>1</sup> M. Lévy,<sup>2</sup> M. Negron,<sup>2</sup> I. Langohr,<sup>1</sup> and W. Van Alstine<sup>1</sup>

<sup>1</sup> Department of Comparative Pathobiology, School of Veterinary Medicine, Purdue University, West Lafayette, Indiana 47907, USA

<sup>2</sup> Department of Clinical Sciences, School of Veterinary Medicine, Purdue University, West Lafayette, Indiana 47907, USA

<sup>3</sup> Corresponding author (email eraizman@purdue.edu)

**ABSTRACT:** The objective of the current study was to elucidate the within-host dynamics of bovine viral diarrhea virus (BVDV) type-1 infection to better understand how this virus could be maintained in white-tailed deer (*Odocoileus virginianus*, WTD) populations. The BVDV type-1 used in this study was originally isolated from a free-ranging WTD in Indiana. Four fawns were intranasally inoculated with 2 ml BVDV type-1 strain 544 WTD at a 10<sup>6</sup> tissue culture infectious dose (TCID<sub>50</sub>)/ml. Two fawns were inoculated with sham inoculum (negative controls). Animals were bled on days –7, 0, 1, 7, and 14 postinoculation (PID) for a complete blood count, chemistry panel, buffy coat (BC), real-time RT-PCR, and virus neutralization (VN). On days 7 and 14 PID, nasal and rectal swabs were obtained for RT-PCR and two of the virus-inoculated fawns and one of the negative controls fawns were euthanized. At necropsy, multiple samples were obtained for histopathology and in situ hybridization (ISH). Quantitative RT-PCR was performed on serum, BC, nasal, and rectal swabs. All animals tested negative for BVDV type 1 neutralizing antibodies on day 0 and animals in the control group remained seronegative throughout the study. No gross lesions were observed at necropsy. BVDV was isolated from lung and pooled lymph nodes from all BVDV-inoculated fawns on days 7 and 14 PID. Infected deer had lymphoid depletion, apoptosis, and lymphoid necrosis in the Peyer's patches and mesenteric lymph nodes. BVDV was detected in lymphoid tissues of infected animals by ISH. No lesions or virus were identified in control fawns. On day 7 PID, samples from two virus-inoculated fawns were positive for BVDV by virus isolation and RT-PCR from BC and nasal swab samples. One fawn was also positive on a rectal swab. Nasal and rectal swabs from all animals were negative on day 14. Results indicate that infection of WTD with BVDV is possible, and leads to histologic lesions in variety of tissues. In addition, virus shedding into the environment through feces and other secretions is likely.

**Key words:** Bovine viral diarrhea virus, BVDV, experimental infection, white-tailed deer.

## INTRODUCTION

Bovine viral diarrhea virus (BVDV) is a positive-stranded RNA pestivirus (Bolin and Grooms, 2004) and has been associated with vast economic losses to the dairy cattle industry (Chi et al., 2002; Houe, 2003; Tiwari et al., 2005). The combined economic impact of BVDV has been estimated at a 20 to 57 million dollar loss per million calving in the US. Based on the 2005 USA calf crop of 38 million, the cost of BVDV to USA producers was 760 million to 2.2 billion dollars in that year (Driskell and Ridpath, 2006).

In cattle, the virus causes a variety of clinical manifestations which can vary from clinically inapparent infection to acute or chronic severe disease (Baker,

1995); BVDV has been associated with neonatal diarrhea in calves (Werding et al., 1989) and might predispose them to respiratory tract infections (Brodersen and Kelling, 1998). However, the most important economical consequence of BVDV infection is reproductive loss. Depending on the time of infection during gestation, BVDV can cause early embryonic death, abortion, congenital defects, and variety of postnatal clinical manifestations including fever, nasal and ocular mucopurulent discharge, profuse watery diarrhea, and mucosal lesions (Grooms, 2004). Fetuses that survive infection with noncytopathic BVDV between 18 and 125 days of gestation invariably develop immune tolerance to the virus and subsequently become persistently infected (PI;

Grooms, 2004). Because PI calves are thought to be the primary nidus of viral infection within herds, the key for BVDV control is to interfere with the process by which the PI calves are generated (Lindberg and Houe, 2005).

Although many US Department of Agriculture (USDA)-approved BVDV vaccines (using killed or modified-live virus) are commercially available, the efficacy of these vaccines to protect fetuses against infection has been questioned (Dubovi, 1992; Van Campen et al., 1998; van Oirschot et al., 1999). Sporadic occurrence of PI calves from vaccinated cows is consistent with the results of experimental challenge-exposure studies. Those studies have demonstrated partial protection against fetal infection using both modified-live and inactivated BVDV vaccines (Ellsworth et al., 1993). Furthermore, a retrospective study in the northwestern US found an increased prevalence of fetal infections and consequently PIs between 1980 and 2000, despite a high (60%) rate of vaccination (Evermann and Ridpath, 2002). This might suggest that the use of BVDV vaccines does not sufficiently reduce the incidence of BVDV fetal infections. Purchasing PI heifers is a primary source of BVDV introduction into naïve herds (Houe, 2005); hence BVDV introduction into herds continues despite vaccination.

Over-pasture fence contact and other animal traffic were also identified as important risk factors for BVDV introduction into noninfected herds (Valle et al., 1999). Direct or indirect contact of infected animals or populations, wild or domestic, with susceptible populations at the interface of their ranges is an important factor responsible for the cause of outbreaks of diseases (Bengis et al., 2002). Furthermore, many pathogens that can influence domestic animal health are sustained in wildlife populations (Van Campen et al., 2001). Hence, the impact of a disease in wild animal populations can have economic significance if the wild animal species is a reservoir of infection for domestic animals.

The evidence for BVDV infection in free-ranging animals includes serologic surveys and virus isolations (Nettelton, 1990). Serologic surveys in free-ranging and captive wildlife indicate infection with BVDV or related pestiviruses in a variety of species such as Scottish red deer (*Cervus elaphus scoticus*), Roe deer (*Capreolus capreolus*), European Bison (*Bison bonasus*) and other wild ruminants (Romvary, 1965; McMartin et al., 1977; Doyle and Heuschele, 1983; Nielsen et al., 2000; Borchers et al., 2002). Thus, BVDV infection introduction into the herd through wildlife is plausible.

Wildlife reservoirs for domestic livestock diseases can seriously undermine the effectiveness of disease control strategy in domestic species by escalating the number of susceptible animals in which the disease can persist, especially at the wildlife-livestock interface. As suggested by Simpson (2002), the reintroduction of BVDV to negative cattle herds can be due to contact with a wildlife reservoir.

The objective of the current study was to elucidate the within-host dynamics of BVDV infection and to relate it to how the virus can be maintained in white-tailed deer (WTD, *Odocoileus virginianus*) populations, using a BVDV type-1 isolated from a free-ranging WTD in Indiana. Specifically, we aimed to assess if inoculation with BVDV can cause WTD to develop typical clinical and pathologic signs as described for cattle, as well if they shed the virus through feces and other secretions. A better understanding of the potential risk of interspecies BVDV transmission between free-ranging WTD and domestic cattle may lead to improvement of BVDV biosecurity and control programs.

## MATERIAL AND METHODS

### Inoculum and study animals

In November 2006, 311 ear notches and more than 434 lymph nodes were collected from harvested deer during the firearm hunting seasons in Indiana, USA and tested

by capture ELISA, virus isolation, and PCR assays for BVDV. Noncytopathic BVDV isolates from two deer were genotyped as a BVDV type-1a and one of these isolates was used in this study as inoculum (GenBank accession number 1077526; Pogranichniy et al., 2008).

Six WTD fawns from a captive deer breeding farm in northern Indiana were used in this study. Fawns were between 2 to 3 wk old and were negative for BVDV virus by quantitative RT-PCR assay on buffy coat (BC) samples. Neutralizing antibodies against BVDV were not detected in any of these animals. All fawns were housed in separate rooms in a biosecurity facility for animal experiments at Purdue University. Fawns were housed in the facility 3 days before the beginning of the trial and were bottle fed with a deer milk replacer (Zoologic Doe Milk Replacer, PetAg, Hampshire, Illinois, USA) 4–5 times a day throughout both the acclimatization (3 days) and the trial (14 days) period.

#### Experimental infection and sample collection

Four fawns were intranasally inoculated with 2 ml of noncytopathic BVDV 1 strain 544 WTD virus suspension with a titer of  $10^6$  tissue culture infectious dose ( $TCID_{50}$ )/ml; the inoculum had been passed three times in cell culture free of pestiviruses. Two fawns received sham inoculums (medium only) and served as negative controls.

The clinical condition of each animal was evaluated daily; rectal temperature, pulse, and respiration rates were recorded. Clinical evaluations of attitude, appetite, consistency of feces, and presence or absence of abnormal respiratory signs also were recorded daily.

Animals were bled on days –7 (on farm), 0 (immediately prior to inoculation), and 1, 7, and 14 postinoculation (PID). Whole blood and serum were collected for complete blood count (CBC), chemistry panel, BC real-time RT-PCR on BC, virus neutralization (VN), and ELISA. On days 7 and 14 PID, two of the virus-inoculated fawns and one of the negative controls fawns were euthanized for postmortem examination using intravenous euthanasia solution (Fatal-Plus®, Vortech Pharmaceuticals, Dearborn, Michigan, USA) according to label directions. On both days nasal and rectal swabs were obtained for real-time RT-PCR.

At necropsy, samples of lymphoid organs (tonsil, spleen, thymus, and retropharyngeal, mandibular, and mesenteric lymph nodes), digestive tract (esophagus, rumen, abomasum, duodenum, jejunum, colon, Peyer's patches in the jejunum, ileum, colon, and rectum),

respiratory tract (trachea and lung), urogenital organs (kidney and testes), CNS tissues (cerebrum, hippocampus, and cerebellum), heart, skin, and bone marrow were collected for histopathology, virus isolation, and real-time RT-PCR; serum was collected for virus neutralization assays for BVDV antibodies. From each tissue, one sample was fixed in 10% formalin for histopathology and the second sample was frozen at –80 C for virus isolation and real-time RT-PCR. Serum samples were stored at –20 C. The CBC was performed by the Clinical Pathology Laboratory of Purdue Veterinary Teaching Hospital.

#### Virus isolation and PCR

Madin Darby Bovine Kidney (MDBK) cells were prepared in 48-well plates grown in media supplemented with 5% (v/v) horse serum (Sigma Chemical Co., St. Louis, Missouri, USA), 20 mM L-glutamine (Gibco/BRL Life Science, Grand Island, New York, USA), and an antibiotic-antimycotic mixture that consists of 100 IU/ml penicillin, 10 µg/ml streptomycin, and 50 µg/ml gentamicin (Sigma Chemical Co.). The samples were inoculated (0.25 ml/well) in duplicate or triplicate on cell suspension and left for 24 hr before being removed. Inoculated cells were observed daily for cytopathic effect (CPE). When CPE was evident in more than 70% of the cell monolayer, cell culture medium was harvested and inoculated onto freshly prepared cells in duplicate. At day 2 postinoculation, cells on duplicate 48-well plates were fixed after the cell culture media was harvested by immersing them in cold 80% aqueous acetone and subjected to immunofluorescence microscopy using FITC-labeled antibodies (USDA NVSL, Ames, Iowa, USA; American Bioresearch, Inc., Seymour, Tennessee, USA) raised against BVDV. The BVDV virus for inoculum was propagated using same protocol only in 75 cm<sup>2</sup> cell culture flasks.

Quantitative real-time reverse transcriptase (RT)-PCR was performed on serum, BC, nasal, and rectal swabs as previously described (Baxi et al., 2006). Viral RNA was extracted from the appropriate sample using QIAamp® viral RNA extraction kit (Qiagen, Santa Clarita, California, USA) as recommended by the manufacturer. Real-time PCR was performed on clinical samples as described by targeting 5' untranslated region of the viral genome. Real-time RT-PCR was used with the QuantiTect Probe real-time RT-PCR Kit (Qiagen) in a 25 µl reaction volume using 2.5 µl extracted template. Primers were added at a final concentration of 0.4 µM each, and

the probe was at a final concentration of 0.2  $\mu$ M. For quantification, we used a set of BVDV type 1 preparations each with a known virus titer to generate a standard curve. The set of standards was included in each run with clinical samples to determine the validity, relative amount, and reproducibility of the assay. The amount of BVDV in each sample was calculated by converting Ct value to virus titer using the standard curve.

#### Histopathology and in-situ hybridization (ISH)

Collected tissues were fixed by immersion in 10% neutral buffered formalin immediately after collection. Fixed tissues were processed, embedded, and sectioned at 5  $\mu$ m using routine technique. Each section was then stained with hematoxylin and eosin.

In order to demonstrate BVDV nucleic acid, ISH was performed on sections of small intestine and mesenteric lymph node of BVDV-inoculated and of negative control deer using a specific 20-mer oligoprobe designed to hybridize with the gene of the viral non-structural protein 3 (NS3) with sequence information (5' TAG ATG AA(G)T ACC ACT GTG C-3'). Briefly, tissue sections from inoculated and control animals were deparaffinized, digested with 20  $\mu$ g/ml of proteinase K, and prehybridized at 42 C for 1 hr. Hybridization was performed overnight at 42 C with the specific 5'-end digoxigenin labeled oligoprobe at a concentration of 2 ng/ $\mu$ l. The detection system consisted of antidigoxigenin antibody conjugated with alkaline phosphatase (dilution 1:500) and the substrates nitroblue tetrazolium (NBT) and 5-bromo-4-chloro-3-indolyl phosphate (BCIP) (Roche Diagnostics Corporation, Indianapolis, Indiana, USA). Sections of intestine and ear notch of acutely and persistently BVDV infected calves, respectively, were used as positive controls. This procedure was modified from a previously published protocol (Gregory et al., 1996).

#### Virus neutralization

Test sera were diluted in a two-fold series from an initial dilution of 1:4 to a maximum dilution of 1:512; each dilution was added to wells of a 96-well tissue culture plate in triplicate. Antigen consisting of 50  $\mu$ l of media containing 200 TCID<sub>50</sub> of BVDV type 1 and BVDV type 2 was added to each well and plates were incubated at 37 C for 2 hr. Fifty  $\mu$ l of suspension of MDBK cells at  $3 \times 10^5$  cells/ml were added to each well and the plates were incubated for a further 3 days at 37 C at 5% CO<sub>2</sub>. Antibody titers were

determined by microscopic examination of the monolayer of cells for cytopathic effect 72 hr postinoculation. Results were expressed as the reciprocal of the serum dilution at which 50% neutralization of virus will occur. A 2-fold or greater antibody titer increase was considered as seroconversion.

## RESULTS

Fawns from both groups remained healthy throughout the study. Temperature, pulse, and respiration remained in the same range before and after inoculation, and appetite remained good during the postinoculation period. Sporadically, before and during the study period, all fawns had fresh blood in their feces, but not for more than three consecutive days. Vital signs, level of activity, and appetite were not affected. Examination of the feces of one of the fawns demonstrated the presence of *Eimeria* oocysts and *Strongyloides papillosus* ova. As a result, all animals were treated with 50 mg/kg amprolium (Corid®, Merial US, Duluth, Georgia, USA) once a day for five consecutive days at the first sign of hematochezia.

All animals tested negative for BVDV type 1 neutralizing antibodies prior to inoculation and throughout the entire study period.

On day 7 PID, BC and nasal swab samples from two BVDV-inoculated fawns were positive using real-time RT-PCR. One of these two fawns also had a positive rectal swab on day 7 PID. On day 14 PID, all nasal and rectal swabs as well as BC samples obtained from the remaining two virus-inoculated fawns and one sham-inoculated negative control fawn were negative for BVDV (Table 1). BVDV was isolated from lung and pooled lymph nodes of all four BVDV-inoculated fawns following necropsy (Table 1).

Gross lesions were not identified in any of the fawns. On day 7 PID, BVDV-infected deer had mild to slight lymphoid depletion with apoptosis and lymphoid necrosis in the Peyer's patches and



TABLE 1. Test results from an experimental infection of white-tailed deer fawns with bovine viral diarrhea virus type-1 isolated from free-ranging white-tailed deer in Indiana, USA.<sup>a</sup>

Deer number	RT-PCR nasal and rectal swabs		Virus isolation		ISH	
	Day 7	Day 14	Day 7	Day 14	Day 7	Day 14
1	+	NA	+	NA	+	NA
2	+	NA	+	NA	+	NA
3	—	—	NA	+	NA	+
4	—	—	NA	+	NA	+
5 Control	—	—	—	—	—	—
6 Control	—	—	—	—	—	—

<sup>a</sup> RT-PCR=Reverse transcriptase PCR; ISH=In situ hybridization; NA=Not applicable; +=Positive; —=Negative.

mesenteric lymph nodes (Figs. 1 and 2). By day 14 PID, a profound lymphoid depletion was identified. Mild lymphocytic vasculitis with some smooth muscle cell degeneration and necrosis was present in a few small-caliber muscular arteries in the bone marrow, pancreas, kidney, small intestine, and large intestine.

Negative control sections remained negative for BVDV (Fig. 3A). Among the virus-inoculated fawns necropsied at day 7 and 14 PID, positive signal for BVDV was present within lymphocytes in lymphoid aggregates in the Payer's patches (Fig. 3B), mesenteric lymph nodes, and in scattered ganglion cells of the myentric plexi in the small intestine (Table 1).

## DISCUSSION

This study confirmed that WTD fawns could be experimentally infected with a type-1 BVDV isolated from free-roaming deer in northern Indiana, develop histologic lesions, and shed the virus through feces and nasal secretions. Recently, Ridpath et al. (2007) described a similar study where fawns were inoculated with BVDV isolated from free-living WTD. Unlike Ridpath et al. (2007), however, clinical signs were not observed in this study, despite successful infection. The differences between the two studies likely are due to the use of different BVDV isolates or infectious dose. Van Campen et al. (1997) describes a similar study in mule deer (*Odocoileus hemionus*) and

WTD inoculated with the NewYork-1 strain of BVDV isolated from cattle. Similar to our study, none of the animals in the Van Campen study developed clinical signs, although virus was recovered as long as days 15 PID. The absence of clinical signs increases the probability that BVDV infection in WTD would not incapacitate the deer, which increases the chance that WTD can remain in contact with cattle and serve as a reservoir of the virus for cattle. Potential transmission through virus shedding by persistently infected (PI) animals within a cattle herd is well documented (Grooms, 2004). Epidemiologically, the role of persistently infected WTD in BVDV transmission to herdmates should be further investigated. To study PI in deer, Passler et al. (2007) infected pregnant WTD does (at 50 days gestation) with BVDV which originated from cattle, and one doe delivered a PI fawn and a mummified fetus.

The potential role of both PI WTD and transiently infected deer on the control of BVDV in domestic cattle is not currently understood. Our study indicates that BVDV type 1 isolated from deer was infectious to fawns and caused lesions. Thus, BVDV feasibly could be shed into the environment. Data from this experiment indicates that horizontal transmission of BVDV between individual deer might be plausible, and based on our results, infections in a white-tailed deer herd can occur without overt clinical signs.

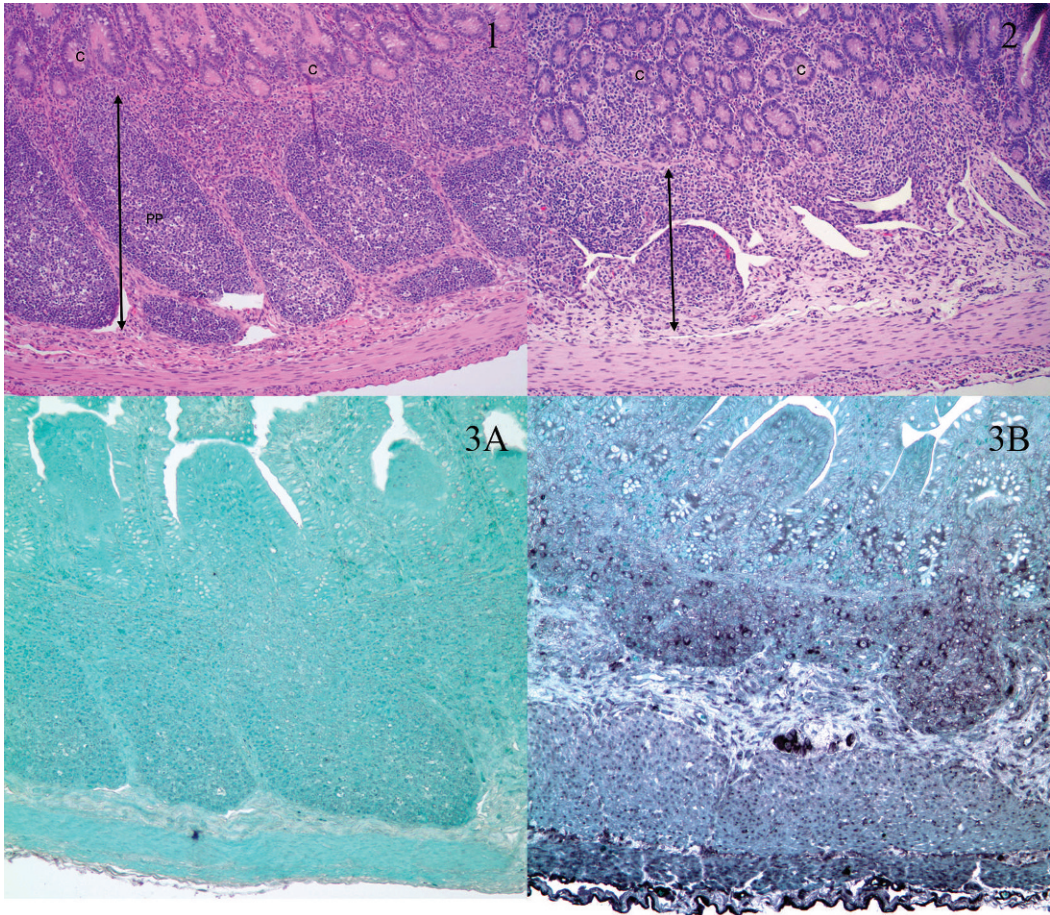


FIGURE 1. Negative control deer. Well-defined Peyer's Patches (arrow, PP) with normal population of lymphocytes. Intestinal crypt epithelium (C) is unremarkable. H&E stain. 100 $\times$  original magnification.

FIGURE 2. BVD virus-infected deer. Peyer's Patches (arrow) are depleted of lymphocytes. Intestinal crypt epithelium (C) is unremarkable. H&E stain. 100 $\times$  original magnification.

FIGURE 3. Photomicrographs of Peyer's Patches (A, B) from a negative control fawn (A) and a fawn experimentally infected with BVDV 1 in which the virus was detected *by in situ* hybridization (B). 200 $\times$  original magnification.

Because deer are often abundant near cattle farms (Raizman et al., 2005), future studies should address the feasibility of horizontal transmission between deer and cattle and vice versa through direct and indirect contact.

#### ACKNOWLEDGMENTS

The authors want to thank F. Douglas from Purdue Animal Facility for his assistance with the study, and D. Hoffmann from PetAg, Inc. for the milk replacer donation.

#### LITERATURE CITED

- BAKER, J. C. 1995. The clinical manifestations of bovine viral diarrhea infection. *Veterinary Clinics of North America Food Animal Practice* 1: 425–445.
- BENGIS, R. G., R. A. KOCK, AND J. FISCHER. 2002. Infectious animal diseases: The wildlife/livestock interface. *Revue scientifique et technique/Office International des Epizooties* 21: 53–65.
- BOLIN, S. R., AND D. L. GROOMS. 2004. Origination and consequences of bovine viral diarrhea virus diversity. *Veterinary Clinics of North America Food Animal Practice* 20: 51–68.

- BORCHERS, K., J. BRACKMANN, O. WOLF, M. RUDOLPH, P. GLATZEL, M. KRASINSKA, Z. A. KRASINSKI, AND K. FRÖLICH. 2002. Virologic investigations of free-living European bison (*Bison bonasus*) from the Bialowieza Primeval Forest, Poland. *Journal of Wildlife Diseases* 38: 533–538.
- BRODERSEN, B. W., AND C. L. KELLING. 1998. Effect of concurrent experimentally induced bovine respiratory syncytial virus and bovine viral diarrhoea virus infection on respiratory tract and enteric diseases in calves. *American Journal of Veterinary Research* 59: 1423–1430.
- CHI, J., J. A. VAN LEEUWEN, A. WEERSINK, AND G. P. KEEFE. 2002. Direct production losses and treatment costs from bovine viral diarrhoea virus, bovine leukosis virus, *Mycobacterium avium* subspecies *paratuberculosis*, and *Neospora caninum*. *Preventive Veterinary Medicine* 55: 137–153.
- DOYLE, L. G., AND W. P. HEUSCHELE. 1983. Bovine viral diarrhoea infection in captive exotic ruminants. *Journal of the American Veterinary Medical Association* 183: 1257–1259.
- DRISKELL, E. A., AND J. F. RIDPATH. 2006. A survey of bovine viral diarrhoea virus testing in diagnostic laboratories in the United States from 2004 to 2005. *Journal of Veterinary Diagnostic Investigation* 18: 600–605.
- DUBOVI, E. 1992. Fetal infection may not be preventive with BVDV vaccines. *Comparative Immunology, Microbiology and Infectious Diseases* 15: 155–162.
- ELLSWORTH, M., C. KELLING, E. DICKENSON, R. CRAVENS, AND E. EIDE. 1993. Fatal infection following intravenous bovine viral diarrhoea virus challenge of vaccinated and nonvaccinated dams. *In Proceedings of the Conference of Animal Diseases Researchers*, Chicago, Illinois, 5–7 December, p. 72.
- EVERMANN, J. F., AND J. F. RIDPATH. 2002. Clinical and epidemiologic observations of bovine viral diarrhoea virus in the northwestern United States. *Veterinary Microbiology* 89: 129–139.
- GREGORY, C. R., K. S. LATIMER, AND F. D. NIAGRO. 1996. Detection of eastern equine encephalomyelitis virus RNA in formalin-fixed, paraffin-embedded tissues using DNA in situ hybridization. *Journal of Veterinary Diagnostic Investigation* 8: 151–155.
- GROOMS, D. L. 2004. Reproductive consequences of infection with bovine viral diarrhoea virus. *Veterinary Clinics of North America Food Animal Practice* 20: 5–19.
- HOUE, H. 2003. Economic impact of BVDV infection in dairies. *Biologicals* 31: 137–143.
- . 2005. BVD Risk assessment. *In Bovine viral diarrhoea virus: Diagnosis, management, and control*, S. M. Goyal and J. F. Ridpath (eds.). Blackwell Publishing, Oxford, United Kingdom, pp. 35–64.
- LINDBERG, A., AND H. HOUE. 2005. Characteristics in the epidemiology of bovine viral diarrhoea virus (BVDV) of relevance to control. *Preventive Veterinary Medicine* 72: 55–73.
- MCMARTIN, D. A., D. R. SNODGRASS, AND W. GONJALL. 1977. Bovine virus diarrhoea antibody in a Scottish red deer. *Veterinary Record* 100: 85–91.
- NETTLETON, P. F. 1990. Pestivirus infections in ruminants other than cattle. *Revue scientifique et technique/Office International des Epizooties* 9: 131–150.
- NIELSEN, S. S., L. ROENSHOLT, AND V. BITSCH. 2000. Bovine virus diarrhoea virus in free-living deer from Denmark. *Journal of Wildlife Diseases* 36: 584–587.
- PASSLER, T., P. H. WALZ, S. S. DITCHKOFF, M. D. GIVENS, H. S. MAXWELL, AND K. V. BROCK. 2007. Experimental persistent infection with bovine viral diarrhoea virus in white-tailed deer. *Veterinary Microbiology* 122: 350–356.
- POGRANICHNIY, R. M., E. A. RAIZMAN, L. THACKER, AND G. W. STEVENSON. 2008. Prevalence and characterization of bovine viral diarrhoea virus in the white-tailed deer population in Indiana. *Journal of Veterinary Diagnostic Investigation* 20: 71–74.
- RAIZMAN, E. A., S. J. WELLS, P. A. JORDAN, G. D. DELGUIDICE, AND R. R. BEY. 2005. *Mycobacterium avium* subsp. *paratuberculosis* from free-ranging deer and rabbits surrounding Minnesota dairy herds. *Canadian Journal of Veterinary Research* 69: 32–38.
- RIDPATH, J. F., C. S. MARK, C. C. CHASE, A. C. RIDPATH, AND J. D. NEILL. 2007. Febrile response and decrease in circulating lymphocytes following acute infection of white-tailed deer fawns with either a BVDV1 or a BVDV2 strain. *Journal of Wildlife Diseases* 43: 653–659.
- ROMVARY, J. 1965. Incidence of virus diarrhoea among roes. *Acta Veterinaria Hungarica* 15: 451–455.
- SIMPSON, V. R. 2002. Wild animals as reservoirs of infectious diseases in the UK. *Veterinary Journal* 163: 128–146.
- TIWARI, A., J. A. VAN LEEUWEN, I. R. DOHOO, H. STRYHN, G. P. KEEFE, AND J. P. HADDAD. 2005. Effects of seropositivity for bovine leukemia virus, bovine viral diarrhoea virus, *Mycobacterium avium* subspecies *paratuberculosis*, and *Neospora caninum* on culling in dairy cattle in four Canadian provinces. *Veterinary Microbiology* 109: 147–158.
- VALLE, P. S., S. W. MARTIN, AND R. TREMBLAY. 1999. Factors associated with being a bovine-virus diarrhoea (BVD) seropositive herd in the Møre and Romsdal county in Norway. *Preventive Veterinary Medicine* 40: 165–177.
- VAN CAMPEN, H., K. FRÖLICH, AND M. HOFMANN. 2001. Pestivirus infections. *In Infectious disease of wild mammals*, E. S. Williams and I. K. Barker (eds.). Iowa State University Press, Ames, Iowa, pp. 232–244.



- , S. HUZURBAZAR, J. EDWARDS, AND J. L. CAVENDER. 1998. Distribution of antibody titers to bovine viral diarrhoea virus in infected, exposed and uninfected beef cattle. *Journal of Veterinary Diagnostic Investigation* 10: 183–186.
- , E. S. WILLIAMS, J. EDWARDS, W. COOK, AND G. STOUT. 1997. Experimental infection of deer with bovine viral diarrhea virus. *Journal of Wildlife Diseases* 33: 567–573.
- VAN OIRRSCHOT, J., C. BRUSCHKE, AND P. VAN RIJN. 1999. Vaccination of cattle against bovine viral diarrhoe. *Veterinary Microbiology* 64: 169–183.
- WERDIN, R. E., T. R. AMES, S. M. GOYAL, AND G. P. DEVRIES. 1989. Diagnostic investigation of bovine viral diarrhea infection in a Minnesota dairy herd. *Journal of Veterinary Diagnostic Investigation* 1: 57–61.

*Received for publication 4 April 2008.*