

Association of *Mycoplasma corogypsi* and Polyarthritits in a Black Vulture (*Coragyps atratus*) in Virginia

Authors: Ruder, Mark G., Feldman, Sanford H., Wünschmann, Arno, and McRuer, David L.

Source: Journal of Wildlife Diseases, 45(3) : 808-816

Published By: Wildlife Disease Association

URL: <https://doi.org/10.7589/0090-3558-45.3.808>

BioOne Complete (complete.BioOne.org) is a full-text database of 200 subscribed and open-access titles in the biological, ecological, and environmental sciences published by nonprofit societies, associations, museums, institutions, and presses.

Your use of this PDF, the BioOne Complete website, and all posted and associated content indicates your acceptance of BioOne's Terms of Use, available at www.bioone.org/terms-of-use.

Usage of BioOne Complete content is strictly limited to personal, educational, and non - commercial use. Commercial inquiries or rights and permissions requests should be directed to the individual publisher as copyright holder.

BioOne sees sustainable scholarly publishing as an inherently collaborative enterprise connecting authors, nonprofit publishers, academic institutions, research libraries, and research funders in the common goal of maximizing access to critical research.

Association of *Mycoplasma corogypsi* and Polyarthrititis in a Black Vulture (*Coragyps atratus*) in Virginia

Mark G. Ruder,^{1,4,5} Sanford H. Feldman,² Arno Wünschmann,³ and David L. McRuer¹
¹ Wildlife Center of Virginia, Waynesboro, Virginia 22980, USA; ² Center for Comparative Medicine, University of Virginia, Charlottesville, Virginia 22908, USA; ³ Veterinary Diagnostic Laboratory, Department of Veterinary Population Medicine, College of Veterinary Medicine, University of Minnesota, St. Paul, Minnesota 55108, USA; ⁴ Current address: Southeastern Cooperative Wildlife Disease Study, Department of Population Health, College of Veterinary Medicine, The University of Georgia, Athens, Georgia 30602, USA; ⁵ Corresponding author (email: mgruder@uga.edu)

ABSTRACT: On 10 October 2007, a Black Vulture (*Coragyps atratus*) was presented to the Wildlife Center of Virginia, Waynesboro, Virginia, USA, because of an inability to fly. Examination revealed multiple swollen, fluctuant joints. The bird suffered from lead toxicosis and had a prominent leukocytosis. Histopathologic evaluation revealed an acute fibrinoheterophilic polyarthrititis, and results of routine aerobic and anaerobic culture of joint fluid were negative, although *Mycoplasma* sp. sequence-specific polymerase chain reaction was positive. Amplification of a portion of the 16S rRNA and subsequent phylogenetic analysis of the amplicon identified *Mycoplasma corogypsi*. This is the first report of polyarthrititis being diagnosed in association with a *Mycoplasma* sp. in a vulture species. However, fulfilling Koch's postulates through experimental infections is required to draw conclusions concerning an etiologic diagnosis.

Key words: Black Vulture, *Coragyps atratus*, lead toxicosis, *Mycoplasma corogypsi*, polyarthrititis, polymerase chain reaction, Virginia.

Infectious polyarthrititis of free-ranging wild birds has been infrequently reported in the literature, although it is well-documented in the poultry industry. *Mycoplasma synoviae* is a well-known pathogen of domestic poultry, causing upper respiratory tract infections and infectious synovitis, often affecting multiple joints and tendon sheaths (Kleven, 2003). *Mycoplasma* species have been identified in association with polyarthrititis in multiple domestic avian and mammalian hosts; however, not in wild birds (Walker, 2004).

Little is known regarding the occurrence, pathogenicity, and distribution of

mycoplasmas in free-living raptors, although many *Mycoplasma* species have been isolated. Some of these isolations were from asymptomatic birds, whereas a few have been associated with clinical signs and the majority of these disease-associated cases manifest clinically as respiratory disease. Among vultures, isolation of mycoplasmas have been most frequently reported in Old World species. *Mycoplasma gypis* was isolated from a Eurasian Griffon (*Gyps fulvus*) with respiratory disease (Poveda et al., 1994). *Mycoplasma gallinarum* has been isolated from the upper respiratory tract of this species (Loria et al., 2008), and several other unidentified mycoplasmas have been cultured from Eurasian Griffons in Europe (Poveda et al., 1990a, b; Loria et al., 2008). *Mycoplasma vulturii* was isolated from pooled lung and spleen samples from an Oriental White-backed Vulture (*Gyps bengalensis*) that died from apparent diclofenac intoxication (Oaks et al., 2004). A Cinereous Vulture (*Aegypius monachus*) with histopathologic inflammatory change in the upper respiratory tract had *M. gallinarum* isolated from a tracheal swab (Poveda et al., 1990b).

Reports of mycoplasmas from New World vultures has been limited to *Mycoplasma corogypsi*, which was first isolated and characterized from a footpad abscess found on a free-living Black Vulture (*Coragyps atratus*) in Alabama, USA (Panangala et al., 1993). *Mycoplasma corogypsi* has also been cultured from

the trachea of asymptomatic captive Peregrine Falcons (*Falco peregrinus*), Saker Falcons (*Falco cherrug*), and gyr-saker hybrids in the Middle East (Lierz et al., 2002). Here, we report a polyarthritis associated with *M. corogypsi* in a free-living Black Vulture in Virginia.

On 10 October 2007, a Black Vulture was captured in Waynesboro, Virginia (38°4'N, 78°53'W) after being observed unable to fly and was transported to the Wildlife Center of Virginia. The bird weighed 1.45 kg; was severely lame, emaciated, and lethargic; had dull mentation; and suffered from severe ectoparasitism. Warm, fluctuant swellings were observed at the left carpal joint, left hock joint, and right tarsal joint.

The bird was anesthetized for diagnostic evaluation. Whole blood was collected for a complete blood count (CBC), serum biochemistry, and lead analysis. The serum biochemistry was unremarkable, whereas the CBC revealed a severe anemia (packed cell volume of 19) and a moderate leukocytosis (30,540 cells/ μ l), characterized by a heterophilia and monocytosis. Whole blood lead levels were 3.1 ppm, indicating lead toxicosis (Minnesota Veterinary Diagnostic Laboratory, St. Paul, Minnesota, USA). Aseptic arthrocentesis was performed on the left hock joint. Approximately 2 ml of cream-colored viscous material was removed from the joint and submitted for aerobic and anaerobic bacterial culture, both of which exhibited no growth. A *Mycoplasma* sp. was detected in the joint exudate by sequence specific polymerase chain reaction (PCR) using methods described previously (Feldman et al., 2006). Whole-body radiographs showed severe osteolytic change in the affected joints, and the bird was subsequently euthanized and necropsied the same day.

Gross examination at necropsy revealed the three abscessed joints distended with viscous, cream-colored liquid and occasional solid, pale yellow, friable masses (Fig. 1). The associated fibrous joint capsules and synovial membranes were

thickened, and associated tendon sheaths were also involved. A solitary 0.5-cm granuloma was discovered in the pulmonary parenchyma, and moderate splenomegaly was present. Formalin-fixed samples of spleen, kidney, testis, adrenal gland, brain, heart, skeletal muscle, lung, ventriculus, proventriculus, small intestine, large intestine, and hock joint were examined histopathologically. Sections of the fixed tissues were embedded in paraffin, sectioned at 4 μ m, and stained with hematoxylin and eosin. In addition, selected tissues were stained with acid-fast bacillus (AFB) stain, Gomori methylene silver (GMS) stain, Gram stain, and Congo red stain. A paraffin-embedded slide of the affected carpal joint was stained with Hoechst 33258 and Giemsa stains.

Abundant heterophilic debris and fibrin were adherent to the synovial membrane of the hock joint. The subsynovial connective tissue was multifocally infiltrated by numerous viable heterophils with fewer macrophages (Fig. 2). These findings were consistent with marked, acute fibrinoheterophilic arthritis. A focally extensive heterophilic bronchitis and prominent lymphoid hyperplasia of the bronchus-associated lymphoid tissue was noted in the lungs. The remainder of the lung tissue was within normal limits. A moderate splenic amyloidosis was present, consistent with chronic inflammation. The remaining submitted tissues, including the kidneys, revealed no significant histopathologic findings. Infectious agents were not detected in the spleen or any of the inflammatory lesions when evaluated with AFB stain, GMS stain, or Gram stain. Hoechst stain of the left carpal joint revealed multiple, small, distinct foci of nucleic acid present along the synovium (Fig. 3).

Phylogenetic analyses of partial 16S rRNA gene sequence (446 nucleotides) were performed. A basic alignment sequence tool (BLAST) search of the National Institutes of Health GenBank identified similarities to several 16S rRNA accessions

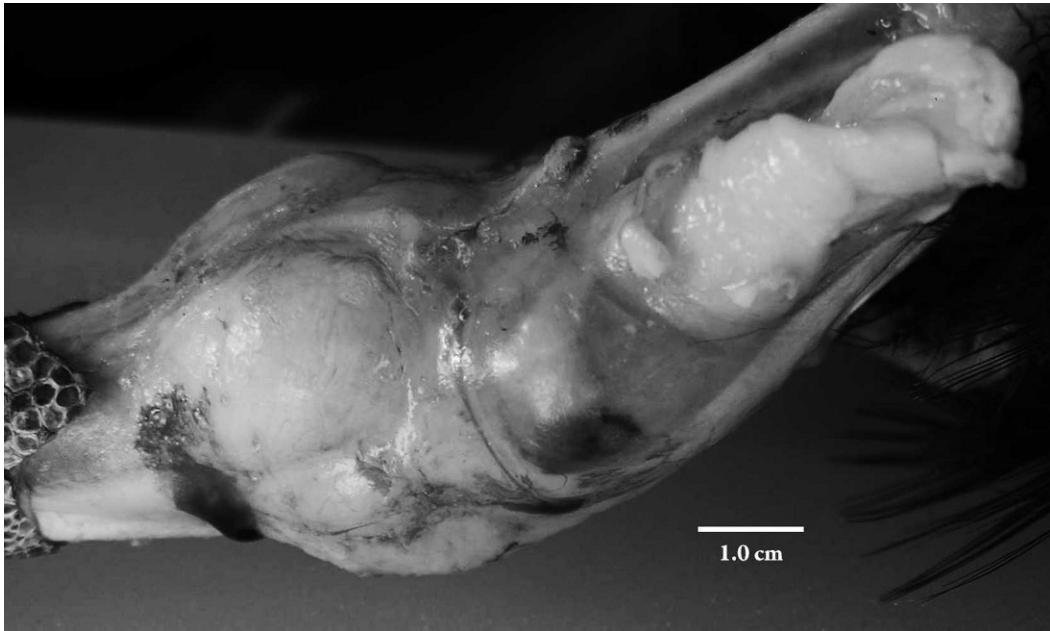


FIGURE 1. Lateral view of the left hock joint of a Black Vulture (*Coragyps atratus*) with polyarthritis during postmortem examination. Overlying skin has been reflected to reveal severe distension of the joint.

from *Mycoplasma* species. GenBank accessions used in the analyses were as follows: *Mycoplasma alderi* (U67943), *M. agalactiae* 1 (AF332749), *M. agalactiae* 2 (AF010477), *M. alligatoris* (U56733), *M. anatis* (AF412970), *M. bovirhinis* (U44766), *M. bovis* strain 120/81 (AF332756), *M. buteonis* (AF412971), *M. canis* 1 (AF340023), *M. canis* 2 (AF412972), *M. capricolum* (AF170102), *M. citreli* (AF412973), *M. columborale* (AF412975), *M. hyosynoviae* (U26730), *M. arthritidis* (M24580), *M. corogypsi* (L08054), *M. cricetuli* (EF036469), *M. crocodyli* (U63137), *M. gatae* (U15796), *M. cynos* 1 (AF412978), *M. cynos* 2 (AF538682), *M. edwardii* (U73903), *M. falconis* (AF125591), *M. felis* ATCC 23391 (U09787), *M. gallinaceum* (L24104), *M. gallinarum* (L24105), *M. gallisepticum* (M22441), *M. gallopavonis* 1 (AF064062), *M. gallopavonis* 2 (AF412980), *M. gateae* (U15796), *M. glycyphilum* (AF412981), *M. gypis* (AF125589), *M. leonicaptivi* (U16759), *M. meleagridis* (L24106), *M. mustelae* (AF412986), *M. opalescens* (AF538961), *M. oxoniensis*

(AF412987), *M. pullorum* (U58504), *M. species* 10T4 (AM182896), *M. species* 11CL2 (AM182893), *M. species* 39CL (AM182895), *M. species* 96430 (AF150495), *M. species* MS02 (DQ-223546), *M. species* (AJ000494), *M. spermatophilum* 1 (AF221119), *M. spermatophilum* 2 (AF013996), *M. sphenisci* (AY756171), *M. sturni* (U22013), *M. synoviae* (X52083), *M. vulturii* (AY191226), and *Escherichia coli* (AY776275). DNA sequences were aligned using ClustalX software (Thompson et al., 1997) and exported as both NEXUS and PHYLIP interleaved files. The GenBank sequences were truncated so that the 5' and 3' ends were coincident with the amplicon studied. Phylogenetic analysis was performed by two methods: Bayesian inference (Helsenbeck and Ronquist, 2001) and maximum-likelihood (Felsenstein, 1989; Fig. 4).

For Bayesian analysis, the following parameters were used: general time reversal model with gamma-distributed rate variation, 100,000 generations of split sampling every 100th generation with a

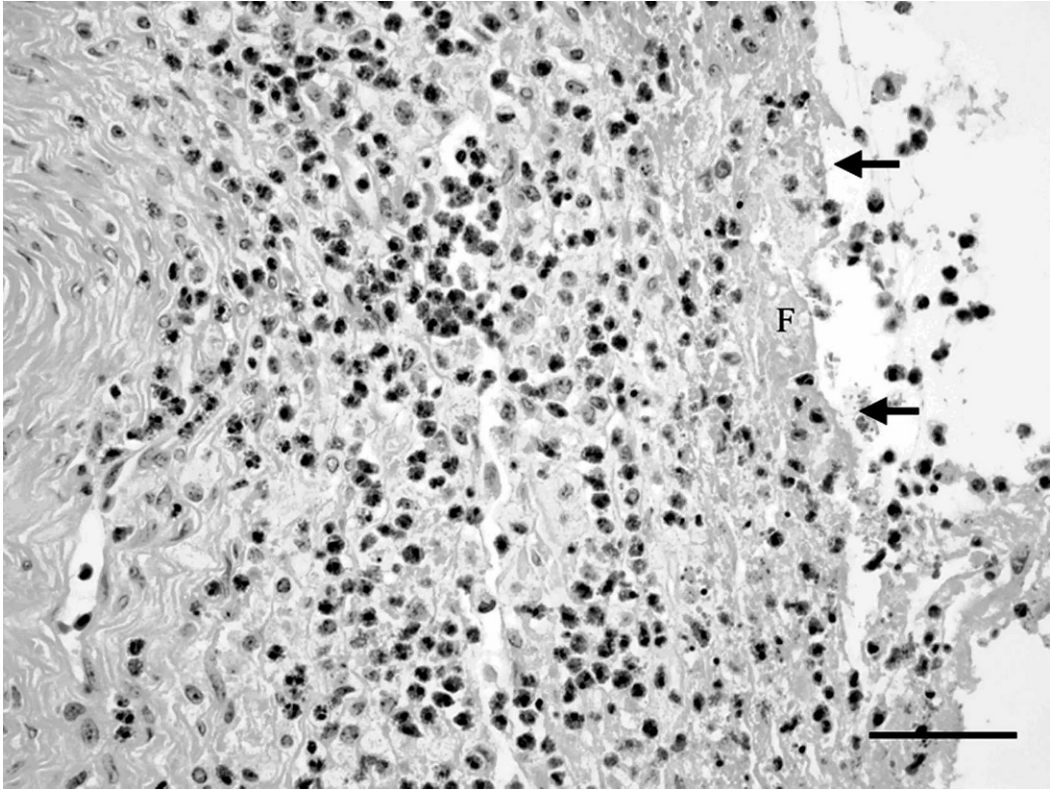


FIGURE 2. Photomicrograph of the left hock joint showing abundant heterophilic debris and fibrin (F) adherent to the synovial membrane and multifocal infiltration of the subsynovial connective tissue by numerous viable heterophils with fewer macrophages. The arrows indicate the luminal surface of the inflamed synovial membrane. Bar=200 μ m (hematoxylin and eosin).

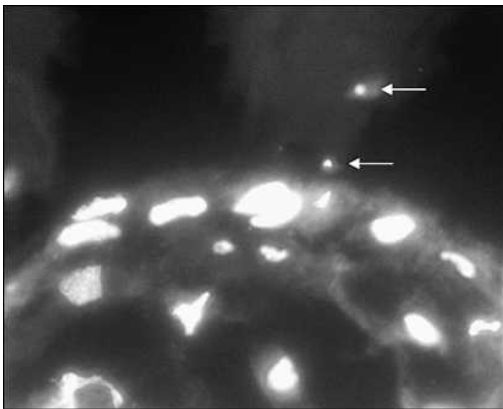


FIGURE 3. Photomicrograph of the left carpal joint using Hoechst 33258 stain revealed multiple, small, distinct foci of nucleic acid present along the synovium (arrows). 400 \times total magnification.

convergence diagnostic rejecting the first 25% of values. The analysis was terminated when stationarity was obtained by observing the log probability plot vs. generation. For maximum-likelihood analysis using the PHYLIP inference software, 100 data sets were generated using SEQBOOT, and bootstrap analysis was performed jumbling input sequence order three times, using global rearrangement of sequences and the analysis set to slow and exact. The consensus phylogram was determined using CONSENSE. Phylograms generated by both methods were not time constrained, were rooted using *E. coli* as the outgroup and then displayed using TREEVIEW (Page, 1996). Regarding the maximum-likelihood analysis, results were similar to those delineated by Bayesian inference, but there were fewer

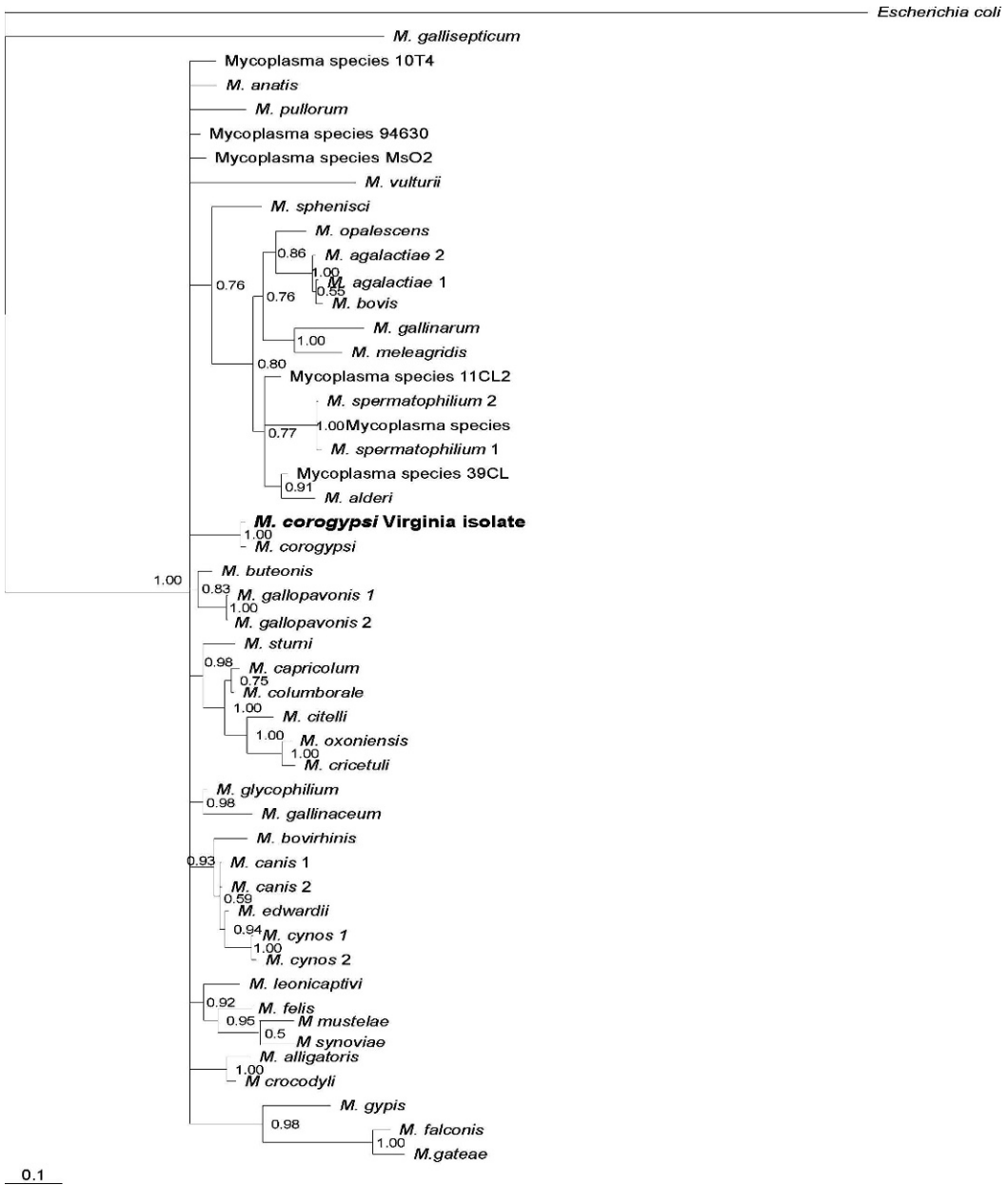


FIGURE 4. Phylogram comparing known pathogenic *Mycoplasma* spp. with the 16S rRNA sequence of the *Mycoplasma corogypsi* isolated from the synovial fluid of a Black Vulture (*Coragyps atratus*) with polyarthritis using Bayesian inference.

terminal branches that were statistically significant. Bayesian inference gave more detailed information about relatedness amongst species, as shown in Figure 4. Bayesian inference retained branchpoints (nodes) that had at least 50% posterior probability.

Conclusive evidence that *M. corogypsi* is a pathogen of Black Vultures causing polyarthritis would require controlled laboratory studies; however, the results of our diagnostic evaluation are suggestive of an association between the presence of this bacterium in the synovial compartment and

the development of septic arthritis. No growth was observed on aerobic or anaerobic culture of synovial fluid from an affected joint; moreover, no microorganisms were seen on histopathologic examination of this joint using AFB stain, GMS-stain, and Gram stain. DNA was isolated from a synovial fluid aspirate when subjected to a generic mycoplasma PCR amplification and yielded a 446-base pair amplicon, indicating the presence of *Mycoplasma* DNA. The degenerate primer sequences were derived from alignments of several mycoplasmas, ureaplasmas, and acholeplasmas and are as follows: forward 5'-GYR-AAYGGGTGACTAACACG and reverse 5'-CCTATGTATTACCGCGRCTG, where Y=C or T and R=A or G. The PCR reaction conditions were 95 C for 14 min 30 sec hotstart; 35 iterations of 95 C for 30 sec, 58 C for 30 sec, and 72 C for 1 min; and 72 C for 5 min final extension. The 25- μ l reaction contained 2 mM MgCl₂, Hot-Star *Taq* polymerase (QIAGEN, Valencia, California, USA), 0.5 μ M each degenerate primer, and 100 ng of specimen DNA. The sequence was determined for the amplicon (Fig. 5) and was submitted for a basic sequence alignment tool (BLAST) search of the GenBank database and returned a near perfect match (two nucleotide mismatches) with *M. corogypsi*. Although not definitive, the results of the Hoechst stain of the left carpus suggested that there was synovial membrane-associated foreign genetic material within the joint. These foci may have represented mycoplasmal DNA; however, it is possible that this staining represented fragmented heterophil nuclei or other DNA contaminants.

The co-occurrence of synovitis/arthritis, pneumonia, and splenic amyloidosis seems to be compatible with a *Mycoplasma* infection. The lymphoid hyperplasia of the bronchus-associated lymphoid tissue can be interpreted as a classic lesion of mycoplasmosis, although *Mycoplasma* sp. PCR was not performed on the pulmonary lesion. Splenic amyloidosis is evidence of chronic inflammation and can occasionally

be seen in mycoplasmosis of poultry with certain strains of *M. synoviae* (Landman and Feberwee, 2001). The histologic appearance of the arthritic change in the Black Vulture in this case was acute, rather than chronic, whereas most articular changes in poultry with *M. synoviae* infection are classically chronic lesions. Specifically, lymphoplasmacytic synovial infiltration, villous synovial hypertrophy, and hypertrophy/hyperplasia of the synovial lining cells have been described in classic mycoplasmal-induced synovitis. None of these findings of chronicity were detected in the examined section of the joint.

Pathogenic mycoplasmas preferentially colonize the mucosa of the respiratory and genital tracts and often establish persistent, superficial infections (Rosenbusch, 1994). Systemic infection and articular involvement can follow this mucosal colonization, especially in immunocompromised hosts (Rosenbusch, 1994). In this case, the concurrent findings of polyarthritis, poor body condition, severe ectoparasitism, and lead toxicosis were interesting, because all indicate a large burden on the immune system. As with all of the pathogenic avian mycoplasmas, the severity of the clinical syndrome may depend on many environmental, agent, and host factors, which makes interpretation of potential predisposing factors in this case difficult (Kleven, 1994).

The role of lead toxicosis, if any, in the poor condition of this bird and in the development of polyarthritis is unknown. Lead ions have a strong affinity for many biochemically reactive compounds and are able to inhibit enzymes involved in major metabolic pathways in many body systems (Locke and Thomas, 1996). Although lead-induced effects on the immune system have not been studied in Black Vultures, there is substantial evidence regarding the negative impacts of lead on immune system function in numerous vertebrate species, as reviewed by Dietert and Piepenbrink (2006). However, there is also evidence that certain species of

<i>M. corogypsi</i> VA isolate	GCGAATGGGTGAGTAACACGTACTTAACATGCCTTTTCAGATTGGGATAACGCTGAGAAAT GTGAATGGGTGAGTAACACGTACTTAACATGCCTTTTCAGATTGGGATAACGCTGAGAAAT * ****
<i>M. corogypsi</i> VA isolate	TAGCGCTAATACCGGATACTTATATTTATCGCATGATAGATATATAAAAGGGGGGTTTC TAGCGCTAATACCGAATACTTATATTTATCGCATGATAGATATATAAAAGGGGGG-TTTC *****
<i>M. corogypsi</i> VA isolate	CCTCACTGGAAGATTGGGGTGCGTAACATTAGCTAGTTGGTAAGGTAATGGCTTACCAAG CCTCACTGGAAGATTGGGGTGCGTAACATTAGCTAGTTGGTAAGGTAATGGCTTACCAAG *****
<i>M. corogypsi</i> VA isolate	GCGATGATGTTTAGCGGGGTTGAGAGACTGATCCGCCATACTGGGACTGAGATACGGCCC GCGATGATGTTTAGCGGGGTTGAGAGACTGATCCGCCACACTGGGACTGAGATACGGCCC *****
<i>M. corogypsi</i> VA isolate	AGACTCCTACGGGAGGCAGCAGTAGGGAATTTCCACAATGGGCGAAAGCCTGATGGAGC AGACTCCTACGGGAGGCAGCAGTAGGGAATTTCCACAATGGGCGAAAGCCTGATGGAGC *****
<i>M. corogypsi</i> VA isolate	GACACAGCGTGCAGGAGGAAGGCCTTCGGGTTGTAACTGCTGTTATAAGGGAAGAAAAA GACACAGCGTGCAGGAGGAAGGCCTTCGGGTTGTAACTGCTGTTATAAGGGAAGAAAAA *****
<i>M. corogypsi</i> VA isolate	GTAGGTTAGGAAATGAACCTTACCTTGACGGTACCTTGTCAGAAAGCAACGGCTAACTATG GTAGGTTAGGAAATGAACCTTACCTTGACGGTACCTTGTCAGAAAGCAACGGCTAACTATG *****
<i>M. corogypsi</i> VA isolate	TGCCAGCAGCCGCGGTAATACATAGG TGCCAGCAGCCGCGGTAATACATAGG *****

FIGURE 5. ClustalX alignment of the 446-base pair amplicon consensus nucleotide sequence from the Virginia isolate and *M. corogypsi* (GenBank accession L08054) is provided. In comparing the two sequences, there are three nucleotide transitions (G→A, C→T, and T→C) and one nucleotide deletion so that the two sequences share 99.1% identity (*=sequence nucleotide agreement).

vultures tolerate lead exposure to a greater extent than other raptors. Carpenter et al. (2003) found that Turkey Vultures (*Cathartes aura*) may be able to tolerate substantial burdens of lead before overt clinical signs or death occurred, although the controlled study did not examine subtle changes in immune system function. It was not possible to determine whether the bird in this case suffered from lead toxicosis before the manifestation of polyarthritis. Thus, no associations can be made; however, the concomitant findings and the poor overall condition of the bird was interesting.

From 2000 to 2008, six Black Vultures presented to the Wildlife Center of Virginia with arthritis of one or more joints, similar in character to the vulture in this case.

Aerobic and anaerobic cultures were performed on three of these cases, all of which exhibited no growth. Furthermore, the arthritis in these three cases resolved with joint lavage and oral enrofloxacin, a drug that shows good efficacy against most mycoplasmas. *Mycoplasma* PCR was not performed in any of these previous cases; however, the similar clinical presentation and response to quinolone therapy is interesting. Conclusive statements regarding the role of *M. corogypsi* as a pathogen of Black Vultures are difficult to make, because this is only the second report of this organism associated with this species (Panangala et al., 1993). Thus, whether *M. corogypsi* is a primary or opportunistic pathogen in free-living Black Vulture populations is unknown.

Future research needs to fulfill Koch's postulates regarding the possible role of *M. corogypsi* as a primary pathogen of Black Vultures and to analyze the epidemiologic importance in free-living populations. Detection of *M. corogypsi* via culture or PCR in samples from asymptomatic Black Vultures obtained by arthrocentesis, tracheal swabs, and air sac biopsies will further the understanding as to whether *M. corogypsi* is an opportunistic commensal organism or a primary pathogen (Lierz et al., 2000).

This case is the first report of a *Mycoplasma* species being found in association with polyarthritis in any species of Old or New World vulture. Furthermore, it represents the first detailed phylogenetic analysis of *M. corogypsi* since the characterization by Panangala et al. (1993).

LITERATURE CITED

- CARPENTER, J. W., O. W. PATTEE, S. H. FRITTS, B. A. RATTNER, S. N. WIEMEYER, J. A. ROYLE, AND M. R. SMITH. 2003. Experimental lead poisoning in turkey vultures (*Cathartes aura*). *Journal of Wildlife Diseases* 39: 96–104.
- DIETART, R. R., AND M. S. PIEPENBRINK. 2006. Lead and immune function. *Critical Reviews in Toxicology* 36: 359–385.
- FELDMAN, S. H., J. WIMSATT, R. E. MARCHANG, A. J. JOHNSON, W. BROWN, J. C. MITCHELL, AND J. M. SLEEMAN. 2006. A novel *Mycoplasma* detected in association with upper respiratory disease syndrome in free-ranging eastern box turtles (*Terrapene carolina carolina*) in Virginia. *Journal of Wildlife Diseases* 42: 279–289.
- FELSENSTEIN, J. 1989. PHYLIP—phylogeny inference package (version 3.2). *Cladistics* 5: 164–166.
- HUELSENBECK, J. P., AND F. RONQUIST. 2001. MRBAYES: Bayesian inference of phylogeny. *Bioinformatics* 17: 754–755.
- KLEVEN, S. H. 1994. Avian mycoplasmas. In *Mycoplasmosis in animals: Laboratory diagnosis*, H. W. Whitford, R. F. Rosenbusch and L. H. Lauerma (eds.). Iowa State University Press, Ames, Iowa, pp. 31–38.
- . 2003. *Mycoplasma synoviae* infection. In *Diseases of poultry*, H. J. Barnes, A. M. Fadly, J. R. Glisson, L. R. McDougald and D. E. Swayne (eds.). Blackwell Publishing, Ames, Iowa, pp. 756–766.
- LANDMAN, J. M., AND A. FEBERWEE. 2001. Field studies on the association between amyloid arthropathy and *Mycoplasma synoviae* infection, and experimental reproduction of the condition in brown layers. *Avian Pathology* 30: 629–639.
- LIERZ, M., R. SCHMIDT, T. GOEBEL, J. EHRLIN, AND M. RUNGE. 2000. Detection of *Mycoplasma* spp. in raptorial birds in Germany. In *Raptor biomedicine III*, J. T. Lumeij, J. D. Remple, P. T. Redig, M. Lierz and J. E. Cooper (eds.). Zoological Education Network, Inc., Lake Worth, Florida, pp. 25–33.
- , ———, AND M. RUNGE. 2002. *Mycoplasma* species isolated from falcons in the Middle East. *Veterinary Record* 151: 92–93.
- LOCKE, L. N., AND N. J. THOMAS. 1996. Lead poisoning of waterfowl and raptors. In *Noninfectious diseases of wildlife*, A. Fairbrother, L. N. Locke and G. L. Hoff (eds.). Iowa State University Press, Ames, Iowa, pp. 108–117.
- LORIA, G. R., E. FERRANTELLI, G. GIARDINA, L. LI VECCHI, L. SPARACINO, F. OLIVERI, L. MCAULIFFE, AND R. A. NICHOLAS. 2008. Isolation and characterization of unusual *Mycoplasma* spp. from captive Eurasian griffon (*Gyps fulvus*) in Sicily. *Journal of Wildlife Diseases* 44: 159–163.
- OAKS, J. L., S. L. DONAHOE, F. R. RURANGIRWA, B. A. RIDEOUT, M. GILBERT, AND M. Z. VIRANI. 2004. Identification of a novel *Mycoplasma* species from an Oriental white-backed vulture (*Gyps bengalensis*). *Journal of Clinical Microbiology* 42: 5909–5912.
- PAGE, R. D. M. 1996. TREEVIEW: An application to display phylogenetic trees on personal computers. *Computer Applications in the Biosciences* 12: 357–358.
- POVEDA, J. B., J. CARRANZA, A. MIRANDA, A. GABRIDO, M. HERMOSO, A. FERNANDEZ, AND J. DOMENECH. 1990a. An epizootiological study of avian mycoplasmas in southern Spain. *Avian Pathology* 19: 627–633.
- , J. GIEBEL, H. KIRCHHOFF, AND A. FERNANDEZ. 1990b. Isolation of mycoplasmas from a buzzard, falcons and vultures. *Avian Pathology* 19: 779–783.
- , ———, J. GIEBEL, J. FLOSSDORF, J. MEIER, AND H. KIRCHHOFF. 1994. *Mycoplasma buteonis* sp. nov., *Mycoplasma falconis* sp. nov., and *Mycoplasma gypis* sp. nov., three species from birds of prey. *International Journal of Systematic Bacteriology* 44: 94–98.
- PANANGALA, V. S., J. S. STINGFELLOW, K. DYBVIC, A. WOODARD, F. SUN, D. L. ROSE, AND M. M. GRESHAM. 1993. *Mycoplasma corogypsi* sp. nov., a new species from the footpad abscess of a black vulture, *Coragyps atratus*. *International Journal of Systematic Bacteriology* 43: 585–590.
- ROSENBUSCH, R. F. 1994. Biology and taxonomy of the mycoplasmas. In *Mycoplasmosis in animals: Laboratory diagnosis*, H. W. Whitford, R. F. Rosenbusch and L. H. Lauerma (eds.). Iowa State University Press, Ames, Iowa, pp. 3–11.

- THOMPSON, J. D., T. J. GIBSON, F. PLEWNIAK, F. JEANMOUGIN, AND D. G. HIGGINS. 1997. The ClustalX windows interface: Flexible strategies for multiple sequence alignment aided by quality analysis tools. *Nucleic Acids Research* 24: 4876–4882.
- WALKER, R. L. 2004. Mollicutes. *In* *Veterinary microbiology*, D. C. Hirsh, N. J. MacLachlan and R. L. Walker (eds.). Blackwell Publishing, Ames, Iowa, pp. 240–249.

Received for publication 8 July 2008.