

SEVERE SPARGANOSIS IN AUSTRALIAN TREE FROGS

Authors: Berger, Lee, Skerratt, Lee F., Zhu, Xing-Quan, Young, Sam, and Speare, Rick

Source: Journal of Wildlife Diseases, 45(4) : 921-929

Published By: Wildlife Disease Association

URL: <https://doi.org/10.7589/0090-3558-45.4.921>

BioOne Complete (complete.BioOne.org) is a full-text database of 200 subscribed and open-access titles in the biological, ecological, and environmental sciences published by nonprofit societies, associations, museums, institutions, and presses.

Your use of this PDF, the BioOne Complete website, and all posted and associated content indicates your acceptance of BioOne's Terms of Use, available at www.bioone.org/terms-of-use.

Usage of BioOne Complete content is strictly limited to personal, educational, and non - commercial use. Commercial inquiries or rights and permissions requests should be directed to the individual publisher as copyright holder.

BioOne sees sustainable scholarly publishing as an inherently collaborative enterprise connecting authors, nonprofit publishers, academic institutions, research libraries, and research funders in the common goal of maximizing access to critical research.

SEVERE SPARGANOSIS IN AUSTRALIAN TREE FROGS

Lee Berger,^{1,3} Lee F. Skerratt,¹ Xing-Quan Zhu,² Sam Young,¹ and Rick Speare¹

¹ Amphibian Disease Ecology Group, School of Public Health, Tropical Medicine and Rehabilitation Sciences, James Cook University, Townsville, Queensland 4811, Australia

² Department of Parasitology, College of Veterinary Medicine, South China Agricultural University, Guangzhou, Guangdong Province 510642, The People's Republic of China

³ Corresponding author (email: lee.berger@jcu.edu.au)

ABSTRACT: Spargana of *Spirometra erinacei* infect many vertebrate species, but severe disease from sparganosis has been reported from few host species. Information on the effects of this common, introduced tapeworm of cats on Australian frogs is lacking. Our survey to detect significant diseases in free-ranging amphibians in eastern Australia between 1993 and 2000 revealed that infection with spargana (plerocercoids) of *S. erinacei* occurred in 12/243 (4.9%) sick frogs. Infections occurred in skeletal muscle and subcutis, especially the thighs, of large adults of *Litoria caerulea*, *Litoria aurea*, *Litoria gracilentia*, and *Litoria peronii*. Three frogs were also infected in the coelomic cavity. Heavy burdens in seven frogs were associated with poor body condition and debilitating lesions, whereas lighter infections in five sick frogs were considered likely to be incidental to other diseases. In severe infections, a large proportion of thigh muscle was replaced with spargana and various amounts of fibrosis, and some frogs also had myonecrosis, granulomatous inflammation, hemorrhage, and skin ulceration. Concurrent infections were common. Our findings suggest sparganosis is one of a few currently recognized serious diseases affecting free-ranging frogs in Australia.

Key words: Amphibian, cestode, *Litoria*, *Ophidascaris pyrrhus*, parasite, pathology, spargana, *Spirometra erinacei*.

INTRODUCTION

The adult stage of the cestode *Spirometra erinacei* inhabits the small intestine of carnivores such as the cat, dog, fox, and dingo (Bowman et al., 2002). The proceroid stage occurs in copepods, and the plerocercoid stage (spargana) is found in amphibians, reptiles, and mammals that ingest infected copepods or other vertebrates infected with spargana. Tadpoles are an important host that can transmit spargana to other intermediate hosts (Sandars, 1953). *Spirometra erinacei* was probably introduced recently to Australia, given that eutherian carnivores are the definitive hosts, and it is the most prevalent helminth of feral cats in eastern Australia (Dickman, 1996). Along with the protozoan *Toxoplasma gondii*, *S. erinacei* is considered an important cat-vectoring pathogen that warrants further study to understand its current impact on native wildlife (Dickman, 1996).

Spirometra erinacei is also present in southeast Asia and is a public health problem, usually occurring as subcutane-

ous or intramuscular sparganosis in humans (Mastura et al., 1996). Routes of infection include ingestion of incompletely cooked tadpoles and frogs, drinking water contaminated with infected copepods, and through using infected frog flesh as a poultice (Mastura et al., 1996).

There are a few reports of severe disease from sparganosis in Australian vertebrates. Infections in Australian snakes occur in subcutaneous areas, intercostal muscles, or the coelomic cavity. Heavy infections can cause inappetence and weight loss, and are treated by surgical removal and antibiotics (McCracken, 1994). Marsupials and monotremes may be infected with *S. erinacei*, and disease has been reported in echidnas, antechinus, and northern quolls (Beveridge, 1978; Whittington et al., 1992; Oakwood and Spratt, 2000). Proliferative sparganosis has caused severe disease in domestic dogs (Beveridge et al., 1998).

Subclinical *S. erinacei* infections have been reported in free-ranging amphibians examined by necropsy. In a recent survey of Australian amphibians, spargana were found in 10/875 (1%) *Bufo marinus*, 2/6 (33%)

Litoria peronii, 1/15 (7%) *Litoria caerulea*, and 7/163 (6%) *Litoria inermis* (Diane Barton, unpubl.). Of 1,000 *B. marinus* surveyed from Ingham, Queensland, 37 (3.7%) were found with infections (Bennett, 1978). Spargana have also been reported in wild adults of *Litoria aurea*, *Litoria nasuta*, and *Litoria rubella*, and experimental infections were produced in adults of *Litoria latopalmata* and *Limnodynastes tasmanienensis* and tadpoles of *L. latopalmata*, *L. caerulea*, and *Limnodynastes tasmaniensis* (Sandars, 1953; Bennett, 1978; Sastrawan, 1978; Barton, 1994). Sandars (1953) reports that about one quarter of the population of *L. caerulea* in the Brisbane area was infected with spargana. However, severe sparganosis and its pathology has not been described in amphibians.

In our survey of 243 sick and dead wild frogs from eastern Australia, spargana were found in 12 frogs from New South Wales and Queensland. Seven frogs had heavy infections that appeared to be causing clinical disease. Here we describe the pathology of severe sparganosis in amphibians with details of concurrent parasites and diseases.

MATERIALS AND METHODS

Between October 1993 and December 2000, 243 sick and dead wild amphibians collected opportunistically from eastern Australia were examined by necropsy. Dead frogs found by herpetologists were preserved in either 10% formalin or 70% ethanol or were frozen. Sick frogs were identified by their unusual behavior or by the presence of lesions (e.g., ulcers, lumps) and were either euthanized and preserved, or were sent by courier to the laboratory. Frogs were euthanized by bathing in 0.2% MS222 (tricaine methane sulphonate; Ruth Consolidated Industries, Annandale, New South Wales, Australia). Frogs received fresh were weighed. Parasites were collected and organs were placed in 10% buffered neutral formalin and prepared for histology. Small frogs (i.e., <15 mm) were not dissected, but were cut in half and sectioned for histology. Tissues were dehydrated, embedded in paraffin, sectioned at 6 μ m, and stained with hematoxylin and eosin or Gram's stain.

In frogs with sparganosis, parasite burden was estimated by reflecting the skin and

counting the number of spargana grossly visible in the subcutis and superficial muscles, then counting any that were free within the coelomic cavity. A total count of spargana infecting each frog was not attempted, as this would involve dissection or dissolution of all muscle bundles, which is incompatible with performing histopathology. Live spargana were relaxed in distilled water, then preserved in 70% ethanol or frozen at -80°C . As identification of spargana using morphologic features is unreliable, the identity of specimens was confirmed by DNA sequencing of part of the cytochrome *c* oxidase subunit 1 gene from five spargana from Cases 3, 7, and 8, and the results were reported in Zhu et al. (2002).

RESULTS

Spargana were found in 12/243 (4.9%) sick wild frogs. Infected frogs were collected between southern New South Wales and northern Queensland (Table 1). Proportions infected in positive species were 1/2 *Litoria gracilentia*, 1/12 *Litoria peronii*, 2/8 *L. aurea*, and 8/73 *L. caerulea*. These were relatively large individuals—the snout–vent lengths of the *L. caerulea* were about 100 mm (Table 1). Other diseases found in the frogs surveyed were described in Berger (2001) and Berger et al. (2004).

Spargana appeared as white flattened flexible structures with transverse wrinkles. They were approximately 3 mm in width, 1 mm thick, and of variable length, up to about 50 mm when removed from the host tissue. Histologically they had features typical of cestodes, including calcareous corpuscles, a thick cuticle, and no digestive tract.

All infected frogs had spargana in the muscle and subcutis of the thighs (Figs. 1–3), and nine were infected in additional locations such as subcutis and muscle of the ventral abdomen (eight frogs), dorsal subcutis especially around the urostyle (seven frogs), lumbar musculature (three frogs), coelomic cavity (three frogs), and muscle and subcutis of the forelimbs (two frogs; Table 1). Worms were curled within fibrous capsules or thin membranes, or

occurred free in body spaces or between muscle fibers.

Four frogs diagnosed with other severe diseases as the major cause of illness had between three and seven spargana visible, which were considered incidental findings (Cases 1–4). One frog (Case 5) had an intermediate burden of at least 11 spargana, which was of uncertain significance to the frog's morbidity. In two of the three frogs where spargana were found histologically, there was a moderate granulomatous response and in one of these the spargana were degenerate.

Seven frogs had heavy infections with over 16 spargana each in sites easily visible at the gross examination (Cases 6–12). In these frogs, the severe sparganosis appeared to be the primary cause of illness based on the associated pathology and intensity of infection, although many had coinfections. In early stages of disease, the main clinical signs were behavioral changes, with frogs typically remaining stationary and in the same unprotected site for about a week. As the disease advanced frogs became moribund. Six frogs were in poor body condition or were emaciated, with negligible fat bodies. Subcutaneous lumps over thighs and caudal belly were readily observed in most cases. Three frogs had dermal ulcers associated with spargana in underlying skeletal muscles. Histologic examination revealed spargana encapsulated within thin, membranous capsules or thicker fibrotic capsules. Unencapsulated spargana occurred free between muscle fibers, in subcutaneous spaces, and in the coelomic cavity. In many frogs, there was negligible cellular reaction (Fig. 4), although in three frogs there was granulomatous inflammation within capsules and in interstitial areas of muscle. Inflammation that was present in the muscle of some frogs appeared to be stimulated by the presence of opportunistic bacterial or protozoal infections. Coagulative necrosis of individual muscle fibers or more extensive myonecrosis occurred in three frogs. In heavily infected frogs,

spargana replaced muscle fibers, which appeared to have dissolved.

Sequencing of the cytochrome *c* oxidase genes of spargana from three frogs (from Queensland and New South Wales) confirmed they were *S. erinacei* but they differed at 2% of nucleotide positions from *S. erinacei* found in dogs, foxes, cats, and a tiger snake from Victoria, and from a python from Queensland (Zhu et al., 2002).

DISCUSSION

Spirometra erinacei is the only species of pseudophyllidean cestode known to occur in Australia, and was confirmed in these frogs by polymerase chain reaction (PCR; Zhu et al., 2002). The different genotype found in the frogs may reflect the limited and geographically scattered sampling, rather than indicating a distinct frog genotype with a novel definitive host. As infected frogs came mostly from populated areas, the source may be a domestic animal or fox. This report of *S. erinacei* in an adult of *L. gracilentia* is a new host record.

For the 10 frogs in which spargana were examined histologically, infection was usually associated with fibrosis, but a cellular reaction was observed in only five frogs. Degenerate spargana were rarely seen, contrasting with an earlier survey in Australian cane toads (*B. marinus*) in which a marked inflammatory response resulted in degeneration of most encapsulated spargana (Bennett, 1978). As cane toads, which inhabit Central and South America, were introduced to Australia, perhaps they have better natural immunity than native frogs that were previously naïve. Immunodiffusion and immunoelectrophoretic tests in the toads revealed antibodies against components of the spargana (Bennett, 1978). We did not test antibodies in the frogs described here.

Proteases occur in the region of the tegument of spargana of *S. erinacei* which are thought to assist in penetration of the

TABLE 1. Summary of pathologic findings in Australian treefrogs with sparganosis.

Species, Accession No. ^a	Location	Date	Sex	Snout-vent length, weight	No. of superficial spargana observed	Sites of infection with spargana ^b	Pathology associated with spargana	Concurrent diseases and infections
1. <i>Litoria caerulea</i> , 96 961/11	Yamanto, Queensland; 27°39'S, 152°44'E	July 1996	F	126 mm	3	Thighs	Granulomatous foci in muscle and fibrous/ granulomatous capsules around spargana	Severe protistan encephalitis; <i>Myxi- dium</i> sp. in gall bladder
2. <i>Litoria caerulea</i> , 98 1469/5	Queensland (origin unknown)	November 1998	–	57 mm, 13 g	7	Thighs	Spargana not found on histology	Severe chytridiomycosis
3. <i>Litoria caerulea</i> , 98 1469/13	Tully, Queensland; 17°55'S, 145°55'E	November 1998	F	96 mm, 176 g	7	Thighs, urostyle	Spargana not found on histology	Ophthalmitis <i>Myxobolus hylae</i> in ovary
4. <i>Litoria aurea</i> , 00 782/11	Captains Flat, New South Wales; 35°34'S, 149°27'E	May 2000	F	52 mm	3	Thighs	Moderate granulomatous inflammation, degenerate spargana	Severe chytridiomycosis
5. <i>Litoria peronii</i> , 98 1469/11	Boambee, New South Wales; 30°19'S, 153°05'E	November 1998	F	82 mm, 59 g	11	Thighs, dorsum, ventral abdomen	Ventral and dorsal adhesions in subcutis	Mild chytridiomycosis
6. <i>Litoria aurea</i> , 98 320/14	Homebush, New South Wales; 33°50'S, 151°04'E	March 1998	F	66 mm, 25 g	35	Thighs, ventral abdomen, dorsum, lumbar muscles, coelomic cavity	Skin ulceration, thin and thick capsules, hemorrhage in dermis and muscle, severe myonecrosis, interstitial granulomatous inflammation	<i>Pleistophora</i> sp. in muscle; Septicemia— <i>Aeromonas sobria</i> , <i>Sphingobacterium spirillum</i> . Encysted nematodes in bladder
7. <i>Litoria caerulea</i> , 98 320/16	Emerald Beach, New South Wales; 30°09'S, 153°11'E	April 1998	M	122 mm, 154 g	16 (plus a heavy infection re- placed limb muscles)	Thighs, ventral abdomen, forearm	Adhesions to skin, thin and thick fibrous capsules, occasional foci of interstitial granulomatous inflammation, muscle loss	Small spleen; <i>Myxidium</i> sp. in gall bladder; protists in brain

TABLE 1. Continued.

Species, Accession No. ^a	Location	Date	Sex	Snout-vent length, weight	No. of superficial spargana observed	Sites of infection with spargana ^b	Pathology associated with spargana	Concurrent diseases and infections
8. <i>Litoria caerulea</i> , 98 871/28	Coffs Harbour, New South Wales; 30°18'S, 153°07'E	August 1998	M	94 mm, 95 g	41	Thighs, ventral abdomen, tarsus, dorsum	Skin ulceration, adhesions to abdominal skin, thin and thick capsules, mild hemorrhage in muscle, myonecrosis, necrotic granulomatous inflammation	Severe cholangiohepatitis due to larval spiruroids and gram+ve bacteria
9. <i>Litoria caerulea</i> , 98 871/29	Korora, New South Wales; 30°15'S, 153°08'E	August 1998	F	126 mm, 181 g	>60 spargana	Thighs, ventral abdomen, dorsum	Excessive subcutaneous fluid, adhesions to dermis, moderate fibrosis	<i>Ophidascaris pyrrhus</i> encysted on serosa of small intestine. Biliary fibrosis
10. <i>Litoria gracilentia</i> , 98 1159/2	Kallangur, Queensland; 27°15'S, 153°00'E	August 1998	F	57 mm	53	Thighs, ventral abdomen	Thin capsules, myodegeneration, muscle loss	Necrotic, shrunken lens. Immunosuppression—small, inactive spleen. <i>Mixidium</i> sp. in gall bladder, <i>Rhabdias</i> sp. in lungs
11. <i>Litoria caerulea</i> , 99 1562/22	Dysart, Queensland; 22°35'S, 148°20'E	September 1999	M	98 mm	23	Thighs, ventral abdomen, dorsum, lumbar muscle, caudal coelomic cavity	Skin ulceration, mild fibrosis, muscle loss	Chytridiomycosis
12. <i>Litoria caerulea</i> , 99 1562/23	Dysart, Queensland; 22°35'S, 148°20'E	August 1999	F	109 mm	40	Thighs, ventral abdomen, dorsum, forearms, lumbar muscle, caudal coelomic cavity	Moderate fibrosis, muscle loss	<i>Rhabdias</i> sp. in lungs

^a Accession numbers refer to cases deposited at the CSIRO Australian Animal Health Laboratory.

^b Spargana occurred within muscle and subcutis apart from those in the coelomic cavity.

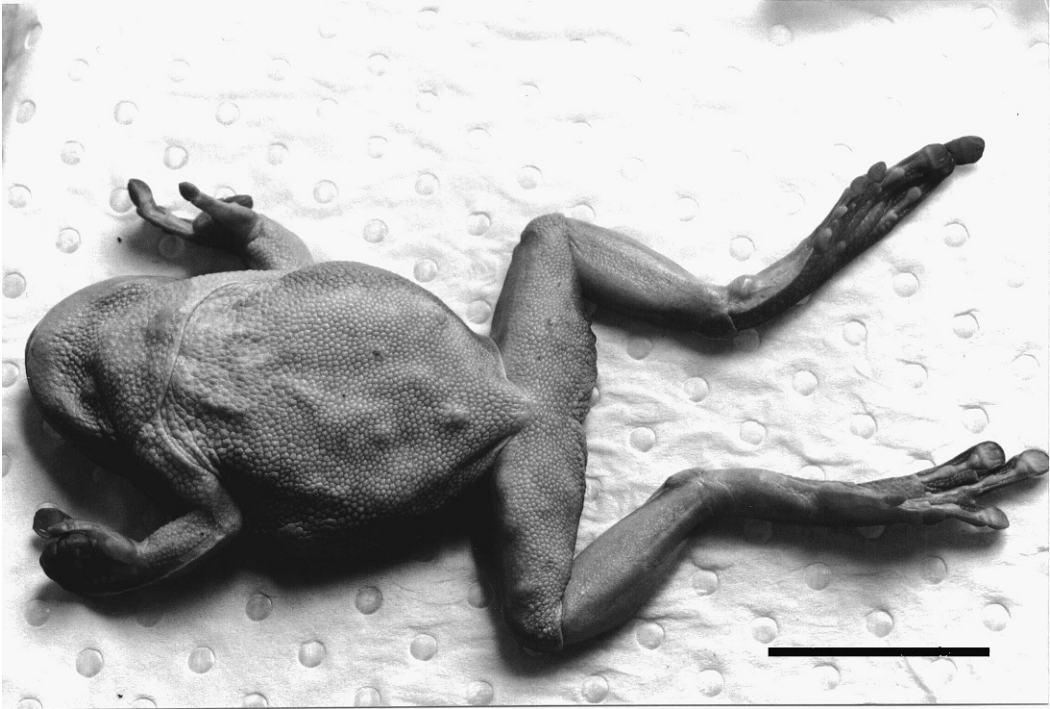

FIGURE 1. An adult of *Litoria caerulea* (Case 8) with subcutaneous lumps due to spargana on the ventral abdomen and thighs and on the left tarsus. Bar=30 mm.

intestinal wall of intermediate hosts (Kwa, 1972). These proteases may also help the spargana move through frog muscles and could contribute to pathogenesis.

Concurrent diseases in three of the severely infected frogs may have contributed to their illness, either as secondary or predisposing problems. The ophthalmitis

in the *L. gracilentia* (Case 10) may have interfered with its ability to catch prey. The nematode infections and bacterial hepatitis in the *L. caerulea* (Case 8) may have also been significant. The severe bacterial infection of the *L. aurea* (Case 6) appeared to be acute and was presumably secondary to the invasion of spargana.

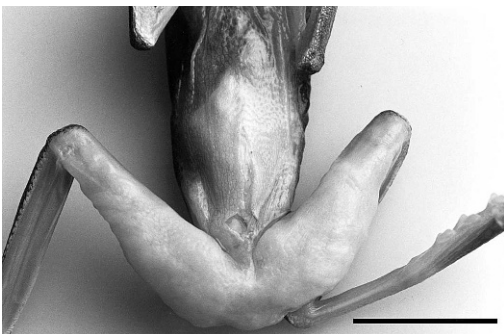


FIGURE 2. Ventral surface of a thin adult of *Litoria gracilentia* (Case 10) with massive enlargement of the thighs due to a heavy burden with spargana occurring free under the skin. Bar=12 mm.

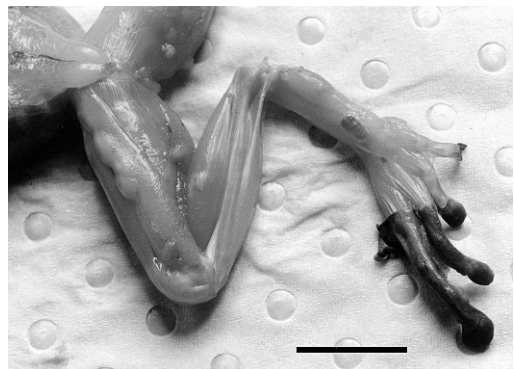


FIGURE 3. Ventral surface of the hind leg of an adult of *Litoria caerulea* (Case 8) with encysted spargana in the muscles. Bar=15 mm.

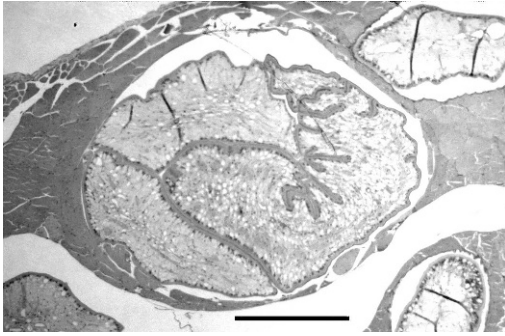


FIGURE 4. Histologic section of an encysted sparganum of *Spirometra erinacei* in the thigh muscle of a *Litoria aurea* (Case 6) without associated tissue reaction. The cestode appears to have replaced muscle mass and there is degeneration and dissolution of the adjacent muscle. HE stain. Bar=380 μ m.

Ophidascaris pyrrhus in the *L. caerulea* (Case 9) is a significant finding, as it is the first reported adult ascaridoid infection in an identified frog species (Barton, 1994; Sprent, 1988). This nematode undergoes extensive growth and development in subcutaneous tissues of lizards (the usual intermediate host), before being eaten by an elapid snake (the definitive host). It is possible that frogs are a significant intermediate host of *O. pyrrhus* in areas of high rainfall.

Heavy burdens in these mature, large frogs may have been a result of high levels of exposure to procercoids in water or to plerocercoids in smaller prey. Severe concurrent infections in three frogs (Cases 6, 8, and 10) could suggest immunosuppression secondary to another problem or high intensities of spargana may cause immune depression. In general, parasites are unevenly distributed between hosts, with most hosts harboring few or no parasites and a few hosts harboring many parasites. This phenomenon is known as overdispersion or aggregation (Poulin, 1998) and could be due to host differences, and to spatial and temporal changes in exposure. As almost all parasite populations fit this type of distribution; when heavily infected hosts are not found this is assumed to be due to parasite-induced

host mortality (Poulin, 1998). Only light infections with spargana were detected in previous surveys of healthy Australian frogs and 20 of 20 infected frogs had between one and seven worms in thigh muscles (Diane Barton, unpubl. data), whereas heavy infections were found in seven of 12 infected frogs when we targeted sick or dead animals. Frogs with heavy burdens were significantly more likely to be sick (lower 95% confidence limit=4, Fisher's exact test $P<0.001$). This supports our pathologic findings that spargana are pathogenic to free-ranging frogs.

Although the pathology of severe sparganosis had not previously been described in amphibians, there are some reports of detrimental effects. Experimental attempts to study the immune reactions in *L. tasmaniensis* failed due to inconsistent infection rates and frequent deaths of infected frogs and tadpoles, thought to be due to the combined stress of parasitism and captivity (Bennett, 1978). Growth of experimentally infected *L. latopalmata* tadpoles was inhibited (Sandars, 1953). In a survey of 948 Malaysian frogs, 11.8% were found infected with spargana, 57% of which had bleeding and/or swelling at infection sites (Mastura et al., 1996).

It is important to differentiate infection and clinical disease in frogs infected with *S. erinacei*. We consider that the severe infections in seven (58%) of the infected frogs caused debilitation of these animals. We suggest that the criteria used to classify sparganosis in frogs as severe include 1) significant clinical signs such as weakness, reluctance to move, loss of body condition, and debilitation; 2) evidence of significant local tissue damage seen as myonecrosis, granulomatous inflammation, hemorrhage, skin ulceration, and/or severe muscle loss and replacement with spargana and various amounts of fibrosis; and 3) sufficient spargana to cause debilitation. This last criterion is difficult to quantify and would vary with frog size; however, from our study a

burden with at least 16 obvious spargana clearly caused severe disease, and also perhaps the intermediate infection of 11 superficial spargana. In addition, frogs with severe sparganosis were more likely to be infected in numerous sites, rather than just the thighs. Transmission experiments are needed to characterize this disease and would provide a more accurate, and perhaps lower, estimate of minimum pathogenic burdens.

Although outbreaks of severe sparganosis were not found in this study, this was the second most common infectious disease found in amphibian populations in Australia, after chytridiomycosis (Berger, 2001). The impact of this disease on amphibian populations remains unknown. *Spirometra erinacei* has a broad host range and may potentially infect all anuran species. The presence of infection or definitive hosts in habitats of threatened species could require intervention. Examples of diseases that have been introduced with eutherians and had severe effects on Australian wildlife include toxoplasmosis (Dickman, 1996) and sarcoptic mange (Skerratt et al., 2004).

ACKNOWLEDGMENTS

For collection of sick frogs we are grateful to M. Christy, H. Hines, N. Sheppard, D. Page, G. Marantelli, K. McDonald, R. Pietsch, and P. Coupar. Many thanks to J. Sprent for identifying *Ophidascaris pyrrhus*, F. Mutschmann for identifying *Pleistophora* sp., and M. Braun for preparing histologic sections. This study was funded by the Australian Government Department of the Environment and Heritage.

LITERATURE CITED

- BARTON, D. 1994. A checklist of helminth parasites of Australian amphibia. Records of the South Australian Museum 27: 13–30.
- BENNETT, L. J. 1978. The immunological responses of amphibia to Australian spargana. Journal of Parasitology 64: 756–759.
- BERGER, L. 2001. Diseases in Australian frogs. PhD Thesis, James Cook University, Townsville, Queensland, Australia, 350 pp.
- , R. SPEARE, H. HINES, G. MARANTELLI, A. D. HYATT, K. R. McDONALD, L. F. SKERRATT, V. OLSEN, J. M. CLARKE, G. GILLESPIE, M. MAHONY, N. SHEPPARD, C. WILLIAMS, AND M. TYLER. 2004. Effect of season and temperature on mortality in amphibians due to chytridiomycosis. Australian Veterinary Journal 82: 31–36.
- BEVERIDGE, I. 1978. Helminth parasites of Australian marsupials. In Fauna, Proceedings 36 Post-Graduate Committee in Veterinary Science, University of Sydney, Australia, pp. 273–285.
- , S. C. E. FRIEND, N. JEGANATHAN, AND J. CHARLES. 1998. Proliferative sparganosis in Australian dogs. Australian Veterinary Journal 79: 757–769.
- BOWMAN, D. D., C. M. HENDRIX, D. S. LINDSAY, AND S. C. BARR. 2002. Feline clinical parasitology. Iowa State University Press, Ames, Iowa, pp. 189–194.
- DICKMAN, C. R. 1996. Overview of the impact of feral cats on Australian native fauna. Australian Nature Conservation Agency, Canberra, <<http://www.deh.gov.au/biodiversity/invasive/publications/cat-impacts/feral.html>>. Accessed 10 February 2007.
- KWA, B. H. 1972. Studies on the sparganum of *Spirometra erinacei*—II. Proteolytic enzyme(s) in the scolex. International Journal for Parasitology 2: 29–33.
- MASTURA, A. B., S. AMBU, O. HASNAH, AND R. ROSLI. 1996. Spargana infection of frogs in Malaysia. Southeast Asian Journal of Tropical Medical Public Health 27: 51–52.
- MCCRACKEN, H. 1994. Husbandry and diseases of captive reptiles. In Wildlife. Proceedings 233 Post-Graduate Committee in Veterinary Science, University of Sydney, Sydney, Australia, pp. 461–541.
- OAKWOOD, M., AND D. SPRATT. 2000. Parasites of the northern quoll, *Dasyurus hallucatus* (Marsupialia: Dasyuridae) in tropical savanna, Northern Territory. Australian Journal of Zoology 48: 79–90.
- POULIN, R. 1998. Parasite aggregation: Causes and consequences. In Evolutionary ecology of parasites. From individuals to communities. Chapman and Hall, London, UK, pp. 90–110.
- SANDARS, D. F. 1953. A study of Diphylobothriidae (Cestoda) from Australian hosts. Proceedings of the Royal Society of Queensland 63: 65–70.
- SASTRAWAN, P. 1978. Studies on the taxonomy and biology of the cestode *Spirometra erinacei*. Master's Thesis, Department of Parasitology, University of Queensland, Brisbane, Australia.
- SKERRATT, L. F., J. H. L. SKERRATT, R. MARTIN, AND K. HANDASYDE. 2004. The effects of sarcoptic mange on the behaviour of wild common wombats *Vombatus ursinus*. Australian Journal of Zoology 52: 331–339.
- SPRENT, J. F. A. 1988. Ascaridoid nematodes of amphibians and reptiles: *Ophidascaris* Baylis, 1920. Systematic Parasitology 11: 165–213.
- WHITTINGTON, R., D. MIDDLETON, D. M. SPRATT, F. MUNTZ, B. CARMEL, H. E. MCCracken, M. R. STRAKOSCH, J. STEPHANSON-SHAW, P. A. HARPER,

- AND W. J. HARTLEY. 1992. Sparganosis in the monotremes *Tachyglossus aculeatus* and *Ornithorhynchus anatinus* in Australia. *Journal of Wildlife Diseases* 28: 636–640.
- ZHU, X. Q., I. BEVERIDGE, L. BERGER, D. BARTON, AND R. B. GASSER. 2002. Single-strand conformation polymorphism-based analysis reveals genetic variation within *Spirometra erinacei* (Cestoda: Pseudophyllidea) from Australia. *Molecular and Cellular Probes* 16: 159–165.
- Received for publication 27 March 2007.*