

## **Feline familial pedal eosinophilic dermatosis in two littermates**

Authors: Pressanti, Charline, and Cadiergues, Marie-Christine

Source: Journal of Feline Medicine and Surgery Open Reports, 1(1)

Published By: SAGE Publishing

URL: <https://doi.org/10.1177/2055116915579683>

---

The BioOne Digital Library (<https://bioone.org/>) provides worldwide distribution for more than 580 journals and eBooks from BioOne's community of over 150 nonprofit societies, research institutions, and university presses in the biological, ecological, and environmental sciences. The BioOne Digital Library encompasses the flagship aggregation BioOne Complete (<https://bioone.org/subscribe>), the BioOne Complete Archive (<https://bioone.org/archive>), and the BioOne eBooks program offerings ESA eBook Collection (<https://bioone.org/esa-ebooks>) and CSIRO Publishing BioSelect Collection (<https://bioone.org/csiro-ebooks>).

Your use of this PDF, the BioOne Digital Library, and all posted and associated content indicates your acceptance of BioOne's Terms of Use, available at [www.bioone.org/terms-of-use](http://www.bioone.org/terms-of-use).

Usage of BioOne Digital Library content is strictly limited to personal, educational, and non-commercial use. Commercial inquiries or rights and permissions requests should be directed to the individual publisher as copyright holder.

---

BioOne is an innovative nonprofit that sees sustainable scholarly publishing as an inherently collaborative enterprise connecting authors, nonprofit publishers, academic institutions, research libraries, and research funders in the common goal of maximizing access to critical research.



# Feline familial pedal eosinophilic dermatosis in two littermates

Charline Pressanti and Marie-Christine Cadiergues

*Journal of Feline Medicine and Surgery*  
*Open Reports*  
 1–5

© The Author(s) 2015

Reprints and permissions:

[sagepub.co.uk/journalsPermissions.nav](http://sagepub.co.uk/journalsPermissions.nav)

DOI: 10.1177/2055116915579683

[jfmsopenreports.com](http://jfmsopenreports.com)



## Abstract

In cats, the most common eosinophilic dermatoses are feline miliary dermatitis and eosinophilic granuloma complex. The most commonly identified underlying cause is a hypersensitivity reaction. Few cases of familial forms of eosinophilic dermatoses are reported in the literature. Two young adult cats from the same litter presented 2 years apart with a severe and chronic fluid or tissue infiltration of the distal part of several limbs. Lesions started on the forelegs and developed on the other limbs. Cytological and histopathological examinations showed lesions consistent with an atypical form of feline eosinophilic dermatosis associated with secondary bacterial infection. In both cats, antibiotics combined with immunosuppressive treatment partially improved the lesions, which continued to progress on a waxing and waning course, even in the absence of treatment. Allergy work-up did not permit the identification of an underlying allergic triggering factor. The severity of the lesions, the unusual presentation and the unsatisfactory response to immunosuppressive therapy in two feline littermates suggested a genetic form of eosinophilic dermatosis.

**Accepted:** 5 August 2014

In cats, the most common eosinophilic dermatoses (EDs) are feline miliary dermatitis and feline eosinophilic granuloma complex (FEGC). The most commonly identified underlying cause is a hypersensitivity reaction.<sup>1</sup> Few cases of familial forms of EDs are described in the literature.<sup>2,3</sup> We report two cases with a presumptive familial pedal ED.

Case 1, a 1-year-old female domestic shorthair spayed cat, presented with a 6 month history of recurrent wounds and swellings, poorly responsive to antibiotics, on the legs. Initial lesions were swelling, exudation, erosions and crusts of the right metacarpal region; discomfort was mild. Oral antibiotics given for 3 weeks did not improve the lesions, which then slowly decreased spontaneously. A few weeks later, similar lesions appeared on the left hindlimb; no response was obtained with antibiotics given for 15 days.

General examination only revealed a moderate lymph node enlargement. Swelling, erosions, oozing on the plantar aspect of the digits and a fistula draining a thick and yellowish pus on the distal part of the leg (Figure 1) were observed on the left hindlimb and were less severe on the right forelimb.

Differential diagnoses included bacterial infection, atypical infections (phaeohyphomycosis, mycobacteriosis,

nocardiosis) and sterile inflammatory conditions such as atypical eosinophilic lesions. Viral infection and neoplasia were considered less likely.

Cytological examination of impression smears showed numerous neutrophils, intracytoplasmic coccoid bacteria and eosinophils. Complete blood count (CBC) showed severe leukocytosis with moderate eosinophilia. Blood chemical profile was unremarkable except for severe hyperprotidaemia (87.6 g/l [reference interval 55–71 g/l]). Feline leukaemia virus (FeLV) and feline immunodeficiency virus (FIV) tests were negative. Cytology from enlarged lymph nodes showed a granulomatous and eosinophilic infiltrate associated with plasmacytic hyperplasia. Fungal culture was negative, and bacterial culture revealed a *Streptococcus* species sensitive to all antibiotics. Histological examination of

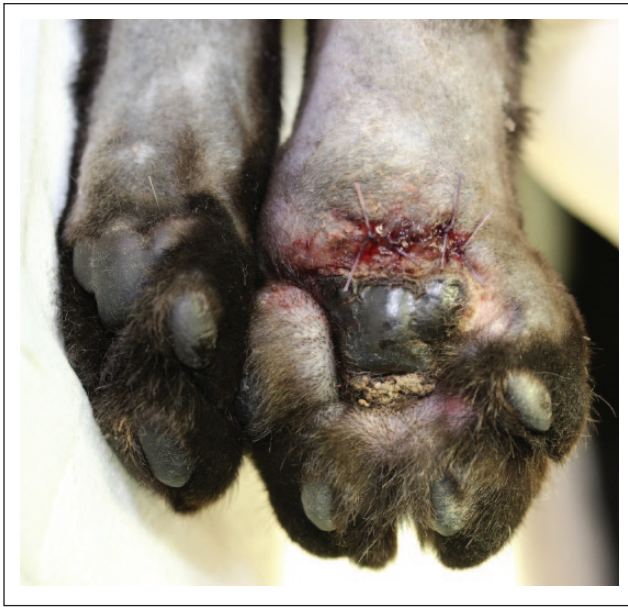Department of Clinical Sciences, National Polytechnic Institute – National Veterinary School of Toulouse (INP-ENVT), France

### Corresponding author:

Marie-Christine Cadiergues DVM, PhD, DipECVD, Department of Clinical Sciences, INP-ENVT, 23 Chemin des Capelles, BP 87614, 31076 Toulouse Cedex 3, France  
 Email: [mc.cadiergues@envt.fr](mailto:mc.cadiergues@envt.fr)



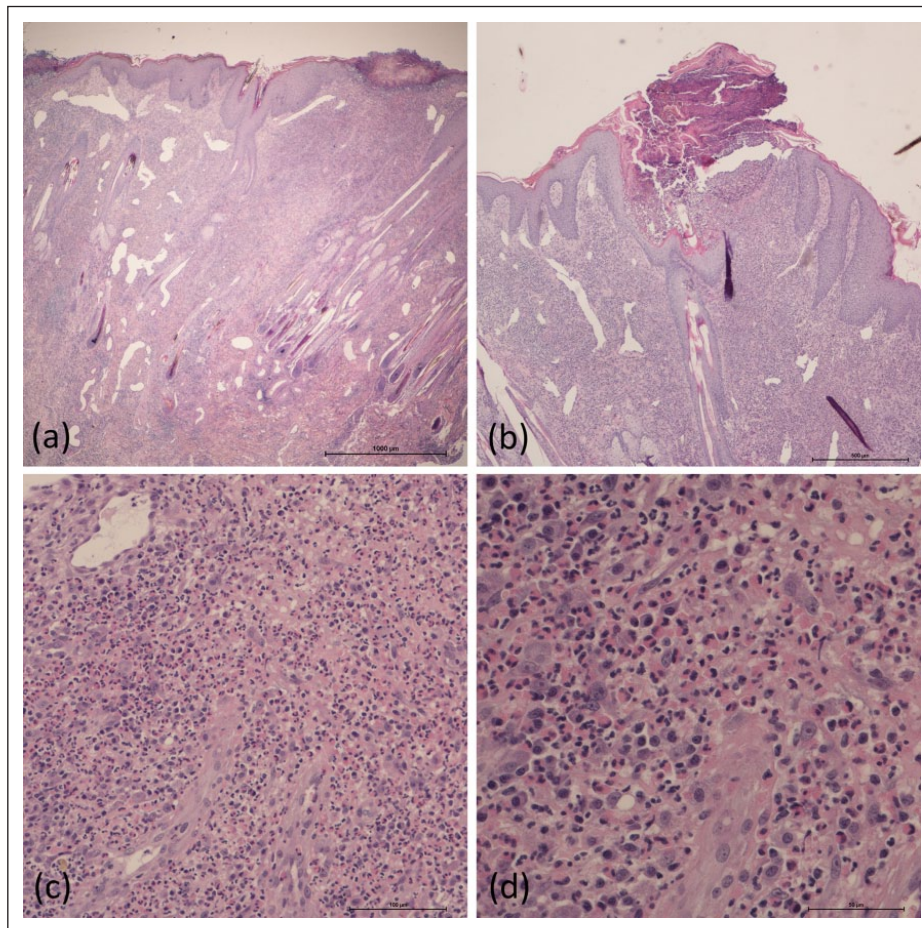
Creative Commons CC-BY-NC: This article is distributed under the terms of the Creative Commons Attribution-NonCommercial 3.0 License (<http://www.creativecommons.org/licenses/by-nc/3.0/>) which permits non-commercial use, reproduction and distribution of the work without further permission provided the original work is attributed as specified on the SAGE and Open Access page (<http://www.uk.sagepub.com/aboutus/openaccess.htm>).



**Figure 1** Case 1, ventral aspect of the left hindlimb. The picture was taken after having performed the biopsies

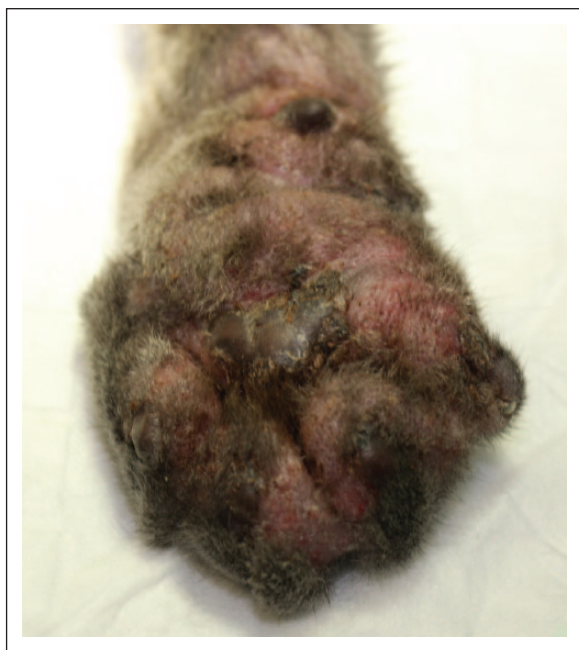skin biopsies revealed a nodular-to-diffuse dermatosis, predominantly mastocytic and eosinophilic. Plasma cells, histiocytes, lymphocytes and a few foci of eosinophilic furunculosis were also observed (Figure 2a–d). Based on these results, a presumptive diagnosis of pedal ED with secondary bacterial infection was considered.

Initial treatment consisted of injectable cefovecin (Convenia; Zoetis), as the owners refused to pill the cat. As poor improvement was seen and the prognosis was guarded, the owners decided to abandon the animal. The cat was rescued and received oral marbofloxacin (Marbocyl; Vetoquinol) 2.5 mg/kg q24h. After a week, oral prednisolone (Megasolone; Merial) was started at 2 mg/kg q24h. An allergy work-up was initiated with a systemic antiparasitic treatment (selamectin [Stronghold; Zoetis]) and a dietary trial (Hypoallergenic DR25; Royal Canin). After 3 weeks, the fistula had resolved; swelling was still present but reduced. The dose of prednisolone was tapered to an every-other-day regimen for 2 weeks and reduced further to 1 mg/kg every other day. Despite the initial improvement, lesions were still present on the hindlimb and a new lesion, consistent with an eosinophilic granuloma, appeared on



**Figure 2** (a) Nodular-to-diffuse dermatosis (haematoxylin and eosin [H&E],  $\times 20$ ). (b) Dense dermal infiltrate and pustular lesion (H&E,  $\times 40$ ). (c) Perifollicular and diffuse interstitial cellular infiltrate. Numerous eosinophils are present (H&E,  $\times 100$ ). (d) Close-up view of the cellular infiltrate: numerous eosinophils are present, along with mast cells, plasma cells and lymphocytes (H&E,  $\times 400$ )





**Figure 3** Case 2, ventral aspect of the right forelimb. Note erythema, oozing and swelling

the chin. After 6 weeks, antibiotics were discontinued and ciclosporin A (Atopica; Novartis) was started at 7 mg/kg q24h. Prednisolone was tapered and then stopped; hypoallergenic diet was maintained. During the daily regimen of ciclosporin, the limb lesions regressed, the chin swelling persisted and ulcerative lesions appeared in the labial region, associated with pain and dysorexia. Oral clindamycin (Antirobe; Zoetis) at 11 mg/kg q24h for 20 days and meloxicam (Metacam; Boehringer Ingelheim) at 0.05 mg/kg for 5 days improved the cat's discomfort. The labial lesions regressed and ciclosporin was given q48h. The dietary re-challenge was negative; however, as ciclosporin had not been discontinued, a dietary-triggering factor could not be ruled out. During the following months, the initial pedal lesions resolved but other eosinophilic lesions appeared randomly on the face, chin, feet and in the oral cavity, and regressed spontaneously. Ciclosporin was stopped and selamectin was maintained monthly.

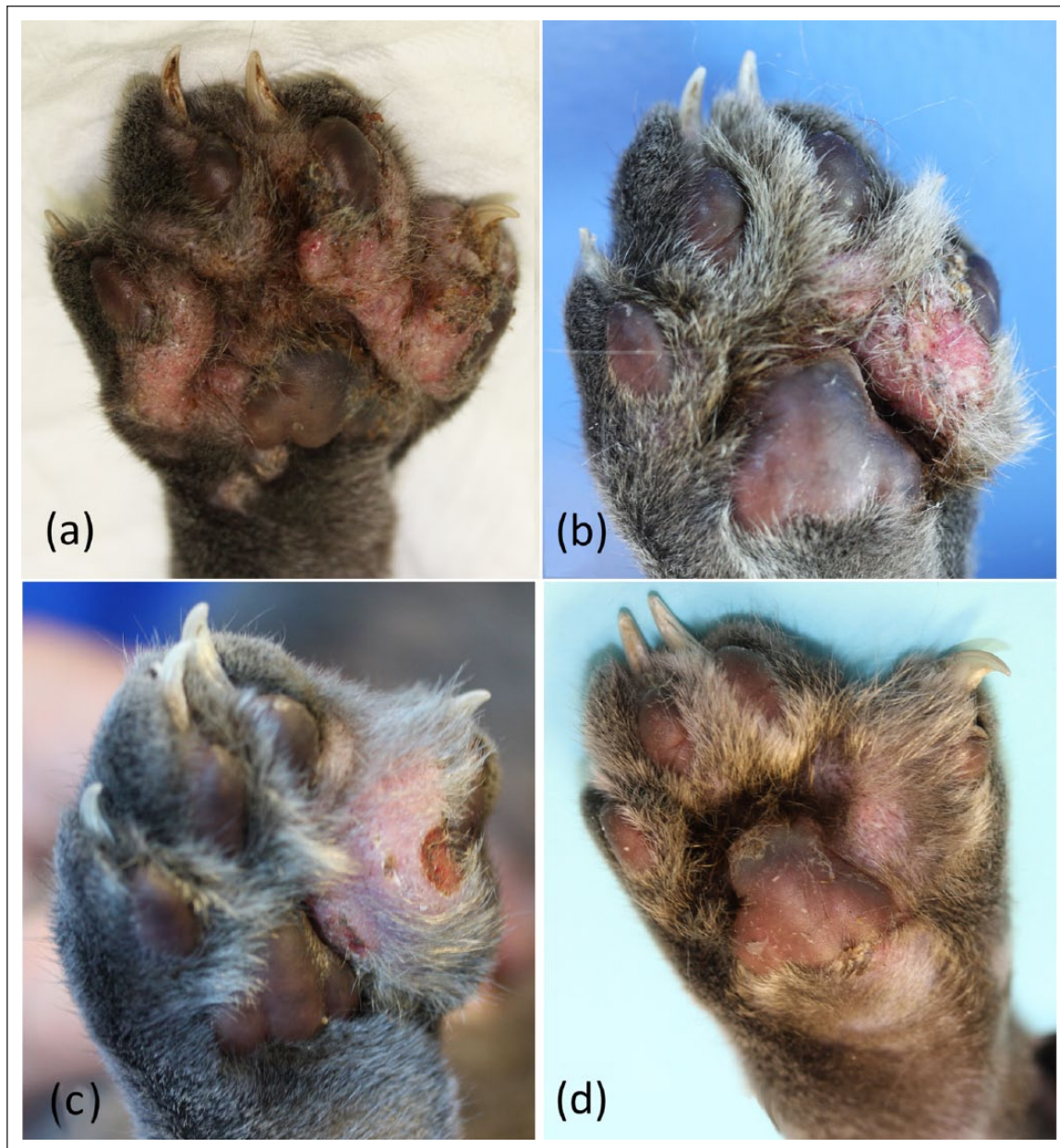
Case 2, a 3-year-old male domestic shorthair neutered cat, presented with a 2.5 year history of recurrent swelling of the right front leg, as the last resort before amputation. He had been rescued and lived with 15 other cats in a house with free outdoor access. Initial lesions were swelling, erosions, crusts and oozing on the left metacarpal and carpal regions; discomfort was mild. The cat had repeatedly received injectable enrofloxacin (Baytril 5%; Bayer) without improvement. Radiographs were unremarkable, and FeLV and FIV tests were negative. Amputation was offered but postponed as lesions regressed and new lesions appeared on the right front and left hindlimbs.

No physical abnormalities were found except for moderate lymph node enlargement. Lesions were present on all four limbs, although they were milder on the left forelimb. Similar lesions to case 1 were observed (Figure 3). The differential diagnoses and diagnostic approach were similar to case 1. Impression smears from small pustules showed mainly eosinophils; neutrophils and intracytoplasmic coccoid bacteria were also noted. CBC revealed a mild neutrophilia with monocytosis. Hyperprotidaemia was more severe (101.9 g/l). Fungal culture results, histopathological examination and cytological examination of nodal aspirates were similar to case 1. Bacterial culture revealed a strain of *Staphylococcus pseudintermedius* sensitive to  $\beta$ -lactams, macrolides, potentiated sulfonamides, quinolones and aminoglycosides.

A similar presumptive diagnosis of pedal ED with secondary bacterial infection was proposed. As it could be established that the two cats were littermates, a familial form of ED was considered. Oral cefalexin at 20 mg/kg q12h (Cefaseptin; Sogeval) was combined with prednisolone at 1.5 mg/kg q24h (Megasolone; Merial). A broad-spectrum antiparasitic treatment was prescribed monthly (selamectin [Stronghold; Zoetis]). All in-contact cats were treated with fipronil spot-on (Effipro; Virbac) monthly.

After 1 month, improvement was observed, with less swelling and oozing (Figure 4a,b). An eosinophilic infiltrate was still present under the crusts. The left frontlimb appeared normal. The prednisolone dose was decreased and antibiotics were maintained for 3 more weeks. A dietary trial was started (the cat was isolated from the in-contacts) but it was stopped prematurely owing to poor owner compliance. After 3 weeks, further improvement was observed (Figure 4c); however, pilling the cat had become difficult. Antibiotics were discontinued and prednisolone was progressively tapered to 0.5 mg/kg q48h. Ciclosporin was declined for financial reasons. When lesions were stable, although not completely resolved (Figure 4d), the owner stopped the treatment. As in case 1, lesions, although limited to the feet, waxed and waned, and the owner refused to keep the cat on a long-term therapy.

Clinical presentation, similar in both cases, was atypical. Eosinophilic and mastocytic infiltrates suggest lesions of the FEGC. In FEGC, although histopathological features are similar,<sup>4</sup> clinical presentations are highly variable and comprise indolent ulcers, eosinophilic plaques and eosinophilic granulomas.<sup>5</sup> Limb swelling is not reported as a true lesion of FEGC; therefore, the terminology 'ED' seems more appropriate in these cases. Numerous aetiological factors have been proposed as potential causes of EDs.<sup>1</sup> Hypersensitivity disorders are mostly suggested and, to a lesser extent, infectious conditions or foreign body reactions.<sup>6</sup> Where the cats live, flea allergy dermatitis (FAD) is the most



**Figure 4** Case 2, follow-up of the left hindlimb. (a) On presentation, note erythema, oozing and swelling. (b) After 1 month, note the diminished swelling, mild erythema, erosions and crusts. (c) After 2 months, there was persistence of swelling on one digit, mild erythema, alopecia and crusts. (d) After 5 months, note the improvement – mild thickening of the digit, mild erythema and hair regrowth

common allergic skin disorder in felines. In both cats flea treatment did not improve the lesions. However, in case 2, flea control was challenging owing to numerous in-contact cats. Cutaneous adverse food reaction (CAFR) can also induce various lesions, including FEGC.<sup>7</sup> In case 1, it was tested after an 8 week dietary trial and subsequent negative re-challenge, whereas in case 2 the owner did not manage to feed the cat a strict diet. Finally, environmental causes of hypersensitivity can also induce FEGC. Also named atopic dermatitis or ‘non-flea

non-food-induced hypersensitivity’,<sup>8,9</sup> this condition is diagnosed after exclusion of FAD and CAFR. As allergic tests are not validated in cats and often difficult to interpret they were not performed in these cases.<sup>10-12</sup> Atopic cases usually respond to immunomodulatory therapy such as glucocorticoids, ciclosporin or antihistamines.<sup>5</sup> Prednisolone was used in both cases without much benefit, and ciclosporin was not effective in case 1.

Considering the lack of improvement with flea/food trials and the low effect of immunosuppressive therapy,

an allergic aetiology seems unlikely. Few cases of familial forms of FEGC are reported. These forms are rare and affect a number of cats with similar clinical lesions within a same litter or lineage. A genetic factor has been shown in a specific pathogen-free family of cats in a closed breeding colony.<sup>3</sup> In a more recent description, a genetic factor was suspected in a lineage of Norwegian forest cats where eosinophilic granulomas were not associated with an evident underlying cause.<sup>2</sup> These few data, combined with the cats' history (littermates, onset at a young and same age), the lack of response to immunomodulatory therapy, and the waxing and waning course of the lesions, strongly suggest a genetic background in this atypical ED.

## Conclusions

Familial forms of EDs are rarely reported, and are possibly underdiagnosed. They should be suspected when eosinophilic lesions start at a young age, no allergic cause can be identified and when a similar history is obtained from one or several relatives.

**Funding** The authors received no grant from any funding agency in the public, commercial or not-for-profit sectors for the preparation of this case report.

**Conflict of interest** The authors declare no conflicts of interest.

## References

- 1 Buckley L and Nuttall T. **Feline eosinophilic granuloma complexities: some clinical clarification.** *J Feline Med Surg* 2012; 14: 471–481.
- 2 Leistra WH, van Oost BA and Willemse T. **Non-pruritic granuloma in Norwegian forest cats.** *Vet Rec* 2005; 156: 575–577.
- 3 Power HT. **Eosinophilic granuloma in a family of specific pathogen-free cats.** Proceedings of the American Academy of Veterinary Dermatology/American College of Veterinary Dermatology; 1990; San Francisco, CA. 18–22 April 1990, p 45.
- 4 Fondati A, Fondevila D and Ferrer L. **Histopathological study of feline eosinophilic dermatoses.** *Vet Dermatol* 2001; 12: 333–338.
- 5 Bloom PB. **Canine and feline eosinophilic skin diseases.** *Vet Clin North Am Small Anim Pract* 2006; 36: 141–160.
- 6 Miller WH, Jr, Griffin C and Campbell K. *Muller & Kirk's small animal dermatology.* 7th ed. St Louis, MO: Elsevier, 2013.
- 7 Bryan J and Frank LA. **Food allergy in the cat: a diagnosis by elimination.** *J Feline Med Surg* 2010; 12: 861–866.
- 8 Favrot C, Steffan J, Seewald W, et al. **Establishment of diagnostic criteria for feline nonflea-induced hypersensitivity dermatitis.** *Vet Dermatol* 2012; 23: 45–50.
- 9 Favrot C. **Feline non-flea induced hypersensitivity dermatitis: clinical features, diagnosis and treatment.** *J Feline Med Surg* 2013; 15: 778–784.
- 10 Rossi MA, Messinger L, Olivry T, et al. **A pilot study of the validation of percutaneous testing in cats.** *Vet Dermatol* 2013; 24: 488–e115.
- 11 Belova S, Wilhelm S, Linek M, et al. **Factors affecting allergen-specific IgE serum levels in cats.** *Can J Vet Res* 2012; 76: 45–51.
- 12 Schleifer SG and Willemse T. **Evaluation of skin test reactivity to environmental allergens in healthy cats and cats with atopic dermatitis.** *Am J Vet Res* 2003; 64: 773–778.