



Fibrosarcoma of the urinary bladder in a cat

Authors: Capasso, Angelo, Raiano, Vera, Sontuoso, Antonio, Olivero, Daniela, and Greci, Valentina

Source: Journal of Feline Medicine and Surgery Open Reports, 1(1)

Published By: SAGE Publishing

URL: <https://doi.org/10.1177/2055116915585019>

BioOne Complete (complete.BioOne.org) is a full-text database of 200 subscribed and open-access titles in the biological, ecological, and environmental sciences published by nonprofit societies, associations, museums, institutions, and presses.

Your use of this PDF, the BioOne Complete website, and all posted and associated content indicates your acceptance of BioOne's Terms of Use, available at www.bioone.org/terms-of-use.

Usage of BioOne Complete content is strictly limited to personal, educational, and non - commercial use. Commercial inquiries or rights and permissions requests should be directed to the individual publisher as copyright holder.

BioOne sees sustainable scholarly publishing as an inherently collaborative enterprise connecting authors, nonprofit publishers, academic institutions, research libraries, and research funders in the common goal of maximizing access to critical research.



Fibrosarcoma of the urinary bladder in a cat

Angelo Capasso¹, Vera Raiano¹, Antonio Sontuoso¹, Daniela Olivero² and Valentina Greci¹

Journal of Feline Medicine and Surgery
Open Reports
 1–6

© The Author(s) 2015
 Reprints and permissions:
sagepub.co.uk/journalsPermissions.nav
 DOI: 10.1177/2055116915585019
jfmsopenreports.com



Abstract

Case summary A 5-year-old female spayed domestic shorthair cat was presented with haematuria, pollakiuria and stranguria of 2 months' duration, and a firm non-painful mass in the urinary bladder was palpated. Abdominal radiographs showed thickening and irregular cranial margins of the urinary bladder wall. Abdominal ultrasound showed a vascularised mass of mixed echogenicity almost entirely occupying the urinary bladder lumen. During explorative laparotomy, the mass appeared pedunculated and was totally excised. Histopathology was characterised by infiltration of the mucosal, submucosal and muscular layers by proliferated atypical mesenchymal cells; immunochemistry confirmed the diagnosis of fibrosarcoma. The cat was discharged with normal urination 5 days after surgery. The owner declined any imaging follow-up but reported the cat to be free of any clinical signs at 16 months after surgery.

Relevance and novel information To the best of our knowledge, this is the first case of primary fibrosarcoma of the urinary bladder in the cat. Fibrosarcoma should be included in the differential diagnosis of urinary bladder neoplasia.

Accepted: 22 August 2014

Introduction

In cats and dogs, urinary bladder tumours are rare and account for approximately 1% of all tumours. The majority of urinary bladder tumours are epithelial in origin, with transitional cell carcinoma (TCC) the most common. Non-epithelial tumours are represented by leiomyoma, leiomyosarcoma, fibroma, haemangioma, haemangiosarcoma and lymphoma.^{1–12} A case of histiocytic sarcoma of the urinary bladder has been reported in a dog.¹³ Nerve sheath tumour and lipoma of the urinary bladder have also been reported in the feline species; but, to date, fibrosarcomas have been described only in dogs.^{1,14–17}

The aim of this report is to describe the clinical and imaging findings and surgical outcome of a urinary bladder fibrosarcoma that occurred in a cat.

Case description

A 5-year-old female spayed domestic shorthair cat was referred to the Gregory VII Veterinary Hospital, Rome, Italy, because of haematuria, pollakiuria and stranguria of 2 months' duration and which were unresponsive to antibiotics.

On abdominal palpation a firm non-painful intra-abdominal mass was palpated in the caudal abdomen that was suspected on the basis of its location to be the urinary bladder.

Blood work abnormalities were seen: creatine phosphokinase was 154 IU/l (reference interval [RI] 10–150 IU/l), aspartate aminotransferase was 49 IU/l (RI 0–40 IU/l), alanine aminotransferase was 55 IU/l (RI 0–50 IU/l), urea was 66 mg/dl (RI 20–60 mg/dl) and creatinine was 1.80 mg/dl (RI 0.35–1.50 mg/dl); urinalysis was not performed because of the impossibility of collecting a suitable sample. Abdominal radiographs (right laterolateral and ventrodorsal projection) showed an over-distended urinary bladder with irregular cranial margins and the presence of a small radiotransparent area in the urinary bladder lumen, compatible with air

¹Gregory VII Veterinary Hospital, Rome, Italy

²Analisi BiEsseA Laboratory, Milan, Italy

Corresponding author:

Valentina Greci DVM, PhD, Ospedale Veterinario Gregorio VII, Piazza di Villa Carpegna 52, 00167, Rome, Italy
 Email: valentina.greci@libero.it



Creative Commons CC-BY-NC: This article is distributed under the terms of the Creative Commons Attribution-NonCommercial 3.0 License (<http://www.creativecommons.org/licenses/by-nc/3.0/>) which permits non-commercial use, reproduction and distribution of the work without further permission provided the original work is attributed as specified on the SAGE and Open Access page (<http://www.uk.sagepub.com/aboutus/openaccess.htm>).

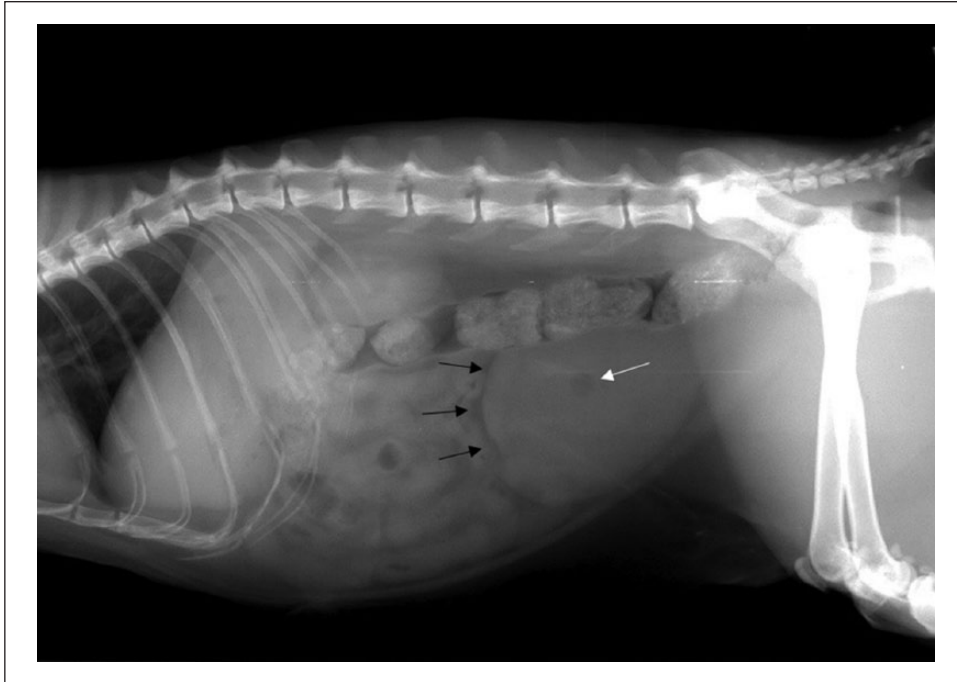


Figure 1 Right lateral view of the abdomen. Note the over-distended urinary bladder, the cranial margins appear irregular and thickened (black arrow); a radiopaque spot is notable in the middle of the urinary bladder (white arrow)

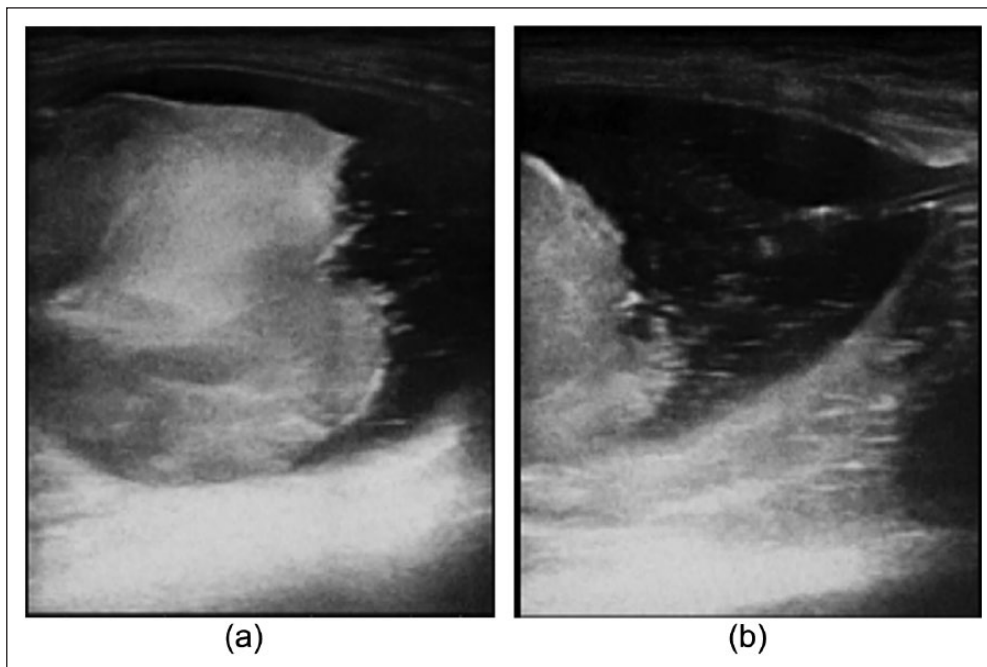


Figure 2 Abdominal ultrasound findings. Longitudinal scan after urethral catheterisation and distension with 0.9% saline solution. (a) An irregular, rounded $4.6 \times 4.2 \times 4$ cm lesion arises from the apex and the dorsal wall of the urinary bladder. (b) The trigone and the urethra appear normal

(Figure 1). The presence of air was attributed to the possibility of a gas-producing bacterial infection.

On abdominal ultrasound, the urinary bladder lumen was entirely occupied by the presence of a mass of mixed

echogenicity (Figure 2a); mild bilateral pyelectasia (1 mm) was also detected. The cat was sedated, and the urethra was catheterised and the urinary bladder distended with sterile 0.9% saline solution for better

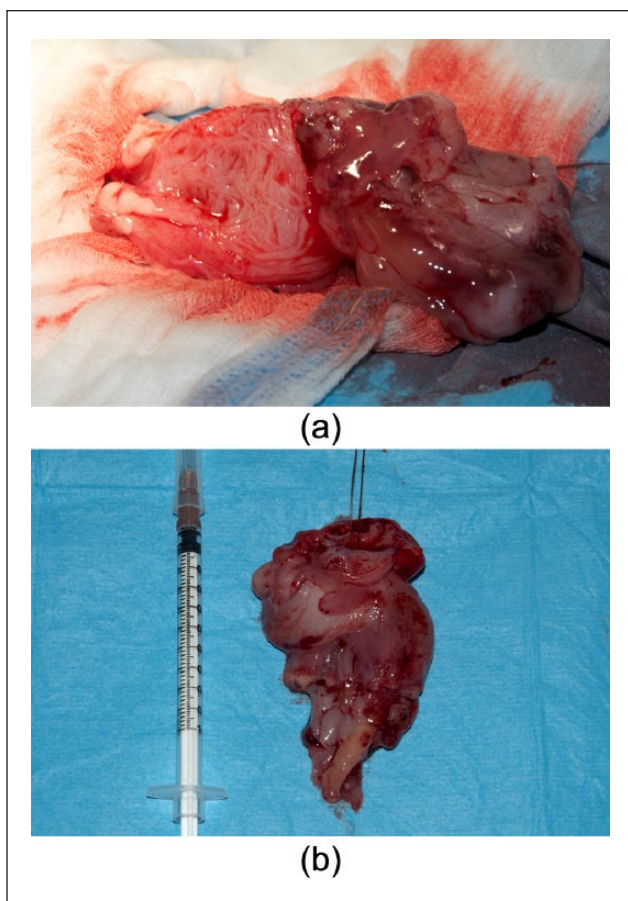


Figure 3 (a) Gross aspect of the urinary bladder and mass during surgery: note the thickened urinary bladder wall and the presence of a pedunculated mass that was filling the urinary bladder. (b) Gross examination: the mass measured $6.0 \times 4.5 \times 3.2$ cm, had a fibroelastic consistency and was white to pinkish in colour; the surface is characterised by the presence of erosion and haemorrhages

evaluation: an irregular vascularised lesion measuring $4.6 \times 4.2 \times 4.0$ cm arising from the cranial and dorsal wall of the urinary bladder was observed (Figure 2b); the urethra and the trigone were not involved. No other changes were detected. A urinary bladder neoplasm was suspected. Three thorax projection radiographs were unremarkable.

The owner declined computed tomography and opted for explorative laparotomy

The cat was anaesthetised and a ventral midline coeliotomy was performed. The urinary bladder appeared over-distended, firm and smooth but filled by a large mass of fibroelastic consistency. Stay sutures were placed in the apex of the bladder and paramedian along the ventral aspect to the level of the bladder neck and proximal urethra. The urinary bladder was isolated from the remainder of the abdominal cavity with laparotomy sponges. A ventral cystotomy was performed to examine the bladder mucosa and the mass appeared pedunculated

and extended from the craniodorsal wall of the urinary bladder into the lumen (Figure 3a). The mass was excised with 1 cm margins of grossly normal urinary bladder and preservation of the caudal vesicular vessels.

On gross examination, the mass was irregular in shape, smooth but not encapsulated, and white to pink in colour; the mass measured $6.0 \times 4.5 \times 3.2$ cm, and there was gross evidence of ulceration and haemorrhage of the surface (Figure 3b).

The mass was routinely fixed in buffered 10% formalin and stained with haematoxylin and eosin. Histopathological examination was characterised by infiltration of the mucosal, submucosal and muscular layers by proliferated atypical mesenchymal cells; cell cytoplasm was bipolar and moderate in quantity; the nuclei were increased in size and pleomorphic to vesicular in appearance, with one or two nucleoli observed per high-power field (HPF) at $\times 40$ magnification. The cells appeared irregularly arranged in interwoven and concentric bundles (Figure 4a,b); moderate infiltration of neutrophils, plasma cells and lymphocytes, and eight mitoses per HPF at $\times 10$ magnification were observed. The transitional epithelium was atrophic and diffusely eroded. The peduncle was not infiltrated and margins evaluated by transverse sectioning were disease-free (8 mm).

Histological examination was consistent with a malignant mesenchymal tumour, suggesting a fibrosarcoma.

The following immunohistochemical stains were performed: vimentin (Vimentin Ab-2, 1:200 in antibody diluent; Thermo Fisher Scientific), S-100 protein (Mouse S-100 Ab-1; Thermo Fisher Scientific), glial fibrillary acidic protein (rabbit antiglial fibrillar acidic protein, 1:500; Dako), smooth muscle actin (Perossidasi DAB detection; Dako) and desmin (Desmin Ab-2; Thermo Fisher Scientific). The neoplastic cells stained strongly positive for vimentin only (Figure 5).

On the basis of the spindle cell morphology, the arrangement of tumour cells and positive staining of the neoplastic cells for vimentin, a diagnosis of fibrosarcoma was made.

The cat was hospitalised on supportive care, fluid therapy, meloxicam 0.05 mg/kg q24h (Metacam; Boehringer Ingelheim), amoxicillin/clavulanic acid 20 mg/kg q12h (Synulox; Pfizer) and methadone hydrochloride 0.2 mg/kg q6h (Metadone Cloridrato; Molteni); after 3 days normal urination was established and the cat was discharged 5 days after surgery.

The owner declined any additional treatment. At the last telephone interview at 16 months after surgery, the cat was free of any clinical signs.

Discussion

To the best of our knowledge, this is the first case of fibrosarcoma of the urinary bladder in the cat. The aim of this work was to describe the clinical presentation, the




Figure 4 Microscopic findings. (a) Section of the urinary bladder mass characterised by a proliferation of spindle cells irregularly arranged in interwoven and concentric bundles. In the central part of the lesion a degenerative mucinous area is observed (haematoxylin and eosin, $\times 4$). (b) High magnification of the spindle cell pattern intertwined with a minimal deposition of amorphous eosinophilic extracellular matrix; in the right upper corner, vessels of small and medium size are observed (haematoxylin and eosin, $\times 10$)

imaging findings, surgical outcome and histological features of a primary urinary bladder fibrosarcoma in a cat.

Clinical presentation of urinary bladder tumours is non-specific but mainly characterised by haematuria, pollakiuria, dysuria and progressive stranguria, and more rarely lethargy, weight loss, urinary tenesmus, mechanical incontinence and rectal prolapse.^{2-5,18-20} Abnormalities on physical examination, such as the presence of a firm mass in the caudal abdomen, have been reported for different urinary bladder tumours.^{2,4,5,12,15,16,18} In the cat reported herein, the urinary tract clinical signs were non-specific (haematuria, severe pollakiuria and stranguria) and could have been due to infection, cystitis, calculi or a tumour; on physical examination, a firm,

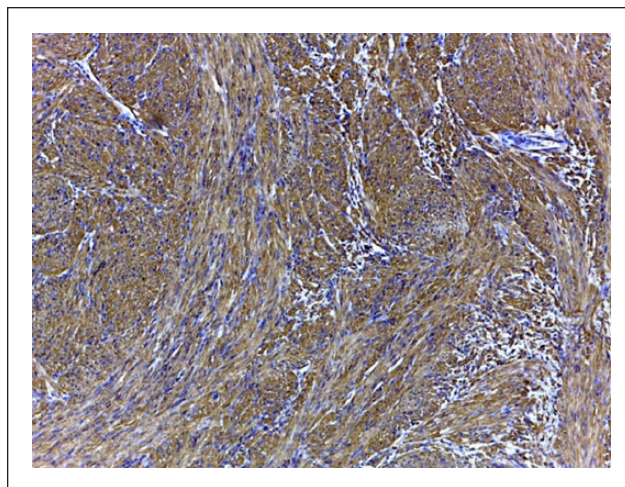


Figure 5 Immunohistochemical staining with vimentin: note the diffuse positive staining of the cytoplasm ($\times 10$)

non-painful mass could be palpated, suggesting the presence of a urinary bladder mass.

Blood work changes are non-specific and mainly related to secondary hydronephrosis and secondary urinary infections. Urinalysis can show increased cellularity and signs of infections. Only in 30% of patients can tumour cells be detected on standard urinalysis; this percentage has been improved by the use of a urinary bladder tumour antigen screening test for TCC in dogs.^{2,4,14,17,18} In the cat reported herein, a mild azotaemia was observed, which could have been explained by a urinary tract infection as gas was noted on plain radiographs, and mild pyelectasia, in the absence of hydronephrosis and trigone involvement, during abdominal ultrasound. However, this is speculative as a urinalysis and a urine culture were not performed because the cat was showing continuing voiding and catheterisation was not possible in the awake patient. Even when the patient was sedated and a catheter placed, urine was not retrieved.

In cats with urinary bladder tumours, abdominal radiographs are mainly unremarkable; however, on plain films a thickened bladder wall, a distended bladder or a displaced urinary bladder and renal changes can be observed; contrast radiography is often necessary to evaluate the lower urinary tract.^{2,4,9,21} In this cat, abdominal changes were an over-distended urinary bladder, irregular cranial margins and thickening of the urinary bladder wall: these changes have already been described and are not diagnostic of a urinary bladder tumour but of urinary bladder disease.^{10,14}

Abdominal ultrasound allows good evaluation of new growths in the urinary bladder. Ultrasonographic aspects of urinary bladder tumours are variable, from irregular wall thickening to pedunculated lesions and masses arising from the urinary bladder wall and invad-

ing the urinary bladder lumen, but do not allow the different types of tumour to be distinguished. TCC usually arises from the urinary bladder neck in the dog but in the cat has been reported to arise in sites distant from the trigone.^{2,5} However, the presence of vascularisation should increase suspicion for neoplasia.^{2,9,11} In this cat, abdominal ultrasound showed a vascularised lesion of mixed echogenicity occupying almost the entire lumen of the urinary bladder. After catheterisation and distension of the urinary bladder with saline solution, the mass appeared to arise from the cranial and dorsal aspect of the urinary wall. These findings are similar to the ones described for other urinary bladder tumours, and the presence of vascularisation suggested the presence of neoplasia.

Diagnosis of urinary bladder growths can be achieved by the use of fine-needle aspiration biopsy (FNAB), traumatic catheterisation, ultrasound-guided transurethral catheterisation, urinary bladder brushing and full-thickness biopsies obtained surgically or endoscopically.^{2,18,22,23} FNAB has been discouraged in the presence of TCC owing to the possibility of tumour implantation along the needle tract.^{5,22,23}

The prognosis and therapy for urinary bladder tumour depend on staging and tumour type. In most cases, the prognosis for malignant urinary bladder tumours is poor because of their tendency to originate from or invade the urinary bladder trigone. Early lesions that have not metastasised and do not involve the trigone may be amenable to surgery; palliative partial cystectomy or debulking can be performed but should be followed by adjuvant therapy. When surgery is not viable, chemotherapy or radiation therapy have to be pursued.^{2,4,5,11,18}

In this cat, the owner declined any further diagnostics and opted for explorative laparotomy, which was acceptable because the urinary trigone was not involved. When the trigone is not involved, surgery can be concurrently diagnostic and therapeutic, as occurred in this cat as the mass was pedunculated.

As reported in the veterinary literature, surgery alone, even with disease-free margins, is palliative if not supported by adjuvant therapy, unless the lesion is benign; however, benign lesions can recur or become malignant.^{2,4,5,8,11} Although this cat was diagnosed with a malignant fibrosarcoma based on histopathology and immunohistochemistry, surgery proved to be effective.

This is a favourable result if compared with the outcome of two young dogs diagnosed with urinary bladder fibrosarcoma that died of widespread metastasis detected during necropsy at 2 weeks and 9 months after diagnosis, respectively.^{16,17} Although in this cat further imaging controls are not available, the absence of any clinical signs and the well-being of the cat at 16 months after surgery suggest that the behaviour of the fibrosarcoma was not as aggressive as in these dogs.

Conclusions

Fibrosarcoma should be considered among the differentials for feline urinary bladder tumour. Surgery with disease-free margins can represent an option, although more cases should be evaluated.

Funding The authors received no specific grant from any funding agency in the public, commercial or not-for-profit sectors for the preparation of this case report.

Conflict of interest The authors do not have any potential conflicts of interest to declare.

References

- Osborne CA, Low DG, Perman V, et al. **Neoplasms of the canine and feline urinary bladder: incidence, etiologic factors, occurrence and pathologic features.** *Am J Vet Res* 1968; 29: 2041–2055.
- Mutsaers AJ, Widmer WR and Knapp DW. **Canine transitional cell carcinoma.** *J Vet Intern Med* 2003; 17: 136–144.
- Wimberly HC and Lewis RM. **Transitional cell carcinoma in the domestic cat.** *Vet Pathol* 1979; 16: 223–228.
- Schwarz PD, Greene RW and Patnaik AK. **Urinary bladder tumors in the cat: a review of 27 cases.** *J Am Anim Hosp Assoc* 1985; 21: 237–245.
- Wilson HM, Chun R, Larson VS, et al. **Clinical signs, treatments, and outcome in cats with transitional cell carcinoma of the urinary bladder: 20 cases (1990–2004).** *J Am Vet Med Assoc* 2007; 231: 101–106.
- Patnaik AK and Greene RW. **Intravenous leiomyoma of the bladder in a cat.** *J Am Vet Med Assoc* 1979; 175: 381–383.
- Burk RL, Meierhenry EF and Schaubhut CW, Jr. **Leiomyosarcoma of the urinary bladder in a cat.** *J Am Vet Med Assoc* 1975; 167: 749–751.
- Esplin DG. **Urinary bladder fibromas in dogs: 51 cases (1981–1985).** *J Am Vet Med Assoc* 1987; 190: 440–444.
- Heng HG, Lowry JE, Boston S, et al. **Smooth muscle neoplasia of the urinary bladder wall in three dogs.** *Vet Radiol Ultrasound* 2006; 47: 83–86.
- Liptak JM, Dernel WS and Withrow SJ. **Haemangiosarcoma of the urinary bladder in a dog.** *Aust Vet J* 2004; 82: 215–217.
- Benigni L, Lamb CR, Corzo-Menendez N, et al. **Lymphoma affecting the urinary bladder in three dogs and a cat.** *Vet Radiol Ultrasound* 2006; 47: 592–596.
- House HB, Specht AJ and Johnson VS. **What is your diagnosis? Lymphoma of the urinary bladder.** *J Am Vet Med Assoc* 2010; 236: 291–292.
- Amores-Fuster I, Elliott JW, Freeman AI, et al. **Histiocytic sarcoma of the urinary bladder in a dog.** *J Small Anim Pract* 2011; 52: 665.
- Khodakaram-Tafti A, Shirian S, Vesal N, et al. **Lipoma of the urinary bladder in a cat.** *J Comp Pathol* 2011; 144: 212–213.
- Pavia PR, Havig ME, Donovan TA, et al. **Malignant peripheral nerve sheath tumour of the urinary bladder in a cat.** *J Small Anim Pract* 2012; 53: 245–248.
- Schiller AG, Maksic D, Beamer PD, et al. **Fibrosarcoma of the urinary bladder in the dog.** *J Am Vet Med Assoc* 1958; 133: 594–598.

- 17 Olausson A, Stieger SM, Lofgren S, et al. **A urinary bladder fibrosarcoma in a young dog.** *Vet Radiol Ultrasound* 2005; 46: 135–138.
- 18 Beatty JA, Martin P, Kendall K, et al. **Haematuria in a geriatric cat.** *Aust Vet J* 1999; 77: 166–167.
- 19 Dill GS Jr, McElyea U, Jr and Stookey JL. **Transitional cell carcinoma of the urinary bladder in a cat.** *J Am Vet Med Assoc* 1972; 160: 743–745.
- 20 Barrand KR. **Rectal prolapse associated with urinary bladder neoplasia in a cat.** *J Small Anim Pract* 1999; 40: 222–223.
- 21 Park RD. **Radiographic contrast studies of the lower urinary tract.** *Vet Clin North Am* 1974; 4: 863–887.
- 22 Nyland TG, Wallack ST and Wisner ER. **Needle-tract implantation following us-guided fine-needle aspiration biopsy of transitional cell carcinoma of the bladder, urethra, and prostate.** *Vet Radiol Ultrasound* 2002; 43: 50–53.
- 23 Vignoli M, Rossi F, Chierici C, et al. **Needle tract implantation after fine needle aspiration biopsy (FNAB) of transitional cell carcinoma of the urinary bladder and adenocarcinoma of the lung.** *Schweiz Arch Tierheilkd* 2007; 149: 314–318.