

## **Multiple acquired portosystemic shunts in a cat secondary to chronic diaphragmatic rupture**

Authors: Barfield, Dominic M, Gibson, Andrew D, and Lipscomb, Vicky J

Source: Journal of Feline Medicine and Surgery Open Reports, 1(1)

Published By: SAGE Publishing

URL: <https://doi.org/10.1177/2055116915585020>

---

BioOne Complete ([complete.BioOne.org](https://complete.BioOne.org)) is a full-text database of 200 subscribed and open-access titles in the biological, ecological, and environmental sciences published by nonprofit societies, associations, museums, institutions, and presses.

Your use of this PDF, the BioOne Complete website, and all posted and associated content indicates your acceptance of BioOne's Terms of Use, available at [www.bioone.org/terms-of-use](https://www.bioone.org/terms-of-use).

Usage of BioOne Complete content is strictly limited to personal, educational, and non - commercial use. Commercial inquiries or rights and permissions requests should be directed to the individual publisher as copyright holder.

---

BioOne sees sustainable scholarly publishing as an inherently collaborative enterprise connecting authors, nonprofit publishers, academic institutions, research libraries, and research funders in the common goal of maximizing access to critical research.



# Multiple acquired portosystemic shunts in a cat secondary to chronic diaphragmatic rupture

*Journal of Feline Medicine and Surgery*  
*Open Reports*  
 1–5

© The Author(s) 2015

Reprints and permissions:

sagepub.co.uk/journalsPermissions.nav

DOI: 10.1177/2055116915585020

jfmsopenreports.com



Dominic M Barfield, Andrew D Gibson and Vicky J Lipscomb

## Abstract

**Case summary** A cat with a chronic diaphragmatic rupture presented with neurological signs, including twitching and focal seizures. Blood ammonia level was markedly elevated and therefore neurological signs were thought to be related to hepatic encephalopathy. Exploratory laparotomy revealed that the left lateral and medial liver lobes were herniated into the thorax and multiple acquired portosystemic shunts (MAPSS) were present. The hernia was reduced and the diaphragm repaired. Neurological signs gradually resolved following surgery and 1 year postoperatively the cat was clinically normal, was not on any medication and had no evidence of hepatic dysfunction.

**Relevance and novel information** This is the first report of a chronic diaphragmatic rupture leading to MAPSS in a cat.

**Accepted:** 8 September 2014

A 3.5-year-old male neutered domestic shorthair cat presented for lethargy, unwillingness to stand and hypersalivation. It had two focal seizures within the 24 h prior to referral. The cat was acquired from a rescue centre 5 months prior to referral; 3 months prior to referral it was noted to have a diaphragmatic rupture on abdominal radiographs (Figure 1). The diaphragmatic hernia had not been surgically corrected, despite the advice of the referring veterinarian.

On physical examination he was stuporous, with an absent menace bilaterally. Pupillary light reflexes were consensual and present, and he was hypersalivating. Rectal temperature was 37.8°C, pulse rate was 170 beats per minute with adequate pulses, and respiratory rate was 40 breaths per minute with normal respiratory effort and no adventitious lung sounds. Cardiac sounds were inaudible on the left thorax. During examination the cat demonstrated facial twitching and partial seizures (see Video 1 in Supplementary material) (Figure 2), consistent with a hippocampal seizure. A thoracic and abdominal free fluid check with an ultrasound was performed, which showed a small volume of fluid in the pleural cavity, which was considered not significant enough to cause any clinical signs in the cat.

Complete blood count showed a mild lymphopenia ( $0.468 \times 10^9/l$ ; reference interval [RI]  $1.5\text{--}7.0 \times 10^9/l$ )

with Heinz bodies present + to ++ in the red blood cells and small-to-medium-sized Döhle bodies present in a moderate number of neutrophils. Biochemistry showed marked hyperammonaemia ( $444 \mu\text{mol/l}$ ; RI  $0\text{--}60 \mu\text{mol/l}$ ) and mild increase in creatine kinase activity ( $3104 \text{ U/l}$ ; RI  $52\text{--}506 \text{ U/l}$ ) but was otherwise normal. Initial stabilisation included oxygen supplementation (oxygen cage) as, although the cat's respiratory effort was, at the time, normal, it was tachypnoeic. Additional treatment included, lactulose ( $3 \text{ ml/kg PR q8h}$ ; Sandoz), levetiracetam (Keppra  $20 \text{ mg/kg PR q8h}$ ; UCB), amoxicillin potentiated with clavulanic acid (Augmentin,  $20 \text{ mg/kg IV q8h}$ ; GlaxoSmithKline) and diazepam (Diazemuls,  $0.5 \text{ mg/kg IV PRN}$ ; Actavis Group). The following day blood urea had decreased from  $10.1 \text{ mmol/l}$  to  $5.9 \text{ mmol/l}$  (RI  $6.1\text{--}12 \text{ mmol/l}$ ), creatinine kinase activity had increased to  $5704 \text{ U/l}$  and ammonia had decreased to  $239 \mu\text{mol/l}$ . Neurological signs, including

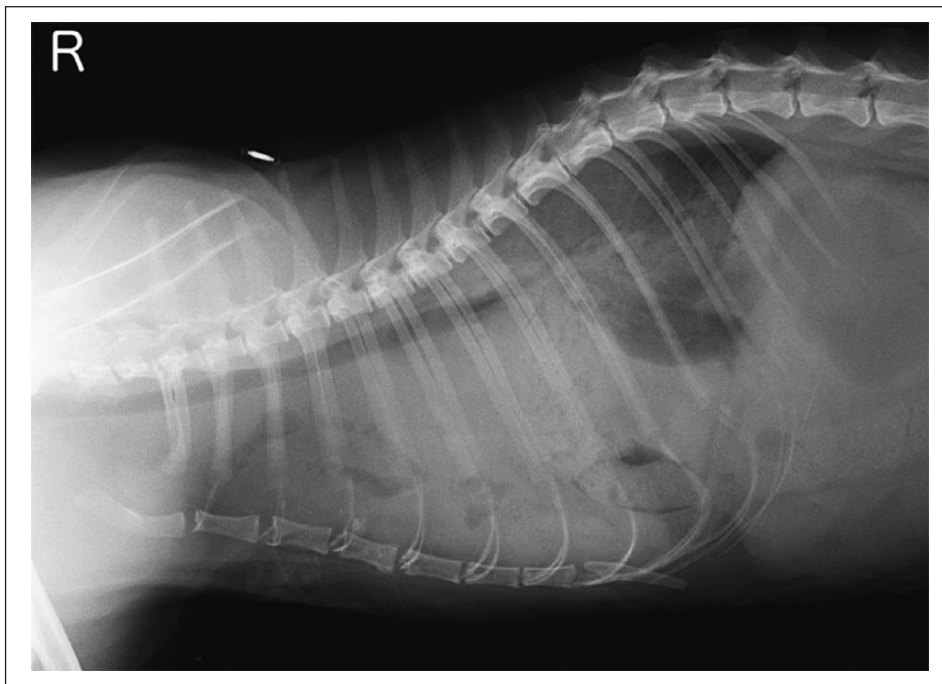
Department of Clinical Science and Services, The Royal Veterinary College, North Mymms, UK

### Corresponding author:

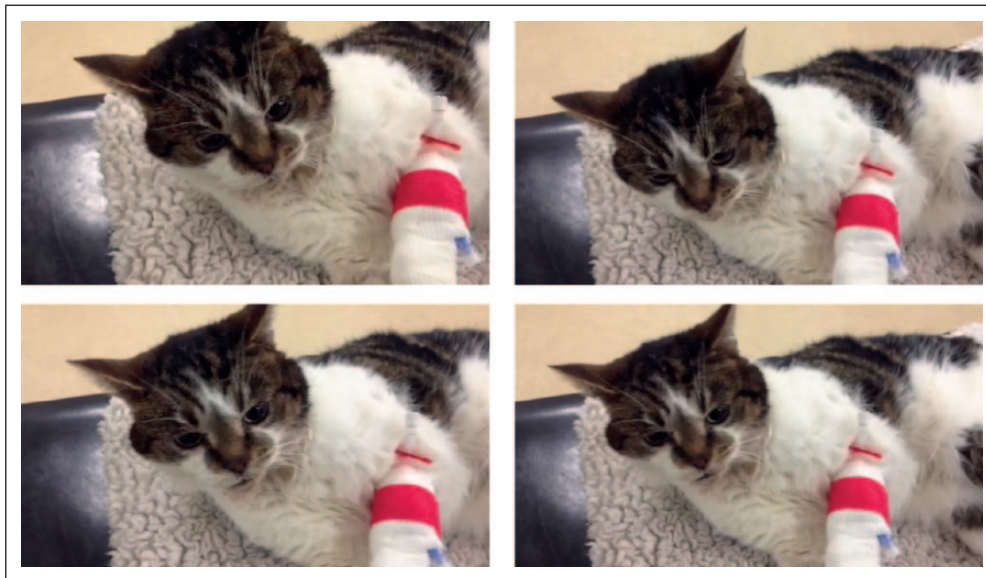Dominic Barfield BSc, BVSc, MVetMed, DACVECC, MRCVS, Department of Clinical Science and Services, The Royal Veterinary College, Hawkshead Lane, North Mymms, AL9 7TA, UK  
 Email: dbarfield@rvc.ac.uk



Creative Commons CC-BY-NC: This article is distributed under the terms of the Creative Commons Attribution-NonCommercial 3.0 License (<http://www.creativecommons.org/licenses/by-nc/3.0/>) which permits non-commercial use, reproduction and distribution of the work without further permission provided the original work is attributed as specified on the SAGE and Open Access page (<http://www.uk.sagepub.com/aboutus/openaccess.htm>).



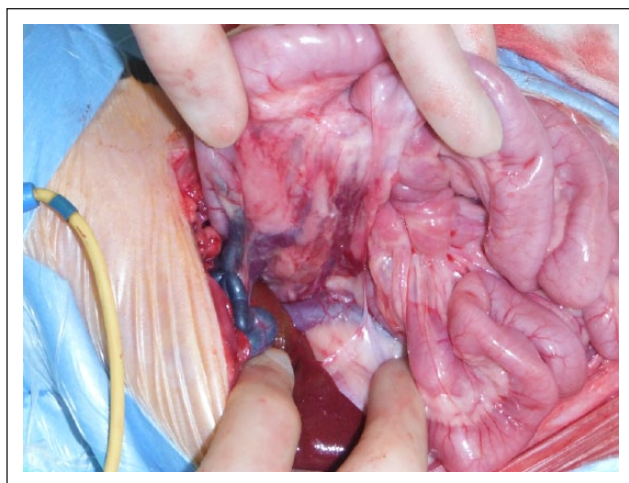
**Figure 1** Right lateral radiograph showing diaphragmatic rupture



**Figure 2** Focal seizure demonstrating the cat's facial twitching (see also Video 1 in the Supplementary material)

marked head pressing, persisted but did not deteriorate further over the following 24 h. The respiratory rate increased overnight and respiratory effort had markedly increased. Therefore, an exploratory laparotomy was performed to address the chronic diaphragmatic rupture on the second day following admission. It was suspected that the clinical signs of the cat were due to hepatic encephalopathy (HE) from multiple acquired portosystemic shunts (MAPSS) secondary to portal hypertension.

Further imaging was discussed with the clinicians involved; however, it was deemed that the diaphragmatic rupture required repairing and therefore exploratory surgery should be able to fix the problem and identify if our suspicions were correct. Abdominal ultrasound is not as sensitive as computer tomography angiography to assess the presence of shunts; however, both imaging modalities would have contributed to the cat's morbidity and cost of therapy.



**Figure 3** Multiple acquired portosystemic shunts

Exploratory laparotomy revealed a 3 cm radial tear in the left, ventral diaphragm. The jejunum and ileum, ileocaecocolic junction, ascending and transverse colon, and the left medial and left lateral liver lobes were within the thoracic cavity. The left medial and lateral liver lobes were markedly atrophied. The right side of the liver appeared grossly normal and remained within the abdominal cavity. The pancreas was displaced cranially by the herniated organs and looked markedly fibrosed. The portal vein was markedly dilated caudal to a point where it was constricted by the displaced and fibrosed right pancreatic limb. Multiple acquired shunts were observed in this region between the portal vein and the caudal vena cava (Figure 3). The diaphragmatic rupture was enlarged and all abdominal organs returned to their normal position in the abdominal cavity. The diaphragm defect was repaired using two metric PDS II (Ethicon) in a simple continuous suture pattern. The lungs were gently re-expanded to a pressure  $<18$  cmH<sub>2</sub>O, to avoid potential re-expansion injury. This left a small-volume pneumothorax that was left to reabsorb slowly. The abdomen was lavaged and closed in a routine fashion.

Postoperative recovery was uneventful, with respiratory rate and effort returning to normal, and the cat resumed eating the next day. Neurological signs, including circling, head pressing, twitching and noise sensitivity, persisted and slowly improved by discharge on day 7. On day 5, ammonia had decreased to 87  $\mu\text{mol/l}$  and there was mild hypoalbuminaemia (25.8 g/l; RI 28.0–42.0 g/l). The cat discharged with potentiated amoxicillin (Kesium, 75 mg PO q12h; Alstoe), lactulose (5 ml PO q8h), levetiracetam (20 mg/kg PO q8h) and maintained on a highly digestible protein, low copper diet with appropriate amino acid ratios to decrease the production of ammonia (Hills 1/d; Hills Pet Nutrition).

Routine re-examination 14 days postoperatively revealed marked neurological improvement with

resolution of hypersalivation, twitching, seizures, head pressing and circling. The cat demonstrated a mild high stepping gait (see Video 2 in Supplementary material). Hyperammonaemia (101  $\mu\text{mol/l}$ ; RI 0–60), a mild hypoalbuminaemia (24.8 g/l; RI 28.0–42.0) and a mild decrease in blood urea (5.0 mmol/l; RI 6.1–12.0) was noted.

Over the subsequent months the cat's progress was monitored by e-mail updates with the owner. There was no further seizure activity and it was weaned off levetiracetam, antibiotics and lactulose. The cat remained on the high-quality protein diet. Five months after being off all medications, a bile acid stimulation test performed at the local veterinary practice showed a prestimulation level of 13.7  $\mu\text{mol/l}$  (RI 0–15  $\mu\text{mol/l}$ ) and a poststimulation level of 12.9  $\mu\text{mol/l}$ . Alanine transaminase activity was mildly elevated (35 U/l; RI 0–20 U/l) as was cholesterol (6.6 mmol/l; RI 1.9–3.9 mmol/l) but liver enzyme activities, urea and albumin levels were all within normal limits. Nine months after referral the cat was continuing to do well and was reported to be clinically normal by the owner.

To our knowledge, this is the first reported case of MAPSS secondary to a diaphragmatic rupture in a cat; and, to date, there have been no reported cases in dogs. Chronic diaphragmatic hernia has been defined as  $>2$  weeks' duration in a series of 16 cats.<sup>1</sup> In that series the liver had herniated in 11/16 cats, although there were no reports of any neurological signs as a presenting complaint. One cat did have its right medial liver lobe resected owing to fibrosis but there was no mention of any MAPSS. Another study looking at 34 cats with acute and chronic traumatic diaphragmatic rupture similarly did not report any presenting neurological signs, with 28 cats having the liver herniate into the thorax and no MAPSS.<sup>2</sup> There are other studies that similarly comment on the liver herniating into the thorax following acute and chronic diaphragmatic rupture, without neurological signs or MAPSS.<sup>3–5</sup> It has been reported in two cats that a chronic diaphragmatic rupture lead to extrahepatic biliary obstruction, which had successful outcomes following repair of the hernia.<sup>6</sup> MAPSS are rarely reported in cats, with only sporadic case reports in the literature, including, more recently, two cats with hepatic fibrosis and two cats with bridging portal fibrosis.<sup>7,8</sup> MAPSS are formed as a result of portal hypertension and can also be seen in cats following attenuation or ligation of a single extrahepatic portosystemic shunt, or from any increase in portal hypertension. Small and multiple portocaval collateral vessels that have a lower pressure than the portal vein develop to divert portal blood flow away from the liver to lower portal pressure. The cause of the portal hypertension in this case was due to strangulation of the portal vein by the herniated left medial and lateral liver lobes and displaced, fibrosed pancreas. Diversion of portal flow blood through MAPSS leads to high levels of waste products (including ammonia) in the systemic

circulation, which causes HE, a syndrome of neurological abnormalities, including facial tremors/focal seizure activity, head pressing and lethargy, as seen in this case. HE is also the most common presentation for a cat with a single, congenital portosystemic shunt (CPSS).<sup>9–15</sup>

In an attempt to make the patient more stable prior to surgery, standard medical management for HE was instigated, including lactulose, antibiotics, and dietary modification, once there was confirmation of the blood ammonia levels.<sup>15</sup> Levetiracetam was used in this patient rather than other antiepileptic drugs (AEDs) owing to controversies surrounding other AEDs (eg, benzodiazepines increasing the effects of HE via their actions on the inhibitory central nervous system neurotransmitter,  $\gamma$ -aminobutyric acid, accentuating its role on the HE complex), concerns over the duration of sedation/anaesthetic effect due to the poor hepatic function of other AEDs (eg, phenobarbital) and any respiratory compromise from the profound sedation of some AEDs (eg, phenobarbital and propofol). Levetiracetam has also been shown in humans and dogs not to undergo hepatic metabolism and is mostly renally excreted unchanged.<sup>16,17</sup> Although the use of levetiracetam per rectum has not, to our knowledge, been investigated in cats, the pharmacokinetics have recently been reported to achieve the target range in healthy dogs.<sup>18</sup>

Although preoperative diagnostic imaging could have provided additional information regarding the presence of MAPSS, owing to the respiratory compromise of the patient and the diaphragmatic rupture, it was not considered in the immediate best interest of the patient, and intraoperative mesenteric portovenography is available at our institution.

Reduction and replacement of abdominal organs and diaphragm repair is likely to have removed ongoing compression of the portal vein caused by tension/stretching in the region but it was unknown at the time of surgery whether the fibrosis associated with the pancreas would continue to cause some portal vein compression and/or whether persistence of already formed MAPSS would result in continued HE. It is therefore interesting to note that the cat's neurological signs eventually resolved completely after surgery and that all medications were stopped. A bile acid stimulation test is highly sensitive for the presence of shunting of any type (MAPSS or CPSS) so a normal test result 5 months after finishing all medication suggests the MAPSS seen at surgery had regressed or were present but functionally insignificant.<sup>19</sup>

## Conclusions

This case report describes a unique cause of MAPSS in a cat. MAPSS should therefore be considered in cats with a diaphragmatic rupture and displaying neurological signs. The report also documents a successful clinical and biochemical outcome following surgical repair of the

diaphragmatic rupture, suggesting resolution of MAPSS is possible if the underlying cause is treated.

**Supplementary material** The following files are available: Video 1: Shortly after presentation facial twitches consistent with a hippocampal seizure. *Courtesy of Steve Murphy RVN*

Video 2: Fourteen days postsurgery, showing mild high stepping gait

**Acknowledgements** We thank Ozlem Cosar BSc (Hons) BVetMed MRCVS at Wood Street Veterinary Hospital, Barnet, for referring the case, and to Brian Cox and Richard Lam for assistance with the images.

**Funding** The authors received no specific grant from any funding agency in the public, commercial or not-for-profit sectors for the preparation of this Case report.

**Conflict of interest** The authors do not have any potential conflicts of interest to declare.

## References

- 1 Minihan AC, Berg J and Evans KL. **Chronic diaphragmatic hernia in 34 dogs and 16 cats.** *J Am Anim Hosp Assoc* 2004; 40: 51–63.
- 2 Schmiedt CW, Tobias KM and Stevenson MA. **Traumatic diaphragmatic hernia in cats: 34 cases (1991–2001).** *J Am Vet Med Assoc* 2003; 222: 1237–1240.
- 3 Wilson GP, Newton CD and Burt JK. **A review of 116 diaphragmatic hernias in dogs and cats.** *J Am Vet Med Assoc* 1971; 159: 1142
- 4 Stokhof AA. **Diagnosis and treatment of acquired diaphragmatic hernia by thoracotomy in 49 dogs and 72 cats.** *Vet Q* 1986; 8: 177.
- 5 Boudrieau SJ and Muir WW. **Pathophysiology of traumatic diaphragmatic hernia in dogs.** *Compend Contin Educ Pract Vet* 1987; 9: 379–385.
- 6 Cornell KK, Jakovljevic S, Waters DJ, et al. **Extrahepatic biliary obstruction secondary to diaphragmatic hernia in two cats.** *J Am Anim Hosp Assoc* 1993; 29: 502.
- 7 Zandvliet MMJM, Szatmári V, van den Ingh T, et al. **Acquired portosystemic shunting in 2 cats secondary to congenital hepatic fibrosis.** *J Vet Intern Med* 2005; 19: 765–767.
- 8 Langdon P, Cohn LA, Kreeger JM, et al. **Acquired portosystemic shunting in two cats.** *J Am Anim Hosp Assoc* 2002; 38: 21–27.
- 9 Barnes HL, Chrisman CL, Mariani CL, et al. **Clinical signs, underlying cause, and outcome in cats with seizures: 17 cases (1997–2002).** *J Am Vet Med Assoc* 2004; 225: 1723–1726.
- 10 Birchard SJ and Sherding RG. **Feline portosystemic shunts.** *Compend Contin Educ Pract Vet* 1992; 14: 1295–1301.
- 11 Lipscomb VJ, Lee KC, Lamb CR, et al. **Association of mesenteric portovenographic findings with outcome in cats receiving surgical treatment for single congenital portosystemic shunts.** *J Am Vet Med Assoc* 2009; 234: 221–228.
- 12 Havig M and Tobias KM. **Outcome of ameroid constrictor occlusion of single congenital extrahepatic portosystemic shunts in cats: 12 cases (1993–2000).** *J Am Vet Med Assoc* 2002; 220: 337–341.

- 13 Lipscomb VJ, Jones HJ and Brockman DJ. **Complications and long-term outcomes of the ligation of congenital portosystemic shunts in 49 cats.** *Vet Rec* 2007; 160: 465–470.
- 14 Lamb CR, Forster-van Hijfte MA, White RN, et al. **Ultrasonographic diagnosis of congenital portosystemic shunt in 14 cats.** *J Small Anim Pract* 1996; 37: 205–209.
- 15 Tivers M and Lipscomb VJ. **Congenital portosystemic shunts in cats. Investigation, diagnosis and stabilization.** *J Feline Med Surg* 2011; 13: 173–184.
- 16 Patsalos PN. **Pharmacokinetic profile of levetiracetam: toward ideal characteristics.** *Pharmacol Ther* 2000; 85: 77–85.
- 17 Isoherranen N, Yagen B, Soback S, et al. **Pharmacokinetics of levetiracetam and its enantiomer (R)- $\alpha$ -ethyl-2-oxo-pyrrolidine acetamide in dogs.** *Epilepsia* 2001; 42: 825–830.
- 18 Peters RK, Schubert T, Clemmons R, et al. **Levetiracetam rectal administration in healthy dogs.** *J Vet Intern Med* 2014; 28: 504–509.
- 19 Ruland K, Fischer A and Hartmann K. **Sensitivity and specificity of fasting ammonia and serum bile acids in the diagnosis of portosystemic shunts in dogs and cats.** *Vet Clin Pathol* 2010; 39: 57–64.