



## Evaluation of thromboelastography in two factor XII-deficient cats

Authors: Blois, Shauna L, Holowaychuk, Marie K, and Wood, R Darren

Source: Journal of Feline Medicine and Surgery Open Reports, 1(1)

Published By: SAGE Publishing

URL: <https://doi.org/10.1177/2055116915585025>

---

BioOne Complete ([complete.BioOne.org](http://complete.BioOne.org)) is a full-text database of 200 subscribed and open-access titles in the biological, ecological, and environmental sciences published by nonprofit societies, associations, museums, institutions, and presses.

Your use of this PDF, the BioOne Complete website, and all posted and associated content indicates your acceptance of BioOne's Terms of Use, available at [www.bioone.org/terms-of-use](http://www.bioone.org/terms-of-use).

Usage of BioOne Complete content is strictly limited to personal, educational, and non - commercial use. Commercial inquiries or rights and permissions requests should be directed to the individual publisher as copyright holder.

---

BioOne sees sustainable scholarly publishing as an inherently collaborative enterprise connecting authors, nonprofit publishers, academic institutions, research libraries, and research funders in the common goal of maximizing access to critical research.



# Evaluation of thromboelastography in two factor XII-deficient cats

Shauna L Blois, Marie K Holowaychuk and R Darren Wood

*Journal of Feline Medicine and Surgery*  
*Open Reports*  
 1–4

© The Author(s) 2015  
 Reprints and permissions:  
[sagepub.co.uk/journalsPermissions.nav](http://sagepub.co.uk/journalsPermissions.nav)  
 DOI: 10.1177/2055116915585025  
[jfmsopenreports.com](http://jfmsopenreports.com)



## Abstract

**Case summary** The current report describes thromboelastography (TEG) findings in two cats with factor XII (FXII) deficiency. The first cat was diagnosed with bilateral perinephric pseudocysts; hemostatic testing was performed prior to performing renal aspirates. The second cat was healthy; hemostatic testing was performed prior to inclusion into a research project. Both cats had markedly prolonged partial thromboplastin times and hypocoagulable TEG tracings when samples were activated with kaolin. However, when tissue factor (TF) was used to activate the sample, both cats had normal-to-hypercoagulable TEG tracings. The cats each had a subnormal FXII level.

**Relevance and novel information** TEG is becoming widely used to investigate hemostasis in veterinary patients, and TEG results in cats with FXII deficiency have not been previously reported. FXII deficiency is the most common hereditary hemostatic defect in cats. While FXII deficiency does not lead to in vivo hemorrhagic tendencies, it can lead to marked prolongation in activated partial thromboplastin and activated clotting times, and cannot be differentiated from true hemorrhagic diatheses without measuring individual factor activity. With the increased use of TEG to evaluate hemostasis in veterinary patients, it is important to recognize the effects of FXII deficiency on this testing modality. The finding of a hypocoagulable kaolin-activated TEG tracing and a concurrent normal TF-activated TEG tracing in samples should prompt clinicians to consider ruling out FXII deficiency.

**Accepted:** 1 November 2014

## Introduction

Factor XII (FXII) deficiency, an autosomal recessive disorder, is the most common hereditary hemostatic defect in cats.<sup>1–4</sup> FXII initiates coagulation and subsequent factor XI activation on artificial surfaces in vitro, but in vivo clot formation is thought to be largely dependent on factor VII and tissue factor (TF) activation.<sup>5</sup> As a result, even severe FXII deficiency does not lead to in vivo hemorrhagic tendencies. However, deficiencies in FXII can lead to marked prolongation in partial thromboplastin time (PTT) and activated clotting time, and cannot be differentiated from true hemorrhagic diatheses without measuring individual factor activity. Global hemostatic assays such as thromboelastography (TEG) are becoming more common in veterinary research and clinical settings, but the impact of FXII deficiency on the results of such assays is not reported in cats. The current report describes the results of kaolin-activated and TF-activated TEG in FXII-deficient cats (Figure 1).

## Case description

An 8-year-old neutered male domestic shorthair cat was presented owing to acute-onset lethargy. Physical

examination revealed marked dehydration, a grade III/VI left parasternal heart murmur and pain elicited during abdominal palpation. Complete blood count revealed a normal hematocrit (0.44 l/l; reference interval [RI] 0.28–0.49 l/l). Abnormal laboratory findings included a mild leukocytosis ( $15.6 \times 10^3/\mu\text{l}$ ; RI  $4.2\text{--}13.0 \times 10^3/\mu\text{l}$ ) and a severe azotemia (urea 202 mg/dl; RI 17–34 mg/dl, creatinine 14.9 mg/dl; RI: 0.7–2.5 mg/dl), hyperphosphatemia (11.8 mg/dl; RI 2.5–7.1 mg/dl) and hypermagnesemia (4.6 mEq/l; RI 1.6–2.2 mEq/l). Urinalysis from a cystocentesis sample revealed a urine specific gravity of 1.015, a pH of 5.5, 1+ Multistix protein, 2+ blood, 3–5 red blood cells/high-power field, and occasional leukocytes and epithelial squamous cells. Abdominal

Department of Clinical Studies, Ontario Veterinary College, Guelph, ON, Canada

### Corresponding author:

Shauna L Blois DVM, DVSc, DACVIM, Department of Clinical Studies, Ontario Veterinary College, 50 Stone Road, Guelph, ON, N1G 2W1, Canada  
 Email: [sblois@uoguelph.ca](mailto:sblois@uoguelph.ca)



Creative Commons CC-BY-NC: This article is distributed under the terms of the Creative Commons Attribution-NonCommercial 3.0 License (<http://www.creativecommons.org/licenses/by-nc/3.0/>) which permits non-commercial use, reproduction and distribution of the work without further permission provided the original work is attributed as specified on the SAGE and Open Access page (<http://www.uk.sagepub.com/aboutus/openaccess.htm>).

ultrasound revealed a small misshapen left kidney with a large volume of echogenic fluid within the capsule, mild right renomegaly with a mild-to-moderate amount of intracapsular fluid, hyperechoic tissues surrounding the right kidney and a mild volume of peritoneal effusion.

Prior to performing renal aspirates, coagulation times were measured and prothrombin time (PT) was 16 s (RI 15–22 s) but partial thromboplastin time (PTT) was >500 s (RI 65–119 s). Additional citrated blood was collected from a jugular venepuncture directly into a syringe and transferred to a 3.2% citrate tube to measure FXII activity and perform a kaolin- and TF-activated TEG. FXII levels were measured using a coagulometric assay with human FXII deficient plasma and a standard curve generated with lyophilized pooled cat plasma. FXII activity was 15% (RI 60–140%), consistent with a FXII deficiency. Kaolin-activated TEG exhibited delayed clot formation characterized by markedly prolonged reaction (R) and kappa ( $\kappa$ ) times, and a decreased angle compared with normal (Table 1; Figures 1a and 2), whereas the TF-activated TEG revealed a normal to mildly hypercoagulable tracing characterized by a mildly increased maximum amplitude (Table 1; Figure 1b).

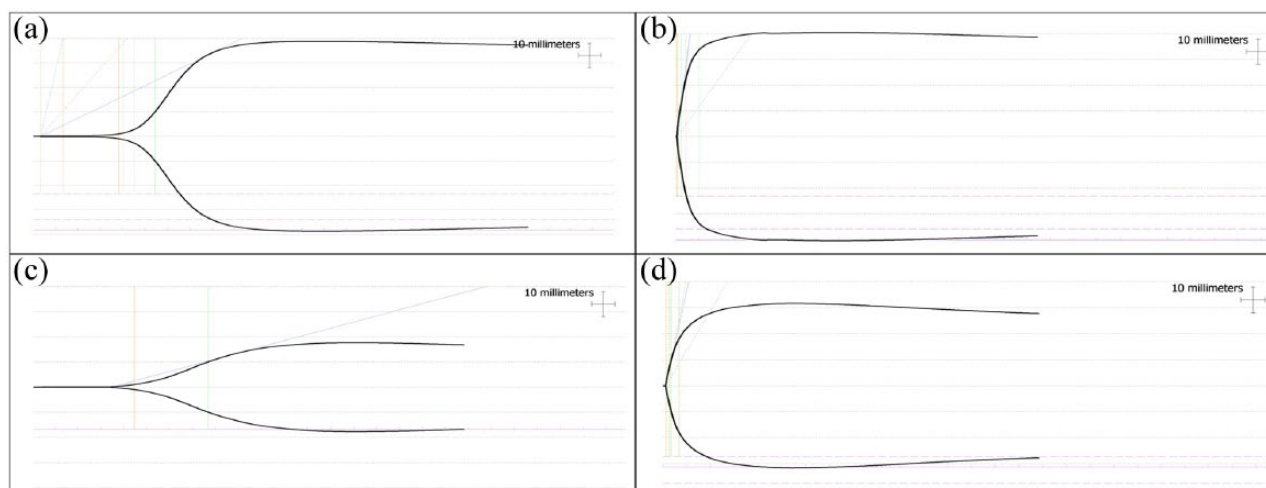
Fluid was drained percutaneously from beneath both renal capsules, and aspirates of the right kidney were performed without evidence of hemorrhage. The next day, an ultrasound examination confirmed re-accumulation of the subcapsular fluid bilaterally and the cat was humanely euthanized. A post-mortem examination revealed bilateral perinephric pseudocysts, pyelectasia with concretions, renal fibrosis with cortical hemorrhage, and partial obstruction of the ureters with

proximal ureteral dilation, as well as bilateral parathyroid enlargement.

A 7-year-old spayed female domestic shorthair cat was presented for inclusion in the study as a healthy control. The cat was apparently healthy at home and physical examination was unremarkable. Complete blood count revealed normal parameters, including hematocrit (0.35 l/l). Serum biochemistry profile and PT results were within the RIs; however, the PTT was markedly prolonged (173 s; RI 24.2–34.9 s). FXII deficiency was suspected; further hemostatic testing was performed. Blood was collected from a jugular venepuncture directly into a syringe and transferred to a 3.2% citrate tube. The kaolin-activated TEG exhibited delayed clot formation and decreased clot strength, characterized by markedly prolonged R and  $\kappa$  times, and decreased angle and maximum amplitude (MA) (Table 1; Figure 1c), whereas the TF-activated TEG was normal (Table 1; Figure 1d). FXII activity was 7%, consistent with a FXII deficiency.

## Discussion

To our knowledge, TEG results from cats with FXII deficiency have not previously been reported. Both cats in this report had normal-to-hypercoagulable TEG results when activated with TF. However, the kaolin-activated TEG tracings in both cats showed delayed clot onset, as well as a mildly decreased clot strength in the second cat. TEG is becoming widely utilized in the diagnosis of hemostatic disorders, and can be performed on citrated blood with or without the addition of activators such as kaolin or TF. The addition of activators decreases TEG variability in some species, although this has been an inconsistent finding in studies of healthy cats.<sup>6,7</sup> Kaolin activates *in vitro* coagulation primarily via the intrinsic

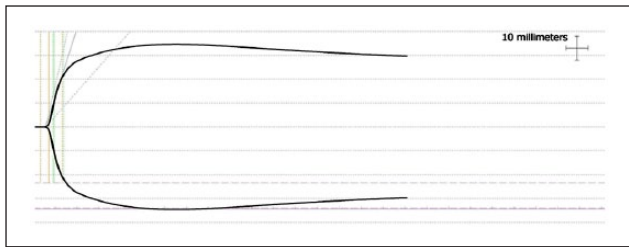


**Figure 1** (a) Kaolin-activated thromboelastography (TEG) and (b) tissue factor-activated TEG tracings from an azotemic cat with bilateral perinephric pseudocysts and factor XII (FXII) deficiency; (c) kaolin-activated TEG and (d) tissue factor-activated TEG tracings from a normal cat with FXII deficiency. Part (d) is considered a normal tissue factor-activated tracing

**Table 1** Selected kaolin and tissue factor (TF)-activated thromboelastography (TEG) results for two cats with factor XII deficiencies

	Case 1 kaolin-activated TEG	Case 2 kaolin-activated TEG	RI kaolin-activated TEG	Case 1 TF-activated TEG	Case 2 TF-activated TEG	RI TF-activated TEG
R (mins)	19.1	22.2	2.0–6.0	0.3	0.6	0–2.0
$\kappa$ (mins)	8.1	16.1	1.0–3.0	0.8	1.1	0–5.0
Alpha (degrees)	23.9	13.8	48.0–75.0	82.1	76.4	52.0–82.0
MA (mm)	76.6	33.7	46.0–64.0	80.5	62.6	46.0–72.0
LY60 (%)	0.7	0	0–15.0	1.1	4.1	0–15.0

RI = reference interval; R = reaction time;  $\kappa$  = clotting time; MA = maximum amplitude; LY60 = lysis value at 60 mins

**Figure 2** Kaolin-activated thromboelastography from a normal cat with normal partial thromboplastin time and presumed normal factor XII concentration

or contact-activated pathway, while TF activates *in vitro* coagulation via the extrinsic or FVII:TF pathway.<sup>8</sup> This explains the difference between the TEG tracings in the cats with FXII deficiency described herein.

FXII deficiencies appear to cause a range of TEG abnormalities in human samples reliant on contact activation, from prolonged R times alone to overall hypocoagulable tracings.<sup>9–11</sup> Similar results have been reported in canine studies when corn trypsin inhibitor is used to inhibit FXII activity.<sup>5,12</sup>

The degree of FXII deficiency appears to have an influence on the magnitude of abnormal TEG results in humans. At very low FXII concentrations (<1% activity), TEG samples that were either inactivated or activated with celite (a contact activator similar to kaolin) did not clot within 120 mins, while a kaolin-activated sample showed a prolonged time to clot onset and decreased clot strength.<sup>10,11</sup> However, as FXII activity was progressively increased in plasma samples in one study, the TEG variables became less hypocoagulable.<sup>11</sup> In the present report, the cat with the lower FXII concentration (case 2; FXII 7%) had a longer R time and  $\kappa$ , and a lower angle than case 1, which had a FXII concentration of 15%. Similar to humans, decreasing levels of FXII in cats may correlate with magnitude of TEG abnormalities, but a larger number of FXII-deficient cats would need to be analyzed to support this observation. The PTT results for these cases did not appear to be related to the magnitude of FXII deficiency, but this is difficult to interpret as the

coagulation profiles were performed on two different analyzers.

In contrast to contact-activated TEG samples, human samples activated with TF had similar TEG results to control plasma, regardless of the magnitude of FXII deficiency.<sup>10,11</sup> This was also apparent for the two cats in the present report. Interestingly, case 1 had an increased MA on both the kaolin and TF-activated TEG tracings, which may be consistent with hypercoagulability.<sup>13</sup> It is unknown whether this cat's underlying disease contributed to this documented hypercoagulability. Perinephric pseudocysts have not been previously associated with hypercoagulability.<sup>14</sup> However, bilateral pyelonephritis could not be ruled out on post-mortem examination. The presence of pyelonephritis could have caused hypercoagulability in this patient, as infection and inflammation have been previously associated with thromboembolism in cats.<sup>15</sup> Alternatively, pre-analytical factors such as a traumatic blood draw could prematurely activate *in vitro* hemostasis and lead to a hypercoagulable TEG tracing, although such effects were mild in a recent canine study.<sup>16</sup> However, venepuncture performed on this cat was reported to be atraumatic.

The TEG results for the above cases were compared with institutional RIs, created from the results of 20 cats deemed healthy after normal physical examination, complete blood count, serum biochemical profile and urinalysis. All cats included in the RI had normal coagulation profiles (PT, PTT and fibrinogen concentration), but individual coagulation factor analysis was not performed. Samples used in creation of the RIs were collected from jugular venepuncture into a plain syringe, then directly transferred into a 3.2% citrated blood tube. None of the TEG samples reported were performed in duplicate, a potential limitation of this report. While TEG results appear to have low analytic variability in dogs, the same has not been investigated in cats.<sup>17</sup>

## Conclusions

While FXII deficiency is the most common factor deficiency in cats, it requires definitive documentation with individual factor activity analysis. However, with the

increased use of TEG to assess hemostasis in veterinary patients, it is important to recognize the abnormalities that common factor deficiencies can create. This case report provides preliminary evidence that FXII deficiency can cause a prolonged time to clot onset, such as prolonged R time and  $\kappa$ , in kaolin-activated TEG samples. A lower rate of clot formation or decreased clot strength, represented by a low angle or MA, respectively, may also be present in these samples. In the light of a concurrent normal TF-activated TEG tracing, such abnormalities would indicate a defect in the contact-activation pathways. In cats, such a defect would most commonly be a FXII deficiency, and should prompt clinicians to rule out FXII deficiency. Further research with larger numbers of cats is needed to determine the utility of TEG for screening for FXII deficiency in cats, and to examine the relationship between FXII concentration and TEG results. Additionally, when creating kaolin-activated TEG reference intervals in cats, screening for FXII deficiency should be considered.

**Funding** The authors received no specific grant from any funding agency in the public, commercial or not-for-profit sectors for the preparation of this case report.

**Conflict of interest** The authors do not have any potential conflicts of interest to declare.

## References

- Brooks M and DeWilde L. **Feline factor XII deficiency.** *Comp Cont Educ Pract Vet* 2006; 28: 148.
- Green RA and White F. **Feline factor XII (Hageman) deficiency.** *Am J Vet Res* 1977; 38: 893–895.
- Kier A, Bresnahan J, White F, et al. **The inheritance pattern of factor XII (Hageman) deficiency in domestic cats.** *Can J Comp Med* 1980; 44: 309.
- Peterson JL, Couto CG and Wellman ML. **Hemostatic disorders in cats: a retrospective study and review of the literature.** *J Vet Intern Med* 1995; 9: 298–303.
- Smith SA, McMichael M, Galligan A, et al. **Clot formation in canine whole blood as measured by rotational thromboelastometry is influenced by sample handling and coagulation activator.** *Blood Coagul Fibrinolysis* 2010; 21: 692–702.
- Marschner CB, Bjornvad CR, Kristensen AT, et al. **Thromboelastography results on citrated whole blood from clinically healthy cats depend on modes of activation.** *Acta Vet Scand* 2010; 52: 38.
- Banerjee A, Blois SL and Wood RD. **Comparing citrated native, kaolin-activated, and tissue factor-activated samples and determining intraindividual variability for feline thromboelastography.** *J Vet Diagn Invest* 2011; 23: 1109–1113.
- Johansson PI, Bochsén L, Andersen S, et al. **Investigation of the effect of kaolin and tissue-factor-activated citrated whole blood, on clot-forming variables, as evaluated by thromboelastography.** *Transfusion* 2008; 48: 2377–2383.
- Pivalizza EG. **Perioperative use of the Thrombelastograph in patients with inherited bleeding disorders.** *J Clin Anesth* 2003; 15: 366–370.
- Pluthero FG, Ryan C, Williams S, et al. **Decreased in vitro thrombin generation and clot stability in human FXII-null blood and plasma.** *Br J Haematol* 2011; 152: 111–112.
- Nielsen V, Cohen B and Cohen E. **Effects of coagulation factor deficiency on plasma coagulation kinetics determined via thrombelastography: critical roles of fibrinogen and factors II, VII, X and XII.** *Acta Anaesthesiol Scand* 2005; 49: 222–231.
- Ralph AG, Brainard BM, Pittman JR, et al. **Effects of rest temperature, contact activation, and sample technique on canine thrombelastography.** *J Vet Emerg Crit Care* 2012; 22: 320–326.
- Goggs R, Brainard B, de Laforcade AM, et al. **Partnership on Rotational ViscoElastic Test Standardization (PROVETS): evidence-based guidelines on rotational viscoelastic assays in veterinary medicine.** *J Vet Emerg Crit Care* 2014; 24: 1–22.
- Ochoa VB, DiBartola SP, Chew DJ, et al. **Perinephric pseudocysts in the cat: a retrospective study and review of the literature.** *J Vet Int Med* 1999; 13: 47–55.
- Mittleman E, Luff J, Drobatz K, et al. **Feline non-cardiogenic thromboembolic disease: a retrospective study of 48 cases (1991–2002).** *J Vet Emerg Crit Care* 2004; 14: S1–S17.
- Garcia-Pereira BL, Scott MA, Koenigshof AM, et al. **Effect of venipuncture quality on thromboelastography.** *J Vet Emerg Crit Care* 2012; 22: 225–229.
- Wiinberg B, Jensen AL, Kjelgaard-Hansen M, et al. **Study on biological variation of haemostatic parameters in clinically healthy dogs.** *Vet J* 2007; 174: 62–68.