



Blepharitis due to *Cryptococcus neoformans* in a cat from northern Portugal

Authors: Pimenta, Paulo, Alves-Pimenta, Sofia, Barros, João, Pereira, Maria J, Maltez, Luís, et al.

Source: Journal of Feline Medicine and Surgery Open Reports, 1(2)

Published By: SAGE Publishing

URL: <https://doi.org/10.1177/2055116915593963>

BioOne Complete (complete.BioOne.org) is a full-text database of 200 subscribed and open-access titles in the biological, ecological, and environmental sciences published by nonprofit societies, associations, museums, institutions, and presses.

Your use of this PDF, the BioOne Complete website, and all posted and associated content indicates your acceptance of BioOne's Terms of Use, available at www.bioone.org/terms-of-use.

Usage of BioOne Complete content is strictly limited to personal, educational, and non - commercial use. Commercial inquiries or rights and permissions requests should be directed to the individual publisher as copyright holder.

BioOne sees sustainable scholarly publishing as an inherently collaborative enterprise connecting authors, nonprofit publishers, academic institutions, research libraries, and research funders in the common goal of maximizing access to critical research.



Blepharitis due to *Cryptococcus neoformans* in a cat from northern Portugal

Journal of Feline Medicine and Surgery
Open Reports
1–4

© The Author(s) 2015
Reprints and permissions:
sagepub.co.uk/journalsPermissions.nav
DOI: 10.1177/2055116915593963
jfmsopenreports.com



Paulo Pimenta¹, Sofia Alves-Pimenta¹, João Barros¹,
Maria J Pereira¹, Luís Maltez³, A Paula Maduro²,
Luís Cardoso³ and Ana C Coelho^{3,4}

Abstract

Case summary We report a clinical case of blepharitis due to *Cryptococcus neoformans* yeasts in a 2-year-old stray cat from northern Portugal (Vila Real) without concurrent naso-ocular signs. Ophthalmological examination revealed mucopurulent discharge from an open wound in the right upper and lower lids. Slit-lamp biomicroscopy showed a normal anterior segment, and intraocular pressure was within the normal reference interval. No fundoscopic alterations were detected in either eye by direct and indirect ophthalmoscopic examination. Cytological examination of an appositional smear showed numerous polymorphic neutrophils and macrophages, together with spherical yeast cells compatible with *Cryptococcus* species. Molecular analysis by means of PCR and restriction fragment length polymorphism identified *C. neoformans* genotype VNI. The cat was treated with itraconazole, and amoxicillin and clavulanic acid, combined with a commercial ear ointment and an imidacloprid/moxidectin spot-on application for bilateral parasitic otitis caused by *Otodectes cynotis*. One month after treatment, the clinical signs were completely resolved. Localised cutaneous lesions, as in the present case, probably result from contamination of cat-scratch injuries with viable encapsulated yeasts.

Relevance and novel information This is, to the best of our knowledge, the first clinical report of feline blepharitis due to *C. neoformans* without concurrent naso-ocular signs. The current findings, together with those from recent reports of the infection in domestic animals, should alert the veterinary community both in Portugal and in Europe to this underdiagnosed disease.

Accepted: 9 February 2015

Introduction

Cryptococcosis is the most common systemic fungal disease in cats worldwide.^{1–4} Infections with *Cryptococcus* species may also occur in several other mammalian species, including dogs and humans, and even in birds and reptiles.^{1,5} Feline cryptococcosis is caused by basidiomycetous encapsulated yeasts of the genus *Cryptococcus* (Tremellomycetes: Tremellaceae) belonging to the *Cryptococcus neoformans*–*Cryptococcus gattii* complex.^{2,4,6–8} Based on molecular characterisation methods, this complex includes eight genotypes (VNI, VNII, VNIII, VNIV, VGI, VGII, VGIII, VGIV) with varying geographical distribution, virulence and antimicrobial susceptibility.^{2,4} The environmental reservoir of *C. neoformans* is usually related to bird faeces, particularly pigeon droppings. However, this yeast has also been found in

decaying trees, wood and plant debris, waterways and soil, all usually contaminated with bird excrement.^{5,9,10}

¹Hospital Veterinário de Trás-os-Montes, Vila Real, Portugal

²Mycology Group, Medical Microbiology Unit, Global Health and Tropical Medicine, Instituto de Higiene e Medicina Tropical, Universidade Nova de Lisboa, Lisbon, Portugal

³Department of Veterinary Sciences, School of Agrarian and Veterinary Sciences, University of Trás-os-Montes e Alto Douro, Vila Real, Portugal

⁴Animal and Veterinary Research Centre, University of Trás-os-Montes e Alto Douro, Vila Real, Portugal

Luís Cardoso and Ana C Coelho contributed equally to this work

Corresponding author:

Paulo Pimenta DVM, MVM, Hospital Veterinário de Trás-os-Montes, Rua de La Lys, 7, 5000-056 Vila Real, Portugal
Email: ppimenta@hvtm.pt



Creative Commons CC-BY-NC: This article is distributed under the terms of the Creative Commons Attribution-NonCommercial 3.0 License (<http://www.creativecommons.org/licenses/by-nc/3.0/>) which permits non-commercial use, reproduction and distribution of the work without further permission provided the original work is attributed as specified on the SAGE and Open Access page (<http://www.uk.sagepub.com/aboutus/openaccess.htm>).

The primary route of infection in cats is the nasal cavity, although, more rarely, transmission can also occur via cutaneous inoculation of fungal forms.^{1,2,6,11} The incubation period varies from months to years, with the source of infection often remaining unknown.^{1,2,6,11,12} The most frequent clinical manifestation of feline cryptococcosis is associated with the nasal form, but the disease can occur in several other distinct clinical forms, with involvement of the central nervous system (CNS), ocular, cutaneous, lymph nodes, and even pulmonary, abdominal and periarticular connective tissues.^{3,4} Ocular lesions are a common manifestation of systemic cryptococcosis (observed in about one-third of clinical cases), primarily manifesting as multifocal chorioretinitis.^{1,13}

A definitive diagnosis of cryptococcosis can be established using cytological examination, serology for the detection of antibodies (cryptococcal antigen latex agglutination test), fungal culture, histopathology and PCR.^{1,2,4,6} PCR allows identification of the implicated species and genotype.⁶ The treatment of feline cryptococcosis usually combines surgical excision of localised granulomas and administration of antifungal azole drugs, such as fluconazole, itraconazole and ketoconazole. However, cats with CNS infection and/or systemic disease often need treatment with amphotericin B plus flucytosine.^{2,6,14} Therapy should be maintained until at least 2–4 months after the resolution of clinical signs.⁶ The prognosis for feline cryptococcosis is good to excellent when the disease is diagnosed in the early stages.^{1,5,12} Nevertheless, CNS involvement negatively affects prognosis.²

Here, we describe, to the best of our knowledge, the first published clinical case of cryptococcosis in domestic animals in Portugal, which simultaneously represents, to the best of our knowledge, the first clinical case of blepharitis due to *C neoformans* without concurrent nasocular signs in a cat.

Case description

A 2-year-old male domestic shorthair stray cat was presented to the Hospital Veterinário de Trás-os-Montes (Vila Real, Portugal) with an open wound of the upper and lower lids of the right eye (Figure 1), and a history of facial pruritus.

On physical examination, fever and bilateral parasitic otitis due to *Otodectes cynotis* were detected. In addition, ophthalmological examination revealed mucopurulent discharge from the upper and lower lids. Slit-lamp biomicroscopy showed a normal anterior segment. Intraocular pressure, measured by applanation tonometry (Tono-Pen Vet; Medtronic Solan), was within the normal reference interval (10 mmHg in OD and 11 mmHg in OS; reference interval 20–25 mmHg). No fundoscopic alterations were detected in either eye by direct and indirect ophthalmoscopic examination. Based on these findings, blepharitis was diagnosed. The differential

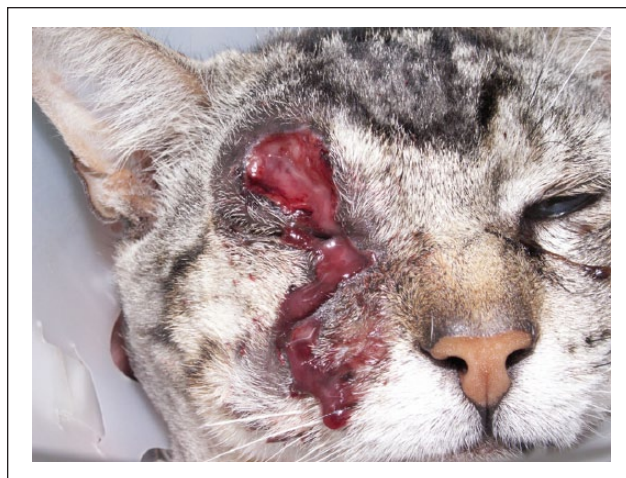

Figure 1 Mucopurulent discharge from an open wound in the right upper and lower lids

diagnoses included bacterial, parasitic, viral, fungal and allergic blepharitis, or an eyelid neoplasia. Complete blood cell count revealed a leukocytosis with neutrophilia with left shift, and the biochemical profile tests were within normal range. A serum sample was positive for feline leukemia virus (FeLV) antigen and antibodies to feline immunodeficiency virus (FIV), using a commercial enzyme-linked immunosorbent assay test (Urinovet; Bionote) for both viruses.

Cytological examination of a Diff-Quik-stained appositional smear showed numerous polymorphic neutrophils and macrophages, together with spherical yeast cells compatible with *Cryptococcus* species (Figure 2). Direct examination of the pathological sample performed with Gram staining confirmed a few spherical and ovoid encapsulated yeasts. The sample was then inoculated into three Sabouraud dextrose (Liofilchem) and potato dextrose (Difco) agar plates.¹ Plates were sealed with parafilm and invertedly incubated in the dark at 37°C. After 10 days, small colonies were noted to be growing on both media. Isolates were confirmed in fresh preparations and with Hiss stainings (Figure 3). Stained colonies showed polymorphic and encapsulated yeasts compatible with *Cryptococcus* species. India ink-stained smears of the isolates revealed negatively coloured capsules compatible with *Cryptococcus* species. DNA extracted from culture was amplified by PCR with specific primer URA5 followed by restriction fragment length polymorphism (RFLP) analysis, with the restriction enzymes *Sau96I* and *HhaI* in a double digest. The molecular type was determined by comparing the obtained URA5 RFLP pattern with the respective standard patterns for each molecular type, allowing the identification of *C neoformans* genotype VNI.¹⁵

Upon diagnosis of cryptococcosis, the cat was treated with itraconazole (5 mg/kg, Itrafungol; Esteve Veterinaria) combined with amoxicillin and clavulanic

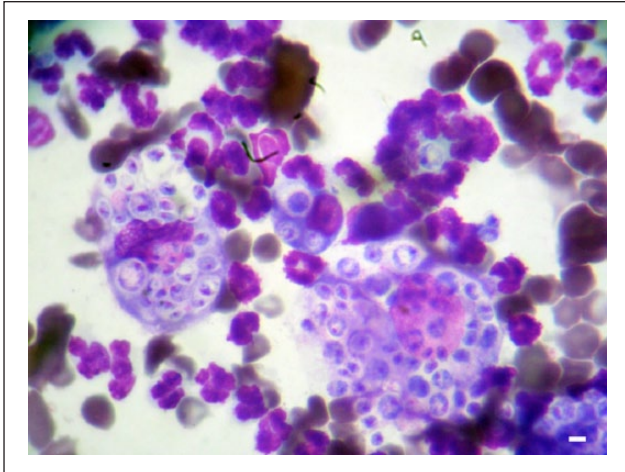


Figure 2 Appositional smear showing numerous polymorphic neutrophils and spherical yeast cells with a prominent unstained capsule compatible with *Cryptococcus* species (Diff-Quik; scale bar = 20 μ m)

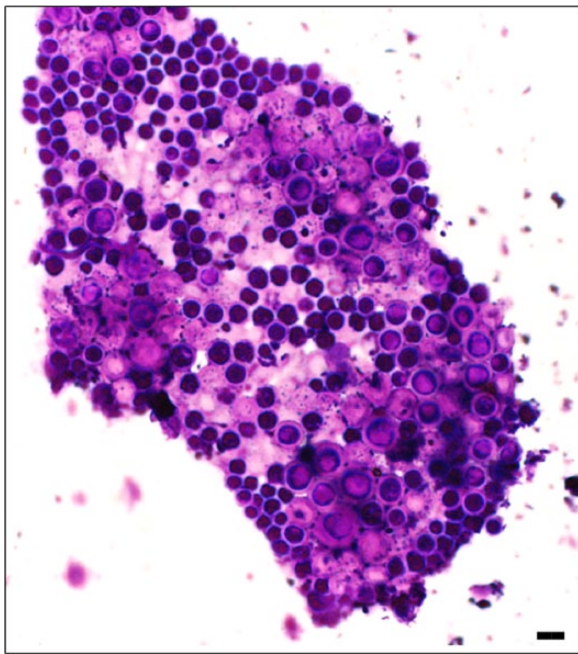


Figure 3 Microscopic examination of fungal culture: cells of encapsulated yeasts compatible with *Cryptococcus* species (Hiss staining; scale bar = 20 μ m)

acid (12.5 mg/kg, Nisamox; Norbrook Laboratories), permethrin, nystatin, triamcinolone acetonide and neomycin sulfate ear ointment (Oridermyl; V etoquinol) and imidacloprid/moxidectin spot-on application (Advocate; Bayer). Blepharitis and otitis were completely resolved 1 month after onset of treatment (Figure 4). Three months later the antifungal therapy was suspended. At this time the cat appeared clinically normal.



Figure 4 Blepharitis had completely resolved 1 month after treatment. Small scars can be noted in the upper and lower lids

Discussion

In Europe, cryptococcosis is usually rare or sporadic.^{6,16} Retrospective studies have shown that there is no breed or sex predisposition.⁶ Cats of any age can be affected.¹ Stray and rural cats seem to be more exposed to *Cryptococcus*, but indoor urban cats can also be infected through infected pigeon droppings.^{1,6} The occurrence of the disease in cats is higher than in other domestic animals, probably owing to their grooming behaviour, which increases the probability of fungal delivery to the nasal cavity.^{6,17}

Localised cutaneous lesions, as in the present case, probably result from contamination of cat-scratch injuries with viable basidiomycetous encapsulated yeasts.^{1,11} Here, the infection was only expressed in a gap in the integrity of normal cutaneous barriers.¹¹ As a result, the cat recovered faster with a shorter duration of therapy than others. The role of immunosuppression cannot be excluded in the pathogenesis of feline cryptococcosis.^{1,6,7} Some studies suggest that cats co-infected with FeLV and FIV are more predisposed to cryptococcosis, but this conclusion is not shared by others.^{7,12,18}

Having been discovered about 100 years ago, cryptococcosis is a non-contagious systemic mycosis currently responsible for an estimated 625,000 human deaths due to cryptococcal meningitis in patients with human immunodeficiency virus/AIDS each year worldwide.¹⁹ Cats, dogs and other infected animals do not represent a direct threat to public health as infection is acquired from contaminated environments, but they may act as sentinel species. The knowledge of local fungal habitats may be useful in planning preventative measures for both human and animal infections.⁶ In an environmental survey carried out in the municipality of Vila Real, *C neoformans* was found in the majority of sampled cages of domestic racing carrier pigeons (genotypes VNIV, VNI and VNIII) and in a few samples of decaying *Eucalyptus* leaves (genotype VNI).¹⁰

Conclusion

To the best of our knowledge, this is the first clinical case report of feline blepharitis due to *C neoformans* without concurrent naso-ocular signs. In addition, besides an anecdotal abstract about infection in a cat and reports of an infected free-living toad and a goat,^{16,20,21} this is the first published clinical case of cryptococcosis in pets in Portugal.

The current findings, together with those from recent reports of the infection in domestic animals, should alert the veterinary community to this underdiagnosed disease. Additionally, in Portugal and other European countries, cryptococcosis should be included in the differential diagnosis of feline blepharitis.

Acknowledgements We would like to express their gratitude to Mrs Fátima Fraga (University of Trás-os-Montes e Alto Douro [UTAD]) for help with the laboratory work and to Prof. Lurdes Pinto (UTAD) for the production of the photomicrographs.

Funding The authors received no specific grant from any funding agency in the public, commercial or not-for-profit sectors for the preparation of this case report.

Conflict of interest The authors do not have any potential conflict of interest to declare.

References

- 1 Sykes JE and Malik R. **Cryptococcosis**. In: Greene CE (ed). *Infectious diseases of the dog and cat*. 4th ed. St Louis, MO: Elsevier Saunders, 2012, pp 621–634.
- 2 Trivedi SR, Malik R, Meyer W, et al. **Feline cryptococcosis. Impact of current research on clinical management**. *J Feline Med Surg* 2011; 13: 163–172.
- 3 Lambert RJ, Levin G, Wendelburg K, et al. **What is your diagnosis?** *J Am Vet Med Assoc* 2006; 229: 931–932.
- 4 Trivedi SR, Sykes JE, Cannon MS, et al. **Clinical features and epidemiology of cryptococcosis in cats and dogs in California: 93 cases (1988–2010)**. *J Am Vet Med Assoc* 2006; 239: 357–369.
- 5 Castellá G, Abarca ML and Cabañes FJ. **Criptococosis y animales de compañía**. *Rev Iberoam Micol* 2008; 25: S19–S24.
- 6 Pennisi MG, Hartmann K, Lloret A, et al. **Cryptococcosis in cats. ABCD guidelines on prevention and management**. *J Feline Med Surg* 2013; 15: 611–618.
- 7 Duncan C, Stephen C and Campbell J. **Clinical characteristics and predictors of mortality for *Cryptococcus gattii* infection in dogs and cats of southwestern British Columbia**. *Can Vet J* 2006; 47: 993–998.
- 8 Lester SJ, Malik R, Bartlett KH, et al. **Cryptococcosis: update and emergence of *Cryptococcus gattii***. *Vet Clin Pathol* 2011; 40: 4–17.
- 9 Martins DB, Zanette RA, França RT, et al. **Massive cryptococcal disseminated infection in an immunocompetent cat**. *Vet Dermatol* 2010; 22: 232–234.
- 10 Ferreira AS, Sampaio A, Maduro AP, et al. **Genotypic diversity of environmental *Cryptococcus neoformans* isolates from Northern Portugal**. *Mycoses* 2014; 57: 98–104.
- 11 Malik R, Vogelnest L, O'Brien C, et al. **Infections and some other conditions affecting the skin and subcutis of the naso-ocular region of cats – clinical experience 1987–2003**. *J Feline Med Surg* 2004; 6: 383–390.
- 12 Malik R, Jacobs GJ and Love DN. **Cryptococcosis: new perspectives on etiology, pathogenesis, diagnosis, and clinical management**. In: August JR (ed). *Consultations in feline internal medicine*. 4th ed. Philadelphia, PA: WB Saunders, 2001, pp 39–50.
- 13 Maggio F, Miller Michau TM, Pizzirani S, et al. **Ocular cryptococcosis in cats: nine cases [abstract]**. *Vet Ophthalmol* 2002; 5: 283–301.
- 14 Kano R, Nakamura Y, Watari T, et al. **A case of feline cryptococcosis treated with itraconazole**. *Mycoses* 1997; 40: 381–383.
- 15 Maduro AP, Mansinho K, Teles F, et al. **Insights on the genotype distribution among *Cryptococcus neoformans* and *C gattii* Portuguese clinical isolates**. *Curr Microbiol* 2014; 68: 199–203.
- 16 Lourenço-Martins AM, Jesus S, Félix N, et al. **Feline ocular cryptococcosis – first report in Portugal [abstract]**. *Vet Ophthalmol* 2011; 15: 66–70.
- 17 Krockenberger MB and Lester SJ. **Cryptococcosis – clinical advice on an emerging global concern**. *J Feline Med Surg* 2011; 13: 158–160.
- 18 Cabañes FJ, Abarca ML, Bonavia R, et al. **Cryptococcosis in a cat seropositive for feline immunodeficiency virus**. *Mycoses* 1995; 38: 131–133.
- 19 Park BJ, Wannemuehler KA, Marston BJ, et al. **Estimation of the current global burden of cryptococcal meningitis among persons living with HIV/AIDS**. *AIDS* 2009; 23: 525–530.
- 20 Seixas F, Martins ML, Pinto LM, et al. **A case of pulmonary cryptococcosis in a free-living toad (*Bufo bufo*)**. *J Wildl Dis* 2008; 44: 460–463.
- 21 Stilwell G and Pissarra H. **Cryptococcal meningitis in a goat – a case report**. *BMC Vet Res* 2014; 10: 84.