



First report of *Cylicospirura felineus* in a feral domestic shorthair cat in North America

Authors: Crossland, Nicholas A, Hanks, Cory R, Ferguson, Jayde A, Kent, Michael L, Sanders, Justin L, et al.

Source: Journal of Feline Medicine and Surgery Open Reports, 1(2)

Published By: SAGE Publishing

URL: <https://doi.org/10.1177/2055116915593964>

BioOne Complete (complete.BioOne.org) is a full-text database of 200 subscribed and open-access titles in the biological, ecological, and environmental sciences published by nonprofit societies, associations, museums, institutions, and presses.

Your use of this PDF, the BioOne Complete website, and all posted and associated content indicates your acceptance of BioOne's Terms of Use, available at www.bioone.org/terms-of-use.

Usage of BioOne Complete content is strictly limited to personal, educational, and non - commercial use. Commercial inquiries or rights and permissions requests should be directed to the individual publisher as copyright holder.

BioOne sees sustainable scholarly publishing as an inherently collaborative enterprise connecting authors, nonprofit publishers, academic institutions, research libraries, and research funders in the common goal of maximizing access to critical research.



First report of *Cylicospirura felineus* in a feral domestic shorthair cat in North America

Journal of Feline Medicine and Surgery
Open Reports
1–4

© The Author(s) 2015
Reprints and permissions:
sagepub.co.uk/journalsPermissions.nav
DOI: 10.1177/2055116915593964
jfmsopenreports.com



Nicholas A Crossland¹, Cory R Hanks¹, Jayde A Ferguson²,
Michael L Kent³, Justin L Sanders³ and Fabio Del Piero¹

Abstract

Case summary A feral domestic shorthair cat was euthanized owing to acute onset and progression of neurological signs attributed to ethylene glycol toxicity. At post-mortem examination two nodules were identified within the fundus of the stomach. Examination of the gastric nodules revealed an intact mucosal surface, each with multiple red slender nematodes extending through an individual central pore. Histopathological evaluation of the nodules highlighted unique reactive fibroplasia, mimicking feline gastrointestinal eosinophilic sclerosing fibroplasia (FGESF), encasing numerous nematodes with females possessing gravid uteri containing abundant larvated eggs. The latter findings were highly suggestive of the *Cylicospirura* genus, further supported by an en face evaluation of the buccal cavity, highlighting a distinctive trifold tooth appearance. Together, these findings are consistent with *Cylicospirura felineus*. PCR for the COX-1 gene was unsuccessful on formalin-fixed specimens, attributed to nucleic acid and protein crosslinking.

Relevance and novel information This represents the first documented case of *Cylicospirura* species in a feral domestic shorthair cat in North America. This particular cat lived in the highly urban environment of New Orleans, Louisiana. Identification of this case demonstrates the potential for feral cats to serve as reservoir hosts and ultimately support transmission of *Cylicospirura* species into domesticated cat populations. Gastric cylicospiruriasis may present clinically as a firm abdominal mass, potentially with a history of chronic vomiting. The latter emphasizes the importance of differentiating this condition from a neoplastic process such as alimentary lymphoma and adenocarcinoma. Histologically, the unique thick anastomosing collagenous cords encasing nematodes represent a stereotypical response observed in a broad array of gastrointestinal inflammation in felines, including intralesional bacteria, fungal hyphae, foreign bodies and, in this case, gastric nematodes that closely resemble FGESF. Additionally, these unique histological lesions have previously been misinterpreted as neoplastic conditions, including sclerosing mast cell tumor and extraosseous osteosarcoma.

Accepted: 3 February 2015

Introduction

Cylicospirura is within the family Spiruroidea, which also includes *Physaloptera* species, *Spirocerca lupi* and *Cyathospirura* species. These all are believed to have arthropod intermediate hosts with thick-shelled larvated eggs or a paratenic vertebrate host. Owing to its unique histologic appearance, Eckstrand et al proposed the term verminous alimentary sclerosing fibroplasia (VASF) for gastrointestinal cylicospiruriasis.¹ Unlike *lupi*, *Cylicospirura* species nodules have not been shown to progress to neoplasms. In this particular case an adult neutered feral domestic shorthair feline of unknown age

¹Department of Pathobiological Sciences, Louisiana State University School of Veterinary Medicine, Baton Rouge, LA, USA

²Alaska Department of Fish and Game, Commercial Fisheries, Anchorage, AK, USA

³Department of Microbiology, Oregon State University College of Veterinary Medicine, Corvallis, OR, USA

Corresponding author:

Nicholas A Crossland DVM, Department of Pathobiological Sciences, School of Veterinary Medicine, Louisiana State University, Skip Bertman Drive, Baton Rouge, LA 70808, USA
Email: ncross6@lsu.edu



Creative Commons CC-BY-NC: This article is distributed under the terms of the Creative Commons Attribution-NonCommercial 3.0 License (<http://www.creativecommons.org/licenses/by-nc/3.0/>) which permits non-commercial use, reproduction and distribution of the work without further permission provided the original work is attributed as specified on the SAGE and Open Access page (<http://www.uk.sagepub.com/aboutus/openaccess.htm>).

was humanely euthanized owing to the acute and progressive neurologic signs ultimately attributed to ethylene glycol toxicity, with gastric cyclospiruriasis representing an incidental finding. However, in wild felids, chronic vomiting, weight loss and intestinal perforation have been attributed to *Cylicospirura* species infection.²

Currently, no data have been published with regard to available efficacious anthelmintic treatments for *Cylicospirura* species. The unique stromal reaction surrounding the gastric nematodes resembles feline gastrointestinal eosinophilic sclerosing fibroplasia (FGESF), which, owing to the presence of large numbers of mast cells and the sclerotic appearance of collagen trabeculae, may be misdiagnosed as sclerosing mast cell tumors or extrasosseous osteosarcoma, respectively. In contrast to our case, FGESF typically occurs as an ulcerated intramural mass within the pyloric sphincter, ileocecolic junction or colon, with occasional regional lymph node involvement and common intralesional bacteria (56% of overall cases, $n = 25$),³ or fungal hyphae associated with the characteristic collagenous cords, although bacteria were concurrently present in this lesion.⁴ Interestingly, one case report of FGESF mimicked a metastatic neoplasm with multiple nodules involving the pylorus, colon, multiple mesenteric and mediastinal lymph nodes.⁵ FGESF cases typically fail to respond to antibiotic treatment; however, the longest survival curves are seen in animals receiving corticosteroids or surgical excision.³ Eosinophils require leukotriene D₄ for initiation of transforming growth factor- β production, a key fibrinogenic mediator, supporting the role of corticosteroids in medical management of these cases by inhibiting lipoxigenase and subsequent leukotriene production. Similar histologic features characterized by an anastomosing fibrous network observed with both VASF and FGESF have also been observed in cougars (*Puma concolor*) with intralesional intestinal porcupine quills.

Case description

At post-mortem examination, the cat was in adequate body condition. Large numbers of fleas (*Ctenocephalides felis*) were detected on external examination. The fundus of the stomach contained two raised, well-circumscribed nodules measuring $2.5 \times 1.5 \times 1$ cm and $2 \times 2 \times 1$ cm, respectively (Figure 1), each with a central mucosal pore containing several red slender nematodes, approximately 2–3 cm in length. On cut surface of the nodules, the wall of the stomach was transmurally expanded by a cavernous network of white-to-gray fibrous connective tissue surrounding numerous slender red nematodes (Figure 2). The renal cortices displayed punctate fluorescence with the use of a Wood's lamp, but were normal in size and cortical contour. Tissues were routinely fixed in neutral-buffered 10% formalin, trimmed, embedded in paraffin and sectioned for microscopic examination.

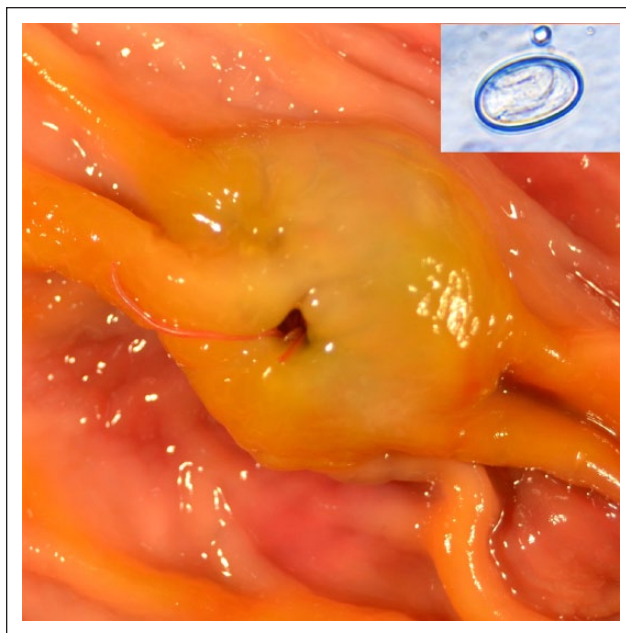

Figure 1 Post-mortem photograph of one of the nodules present in the fundus of the stomach; the raised nodule contains a central mucosal pore with multiple slender red nematodes extending onto the mucosal surface of the stomach. The inset highlights a larvated egg, observed upon fecal float examination; mean measurements of 10 eggs were $40 \times 30 \mu\text{m}$

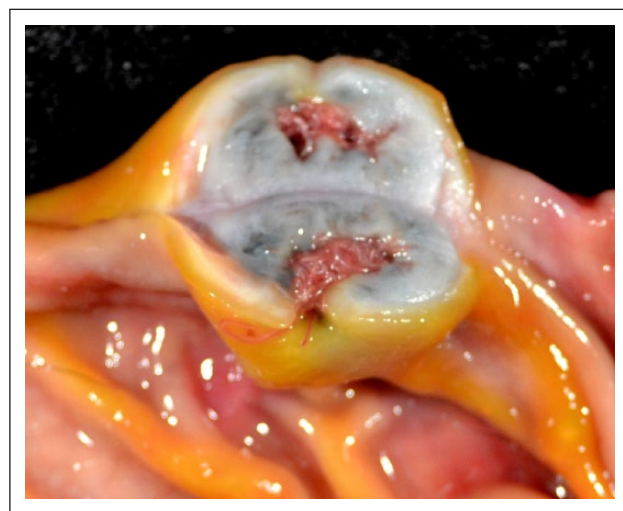


Figure 2 Post-mortem cross-sectional photograph of one of the two stomach nodules displaying mural expansion of the submucosa by a labyrinth of white-to-gray fibrous connective tissue surrounding numerous red nematodes

Nodules within the gastric fundus were characterized by marked expansion of the submucosa by thick anastomosing cords of dense sclerotic collagen interlaced by loose aggregates of spindle cells, moderate numbers of lymphocytes and plasma cells, with lesser numbers of eosinophils and mast cells. The underlying

muscularis and serosa were otherwise unaffected. Within the confines of the dense connective tissue were numerous transverse and longitudinal sections of adult nematodes measuring approximately 250–450 μm in diameter, with an overlying mucosal pore. Nematodes contained an 8- μm -thick eosinophilic cuticle with fine serrated ridges, prominent compartmentalized lateral cords, coelomyarian musculature and a pseudocoelom containing amorphous basophilic material and occasional foci of yellow-to-brown granular pigment. The intestinal tract was lined by uninucleate columnar epithelium with long, fine apical projections.

The vast majority of nematodes were female containing gravid uteri with large numbers of larvated eggs (Figure 3, inset). Wet mount microscopic examination of a dissected gravid female identified larvated eggs measuring $40 \times 30 \mu\text{m}$ (mean measurement of 10 eggs). For identification, nematodes were mounted onto glass slides for en face examination of longitudinal ribs, identifying terminal trifold projections (Figure 4).

Renal tubules, most often within the cortex, contained abundant translucent, pale yellow, anisotropic, birefringent crystals arranged in sheaves and prisms (calcium oxalate). Tubular epithelial cells were frequently degenerate or necrotic, as evidenced by abundant vacuolated eosinophilic cytoplasm or hypereosinophilia and shrinkage with nuclear pyknosis, respectively. These renal changes were consistent with ethylene glycol toxicity.

Discussion

To the best of our knowledge this is the first case report of *Cylicospirura* species in a feral domestic shorthair cat (*Felis catus*) within North America, although this organism is frequently observed in multiple North American wild felids, including the bobcat (*Lynx rufus*), lynx (*Lynx lynx*) and cougar (*P concolor*).² This species has been previously reported from domestic cats in Asia, Africa and Australia.^{4–8} Other species infecting domestic cats include *Cylicospirura subaequalis* and *Cylicospirura (Petrospirura) barusi* in Asia, *Cylicospirura heydoni* in Australia, *Cylicospirura advena* in New Zealand and an unidentified *Cylicospirura* species in Italy.^{9–12}

Species can be differentiated based on morphological differences of tooth morphology within the buccal cavity, location of the vulva in comparison with the esophageal intestinal junction or DNA sequence of the mitochondrial cytochrome c oxidase subunit 1 gene (*cox1*). In this particular case, specimens were identified as *Cylicospirura felineus* based on the distinctive trifold morphology of the anterior portion of the longitudinal ribs (Figure 4). There are three other species with distinct trifold dentation: *Cylicospirura crocutae* from hyenas in Africa, *Cylicospirura pardalis* from leopards in Africa and *Cylicospirura skrjabini* from foxes in Siberia. The shape of the cusps in teeth of *C skrjabini* are conical, whereas

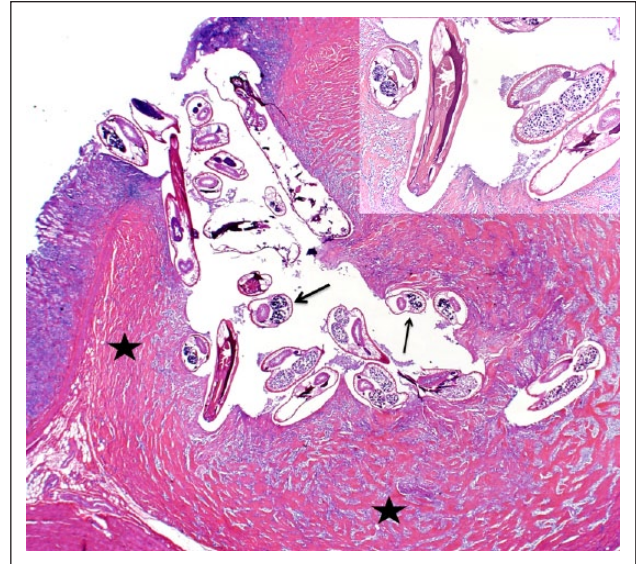


Figure 3 Photomicrograph of the gastric parasitic nodule displayed in Figures 1 and 2. Numerous transverse and longitudinal sections of nematodes (indicated by arrows) are surrounded by concentric anastomosing dense fibrous bands of sclerotic collagen (indicated by stars). The inset highlights nematodes containing a thick eosinophilic cuticle and paired gravid uteri containing numerous larvated eggs (hematoxylin and eosin)

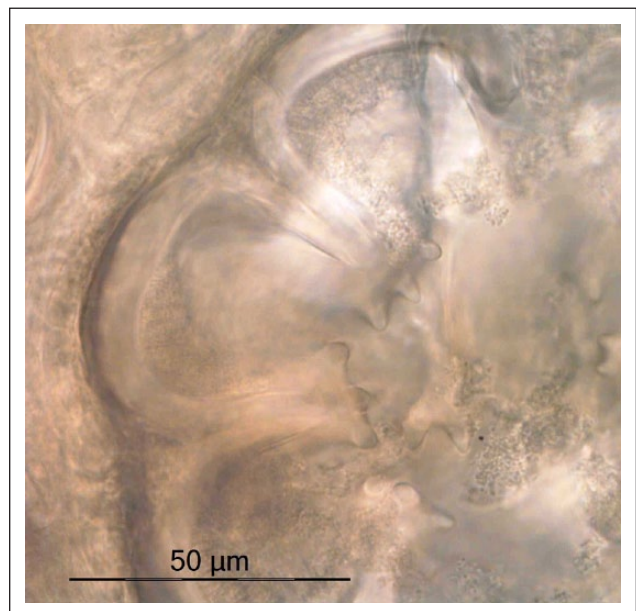


Figure 4 Photomicrograph of the buccal cavity en face displays a distinctive trifold appearance of the anterior segments of longitudinal ribs resembling a crown (bar = 50 μm)

those in *C pardalis* are claw-like in appearance.⁷ Both *C crocutae* and *C felineus* have rounded cusps, but *C felineus* has a 50–70% shorter esophagus than *C crocutae*.¹³ We previously distinguished *C felineus* from *C subaequalis* using differences in *cox1*.² We attempted multiple times to obtain the *cox1* sequence from the several of the worms

in the present study using the same primer sequences that amplify approximately 700 base pairs, but were unsuccessful. Nevertheless, given the worm morphology, host and geographic location, we conclude that the infection presented here was caused by *C felineus*.

Conclusions

This case represents the first documented report of *Cylicospirura* species in a feral domestic shorthair cat in North America. This animal originated from a highly urban environment in New Orleans, Louisiana, where feral cats flourish. Although a single isolated case such as this cannot definitely support an established burden of gastric cylicospiruriasis in feral cats, animals such as this could serve as a reservoir for spillover into domestic cats, stressing the importance of monitoring feral cat populations. The lack of previous identification in domesticated cats within North America may suggest decreased consumption of intermediate and/or paratenic hosts. Additionally, standard anthelmintic medications frequently administered to domesticated cats could potentially be highly efficacious against *Cylicospirura* species. These findings continue to support a predictable fibrosing process within the gastrointestinal tract of felines in response to a variety of foreign objects, including nematodes, bacteria, fungal hyphae and foreign bodies (porcupine needles). These unique stromal changes may be misdiagnosed as sclerosing mast cell tumors or extrasosseous osteosarcomas. Although uncommon, *Cylicospirura* species can result in chronic vomiting when associated with the pyloric outflow tract.

Funding The authors received no specific grant from any funding agency in the public, commercial or not-for-profit sectors for the preparation of this case report.

Conflict of interest The authors do not have any potential conflicts of interest to declare.

References

- 1 Eckstrand CD, Barr BC, Woods LW, et al. Nematode-associated intramural alimentary nodules in pumas are histologically similar to gastrointestinal eosinophilic sclerosing fibroplasia of domestic cats. *J Comp Path* 2013; 148: 405–409.
- 2 Ferguson JA, Woodberry K, Gillin CM, et al. *Cylicospirura* species (Nematoda: Spirocercidae) and stomach nodules in cougars (*Puma concolor*) and bobcats (*Lynx rufus*) in Oregon. *J Wildlife Disease* 2011; 47: 140–153.
- 3 Craig LE, Hardam EE, Hertzke DM, et al. Feline gastrointestinal eosinophilic sclerosing fibroplasia. *Vet Path* 2009; 46: 63–70.
- 4 Grau-Roma L, Galindo-Cardiel I, Isidoro-Ayza M, et al. A case of feline gastrointestinal eosinophilic sclerosing fibroplasia associated with phycomyces. *J Comp Path* 2014; 151: 318–321.
- 5 Munday JS, Martinez AW and Soo M. A case of feline gastrointestinal eosinophilic sclerosing fibroplasia mimicking metastatic neoplasia. *N Z Vet J* 2014; 62: 356–360.
- 6 Gill HS. Incidence of gastro-intestinal helminthes in cat (*Felis catus*) in Delhi. *J Commun Dis* 1972; 4: 109–111.
- 7 Ibba F, Lepri E, Veronesi F, et al. Gastric cylicospirurosis in a domestic cat from Italy. *J Feline Med Surg* 2014; 16: 522–526.
- 8 Milstein TE and Goldsmid JM. Parasites of feral cats from southern Tasmania and their potential significance. *Aust Vet J* 1997; 75: 218–219.
- 9 Clark WC. *Cylicospirura advena* n.sp. (Nematoda: Spirocercidae) a stomach parasite from a cat in New Zealand, with observations on related species. *Syst Parasitol* 1981; 3: 185–191.
- 10 Gregory GG and Munday BL. Internal parasites of feral cats from the Tasmanian midlands and King Island. *Aust Vet J* 1976; 52: 317–320.
- 11 Junker K, Lane EP, McRee AE, et al. Two new species of *Cylicospirura* Vevers, 1922 (Nematoda: Spirocercidae) from carnivores in southern Africa, with validation of the related genera *Gastronodus* Singh, 1934 and *Skrjabino-cercina* Matschulsky, 1952. *Folia Parasitol (Praha)* 2013; 60: 339–352.
- 12 O'Callaghan M, Reddin J and Lehmann D. Helminth and protozoan parasites of feral cats from Kangaroo Island. *Trans R Soc S Aust* 2005; 129: 81–83.
- 13 Junker K, Vorster JH and Boomker J. First record of *Cylicospirura* (*Cylicospirura*) *felineus* (Chandler, 1925) Sand-ground, 1933 (Nematoda: Spirocercidae) from a domestic cat in South Africa. *Onderstepoort J Vet Res* 2006; 73: 257–262.