



## **Supratentorial arachnoid cyst management by cystoperitoneal shunt in a 1-year-old European cat**

Authors: Taroni, Mathieu, Seurin, Marie-Jose, Carozzo, Claude, and Escriou, Catherine

Source: Journal of Feline Medicine and Surgery Open Reports, 1(2)

Published By: SAGE Publishing

URL: <https://doi.org/10.1177/2055116915593970>

---

BioOne Complete ([complete.BioOne.org](http://complete.BioOne.org)) is a full-text database of 200 subscribed and open-access titles in the biological, ecological, and environmental sciences published by nonprofit societies, associations, museums, institutions, and presses.

Your use of this PDF, the BioOne Complete website, and all posted and associated content indicates your acceptance of BioOne's Terms of Use, available at [www.bioone.org/terms-of-use](http://www.bioone.org/terms-of-use).

Usage of BioOne Complete content is strictly limited to personal, educational, and non - commercial use. Commercial inquiries or rights and permissions requests should be directed to the individual publisher as copyright holder.

---

BioOne sees sustainable scholarly publishing as an inherently collaborative enterprise connecting authors, nonprofit publishers, academic institutions, research libraries, and research funders in the common goal of maximizing access to critical research.



# Supratentorial arachnoid cyst management by cystoperitoneal shunt in a 1-year-old European cat

Mathieu Taroni<sup>1</sup>, Marie-Jose Seurin<sup>2</sup>, Claude Carozzo<sup>1</sup> and Catherine Escriou<sup>1</sup>

## Abstract

Arachnoid cysts are defined as an accumulation of fluid within the arachnoid membrane. Feline intracranial arachnoid cysts are seldom reported, with only three cases in the veterinary literature. A 1-year-old male neutered European cat with a 24 h history of seizures was presented to the small animal neurology department at Vetagro Sup, Lyon. Magnetic resonance imaging (MRI) revealed a large intracranial arachnoid cyst ventral to the brain in the left temporal area. Cystoperitoneal shunt placement resulted in complete resolution of the cyst without recurrence (follow-up MRIs 3 weeks and 21 months after surgery). Anticonvulsant treatment (phenobarbital 2.5 mg/kg q12h) was initiated at presentation and gradually stopped after 17 months. Seizures recurred 4 months after ending treatment, and seizure therapy was therefore restarted at the initial dose. We report a case of an intracranial arachnoid cyst in an unusual location not previously described. A cystoperitoneal shunt resolved the cyst without complications. Maintenance anticonvulsant treatment was required to control symptomatic epilepsy.

**Accepted:** 12 April 2015

## Introduction

An intracranial arachnoid cyst (IAC) is a developmental brain disorder in which fluid accumulates within a split of the arachnoid membrane. These structures do not fit the anatomical definition of a cyst and should be referred to as pseudocysts or diverticula. However, we have adopted the widely used term ‘arachnoid cyst’ in this article. The cavity does not usually communicate with the subarachnoid space (‘non-communicating’ cyst). However, IACs communicating with the subarachnoid space have been reported in humans.<sup>1</sup>

In humans, IACs are often incidental findings, but their clinical incidence seems to be more frequent than previously thought in humans, as well as in dogs, although this is hard to confirm.<sup>1</sup> Associated clinical signs are usually focal and generalised seizures.

IACs represent 1% of all intracranial masses in humans, and they have been sporadically reported in dogs, where they occur most commonly in the quadrigeminal cistern.<sup>1–7</sup> Only three cases have been reported in cats; all were located in the caudal fossa at the level of the quadrigeminal cistern.<sup>4,8,9</sup>

This case describes an IAC with an unusual location treated conventionally by cystoperitoneal shunt (CPS) placement.

## Case description

A 1-year-old male neutered European cat was presented to the small animal neurology department at Vetagro Sup, Lyon, after a 24 h history of focal seizures and one generalised seizure.

The cat had about 12 complex partial seizures characterised by orofacial motor signs (chewing, licking, and eye and facial twitching), hypersalivation, obtundation, tremors of the thoracic limbs and urination. The cat was presented after a generalised tonic-clonic episode.

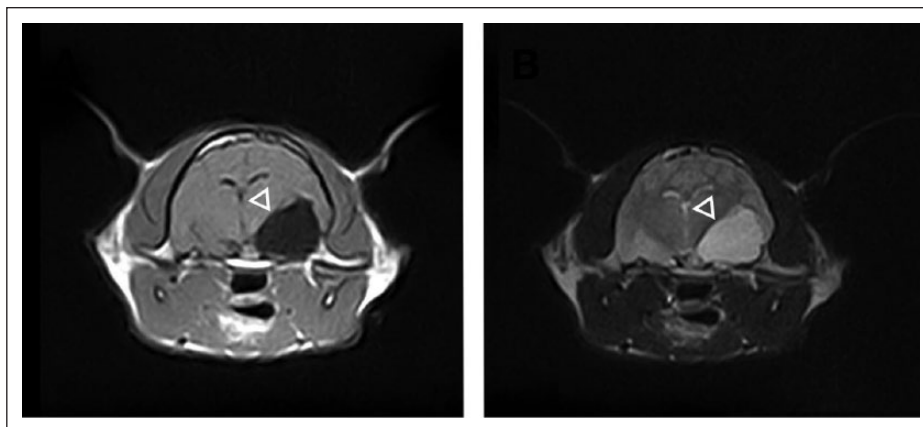
<sup>1</sup>VetAgro Sup, Lyon, France

<sup>2</sup>CIRMA, Lyon, France

### Corresponding author:

Catherine Escriou DVM, PhD, VetAgro Sup, 1 Avenue Bourgelat, 69280 Lyon, France  
 Email: [catherine.escriou@vetagro-sup.fr](mailto:catherine.escriou@vetagro-sup.fr)





**Figure 1** T1-weighted transverse magnetic resonance image (left) demonstrating a hypointense extra-axial lesion in the left temporal lobe (open arrowhead). The lesion is hyperintense in T2-weighted images (right)

At admission, clinical features were unremarkable with the exception of slight obtundation and tachypnoea with ptyalism.

Routine biochemistry (glucose, urea, creatinine, alkaline phosphatase, alanine aminotransferase, total proteins, total cholesterol and triglyceride) and bile acid stimulation were normal.

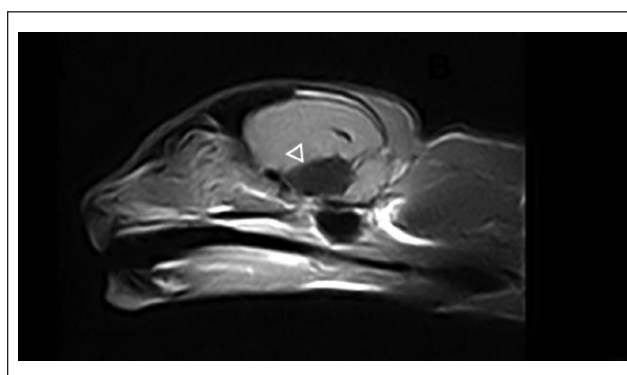
Magnetic resonance imaging (MRI) of the brain was performed using a 0.2-Tesla MRI system (E-Scan XQ; Esaote). A large, well-demarcated, extra-axial cystic lesion was present in the left temporal area, mainly beneath the piriform lobe. It measured 1.6 cm in width, 1.7 cm in height and 2.1 cm in length at its largest points. The lesion was mainly supratentorial and was associated with mild mass effect. Rostrally, it extended up to the caudal mesencephalon. The signal intensity of the content was identical to cerebrospinal fluid (CSF; hypointense on T1-weighted and fluid-attenuated inversion recovery images, hyperintense on T2-weighted images) (Figures 1 and 2). This lesion did not enhance after administration of gadolinium (Dotarem; Guerbet).

The degree of parenchymal compression of the fore-brain was calculated with a method previously described by Matusiak et al for IAC in dogs.<sup>10</sup> The calculated compression was 41.2%.

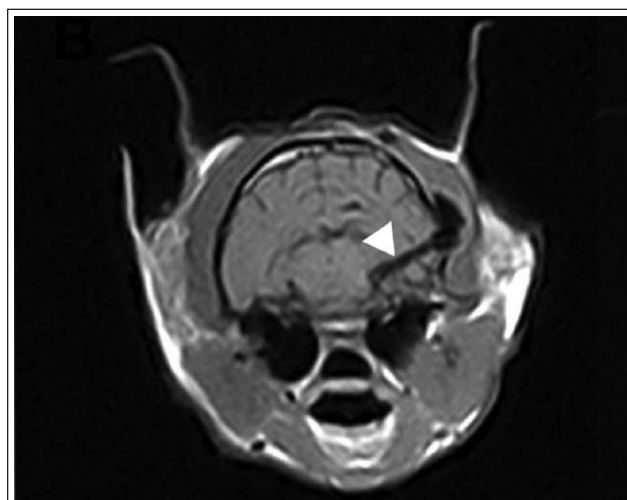
The MRI features were consistent with the diagnosis of a supratentorial left arachnoid cyst with left hemisphere (and particularly temporal lobe) compression.

The seizures were controlled with anticonvulsant treatment started after admission (phenobarbital 2.5 mg/kg q12h). Surgical treatment was cystoperitoneal shunt placement (Figure 3).

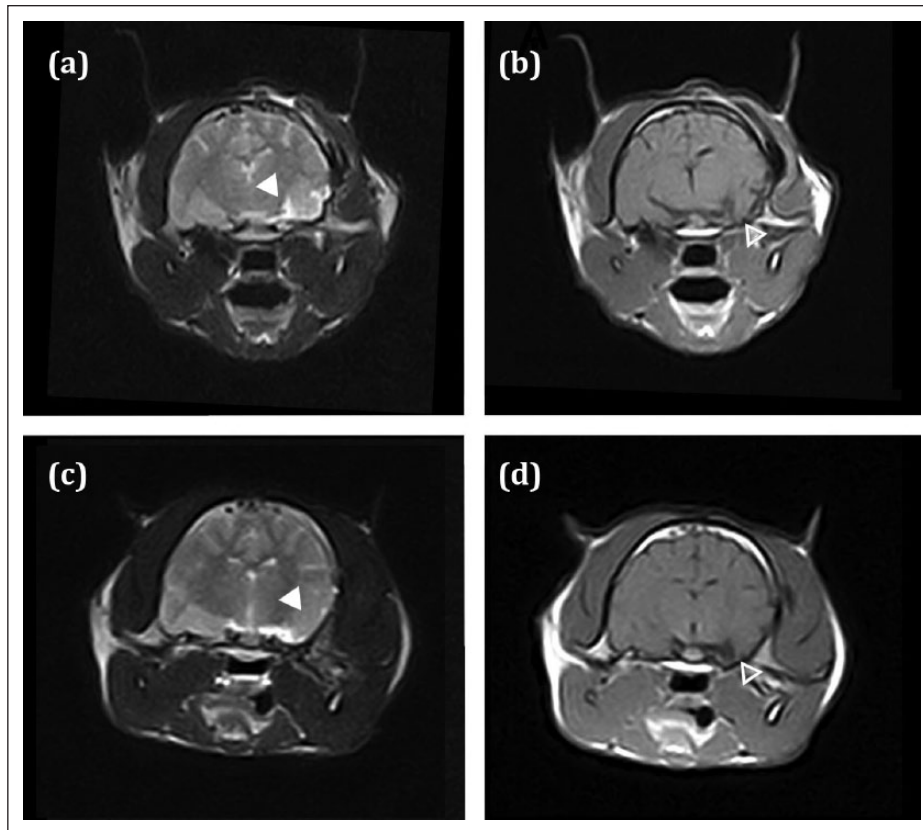
A dorsolateral approach to the skull was chosen, lateral to the sagittal crest. A peritoneal catheter was tunneled to the left hypochondrium and introduced into the peritoneal cavity by mini-laparotomy. After periosteal elevation, a 5 mm hole was drilled into the temporal bone. The dura was incised after preventive hemostasis,



**Figure 2** T1-weighted parasagittal magnetic resonance image demonstrating a hypointense lesion in the left temporal lobe (open arrowhead)



**Figure 3** T1-weighted transverse magnetic resonance image demonstrating postoperative reduction of the cyst. The catheter can be observed as a hypointense signal on the right (filled arrowhead)



**Figure 4** Magnetic resonance images demonstrating postoperative reduction of the cyst. (a,c) T2-weighted image signal abnormalities (diffuse hyperintensity) in the former cyst location (filled arrowhead) at (a) 3 weeks and (c) 21 months after surgery. (b,d) T1-weighted image showing parenchymal atrophy in the former cyst location (open arrowhead) compared with the contralateral side at (b) 3 weeks and (d) 21 months

and the cystic catheter was placed. It was anchored to the temporal bone and fixed to a low-pressure valve in the neck, under the muscular fascia. The valve was fixed to the peritoneal catheter.

Cystic fluid analysis collected during surgery was consistent with normal CSF.

MRI performed 3 weeks after surgery showed a total resolution of the cyst. However, persistent modifications of the brain parenchyma were observed in the temporal lobe, including decreased thickness of the temporal lobe compared with the contralateral side and slight signal abnormalities in T2-weighted images (Figure 3). Anticonvulsant treatment was ended 17 months after surgery with progressive tapering for 6 months. Four months after treatment discontinuation, epilepsy recurred and the cat presented two focal and one generalised seizures over 24 h. MRI was performed again and showed the same lesions as described 3 weeks after surgery (Figure 3). Phenobarbital treatment was restarted at the initial dose (2.5 mg/kg q12h) (Figure 4).

## Discussion

Differential diagnoses for intracranial cystic lesions are extensive but histological analysis of the lesions can give

an accurate diagnosis. In our case, no biopsy was performed perioperatively in order to avoid leaking at the catheter site. The lesions considered in the differential diagnoses list in cats, according to veterinary literature, are parasite cysts, cystic neoplasms, abscesses, cysts with a non-neural epithelial lining or ex vacuo-type cysts.<sup>7,11–18</sup>

The lack of contrast enhancement, extra-axial position and homogenous CSF-like aspect of this cyst makes all other possibilities than an IAC less likely.

To our knowledge, this is the first case of a supratentorial arachnoid cyst reported in a cat.

Only three cases of feline IAC have been described in the veterinary literature. The cats were three Persian-breed males ranging in age from 10 weeks to 4 years. The cysts were diagnosed with MRI in two cases or during necropsy in one case. The cyst was in the caudal fossa at the level of the quadrigeminal cistern in all cases,<sup>4,8,9</sup> and in one case it extended rostrally to the cerebral hemisphere.<sup>8</sup>

In dogs, males and small breeds are over-represented.<sup>2,4–7,11</sup> Canine IAC tends to occur mainly in the quadrigeminal cistern, with other infratentorial locations sporadically reported (eg, cerebellomedullary angle).<sup>7</sup>

In humans, IAC are mainly supratentorial, with 50–60% of them occurring in the middle cranial fossa.<sup>3,19,20</sup> They occur less often in the caudal fossa (10%), wherein they occur most frequently in the cerebellopontine angle and not the quadrigeminal cistern.

In our case, the cystic lesion was mainly in the forebrain region, spreading slightly to the brain stem, and it looked more similar to human than canine IAC.

IAC is often an incidental finding in humans, and it has recently been suggested that this may also be true for dogs;<sup>2,5,9,10,21</sup> however, numerous canine symptomatic cases have been reported.<sup>2,5–7,10,21</sup> Matiassek et al evaluated brain compression in 28 dogs with quadrigeminal cysts and concluded that occipital lobe compression of >14% was always associated with clinical signs (focal seizures, generalised seizures or both).<sup>10</sup> No such statistics exist in cats because only three cases of quadrigeminal cysts have been reported, and their clinical significance is difficult to assess. The first case was a 1-year-old cat with a history of uncontrollable seizures.<sup>9</sup> Anticonvulsant therapy (diazepam and phenobarbital) stopped the seizures for 5 months, but the cat relapsed and was euthanased. The second reported case was a 4-year-old cat with a 12 month history of episodic collapse and altered mentation that was presented after a severe episode of non-ambulatory tetraparesis and cranial nerve abnormalities.<sup>8</sup> It was treated by CPS placement and had not relapsed 10 months after surgery. The third case was a 10-week-old kitten that died after a 24-h period of lethargy with decreasing levels of consciousness.<sup>4</sup>

In our case, the clinical significance of the cyst, located in the left temporal area, is difficult to assess. The type of seizures (complex partial seizures with predominant orofacial motor signs) is similar to those observed with hippocampal necrosis. Forebrain compression calculated with a method previously described by Matiassek et al was 41.2%.<sup>10</sup> This value is given on an indicative basis and cannot be compared to the percentages found in the study by Matiassek et al (12–23%) because the location of the cyst was not the same.<sup>10</sup> Nonetheless, because of this value, the cyst likely had clinical significance. Recurrence of seizures after resolution of the cyst can be explained by the persistence of lesions in the temporal lobe (atrophy and diffuse hyperintensity in the hippocampal structures in T2-weighted images) (Figure 3).

Management of IAC in dogs is usually achieved by either cyst fenestration or, more commonly, by CPS placement.<sup>2,5,7,22,23</sup> In humans, it is reported that CPS reduces the cyst permanently, while fenestration may require secondary intervention.<sup>24–26</sup> Arachnoid cysts do not have an epithelial lining and should be described as pseudocysts or diverticula, but the inner membrane is believed to have secretory activity.<sup>11,23,27</sup> In veterinary medicine, both fenestration and shunting are described as treatments, but no study reports the therapeutic superiority of any of them.

In our case, CPS placement resulted in no complications during surgery and lead to total resolution of the cyst 21 months after surgery (MRI assessment). Shunting was chosen because it is considered as an efficient and low-morbidity method, and is reported in the literature more frequently.<sup>2,8,22,23</sup> Although this technique does not allow histological analysis of the cyst, to avoid catheter leaking, it is considered a less invasive method than fenestration.

## Conclusions

To our knowledge, this is the first reported case of a supratentorial arachnoid cyst in a cat, as all other IACs mentioned in the literature were quadrigeminal cysts.<sup>4,8,9,22,23</sup> The location of the cyst in the temporal lobe is unusual in cats and dogs but is consistent with the predominant location in humans.<sup>19,20,24–27</sup>

The semiology of the seizures suggests that the cyst had clinical significance, even if this cannot be definitively proven.

This case describes an IAC that was successfully managed by CPS placement without complications. Shunting could be considered a reference method in IAC surgical therapy but too few cases are reported in veterinary medicine to assess the therapeutic superiority of either CPS or fenestration.

**Funding** The authors received no specific grant from any funding agency in the public, commercial or not-for-profit sectors for the preparation of this case report.

**Conflict of interest** The authors do not have any potential conflicts of interest to declare.

## References

- 1 Rengachary SS and Watanabe I. **Ultrastructure and pathogenesis of intracranial arachnoid cysts.** *J Neuropath Exp Neurol* 1981; 40: 61–83.
- 2 Dewey CW, Krotscheck U, Bailey KS, et al. **Craniotomy with cystoperitoneal shunting for treatment of intracranial arachnoid cysts in dogs.** *Vet Surg* 2007; 36: 416–422.
- 3 Osborn AG and Preece MT. **Intracranial cysts: radiologic-pathologic correlation and imaging approach.** *Radiology* 2006; 239: 650–664.
- 4 Reed S, Cho DY and Paulsen D. **Quadrigeminal arachnoid cysts in a kitten and a dog.** *J Vet Diagn Invest* 2009; 21: 707–710.
- 5 Dewey CW, Scrivani PV, Krotscheck U, et al. **Intracranial arachnoid cysts in dogs.** *Compend Contin Educ Vet* 2009; 31: 160–167.
- 6 Vernau KM, LeCouteur RA, Sturges BK, et al. **Intracranial intra-arachnoid cyst with intracystic hemorrhage in two dogs.** *Vet Radiol Ultrasound* 2002; 43: 449–454.
- 7 Vernau KM, Kortz GD, Koblik PD, et al. **Magnetic resonance imaging and computed tomography characteristics of intracranial intra-arachnoid cysts in 6 dogs.** *Vet Radiol Ultrasound* 1997; 38: 171–176.

- 8 Lowrie M, Wessmann A, Gunn-Moore D, et al. **Quadrigeminal cyst management by cystoperitoneal shunt in a 4-year-old Persian cat.** *J Feline Med Surg* 2009; 11: 711–713.
- 9 Milner RJ, Engela J and Kirberger RM. **Arachnoid cyst in cerebellar pontine area of a cat—diagnosis by magnetic resonance imaging.** *Vet Radiol Ultrasound* 1996; 37: 34–36.
- 10 Matiasek LA, Platt SR, Shaw S, et al. **Clinical and magnetic resonance imaging characteristics of quadrigeminal cysts in dogs.** *J Vet Intern Med* 2007; 21: 1021–1026.
- 11 Mackillop E. **Magnetic resonance imaging of intracranial malformations in dogs and cats.** *Vet Radiol Ultrasound* 2011; 52: 42–51.
- 12 Gökalp HZ, Yuceer N, Arasil E, et al. **Colloid cyst of the third ventricle.** *Acta Neurochir* 1996; 138: 45–49.
- 13 Jull P, Browne E, Boufana BS, et al. **Cerebral coenurosis in a cat caused by *Taenia serialis*: neurological, magnetic resonance imaging and pathological features.** *J Feline Med Surg* 2012; 14: 646–649.
- 14 Smith MC, Bailey CS, Baker N, et al. **Cerebral coenurosis in a cat.** *J Am Vet Med Assoc* 1988; 192: 82–84.
- 15 Pau A, Turtas S, Barmbilla M, et al. **Computed tomography and magnetic resonance imaging of cerebral coenurosis.** *Surg Neurol* 1987; 27: 548–552.
- 16 Troxel MT, Vite CH, Massicotte C, et al. **Magnetic resonance imaging features of feline intracranial neoplasia: retrospective analysis of 46 cats.** *J Vet Intern Med* 2004; 18: 176–189.
- 17 Elliott I and Skerritt G. **Handbook of small animal MRI.** Oxford: Wiley-Blackwell, 2010.
- 18 Lang J and Seiler G. **Neuroradiology.** In: Jaggy A and Le Couteur R (eds). Atlas and textbook of small animal neurology. Hannover: Schlütersche, 2010, pp 87–151.
- 19 Sommer IE and Smit LM. **Congenital supratentorial arachnoidal and giant cysts in children: a clinical study with arguments for a conservative approach.** *Child Nerv Syst* 1997; 13: 8–12.
- 20 Kitagawa M, Kanayama K and Sakai T. **Quadrigeminal cisterna arachnoid cyst diagnosed by MRI in five dogs.** *Aust Vet J* 2003; 81: 340–343.
- 21 Duque C, Parent J, Brisson B, et al. **Intracranial arachnoid cysts: are they clinically significant?** *J Vet Intern Med* 2005; 19: 772–774.
- 22 Bagley RS. **Intracranial surgery.** In: Slatter DH (ed). Textbook of small animal surgery. Vol 1. 3rd ed. Philadelphia, PA: Elsevier Science, 2003, pp 1261–1277.
- 23 Dewey CW and Marino DJ. **Congenital brain malformation.** In: Tobias KM (ed). Veterinary surgery: small animal. Vol 1. St Louis, MO: Elsevier, 2012, pp 517–529.
- 24 Ciricillo SF, Cogen PH, Harsh GR, et al. **Intracranial arachnoid cysts in children. A comparison of the effects of fenestration and shunting.** *J Neurosurg* 1991; 74: 230–235.
- 25 Harsh GR, 4th, Edwards MS and Wilson CB. **Intracranial arachnoid cysts in children.** *J Neurosurg* 1986; 64: 835–842.
- 26 Duz B, Kaya S, Daneyemez M, et al. **Surgical management strategies of intracranial arachnoid cysts: a single institution experience of 75 cases.** *Turk Neurosurg* 2012; 22: 591–598.
- 27 Go KG, Houthoff HJ, Blaauw EH, et al. **Arachnoid cyst of the sylvian fissure: evidence of fluid secretion.** *J Neurosurg* 1984; 60: 803–813.