



Digital flexor tendon contracture treated by tenectomy: different clinical presentations in three cats

Authors: Cabon, Quentin, Plante, Jérôme, and Gatineau, Matthieu

Source: Journal of Feline Medicine and Surgery Open Reports, 1(2)

Published By: SAGE Publishing

URL: <https://doi.org/10.1177/2055116915597237>

BioOne Complete (complete.BioOne.org) is a full-text database of 200 subscribed and open-access titles in the biological, ecological, and environmental sciences published by nonprofit societies, associations, museums, institutions, and presses.

Your use of this PDF, the BioOne Complete website, and all posted and associated content indicates your acceptance of BioOne's Terms of Use, available at www.bioone.org/terms-of-use.

Usage of BioOne Complete content is strictly limited to personal, educational, and non - commercial use. Commercial inquiries or rights and permissions requests should be directed to the individual publisher as copyright holder.

BioOne sees sustainable scholarly publishing as an inherently collaborative enterprise connecting authors, nonprofit publishers, academic institutions, research libraries, and research funders in the common goal of maximizing access to critical research.



Digital flexor tendon contracture treated by tenectomy: different clinical presentations in three cats

Journal of Feline Medicine and Surgery
Open Reports
 1–7

© The Author(s) 2015
 Reprints and permissions:
sagepub.co.uk/journalsPermissions.nav
 DOI: 10.1177/2055116915597237
jfmsopenreports.com



Quentin Cabon², Jérôme Plante¹ and Matthieu Gatineau¹

Abstract

Case series summary Three cats, Siamese or Siamese cross, were presented with a chronic thoracic limb weightbearing lameness. Previous anti-inflammatory administrations were unable to improve lameness consistently in the three cats. Two of the three cats had undergone onychectomy several years before presentation. A permanent flexion of the proximal interphalangeal joint of one or more digits, associated with a difficult and painful extension of the proximal interphalangeal joint, was noticed during orthopedic examination. A digital flexor tendon contracture was suspected and confirmed with radiographic examination. Surgical exploration was then performed. For all cats, treatment consisted of a tenectomy or tenotomy of the superficial and deep digital flexor tendons in order to release the contracture. The three cats responded well to the surgical treatment and became sound around 2–4 weeks after surgery.

Relevance and novel information Digital flexor tendon contracture is rarely reported as a cause of lameness in cats. It should be considered in a differential diagnosis of feline lameness whenever onychectomy has been performed in the past. The precise etiology that explains this tendon contracture is unknown, but trauma or breed predisposition could represent potential causes.

Accepted: 17 April 2015

Introduction

Digit pathologies are quite common in dogs and cats. Digit lesions are most often associated with fractures, luxations, wounds, shearing injuries or tumors, and, less commonly, osteomyelitis or osteoarthritis.¹ Various surgical interventions are feasible, and digit amputation or luxation reduction is the most frequently performed treatment.¹ Feline onychectomy is also a common surgery in North America, despite debate over the ethics of this procedure. Complications after digit surgery or onychectomy are quite common.² Flexor tendon contracture has been described as a chronic complication of this procedure.³ Feline digital flexor tendon pathology, especially tendon contracture, is not well described. To our knowledge, only one report in the veterinary literature describes this type of pathology.³ The term contracture refers to an abnormal pathologic process resulting in fibrosis and permanent damage to a muscle, characterized by replacement of the muscle and/or associated tendon with fibrous connective tissue.⁴ This phenomenon leads to shortening of the tendon or the muscle, and can have functional

consequences on the range of motion of adjacent joints.⁴ Most contractures are associated with a previous trauma, weeks to months before the contracture occurs, but repetitive strains, infectious diseases, ischemia, compartment syndrome or neoplasia may also lead to contracture.⁴ This case series reports three different clinical presentations of digital flexor tendon contracture in three cats, all successfully treated by tenectomy.

Case 1

A 4-year-old neutered male Siamese cat weighing 4.8 kg was presented to a referral hospital for chronic left forelimb weight-bearing lameness of 1 year's duration.

¹DMV Veterinary Centre, Montréal (Lachine), Québec, Canada

²Surgery Department, VetAgroSup, Veterinary Campus of Lyon, Marcy l'Etoile, France

Corresponding author:

Jérôme Plante PhD, DES, Dipl ECVS, DMV Veterinary Centre, 2300 54th Avenue, Montréal, Québec, Canada
 Email: jplante@centredmv.com



Creative Commons CC-BY-NC: This article is distributed under the terms of the Creative Commons Attribution-NonCommercial 3.0 License (<http://www.creativecommons.org/licenses/by-nc/3.0/>) which permits non-commercial use, reproduction and distribution of the work without further permission provided the original work is attributed as specified on the SAGE and Open Access page (<http://www.uk.sagepub.com/aboutus/openaccess.htm>).

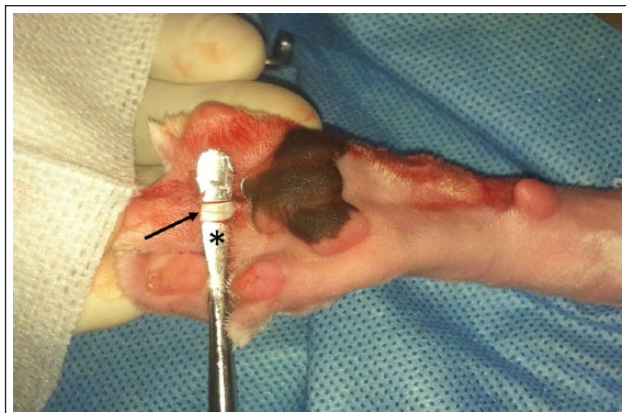

Figure 1 Intraoperative plantar visualization of the flexor tendons of the third digit before tenectomy (black arrow), exposed with a periosteal elevator (*). Left is distal, right is proximal, up is medial, down is lateral)

The cat showed mild and transient lameness improvement with meloxicam (0.05 mg/kg PO q24h Metacam; Boehringer Ingelheim), but long-term medication did not show any additional benefits. The cat had undergone onychectomy 3.5 years before presentation. Upon examination, the cat showed very mild lameness, with the left forelimb constantly non-weight bearing at rest. A permanent flexion of the proximal interphalangeal joint of the left forelimb second digit was noted. Asymmetry of the proximal interphalangeal joint was obvious when compared with the contralateral limb. Extension of the proximal interphalangeal joint was possible but very difficult and palpation of this digit was significantly painful. The rest of the physical and orthopedic examination was uneventful.

Six months after initial presentation, the cat was presented for follow-up, without improvement. Radiographic views of the left forelimb extremity revealed an abnormal positioning of the middle phalanx. Indeed, the angulation between the middle and proximal phalanges was decreased and reached almost 90° between these two phalanges on the second digit. There was no evidence of retention of remnants, osteomyelitis or hyperostosis of the distal phalanx. After discussion with the owner, exploratory surgery was scheduled.

Following premedication with hydromorphone (0.1 mg/kg IV Hydromorphone; Summit) and acepromazine (0.02 mg/kg IV Atravent; Boehringer Ingelheim), general anesthesia was induced with propofol (4 mg/kg IV Diprivan; AstraZeneca) and maintained with 2% isoflurane (Forane; Baxter) in 100% oxygen after orotracheal intubation. The cat was placed in dorsal recumbency, and the palmar surface from mid-radius to the extremity of the limb was clipped and aseptically prepared. Surgery involved a palmar approach to the proximal interphalangeal joint of the second digit, with a midline skin incision extending from the distal aspect of the

carpal pad to the proximal aspect of the metacarpal pad. Following blunt dissection, the deep and superficial digital flexor muscle tendons were visualized and elevated, and a portion of the tendons (5 mm) were transected with a #15 scalpel blade (Figure 1). The surgical wound was copiously lavaged with 0.9% sodium chloride (0.9% Sodium Chloride Irrigation; Baxter). The subcutaneous tissues were closed with a continuous pattern, using a 4-0 absorbable monofilament (Poliglecaprone 25, Monocryl; Ethicon). The skin was closed with an interrupted pattern, using a 4-0 non-absorbable monofilament (Polyamide 6, Ethilon II; Ethicon). The recovery and postoperative periods were uneventful. The patient was discharged from the hospital the day after the surgery with strict rest instructions for 3 weeks and meloxicam (0.05 mg/kg q24 h PO) for 2 weeks.

Two weeks after surgery, the owner mentioned that the cat was very active, walking normally at home and was more playful than before surgery. Upon follow-up examination no lameness was observed, and manipulation of the left proximal interphalangeal joint of the second digit was normal and pain free. Two years after surgery the owner reported that the cat was totally sound, very active and had returned to its usual activity level.

Case 2

A 7-month-old neutered female Siamese weighing 3 kg was presented for a lameness of the left forelimb of 2 months' duration. The owner reported that the lameness was most likely due to a trauma that occurred 2 months previously and was permanent since the incident. The cat received two different unknown non-steroidal anti-inflammatories before presentation at our hospital and did not show any improvement. The cat had not undergone onychectomy. Upon examination, the lameness was moderate at a walk and severe and non-weight bearing when the cat was running. At rest, a non-weight bearing stance was also obvious on the left forelimb. A permanent flexion of the proximal interphalangeal joint was noted on the fourth digit of the left forelimb. Asymmetry of the proximal interphalangeal joint was obvious when compared with the contralateral limb. Extension of the proximal interphalangeal joint was possible but very difficult. Palpation of this digit also induced some discomfort.

Five months after initial presentation, the cat was presented for the same condition, without any improvement regarding lameness or comfort upon palpation. Radiographic views of the left forelimb extremity revealed an abnormal positioning of the middle phalanx compared with the proximal phalanx, characterized by a decreased angulation between these two phalanges on the fourth digit. All three phalanges were observed in this cat, without bony or articular lesions. After discussion with the owner, an exploratory surgery was scheduled.

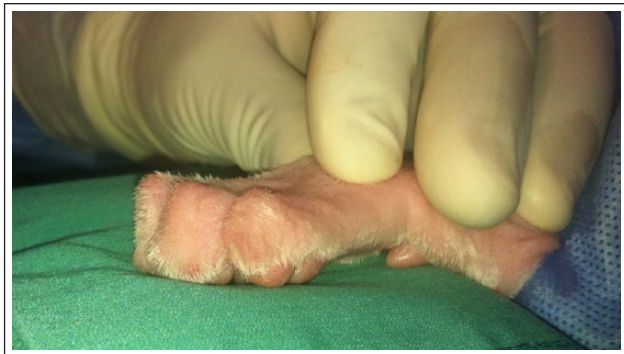

Figure 2 Preoperative aspect of the distal extremity of the thoracic limb in case 3. Flexor contracture of all digits can be visualized (left is distal, right is proximal, up is dorsal, down is plantar)

Following premedication with butorphanol (0.1 mg/kg IV Torbugesic; Pfizer), general anesthesia was induced with propofol (4 mg/kg IV) and maintained with 2% isoflurane in 100% oxygen after orotracheal intubation. A tenectomy of the deep and superficial digital flexor muscle tendons was performed as previously described for the first case. The surgical preparation and operative technique were similar to those used in case 1, except that the surgical site was the tendons of the fourth digit. The cat was discharged from the hospital the day after surgery with strict rest instructions for 3 weeks and meloxicam (0.05 mg/kg q24h orally) for 2 weeks.

At the 2 week re-evaluation, the cat still presented a mild lameness of the left thoracic limb, although the extension of the proximal interphalangeal joint of the fourth digit was improved compared with preoperative examination. However, a mild stiffness of this joint was still present. One month after surgery, the cat was totally sound and manipulation of the digit was not painful. At a 1.5 year postoperative follow-up, the owner reported that the cat was not limping anymore, was pain free and had returned to its normal activity.

Case 3

A 7-year-old neutered male Siamese cross weighing 6 kg presented with right forelimb lameness, which had appeared a month earlier. The owner also reported that the cat had undergone onychectomy at 6 months of age. The cat received a non-steroidal anti-inflammatory treatment (0.05 mg/kg q24h PO meloxicam) for 2 weeks before presentation and did not show any improvement in lameness. Upon examination, the cat's right forelimb was non-weight bearing at rest, and the cat was uncomfortable while walking on both forelimbs. A permanent flexion of the proximal interphalangeal joint was noted in all four digits of both forelimbs (Figure 2). Digit extension was still possible but was painful bilaterally for digits III and IV. Moreover, a 3 mm diameter white firm and

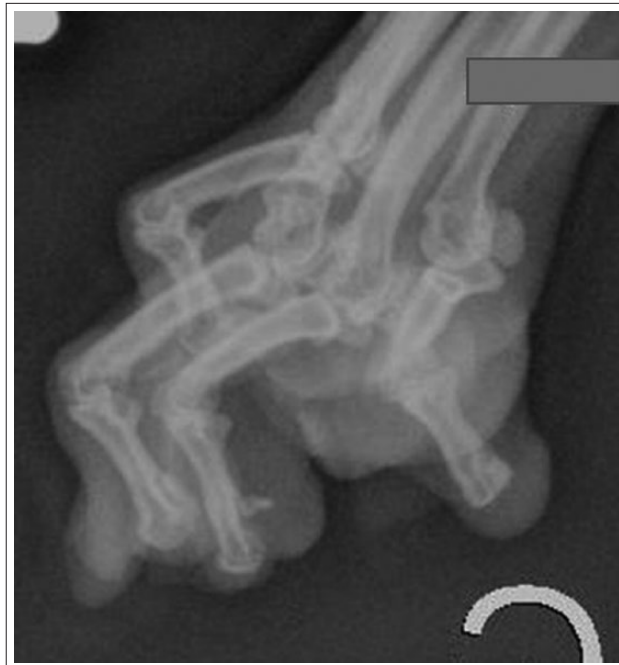

Figure 3 Forelimb oblique extremity radiographic view of the left limb in case 3. An abnormal positioning between the middle and the proximal phalanx is observed in the four digits. The angulation between these two phalanges is decreased and reached almost 90° in all digits

painful callus was palpable at the craniodistal aspect, bilaterally, of the third and fourth digital pads. Radiographic views of the forelimb extremity revealed an abnormal positioning on both limbs between the middle and the proximal phalanx. Indeed, the angulation between these two phalanges was decreased and reached almost 90° in all digits. No bony or articular lesion or osteomyelitis of the proximal and middle phalanges was observed. Remnants of the distal phalanx were not observed in the radiographs (Figure 3). A digital flexor tendon contracture of both forelimb digits was then suspected, and, after discussion, the owner agreed to surgical treatment.

Following premedication with hydromorphone (0.1 mg/kg IV), general anesthesia was induced with alfaxalone (2 mg/kg IV Alfaxan; Abbott Laboratories) and maintained with 2% isoflurane in 100% oxygen after orotracheal tube placement. A local regional anesthetic bloc was performed bilaterally with bupivacaine (0.5 mg/kg SC Marcaïne 0.5%; Hospira Healthcare Corporation). The surgical preparation was similar to that used in case 1. The surgical procedure was performed as described in case 1 for digits III and IV of both forelimbs, and a tenotomy was performed on digits II and V on both forelimbs (Figure 4). Some parts of the digital flexor tendons were submitted for histopathology. The cat was discharged from the hospital the day after the surgery with strict rest instructions for 3 weeks, meloxicam

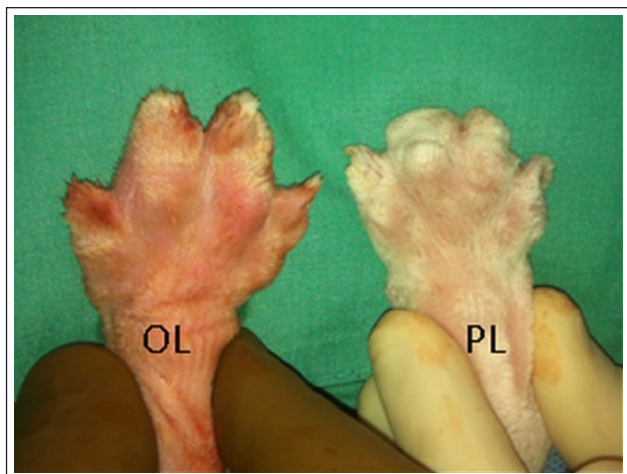


Figure 4 Perioperative dorsal view of an operated limb (OL) and a preoperative limb (PL) in case 3. Flexor contracture is well visualized in PL compared with OL
OL = on the left; PL = on the right

(0.05 mg/kg q24h PO) for 6 days and buprenorphine (20 µg/kg q8h sublingually buprenorphine; Chiron Compounding Pharmacy) for 7 days.

At the 2 week follow-up, the cat was totally sound and manipulation of the forelimb digits was very comfortable. At rest, digits were in hyperextension (Figure 5). Histopathologic examination of some parts of the flexor tendons revealed dense and thick collagen bundles associated with a few non-reactive small fibroblasts. Superficial, loosely arranged, fibrovascular tissue was noted. These observations were considered to be consistent with a chronic degeneration or trauma of this tendon. A definitive diagnosis of flexor tendon contracture was made (Figure 6).

Discussion

The three cats reported in this study presented with chronic mild forelimb lameness associated with reduction of the normal extension of the proximal interphalangeal joint of one or more digits. A contracture of the digital flexor tendon was suspected and confirmed by histopathologic analysis in one case. This case series is of particular interest because it describes three different presentations of digital flexor tendon contracture in cats. In case 1, which involved an onychectomized cat, tendon contracture involved only one digit, which is different from the two cases reported by Cooper et al.³ In case 2, the cat developed a tendon contracture on a digit, although it had not undergone onychectomy. Case 3 is more comparable to the cases reported by Cooper et al because this case involved tendon contracture of all digits in both forelimbs after onychectomy.³ However, such an important delay, as seen in this case, between onychectomy and the development of digital flexor tendon

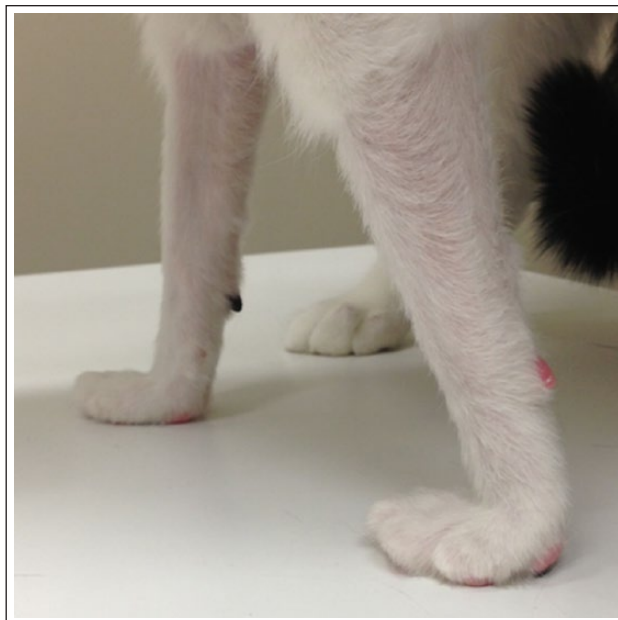

Figure 5 Thoracic limbs of case 3, 4 weeks after flexor tendon tenectomy and tenotomy

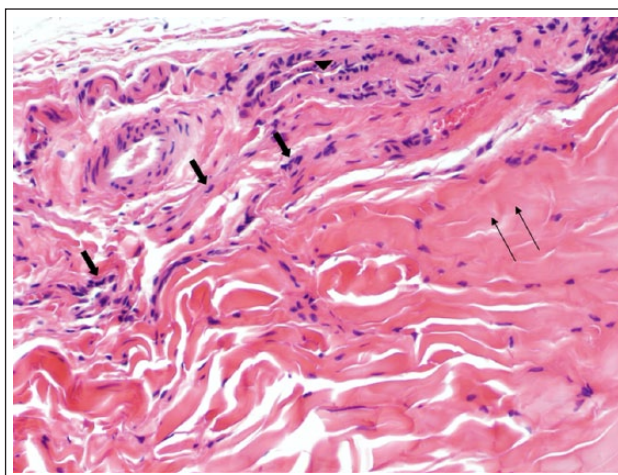


Figure 6 Photomicrograph of a tendon section from a domestic cat. Note the presence of increased well-differentiated fibroblasts (large arrows) in the tendon accompanied by few small-caliber blood vessels (arrowhead) and thin collagen fibers (thin arrows). These changes have been interpreted as reactive fibroplasia. Stained with hematoxylin and eosin (× 200, 5 µm section)

contracture has not been previously reported. Tenectomy of the affected digits was performed in all cats. We elected to perform only tenotomy on digits II and V in case 3 because of a satisfactory intraoperative contracture release after tenotomy. However, although we thought that tenectomy was not mandatory to relieve contracture in these digits, it could have been a valuable option for treatment of contracture. The surgical outcome

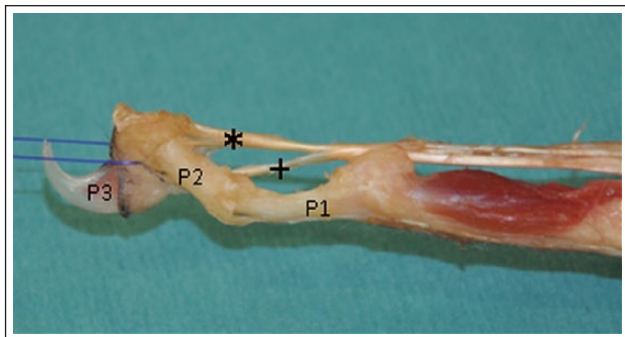


Figure 7 Distal aspect of flexor tendon anatomy on a third thoracic digit (distal digital annular ligament has been removed). *Deep flexor tendon; P1 = proximal phalanx; P2 = middle phalanx; P3 = distal phalanx; (+) = superficial flexor tendon

was excellent in all cats, as in the two cases reported elsewhere.³ Flexor contracture can be painful and disabling and can induce abnormal contact on normally non-contact areas of the digits. A phalangeal mechanical dysfunction can also be a cause of the lameness. Contracture release by tenectomy or tenotomy seemed to improve the lameness quickly, while long-term anti-inflammatory treatments failed in each of the cases reported here.

The deep and superficial digital flexor tendons provide digital flexion through contraction of the muscle bellies.³ More precisely, the proximal interphalangeal joint is flexed by the action of the superficial digital flexor and the distal interphalangeal joint is flexed by the deep digital flexor.³ The superficial digital flexor (flexor digitorum superficialis) tendon runs on the palmar surface of the deep digital flexor tendon (flexor digitorum profundus). It splits distally into four parts, which diverge to the second to fifth metacarpophalangeal joints, with the corresponding terminal tendons of the deep flexor tendon.⁵ Each superficial digital flexor ends on the proximal aspect of the palmar surface of the middle phalanx after being perforated by its respective deep flexor tendon, which ends on the tuberosity of the distal phalanges of digits II–V (Figure 7).⁵ Those superficial and deep tendons are bridged by three transverse ligaments, at the metacarpophalangeal joints and at the proximal and middle phalangeal joints, on each of the four main digits.⁵ In two of the cases reported here, tendon contracture was only found on one digit. Therefore, the cause of the contracture must have been distal to the common tendon. With the third cat, the contracture could have been located more proximally than the tendon division, but multiple contractures of the distal portion of each superficial digital flexor tendon were confirmed by histopathologic analysis.

A precise etiology is unknown in these cats. However, a traumatic episode was reported by the owner of case 2, and this could have been the initial cause of the flexor

tendon damage that led to a chronic problem. Two cats presented for bilateral and painful flexor tendon contracture following onychectomy have been previously reported.³ Both cats underwent onychectomy 6 weeks and 3 months before presentation, respectively, and had all digits of both front paws fixed in flexion.³ Tenectomy of each deep digital flexor tendon successfully resolved the condition, and the cats were sound 2 months after surgery.³

The authors hypothesized that the postoperative contracture was the result of inflammation due to a suboptimal surgical technique (excessive or rough tissue manipulation, use of a dull scalpel blade, improper use of tissue adhesives or poor aseptic technique).³ These factors could elicit an abnormal inflammatory response and result in flexor fibrosis, adhesion formation and evolution toward flexor tendon contracture.³ Tobias et al reported that the duration of the surgery, which was potentially secondary to a suboptimal surgical technique, was correlated with the occurrence of postoperative lameness.² This association could also be observed with persistent long-term lameness but the number of cases observed was considered too low to determine such an association.²

The anatomic relation between the deep digital flexor tendon and the middle phalanx could explain the long-term contracture. Indeed, traumatic resection of the distal phalanx could be the cause of an inflammatory reaction in the area of the distal extremity of the middle phalanx and the deep digital flexor tendon. Fibrosis between these two anatomic parts could create clinical, permanent digit flexion.

In addition to contracture of the digital flexor, other complications have been associated in 0–40% of cases of onychectomy in cats, such as pain, hemorrhage, lameness, swelling, non-weightbearing, infection, claw regrowth, middle phalanx protrusion and palmigrade stance.^{2,6} Lameness is usually an early postoperative complication and is associated with pain, which resolves in 2 days but can persist for up to 2 months.² However, some undiagnosed postoperative contracture could possibly explain long-term lameness. Cases 1 and 3 underwent onychectomy 3.5 and 6.5 years before presentation, respectively. The postoperative flexor contracture was previously reported in the first months after onychectomy but long-term postoperative contracture after onychectomy could explain undiagnosed chronic pain in some cats and particularly in cats 1 and 3.³ Thus, digital flexor tendon contracture cannot be ruled out because of an increased delay from the onychectomy. A trauma was suspected for the second cat, as no previous onychectomy was performed on this patient.

Digital flexor tendon injuries in dogs and cats are uncommon and most often result from laceration by sharp or penetrating foreign objects.¹ These types of

lesion require wound management and accurate tendon surgical repair. Other conditions of digital flexor tendons are rare, and only a few cases have been reported. A report of a 10-month-old male Great Dane affected by an excessive non-painful flexion of the digits of the right forelimb (more pronounced on the fourth digit) has been published.⁷ This dog was lame for 2 months. Restricted extension of the fourth digit was confirmed under general anesthesia, and a modified Z-tenotomy was performed. Surgery provided a very good outcome, as postoperative extension of the affected digit was possible and pain free, and no lameness was noted 7 months after surgery.⁷ A 5-month-old Basset Hound was also reported with simple incomplete syndactyly (fusion of the third and fourth digital pads on a hindlimb) and secondary contracture of the deep digital flexor tendon of the third and fourth digit.⁸ With this dog, the deep digital flexor tendon contracture was suspected to be secondary to the primary congenital anomaly and was treated by palmar tenotomy. The surgical outcome was good, with no lameness 8 months postoperatively.

The first two cats reported here were middle-aged indoor Siamese cats, and the third case was a Siamese cross. Siamese cats are under-represented in our hospital population. They are known to be predisposed to many diseases, including cardiovascular, dermatologic, endocrine, gastrointestinal, hematologic, infectious and musculoskeletal conditions, such as congenital myasthenia gravis, mucopolysaccharidosis VI or hip dysplasia.⁹ We can speculate that Siamese cats may be predisposed to digital flexor tendon contracture. However, this hypothesis needs to be confirmed with additional cases and with tendon histopathologic analysis to find a more specific cause to the digital flexor contracture.

Finally, a condition known as 'trigger finger' exists in human.^{10,11} This pathology is a flexor tendon entrapment of the digits that is characterized by locking of the fingers, with or without pain.¹⁰ The flexor entrapment is due to hypertrophy, narrowing and relative stenosis of the palmar retinacular sheath (most often the transverse ligament at the metacarpophalangeal joint), which progressively restricts the motion of the flexor tendon.¹⁰⁻¹² The precise etiology is not well understood and repetitive finger movements or local trauma leading to a progressive loss of fingers extension is currently the most plausible hypothesis.^{11,13} Diagnosis is usually made by history and clinical presentation. Different treatments, such as medical treatment, joint immobilization, or corticosteroid injections, have been tried to manage the disease but surgical treatment is indicated when conservative management fails to resolve the pain and clinical signs.¹¹ The surgical treatment consists of resection of

the metacarpophalangeal transverse ligament, with or without resection of the superficial flexor tendon, and is highly effective with low associated complication and recurrence rates.^{11,14}

Conclusions

Digital flexor contracture can affect an isolated digit or all digits of a limb and is characterized by a chronic lameness and a painful permanent flexion of the affected digit. In contrast to medical management, tenectomy of the deep and superficial flexor tendons is associated with a good-to-excellent surgical outcome for this condition. Etiology of this contracture is unknown but trauma, whether related to an onychectomy or not, seems to predispose a cat to this condition. This pathology could therefore be considered as a long-term complication of onychectomy in some cases. However, further cases need to be reported to better understand the pathogenesis of this condition. Digit evaluation seems to be of paramount importance when investigating cases of chronic lameness in cats.

Funding The authors received no specific grant from any funding agency in the public, commercial or not-for-profit sectors for the preparation of this case report.

Conflict of interest The authors do not have any potential conflicts of interest to declare.

References

- 1 Kapatkin AS, Garcia-Nolen T and Hayashi K. **Carpus, metacarpus and digits**. In: Tobias KM and Johnston SA (eds). *Veterinary surgery small animal*. St Louis, MO: Elsevier Saunders, 2012, pp 785–800.
- 2 Tobias KS. **Feline onychectomy at a teaching institution: a retrospective study of 163 cases**. *Vet Surg* 1994; 23: 274–280.
- 3 Cooper MA, Laverty PH and Soiderer EE. **Bilateral flexor tendon contracture following onychectomy in 2 cats**. *Can Vet J* 2005; 46: 244–246.
- 4 Taylor J and Tangner CH. **Acquired muscle contractures in the dog and cat. A review of the literature and case report**. *Vet Comp Orthop Traumatol* 2007; 20: 79–85.
- 5 Evans HE. **Muscles of the thoracic limb**. In: Evans HE (ed). *Miller's anatomy of the dog*, 3rd ed. Philadelphia, PA: WB Saunders, 1993, pp 333–349.
- 6 Patronek GJ. **Assessment of claims of short- and long-term complications associated with onychectomy in cats**. *J Am Vet Med Assoc* 2001; 219: 932–937.
- 7 Bailey CJ and Culvenor JA. **The surgical management of superficial digital flexor contracture in a Great Dane**. *Aust Vet J* 2007; 85: 20–22.
- 8 Towle H, Friedlander K, Ko R, et al. **Surgical treatment of simple syndactylism with secondary deep digital flexor tendon contracture in a Basset Hound**. *Vet Comp Orthop Traumatol* 2007; 20: 219–223.

- 9 Gough A. **Siamese**. In: Gough A and Thomas A (eds). *Breed predispositions to diseases in dogs and cats*. Oxford: Blackwell Publishing, 2004, pp 172–175.
- 10 Moore JS. **Flexor tendon entrapment of the digits (trigger finger and trigger thumb)**. *J Occup Environ Med* 2000; 42: 526–545.
- 11 Makkouk AH, Matthew AE, Oetgen E, et al. **Trigger finger: etiology, evaluation, and treatment**. *Curr Rev Musculoskelet Med* 2008; 1: 92–96.
- 12 Akhtar S. **Management and referral for trigger finger**. *BMJ* 2005; 331: 30–33.
- 13 Hueston JT and Wilson WF. **The etiology of trigger finger: explained on the basis of intratendinous architecture**. *Hand* 1972; 4: 257–260.
- 14 Favre Y and Kinnen L. **Resection of the flexor digitorum superficialis for trigger finger with proximal interphalangeal joint positional contracture**. *J Hand Surg* 2012; 37: 2269–2272.