



## **Dorsally located corneal dermoid in a cat**

Authors: LoPinto, Alexander J, Pirie, Chris G, Huynh, Thanhthao, and Beamer, Gillian

Source: Journal of Feline Medicine and Surgery Open Reports, 2(1)

Published By: SAGE Publishing

URL: <https://doi.org/10.1177/2055116916641970>

---

BioOne Complete ([complete.BioOne.org](http://complete.BioOne.org)) is a full-text database of 200 subscribed and open-access titles in the biological, ecological, and environmental sciences published by nonprofit societies, associations, museums, institutions, and presses.

Your use of this PDF, the BioOne Complete website, and all posted and associated content indicates your acceptance of BioOne's Terms of Use, available at [www.bioone.org/terms-of-use](http://www.bioone.org/terms-of-use).

Usage of BioOne Complete content is strictly limited to personal, educational, and non - commercial use. Commercial inquiries or rights and permissions requests should be directed to the individual publisher as copyright holder.

---

BioOne sees sustainable scholarly publishing as an inherently collaborative enterprise connecting authors, nonprofit publishers, academic institutions, research libraries, and research funders in the common goal of maximizing access to critical research.



# Dorsally located corneal dermoid in a cat

Alexander J LoPinto<sup>1</sup>, Chris G Pirie<sup>1</sup>,  
 Thanhthao Huynh<sup>2</sup> and Gillian Beamer<sup>2</sup>

*Journal of Feline Medicine and Surgery*  
*Open Reports*  
 1–4

© The Author(s) 2016  
 Reprints and permissions:  
[sagepub.co.uk/journalsPermissions.nav](http://sagepub.co.uk/journalsPermissions.nav)  
 DOI: 10.1177/2055116916641970  
[jfmsopenreports.com](http://jfmsopenreports.com)

This paper was handled and processed  
 by the American Editorial Office (AAFP)  
 for publication in JFMS



## Abstract

**Case summary** A 2-month-old, male kitten was presented for evaluation of unilateral blepharospasm and epiphora involving the right eye. Ocular examination revealed conjunctivitis, a superficial corneal ulcer, reflex anterior uveitis and a haired mass within the dorsal cornea of the right eye. The mass was subsequently removed surgically via a lamellar keratectomy. Histologic evaluation of the mass via light microscopy revealed it to be comprised of normal-haired skin with mild inflammation. One week after surgical removal and medical management of the corneal ulcer, all ocular clinical signs had resolved with minimal corneal scarring. On re-examination 6 months following surgical excision of the mass, the kitten was noted to be comfortable with no significant corneal scarring.

**Relevance and novel information** To our knowledge, this is the first case report of a dorsally located corneal dermoid in a cat.

**Accepted:** 8 March 2016

## Introduction

A dermoid is a localized area of normal tissue that develops in an abnormal location.<sup>1</sup> The composition of a dermoid can vary and may include epidermis, dermis, fat, sebaceous glandular tissue, hair follicles and hair.<sup>2</sup> Ocular dermoids can develop in a variety of locations, including the eyelids, conjunctiva, nictitating membrane and cornea.<sup>3</sup> Ocular dermoids have been reported in multiple species, including cats,<sup>4</sup> dogs,<sup>5</sup> horses,<sup>6</sup> cows,<sup>7</sup> pigs,<sup>8</sup> rabbits<sup>9</sup> and guinea pigs.<sup>10</sup> Although a dermoid is a developmental abnormality present at birth, ocular dermoids may not be identified until secondary complications arise.<sup>11</sup> These may include chronic epiphora, keratitis and corneal ulceration.<sup>12,13</sup> If secondary complications develop and are associated with ocular pain, surgical excision of a corneal dermoid is recommended.<sup>1</sup> Overall, ocular dermoids occur infrequently in cats.<sup>14</sup> In this report, we discuss the rare clinical presentation and treatment of a corneal dermoid in a domestic shorthair kitten. To our knowledge, this is the first case report of a dorsally located corneal dermoid of a cat.

## Case description

A 2-month-old, male, domestic shorthair kitten was presented to the ophthalmology service at the Cummings Veterinary Medical Center at Tufts University for

evaluation of blepharospasm and epiphora involving the right eye. On ocular examination, both eyes were visual with intact dazzle and pupillary light reflexes. Menace response was absent bilaterally, which was considered to be a normal finding given the age of the kitten. Swelling and mild conjunctival hyperemia of the right eye was noted. Additionally, a mass within the dorsal cornea, approximately 5 mm in length, spanning from the 10 to 2 o'clock position was noted (Figure 1). The clinical appearance of this haired corneal mass was consistent with a dermoid. A superficial corneal ulcer was noted ventrolateral to the dermoid, which was positive on fluorescein staining. Additionally, signs consistent with chronic and severe reflex uveitis were noted, including miosis, flare, hypopyon, hyphema and iridal color

<sup>1</sup>Department of Clinical Sciences, Cummings Veterinary Medical Center at Tufts University, North Grafton, MA, USA

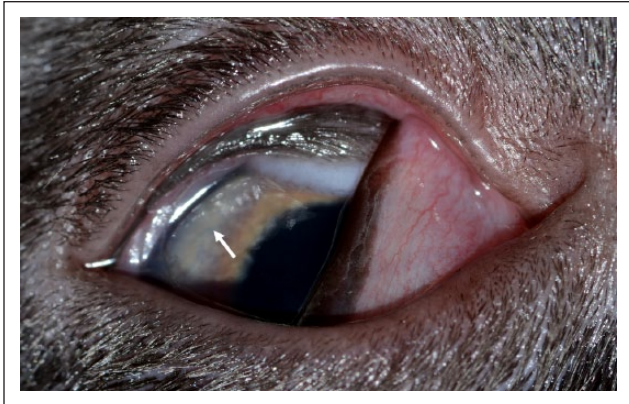<sup>2</sup>Department of Biomedical Sciences, Cummings Veterinary Medical Center at Tufts University, North Grafton, MA, USA

### Corresponding author:

Chris Pirie DVM, DACVO, Cummings Veterinary Medical Center at Tufts University, 55 Willard St, North Grafton, MA, USA  
 Email: [chris.pirie@tufts.edu](mailto:chris.pirie@tufts.edu)



Creative Commons Non Commercial CC-BY-NC: This article is distributed under the terms of the Creative Commons Attribution-NonCommercial 3.0 License (<http://www.creativecommons.org/licenses/by-nc/3.0/>) which permits non-commercial use, reproduction and distribution of the work without further permission provided the original work is attributed as specified on the SAGE and Open Access pages (<https://us.sagepub.com/en-us/nam/open-access-at-sage>).



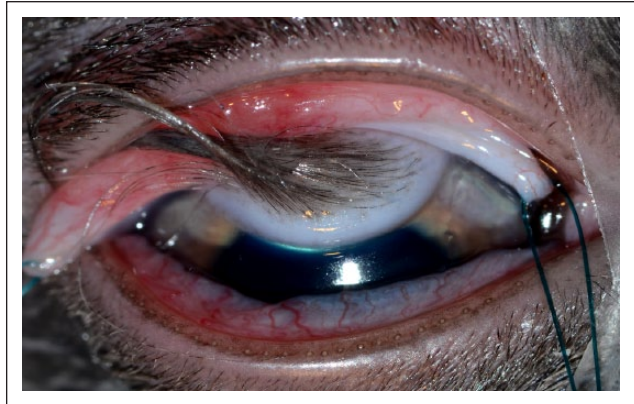
**Figure 1** Clinical photograph of the right eye of a 2-month-old kitten on initial presentation for evaluation of blepharospasm and epiphora. Note the haired mass at the dorsal aspect of the cornea and the superficial ulcer located ventral to the mass (arrow). The third eyelid is elevated owing to ocular pain. The pupil is mid-range as a result of the mydriatic that was applied following ocular examination and prior to ophthalmic photography

change (ie, darkening). The remainder of the ocular and physical examination was normal.

Medical and surgical treatment options were discussed with the owner. Medical management included an Elizabethan collar, a topical antibiotic, a topical mydriatic and topical artificial tears, as well as a systemic pain medication. As persistent irritation and ulceration from the hairs arising from the dermoid were considered likely, medical treatment was not recommended. Surgical removal of the dermoid via lamellar keratectomy was recommended in order to treat the corneal irritation permanently. The owner elected surgical removal of the dermoid.

The kitten was subsequently hospitalized overnight to initiate medical therapy. Treatment included topical oxytetracycline hydrochloride with polymyxin B sulfate ophthalmic ointment (Terramycin; Pfizer) (1/4 inch strip, OD, q8h), tropicamide ophthalmic solution (Akorn) (1 drop, OD, q8h), preservative-free artificial tears (I-Drop Vet; I-MED Pharma) (1 drop, OD, q8h) and famciclovir (Apotex) (33 mg/kg, PO, q12h). An Elizabethan collar was placed to prevent self-trauma.

The following day, the kitten was premedicated with oxymorphone hydrochloride (Opana; Endo Pharmaceuticals) (0.05 mg/kg IM), alfaxalone (Alfaxan; Jurox) (1 mg/kg IM) and glycopyrrolate (American Regent) (0.02 mg/kg IM). It was induced via alfaxalone (Alfaxan; Jurox) (3 mg/kg IV) and ketamine hydrochloride (Putney) (2 mg/kg IV) and maintained on sevoflurane gas inhalant (SevoFlo; Abbott Animal Health) for surgical excision of the haired corneal mass. The kitten was placed in dorsal recumbency with the affected eye positioned under the operating microscope. The cornea and periocular tissues



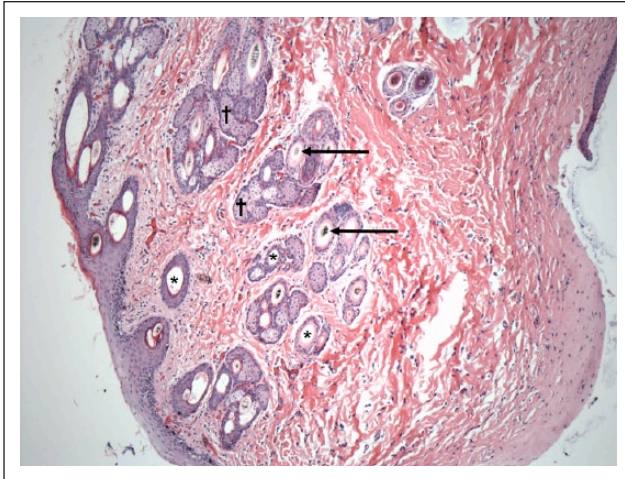
**Figure 2** Clinical photograph of the right eye of the kitten in Figure 1 at the time of surgery. Note the full extent of the haired mass located within the dorsal aspect of the cornea. The globe has been rotated ventrally via a conjunctival stay suture

were routinely prepped with a 1% betadine solution. A single stay suture was placed within the dorsal bulbar conjunctiva using 5-0 nylon suture (Ethilon; Johnson & Johnson) to aid in globe positioning/manipulation during the surgical procedure (Figure 2). The haired mass was completely excised by a non-penetrating, lamellar keratectomy, commencing from the lateral aspect of the dermoid and involving a third of the corneal stroma depth, including 1 mm of normal corneal tissue circumferentially. The neighboring dorsal bulbar conjunctiva was undermined and excised in order to remove the dermoid en bloc. The biopsy specimen was placed in 10% formalin and submitted for light microscopy to confirm the clinical suspicion of a corneal dermoid.

Microscopic examination of the haired mass identified that the corneal stroma contained a nodule composed of multiple well-differentiated adnexal units with secondary hairs and sebaceous glands embedded within adipose tissue (subcutis), loose collagenous and vascular stroma (dermis), with an overlying multifocally keratinized and stratified squamous epithelium (epidermis) (Figure 3). All anatomic segments of the hair follicle were represented, including the dermal hair papilla, the isthmus with trichohyaline granule-containing keratinocytes and the infundibulum, which contains keratinocytes exhibiting trocholemmal cornification. Few hair shafts were pigmented brown–yellow. The dermis-like stroma contained small numbers of viable neutrophils, lymphocytes and plasma cells.

Once excised, anesthetic recovery was uneventful and the kitten was hospitalized overnight. Topical and systemic medical management was continued as previously described, with the addition of heterologous equine serum (1 drop, OD, q6h) and buprenorphine (0.015 mg/kg IV) for pain. Buprenorphine was administered intravenously in the immediate postoperative time period





**Figure 3** A  $\times 10$  photomicrograph of the haired mass that was excised from the dorsal cornea. Note the ectopic hair follicles (\*), hair shafts (arrows) and surrounding sebaceous glandular tissue (t) within the subcutis of the dermoid

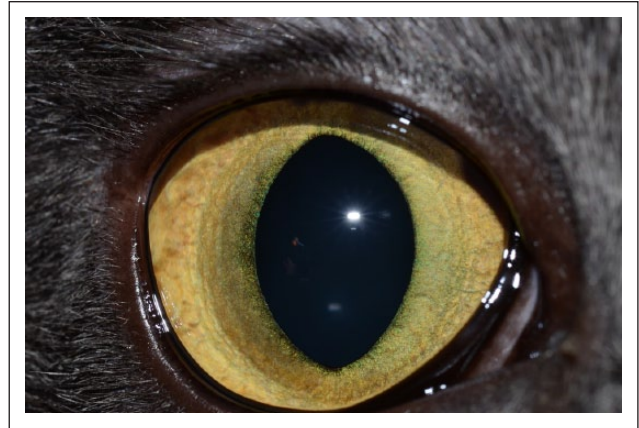
and continued PO (sublingual q8h) as needed. The following day, the kitten appeared comfortable and visual. The iatrogenic corneal defect and superficial corneal ulcer were stable. The bulbar conjunctival hyperemia and swelling, in addition to indicators of uveitis (ie, flare), were improved. Owing to the rapid improvement in the clinical indicators of uveitis postoperatively, as well as the potential risks associated with both topical (ie, delayed healing) and systemic (ie, age of the animal) anti-inflammatories, these medications were not employed. The kitten was subsequently discharged to the care of his owner with instructions to continue the same topical and systemic medications administered while in the hospital. An Elizabethan collar was recommended to be worn at all times.

At the 1 week recheck, ocular examination revealed complete resolution of both corneal defects with no fluorescein retention and minimal corneal scarring at the site of the previous dermoid. Mild conjunctivitis was noted. Additionally, all indicators of prior reflex uveitis (ie, flare, miosis, hyphema and hypopyon) were resolved. Based on examination findings, all medications were discontinued except for the Terramycin ophthalmic ointment. This medication was continued primarily for its surface anti-inflammatory properties and was instructed to be continued OD q8h for one more week.

Ocular examination 6 months later revealed a smooth and regular corneal profile, with no evidence of corneal scarring and/or pigmentation (Figure 4).

## Discussion

In this report, we discuss a case of an ocular dermoid, located within the dorsal cornea of a 2-month-old kitten. This was confirmed by microscopic examination to be



**Figure 4** Clinical photograph of the right eye of the kitten from Figures 1 and 2, 6 months after mass removal via lamellar keratectomy. No corneal scarring is present

composed of normal epidermal, dermal and subcuticular elements.<sup>1</sup> Inclusion of these surface ectoderm and neural crest-derived tissues are thought to occur during closure of the fetal clefts when abnormal invagination of ectodermal tissue later in gestation results in a pocket of differentiated dermal tissue.<sup>15</sup> In dogs, ocular dermoids are most frequently located at the temporal limbus; however, they can also involve the conjunctiva, eyelid, nictitating membrane, limbus or cornea.<sup>1</sup> In cats, ocular dermoids have been primarily reported to occur at the temporal limbus.<sup>16,17</sup> To our knowledge, this is the first reported case of a feline ocular dermoid to involve the dorsal aspect of the cornea.

Ocular dermoids seem to occur spontaneously; however, in the Birman breed, a multifactorial mode of inheritance with a threshold phenomenon has been proposed.<sup>4</sup> Independent of the true underlying etiology, variations in dermoid size can be seen.<sup>18</sup> Additionally, concurrent ocular abnormalities may exist.<sup>19</sup> For example, Koch described a case series of three Burmese cats that all had an incomplete lateral canthus, minimal dermoid formation and accessory lacrimal gland swelling.<sup>18</sup> Similarly, Christmas reported on the diagnosis and surgical correction of congenital ocular and nasal dermoids and third eyelid gland prolapse in related Burmese kittens.<sup>20</sup> Alternatively, a single dermoid can also involve multiple locations on a single eye. Carter and Himes described a cat with an epibulbar dermoid that involved the sclera, bulbar conjunctiva, and temporal aspect of the left eye and upper eyelid.<sup>16</sup> Interestingly, the cat also had a small conjunctival dermoid present at the corresponding position of the other eye.

An ocular dermoid that contains hairs can result in irritation of surrounding tissue, leading to epiphora, conjunctival and corneal inflammation, and corneal ulceration.<sup>21</sup> It is recommended to remove a dermoid surgically when these clinical signs are seen as a means to provide comfort and prevent permanent changes to the

ocular tissues. One should also remove a dermoid if it is obstructing vision.<sup>1</sup> In the case described, the abnormally located hairs were the cause of the superficial corneal ulcer and conjunctivitis diagnosed on initial examination. Surgical removal of the tissue by non-penetrating lamellar keratectomy resulted in resolution of the chronic irritation, allowing the cornea and surrounding tissues to heal with no corneal scarring. Owing to the potential sight-threatening complications associated with lamellar keratectomy (ie, delayed healing, infection, keratomalacia, inadvertent corneal perforation, bleeding and excessive corneal scarring), experience with microsurgical techniques and the ability to work well with magnification (ie, operating microscope) are necessary.

## Conclusions

Corneal dermoids are rare in cats, and although they can result in significant discomfort and secondary complications, surgical removal is generally curative with a good visual outcome. Although previous reports of dermoids in cats exist, this is the first known description of a cat with a dorsally located corneal dermoid.

**Funding** The authors received no financial support for the research, authorship, and/or publication of this article.

**Conflict of interest** The authors declared no potential conflicts of interest with respect to the research, authorship, and/or publication of this article.

## References

- Ledbetter EC and Gilger BC. **Diseases and surgery of the canine cornea and sclera.** In: Gelatt KN, Gilger BC and Kern TJ (eds). *Veterinary ophthalmology*. 5th ed. Ames, IA: John Wiley & Sons, 2013, pp 983–986.
- Grahn BH and Peiffer RL. **Veterinary ophthalmic pathology.** In: Gelatt KN, Gilger BC and Kern TJ (eds). *Veterinary ophthalmology*. 5th ed. Ames, IA: John Wiley & Sons, 2013, pp 456–457.
- Latimer CA and Wyman M. **Neonatal ophthalmology.** *Vet Clin North Am Equine Pract* 1985; 1: 235–259.
- Hendy-Ibbs PM. **Familial feline epibulbar dermoids.** *Vet Rec* 1985; 116: 13–14.
- Gelatt KN. **Bilateral corneal dermoids and distichiasis in a dog.** *Vet Med Small Anim Clin* 1971; 66: 658–659.
- Gornik KR, Pirie CG and Beamer GL. **Unilateral choristoma of the nictitating membrane in a horse.** *J Am Vet Med Assoc* 2015; 246: 231–235.
- Barkyoumb SD and Leipold HW. **Nature and cause of bilateral ocular dermoids in Hereford cattle.** *Vet Pathol* 1984; 21: 316–324.
- Brightman AH, Everitt J and Bevier G. **Epibulbar solid dermoid choristoma in a pig.** *Vet Pathol* 1985; 22: 292–294.
- Wagner F, Brüggemann M, Drommer W and Fehr M. **Corneal dermoid in a dwarf rabbit (*Oryctolagus cuniculi*).** *J Am Assoc Lab Anim Sci* 2000; 39: 39–40.
- Gupta BN. **Scleral dermoid in a guinea pig.** *Lab Anim Sci* 1972; 22: 919–921.
- Moore PA. **Feline corneal disease.** *Clin Tech Small Anim Pract* 2005; 20: 83–93.
- Dubielzig R. **Diseases of the eyelids and conjunctiva.** In: Dubielzig R, Ketring K, McLellan G, et al (eds). *Veterinary ocular pathology: a comparative review*. St Louis, MO: Saunders Elsevier, 2010, pp 143–199.
- Maggs D. **Conjunctiva.** In: Maggs D, Miller P and Ofri R (eds). *Slatter's fundamentals of veterinary ophthalmology*. 4th ed. St Louis, MO: Elsevier, 2008, pp 148–149.
- Stiles J. **Feline ophthalmology.** In: Gelatt KN, Gilger BC and Kern TJ (eds). *Veterinary ophthalmology*. 5th ed. Ames, IA: John Wiley & Sons, 2013, pp 1500–1501.
- Cook CS. **Ocular embryology and congenital malformations.** In: Gelatt KN, Gilger BC and Kern TJ (eds). *Veterinary ophthalmology*. 5th ed. Ames, IA: John Wiley & Sons, 2013, pp 22–25.
- Carter J and Himes R. **Epibulbar dermoid involving the sclera, conjunctiva and eyelid in a cat.** *Am Coll Vet Toxicol News* 1971; 7: 14–20.
- Labue R, Jones B and Johnstone A. **Congenital dermoid in a cat.** *N Z Vet J* 1985; 33: 154–155.
- Koch SA. **Congenital ophthalmic abnormalities in the Burmese cat.** *J Am Vet Med Assoc* 1979; 174: 90–91.
- Narfstrom K. **Hereditary and congenital ocular disease in the cat.** *J Feline Med Surg* 1999; 1: 135–141.
- Christmas R. **Surgical correction of congenital ocular and nasal dermoids and third eyelid gland prolapse in related Burmese kittens.** *Can Vet J* 1992; 33: 265–266.
- Glaze MB. **Congenital and hereditary ocular abnormalities in cats.** *Clin Tech Small Anim Pract* 2005; 20: 74–82.