



Accidental alfaxalone overdose in a mature cat undergoing anaesthesia for magnetic resonance imaging

Authors: Bayldon, Wendy, Carter, Jennifer E, Beths, Thierry, Warne, Leon N, Whitem, Ted, et al.

Source: Journal of Feline Medicine and Surgery Open Reports, 2(1)

Published By: SAGE Publishing

URL: <https://doi.org/10.1177/2055116916647740>

BioOne Complete (complete.BioOne.org) is a full-text database of 200 subscribed and open-access titles in the biological, ecological, and environmental sciences published by nonprofit societies, associations, museums, institutions, and presses.

Your use of this PDF, the BioOne Complete website, and all posted and associated content indicates your acceptance of BioOne's Terms of Use, available at www.bioone.org/terms-of-use.

Usage of BioOne Complete content is strictly limited to personal, educational, and non - commercial use. Commercial inquiries or rights and permissions requests should be directed to the individual publisher as copyright holder.

BioOne sees sustainable scholarly publishing as an inherently collaborative enterprise connecting authors, nonprofit publishers, academic institutions, research libraries, and research funders in the common goal of maximizing access to critical research.



Accidental alfaxalone overdose in a mature cat undergoing anaesthesia for magnetic resonance imaging

Wendy Bayldon, Jennifer E Carter, Thierry Beths, Leon N Warne, Ted Whittem, Lorena Martinez and Sébastien H Bauquier

Journal of Feline Medicine and Surgery
Open Reports
1–6

© The Author(s) 2016
Reprints and permissions:
sagepub.co.uk/journalsPermissions.nav
DOI: 10.1177/2055116916647740
jfmsopenreports.com

This paper was handled and processed by the European Editorial Office (ISFM) for publication in JFMS Open Reports



Abstract

Case summary This case report describes the clinical signs and treatment of an alfaxalone 10 times overdose in a 12-year-old cat undergoing anaesthesia for MRI. The cat was discharged from hospital following a prolonged recovery including obtunded mentation and cardiorespiratory depression for several hours following cessation of anaesthesia. The cat received supportive therapy that included supplemental oxygen via a face mask, intravenous crystalloid fluids and active rewarming. The benefits of using alfaxalone for maintenance of anaesthesia, its pharmacokinetics and previously reported lethal doses are discussed. Strategies for reducing the incidence of medication errors are presented.

Relevance and novel information An unintentional overdose of alfaxalone by continuous rate infusion has not been reported previously in a cat. Treatment is supportive and directed towards maintenance of the cardiorespiratory systems. Whenever possible, smart pumps that have been designed to reduce human error should be used to help prevent medication errors associated with continuous rate infusions.

Accepted: 25 March 2016

Introduction

Alfaxalone 2-hydroxypropyl-beta-cyclodextrin (Alfaxan-CD RTU; Jurox) is a synthetic neuroactive steroid anaesthetic used for induction and maintenance of anaesthesia. Anaesthetic and muscle relaxation effects produced by alfaxalone are attributed to enhancement and modulation of the inhibitory gamma (γ) aminobutyric acid (GABA) neurotransmitter at the GABA_A receptor complex.^{1–3} Intravenous administration of alfaxalone results in rapid onset of anaesthesia, fast redistribution, short elimination half-life and, consequently, short duration of action – properties suitable for continuous rate infusions (CRI).^{4,5}

The benefits of using alfaxalone in cats include minimal changes in cardiovascular parameters including heart rate (HR), blood pressure (BP), cardiac output, pulmonary arterial pressure and systemic vascular resistance at clinically relevant dose rates, and less adverse influence on respiration than propofol.^{1,4} No biochemical or haematological changes have been reported in cats and no clinically relevant pharmacokinetic accumulation has been described when consecutive maintenance doses of

alfaxalone (2 mg/kg every 7 mins) were administered to healthy cats.^{1,5}

There is little information on the types of medication errors and strategies to prevent medication errors in the veterinary profession. This case report describes the inadvertent overdose of alfaxalone by CRI during partial intravenous anaesthesia in conjunction with isoflurane in a cat. Alfaxalone was administered at 25.2 ml/h to a cat weighing 4.2 kg. This resulted in the cat receiving 1 mg/kg/min of alfaxalone rather than the intended 0.1 mg/kg/min of alfaxalone, due to human miscalculation.

Translational Research and Animal Clinical Trials (TRACTs), Veterinary Hospital, Faculty of Veterinary and Agricultural Sciences, The University of Melbourne, Werribee, VIC 3030, Australia

Corresponding author:

Wendy Bayldon, Translational Research and Clinical Trials (TRACTs), Veterinary Hospital, Faculty of Veterinary and Agricultural Sciences, The University of Melbourne, Werribee, VIC 3030, Australia
Email: Bauquier@unimelb.edu.au



Creative Commons Non Commercial CC-BY-NC: This article is distributed under the terms of the Creative Commons Attribution-NonCommercial 3.0 License (<http://www.creativecommons.org/licenses/by-nc/3.0/>) which permits non-commercial use, reproduction and distribution of the work without further permission provided the original work is attributed as specified on the SAGE and Open Access pages (<https://us.sagepub.com/en-us/nam/open-access-at-sage>).

Strategies that could have prevented this overdose from occurring are discussed.

Case description

A 12-year-old, 4.2 kg male neutered Birman cat was presented for MRI to investigate progressive hindlimb ataxia and lumbosacral pain. The owners reported one episode of 'seizure-like' activity approximately 2 years earlier, which resulted in admission to an emergency department. Serum biochemistry and haematology were performed at that time and they were within normal range. After administration of thiamine injections, the cat recovered and no further investigations were undertaken.

On presentation, the cat was bright, alert and responsive. Physical examination findings were unremarkable. Neurological examination findings were consistent with right-sided thoracolumbar myelopathy and marked lumbosacral pain. The remainder of the neurological examination was within normal limits. Serum biochemistry revealed mild elevations in alanine aminotransferase (102 U/l, reference interval [RI] 5–80 U/l), creatine kinase (615 U/l, RI 50–400 U/l), total solids (TS) (81 g/l, RI 60–80 g/l) and hypercholesterolaemia (8.2 mmol/l, RI 1.9–3.9 mmol/l). The packed cell volume (PCV) was 38%, haematology was unremarkable and cryptococcus antigen was negative.

Preanaesthetic medications included methadone (Methadone Hydrochloride; Aspen Pharma) 0.5 mg/kg in combination with dexmedetomidine (Dexmedetomidine Hydrochloride; Zoetis, Orion Pharma) 3 µg/kg intramuscularly administered using an insulin syringe and needle (30 G, 12.7 mm) (BD Ultra-Fine; BD Biosciences) in the epaxial muscles in the cervical region. Twenty minutes later, a 22 G intravenous (IV) catheter (Introcan Safety; B Braun) was placed into the right cephalic vein. Following 5 mins of preoxygenation, anaesthesia was induced with IV alfaxalone (Alfaxan-CD RTU; Jurox) administered to effect to a total dose of 2.5 mg/kg. One spray of lidocaine hydrochloride (5 mg/spray) and phenylephrine hydrochloride (0.5 mg/spray) (Co-Phenylcaine Forte; ENT Technology) was applied to the larynx. The trachea was intubated with a size 3.5 mm internal diameter MRI compatible orotracheal tube and the cuff inflated until no leak could be detected at 20 cm of water (cmH₂O). The tube was connected to a paediatric rebreathing circle system and oxygen flow was set at 1 l/min (Small Animal Anaesthesia Machine; SurgiVet CDS 2000 [Smiths Medical PM]).

Five minutes after induction the cat was transferred onto the MRI table and positioned in dorsal recumbency. Warmed hot packs were placed alongside the cat and it was covered with towels to maintain body temperature. Positive pressure ventilation was started using an MRI-compatible, volume-controlled mechanical ventilator

(Small Animal Ventilator; Mallard Medical) set at a respiratory rate (RR) of 10 breaths per minute and tidal volume of around 10 ml/kg, adjusted to maintain a partial pressure of end-tidal CO₂ (PETCO₂) between 35 and 45 mmHg. Isoflurane (IsoFlo; Abbott) (vaporiser setting 1%) in oxygen (O₂, 1 l/min) was administered in combination with an alfaxalone CRI (alfaxalone 10 mg/ml at 25.2 ml/h or 1 mg/kg/min) to maintain anaesthesia. A balanced crystalloid solution (Hartmann's Solution for Injection; Fresenius Kabi) was administered intravenously at 10 ml/kg/h during anaesthesia. MRI-compatible fluid pumps (MEDRAD; Caesarea Medical Electronics) were used to administer fluid therapy and the alfaxalone CRI in ml/h. A syringe attachment was used for the alfaxalone CRI.

A multiparametric anaesthesia monitor (Vet Advisor Vital Signs Monitor V9203; SurgiVet, Smiths Medical) was used to monitor electrocardiogram, HR, RR, PETCO₂ and oxygen haemoglobin saturation (by pulse oximetry [SpO₂]) outside of the MRI room. Inside the MRI room, a multiparametric monitor (MEDRAD, Veris, Criticare Care Systems) was used. Body temperature was not monitored, while in the MRI room (no MRI-compatible temperature probe was available). Arterial blood pressures were obtained throughout anaesthesia via a non-invasive oscillometric BP device (petMAP Graphic; Ramsey Medical) placed above the metacarpal region.

At 75 mins after the start of the MRI, the capnogram displayed a waveform indicative of contamination of expired sample by fresh air, which was attributed to a leak and air was added into the endotracheal tube cuff. At the same time, the alfaxalone CRI was decreased by 20%. At 105 mins after the start of the MRI, the capnogram again indicated a leak in the endotracheal tube cuff. The procedure was interrupted, the cat was taken out of the MRI room and the trachea of the cat re-intubated with a 4 mm internal diameter MRI compatible orotracheal tube and the cuff inflated until no leak could be detected at 20 cmH₂O. While the cat was out of the MRI room, hypersalivation was noted. At this time, the cat's anaesthetic plane was evaluated to be too deep, based on the absence of palpebral, corneal reflexes, the central position of the eyes and absence of jaw tone. The alfaxalone CRI was discontinued and the isoflurane vaporiser setting reduced to 0.8%. The MRI was resumed for another 45 mins. A summary of the physiological variables during that time are presented in Figure 1.

On completion of the MRI, isoflurane was discontinued and the cat remained ventilated with O₂ for an additional 30 mins until spontaneous ventilation resumed. The cat's body temperature was 35.5 °C per rectum. As the cat was showing a very slow recovery, atipamezole (0.0357 mg/kg IM [Zoetis; Orion Pharma]) followed by naloxone (0.04 mg/kg IV [Hospira Australia]) was administered 25 mins after discontinuation of isoflurane.

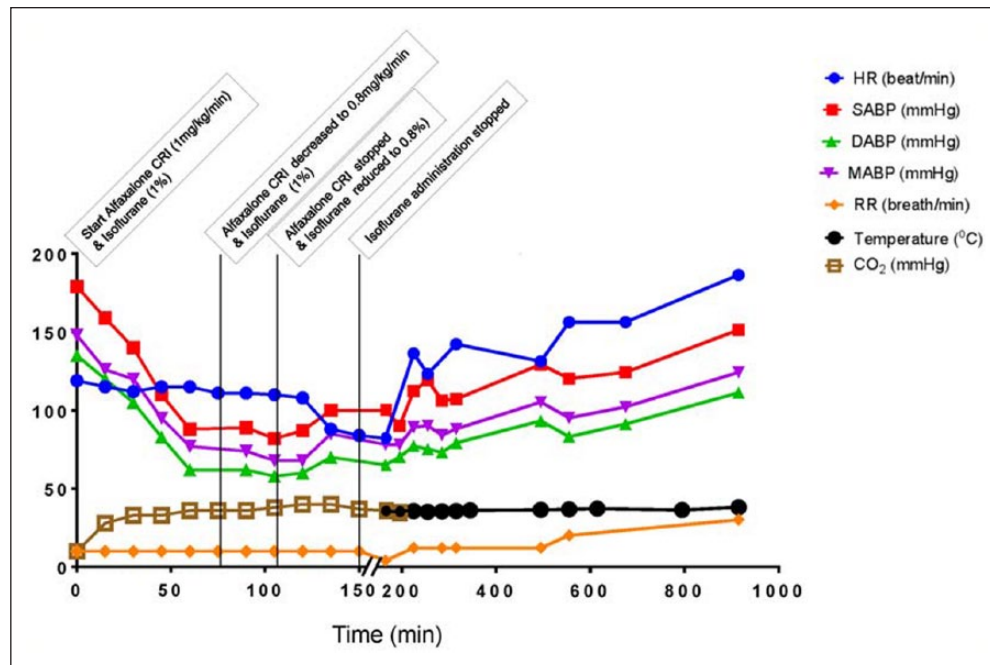


Figure 1 Physiological variables recorded during and after general anaesthesia for MRI. A cat referred for MRI to investigate a T3–L3 myelopathy was premedicated intramuscularly with methadone (0.5 mg/kg) and dexmedetomidine (3 µg/kg). At time 0, anaesthesia was induced with intravenous alfaxalone (2.5 mg/kg) and maintained with an alfaxalone continuous rate infusion (CRI) at 1 mg/kg/min and isoflurane 1%. After 75 mins, the alfaxalone CRI was reduced to 0.8 mg/kg/min and at 105 mins the alfaxalone CRI and the isoflurane were discontinued and reduced to 0.8%, respectively. Isoflurane was discontinued at 150 mins. HR = heart rate; SABP = systolic arterial pressure; DABP = diastolic arterial pressure; MABP = mean arterial blood pressure; RR = respiratory rate; Temperature = rectal temperature; CO₂ = partial pressure of end-tidal CO₂

Oxygen at 1 l/min was continued during the recovery period via the endotracheal tube. Extubation was performed 50 mins after discontinuation of isoflurane.

Owing to the cat's condition, it was transferred to the intensive care unit. Oxygen was supplemented via face mask, as SpO₂ readings were between 89% and 94%. IV fluid administration was maintained at 4.75 ml/kg/h and the cat was actively warmed with a warming blanket (Bair Hugger; Arizant Healthcare), owing to hypothermia (temperature 35.4 °C). A cough was elicited when the cat was moved and a referred upper respiratory tract noise with a fluid character was detected on thoracic auscultation at that time. The cat remained generally non-responsive (except when having its temperature taken) for 7.5 h postextubation. During this time, its HR increased from 123 to 156 beats per minute, RR increased from 12 to 20 breaths per minute and mean arterial pressure increased from 84 to 106 mmHg (Figure 1). Adequacy of ventilation was assessed by monitoring respiratory rate and chest expansion. Approximately 11 h postextubation the cat became more active, alert and responsive, although normal mentation had not yet returned. Supplemental oxygen was discontinued as a SpO₂ of 97% was maintained on room air and thoracic auscultation was unremarkable. Additional analgesia

consisting of methadone at 0.2 mg/kg IV was administered owing to persistence of the pre-MRI signs of pain. A neurological examination approximately 3.5 h post-methadone administration (14.5 h postextubation) revealed slightly reduced menace response and dilated pupils bilaterally. The rest of the cranial nerve examination was unremarkable. The cat was mildly obtunded with ambulatory paraparesis. Marked hindlimb ataxia was present, which was more severe than prior to the anaesthetic, owing to its abnormal mentation combined with its presenting condition. At this time, the cat ate food placed in front of it. Venous blood gas measurements (ABL 800 Basic Analyser; Radiometer) revealed a partial pressure of oxygen of 45.3 mmHg (RI 28.0–61.0), a partial pressure of CO₂ of 49.8 mmHg (RI 33.0–52.0), pH 7.315 (RI 7.350–7.440) and a lactate concentration of 3.7 mmol/l (RI 0.6–2.5). A repeat PCV was 35% and TS was 74 g/l. Repeat haematology was unremarkable. The cat was continued on IV fluids until discharge and no further drugs were administered. At the time of discharge (24 h after discontinuation of anaesthesia) the cat was eupnoeic, bright and of normal mentation. The MRI revealed protrusion of the intervertebral discs at the level of T12–T13, L2–L3 and L7–S1, causing compression of the spinal cord. A right-sided extradural cyst at the

level of T12–T13 articular facets and a focal right-sided contrast enhancement in the spinal cord at that level were also revealed, with differential diagnoses including inflammation (due to chronic trauma), infection and neoplasia (such as lymphoma).

Discussion

The alfaxalone CRI rate used was the equivalent of 1 mg/kg/min when the intended rate was 0.1 mg/kg/min. This calculation error resulted in an alfaxalone overdose of 10 times. After a delayed recovery, the cat recovered well. Alfaxalone was chosen for maintenance anaesthesia as it may be more suitable than propofol for CRIs in cats; propofol CRIs have been associated with prolonged anaesthetic recoveries.⁶ Cats metabolise alfaxalone in the liver by phase I and phase II enzymatic systems, whereas propofol is metabolised predominantly by phase II glucuronide and sulfate conjugation pathways.² Cats lack the major phenol uridine 5'-disphospho-glucuronosyltransferase enzyme, UGT1A9, that glucuronidates propofol.⁷ As such, continuous infusions of propofol, for even 30 mins, have been associated with long recoveries in cats.^{6,7}

Alfaxalone has non-linear pharmacokinetics and at clinical dose rates is non-cumulative to a clinically relevant extent.⁵ As such, the effects and persistence of alfaxalone at different dose rates are unpredictable. Alfaxalone has 'capacity-limited' pharmacokinetics and saturation of metabolism according to Michaelis–Menten kinetics has been described.⁵ In this case, the excessive dose of alfaxalone administered may have overwhelmed the cat's metabolic capacity, prolonging recovery time. Additionally, alfaxalone causes dose-dependent depression of cardiac output, with the most pronounced effect demonstrated at 10 times the labelled dose.¹ Decreased cardiac output and therefore hepatic blood flow may have also delayed hepatic clearance of the drug.

In an experimental study, 5/7 cats administered 50 mg/kg alfaxalone IV over 60 s displayed pronounced cardiorespiratory depression, required mechanical ventilation and, as no significant improvement was seen after 5 h, were subsequently euthanased.¹ Another experimental study resulted in a sudden and an unexpected death of one cat shortly after IV administration of 25 mg/kg alfaxalone over 60 s. Necropsy did not identify a cause of death and it was presumed due to respiratory or cardiac arrest, attributed to variation in individual responses or pharmacokinetic differences, as doses of up to 30 mg/kg had been administered safely.⁵ Neurosteroid GABA_A anaesthetics are reported to have a wide therapeutic range and high therapeutic index (>30 mg/kg) in cats, although the exact therapeutic index for alfaxalone use in cats has not yet been established.^{1,2} The cat in the present case report received 100 mg/kg of IV alfaxalone over 105 mins. It is most likely that the time frame of

alfaxalone administration allowed for some metabolism of the drug, while cardiorespiratory support enabled this cat to recover.

During the MRI, monitoring the cat's depth of anaesthesia was difficult as it was covered with a body shield. The removal of the body shield for frequent anaesthetic depth checks would have greatly extended the duration of the MRI and potentially have resulted in moving the cat. Therefore, anaesthetic depth was mainly assessed by variation in vital signs.

Clinical signs of an alfaxalone overdose are apnoea, often necessitating mechanical ventilation; decreases in HR, BP, cardiac output, pulmonary arterial pressure, systemic vascular resistance, tidal volume, PaO₂ and core body temperature; increases in arterial partial pressure of CO₂ (PaCO₂) and excess saliva or mucus production.^{1,5} In the present case, as intermittent positive pressure ventilation was provided during the MRI, more severe respiratory depression was not observed until cessation of the MRI. Although, as the end-tidal CO₂ was maintained around 40 mmHg, one could argue that in the absence of spontaneous ventilation some degree of respiratory depression was present. Also, it took 30 mins for spontaneous ventilation to resume after cessation of isoflurane and the reduced SpO₂ readings following extubation were attributed to poor ventilation.

While decreases in HR and BP were observed, they remained within acceptable limits and did not correspond to vital parameters one would expect to see in a case of severe alfaxalone overdose. However, BP readings were taken via a non-invasive BP device that has been shown to be inaccurate in hypotensive states in dogs.⁸ Similar studies have not been undertaken in cats. The cat was maintained on high IV fluid rates during anaesthesia, which were excessive and not in accordance with the new American Animal Hospital Association/American Association of Feline Practitioners fluid therapy guidelines.⁹ In addition, the cat was given 6 ml/kg/h of alfaxalone, increasing the total IV fluid administration to 16 ml/kg/h. This could have contributed to maintaining an acceptable BP. It may have also resulted in fluid overload as the cat displayed a cough and fluid sounding upper respiratory tract noise later in the intensive care unit. Alternatively, excess saliva and mucus was still being produced by the cat, due to the alfaxalone, which could explain the upper respiratory tract sound. Dexmedetomidine may have increased systemic vascular resistance and maintained adequate BP, while cardiac output and tissue perfusion was reduced. Yet an actual increase in arterial BP does not appear to be commonly seen following α_2 -agonist administration in cats.^{10,11} PETCO₂ slightly increased from 35 to 40 mmHg during the MRI, suggesting that tissue perfusion was maintained, even though accumulation of alfaxalone was occurring. Yet a mild hyperlactataemia was observed

more than 15 h following extubation, possibly due to hypoperfusion (type A lactic acidosis) as no other medical condition that could have induced type B hyperlactaemia was diagnosed. Unfortunately, a preanaesthetic serum lactate was not performed to confirm or refute this. Although it cannot be excluded, neither alfaxalone nor cyclodextrin have been associated with type B lactic acidosis (impaired cellular metabolism).^{1,12} An alternative reason could be attributed to the cat struggling during blood collection.¹³

Treatment for alfaxalone overdose is supportive and includes ventilation, oxygen supplementation, maintenance of a clear airway, IV fluid therapy and provision of warmth. There is no reversal agent for alfaxalone; however, other drugs administered that cause cardiorespiratory depression should be antagonised if possible. Supportive therapy is needed to allow the cat to maintain adequate tissue perfusion, PaO₂ and PaCO₂ while they metabolise and excrete the drug. Alfaxalone has shown dependence on hepatic blood flow for metabolism and clearance; therefore, IV fluid support should be given and cardiac output should be supported with inotropes or vasopressors if necessary.^{2,5} Rapid infusion of a lipid emulsion (similar to treatment for lidocaine intoxication) may be a potential treatment option for alfaxalone toxicoses, owing to the drug's lipid solubility.¹⁴ The high binding capacity of lipid emulsions could trap circulating alfaxalone molecules and render them inactive.^{14–17} Clinical investigations would need to be undertaken to test this theory.

There is a large body of literature on ways to prevent medication errors in human medicine, and research on ways to reduce error in the veterinary profession is increasing.^{18–22} An investigation into the types and causes of errors has identified similarities between the human and veterinary medical professions with errors classified as active failures and systems failures.²¹ In this case, active failures included cognitive limitations and a lack of technical knowledge as the anaesthetist was new to the service, distracted by undergraduate veterinary students, unfamiliar with the technique and was unable to identify that the volume of alfaxalone drawn up was excessive.²¹ Being familiar with a drug allows the clinician to double-check drug calculations instinctively by identifying any unusual volume to be administered. This anaesthetist thought the volume was large and asked two veterinary students to also calculate the alfaxalone administration rate. Both of the veterinary students calculated the same 25.2 ml/h. Alfaxalone has been recently introduced to the US and veterinarians may be unaware of the volumes required for cats. It is then even more important to have a qualified and experienced person to review the drug calculation.

The pressures of time to get this late add-on MRI case done within business hours and the basic ml/h infusion device were system failures. The lack of communication

to request adequate help led to the medication calculation error, and the design of products or equipment did not allow prevention of accidental overdose.²¹ The calculation to convert an alfaxalone CRI of 0.1 mg/kg/min into ml/h resulted in a 10-fold error, as the concentration of alfaxalone being 10 mg/ml was not included in the equation.

There are many factors that increase the risk of error, which include distraction and interruption of the anaesthetist, and the use of non-standardised protocols or unfamiliar drugs. Strategies that may have prevented the present error include quiet time for drug calculations, as there is a 13% increased chance of error with each interruption.²³ Use of infusion devices such as smart pumps, that contain dose error reduction software programs and drug libraries designed to reduce human error, have been associated with a decrease in medication administration errors from 18% to 3.6%, although they are not infallible and still require a human operator.²⁴ Having additional checking measures such as a second experienced person check drug calculations have been shown to minimise medication errors.^{18,25–27} Furthermore, safety checklists and standardisation of prescribing doses have been associated with reduced morbidity and mortality in human medical settings and improved outcomes in veterinary anaesthesia.^{20,21,28} Indeed, standardising infusion rate to mg/kg/min rather than mg/kg/h may avert a 60-fold calculation error.

Following the incident morbidity and mortality rounds, we have introduced checklists prior to induction of anaesthesia and start of surgery, including a drug check with the senior anaesthetist. This institution is also progressively introducing the same smart pump throughout the hospital for drug and fluid administration.

Conclusions

This case report presented the accidental overdose of alfaxalone in a cat that resulted in cardiorespiratory depression and a prolonged recovery. Treatment was supportive and included oxygen, fluid therapy and active warming. Simple measures to reduce the incidence of medication errors include use of smart pumps for CRIs, quiet time for drug calculations and independent drug checks.

Acknowledgements We thank Dr Robert Pope for his assistance during the postoperative period.

Conflict of interest The authors declared no potential conflicts of interest with respect to the research, authorship, and/or publication of this article.

Funding The authors received no financial support for the research, authorship, and/or publication of this article.

References

- 1 Muir W, Lerche P, Wiese A, et al. **The cardiorespiratory and anesthetic effects of clinical and supraclinical doses of alfaxalone in cats.** *Vet Anaesth Analg* 2009; 36: 42–54.
- 2 Warne LN, Beths T, Whittam T, et al. **A review of the pharmacology and clinical application of alfaxalone in cats.** *Vet J* 2015; 203: 141–148.
- 3 Lambert JJ, Belelli D and Peden DR. **Neurosteroid modulation of GABA_A receptors.** *Prog Neurobiol* 2003; 71: 67–80.
- 4 Campagna I, Schwarz A, Keller S, et al. **Comparison of the effects of propofol or alfaxalone for anaesthesia induction and maintenance on respiration in cats.** *Vet Anaesth Analg* 2015; 42: 484–492.
- 5 Whittam T, Pasloske KS, Heit MC, et al. **The pharmacokinetics and pharmacodynamics of alfaxalone in cats after single and multiple intravenous administration of Alfaxan at clinical and supraclinical doses.** *J Vet Pharmacol Ther* 2008; 31: 571–579.
- 6 Pascoe PJ, Ilkiw JE and Frischmeyer KJ. **The effect of the duration of propofol administration on recovery from anaesthesia in cats.** *Vet Anaesth Analg* 2006; 33: 2–7.
- 7 Court MH. **Feline drug metabolism and disposition: pharmacokinetic evidence for species differences and molecular mechanisms.** *Vet Clin North Am Small Anim Pract* 2013; 43: 1039–1054.
- 8 Shih A, Robertson S, Vigani A, et al. **Evaluation of an indirect oscillometric blood pressure monitor in normotensive and hypotensive anesthetized dogs.** *J Vet Emerg Crit Care* 2010; 20: 313–318.
- 9 Davis H, Jensen T, Johnson A, et al. **2013 AAHA/AAFP fluid therapy guidelines for dogs and cats.** *J Am Anim Hosp Assoc* 2013; 49: 149–159.
- 10 Monteiro ER, Campagnol D, Parrilha LR, et al. **Evaluation of cardiorespiratory effects of combinations of dexmedetomidine and atropine in cats.** *J Feline Med Surg* 2009; 11: 783–792.
- 11 Selmi AL, Mendes GM, Lins BT, et al. **Evaluation of the sedative and cardiorespiratory effects of dexmedetomidine, dexmedetomidine-butorphanol, and dexmedetomidine-ketamine in cats.** *J Am Vet Med Assoc* 2003; 222: 37–41.
- 12 Kovacic JP. **Lactic acidosis.** In: Silverstein DC and Hopper K (eds). *Small animal critical care medicine.* St Louis, MO: Saunders/Elsevier, 2009, pp 254–257.
- 13 Rand JS, Kinnaird E, Baglioni A, et al. **Acute stress hyperglycemia in cats is associated with struggling and increased concentrations of lactate and norepinephrine.** *J Vet Intern Med* 2002; 16: 123–132.
- 14 O'Brien TQ, Clark-Price SC, Evans EE, et al. **Infusion of a lipid emulsion to treat lidocaine intoxication in a cat.** *J Am Vet Med Assoc* 2010; 237: 1455–1458.
- 15 Eren Cevik S, Tasyurek T and Guneyssel O. **Intralipid emulsion treatment as an antidote in lipophilic drug intoxications.** *Am J Emerg Med* 2014; 32: 1103–1108.
- 16 Herring JM, McMichael MA, Corsi R, et al. **Intravenous lipid emulsion therapy in three cases of canine naproxen overdose.** *J Vet Emerg Crit Care* 2015; 25: 672–678.
- 17 Ozcan MS and Weinberg G. **Intravenous lipid emulsion for the treatment of drug toxicity.** *J Intensive Care Med* 2014; 29: 59–70.
- 18 Carthey J. **Medication errors: causes, prevention and reduction.** *Br J Haematol* 2002; 116: 255–265.
- 19 Heard G. **Errors in medicine: a human factors perspective.** *Australasian Anaesthesia* 2005; 5: 1–11.
- 20 Hofmeister EH, Quandt J, Braun C, et al. **Development, implementation and impact of simple patient safety interventions in a university teaching hospital.** *Vet Anaesth Analg* 2014; 41: 243–248.
- 21 Oxtoby C, Ferguson E, White K, et al. **We need to talk about error: causes and types of error in veterinary practice.** *Vet Rec* 2015; 177: 438.
- 22 Roughead L, Semple S and Rosenfeld E. **Literature review: medication safety in Australia.** In: Care ACoSaQiH (ed). Sydney: ACSQHC, 2013, pp 1–126.
- 23 Westbrook J, Woods A, Rob M, et al. **Association of interruptions with an increased risk and severity of medication administration errors.** *Arch Intern Med* 2010; 170: 683–690.
- 24 Pang RKY, Kong DCM, de Clifford JM, et al. **Smart infusion pumps reduce intravenous medication administration errors at an Australian teaching hospital.** *J Pharm Pract Res* 2011; 41: 192–195.
- 25 Abeysekera A, Bergman IJ, Kluger MT, et al. **Drug error in anaesthetic practice: a review of 896 reports from the Australian Incident Monitoring Study database.** *Anaesthesia* 2005; 60: 220–227.
- 26 Mahajan R. **Medication errors: can we prevent them?** *Br J Anaesth* 2011; 107: 3–5.
- 27 Aronson JK. **Medication errors: what they are, how they happen, and how to avoid them.** *Q J Med* 2009; 102: 513–521.
- 28 Allard J, Carthey J, Cope J, et al. **Medication errors: causes, prevention and reduction.** *Br J Haematol* 2002; 116: 255–265.