



Scapular osteomyelitis in an immature domestic shorthair cat

Authors: Viskjer, Sivert, and Rapp, Martin

Source: Journal of Feline Medicine and Surgery Open Reports, 2(2)

Published By: SAGE Publishing

URL: <https://doi.org/10.1177/2055116916668199>

BioOne Complete (complete.BioOne.org) is a full-text database of 200 subscribed and open-access titles in the biological, ecological, and environmental sciences published by nonprofit societies, associations, museums, institutions, and presses.

Your use of this PDF, the BioOne Complete website, and all posted and associated content indicates your acceptance of BioOne's Terms of Use, available at www.bioone.org/terms-of-use.

Usage of BioOne Complete content is strictly limited to personal, educational, and non - commercial use. Commercial inquiries or rights and permissions requests should be directed to the individual publisher as copyright holder.

BioOne sees sustainable scholarly publishing as an inherently collaborative enterprise connecting authors, nonprofit publishers, academic institutions, research libraries, and research funders in the common goal of maximizing access to critical research.



Scapular osteomyelitis in an immature domestic shorthair cat

Sivert Viskjer¹ and Martin Rapp²

Journal of Feline Medicine and Surgery
Open Reports
1–5

© The Author(s) 2016
Reprints and permissions:
sagepub.co.uk/journalsPermissions.nav
DOI: 10.1177/2055116916668199
jfmsopenreports.com

This paper was handled and processed
by the European Editorial Office (ISFM)
for publication in JFMS Open Reports



Abstract

Case summary A 12-week-old, male, domestic shorthair cat was presented with severe left thoracic limb lameness. Investigation included physical examination, diagnostic imaging with radiography and CT, histopathology and microbiological culture. Physical examination revealed a large, firm mass on the left scapula. Radiography and CT showed a monostotic spherical expansile bone lesion in the infraspinatus fossa of the left scapula. The histopathological description was a central acute suppurative osteomyelitis with reactive fibrosis and new bone formation at the periphery. Aerobic and anaerobic cultures were negative and the underlying cause of the osteomyelitis could not be identified. The use of broad-spectrum antibiotics for 8 weeks proved effective with full clinical recovery and no signs of relapse during the follow-up time of 8 months.

Relevance and novel information This report describes the management and outcome of a rare case of osteomyelitis with severe deformation of scapular bone morphology in an immature cat that was treated successfully with full recovery of limb function and restored integrity of the scapula.

Accepted: 16 August 2016

Introduction

Osteomyelitis (OM) is defined as an inflammatory condition of bone and bone marrow. In dogs and cats OM is most commonly caused by bacterial infection,¹ but mycotic and viral osteomyelitis have also been described.² Osteomyelitis is often classified as either haematogenous or post-traumatic in origin,³ and fracture and subsequent surgical repair represent most of the cases of post-traumatic osteomyelitis reported in companion animals.^{4–6} Normal, healthy bone in an immune-competent animal is highly resistant to infection,^{2,5} but injury and infection of adjacent soft tissue may induce a post-traumatic osteomyelitis subsequent to a bite or scratch.^{2,5,7} Haematogenous OM is uncommon in dogs and cats and typically affects young animals.^{5,6} Bacteria lodge in the capillaries in the metaphyseal area of the bone and, through inflammation and thrombus formation, create an ischaemic environment that is conducive for further bacterial growth.^{5,8}

Staphylococcal species are isolated in up to 74% of bone infections reported in small animals,⁵ and infections with a mixed bacterial flora, including aerobic and anaerobic combinations, are common.^{1,5,7,9} Osteomyelitis

may involve different bones in the body but most frequently occurs in long bones.^{1,6,10} Only a few cases of scapular osteomyelitis have been reported in dogs,^{6,11} and to our knowledge, osteomyelitis in the scapula of a cat has not previously been reported.

Case description

A 12-week-old male intact domestic shorthair cat weighing 1.1 kg was presented for a progressive lameness of the left thoracic limb first noticed by the owners a week prior to presentation. The cat had been introduced to the household with no signs of disease 2 weeks earlier. There

¹Surgery, Evidensia Strömsholm Referral Small Animal Hospital, Strömsholm, Sweden

²Diagnostic Imaging, Evidensia Strömsholm Referral Small Animal Hospital, Strömsholm, Sweden

Corresponding author:

Sivert Viskjer DVM, Evidensia Strömsholm Referral Small Animal Hospital, Djursjukhusvägen 11, 734 94 Strömsholm, Sweden

Email: sivert.viskjer@evidensia.se



Creative Commons Non Commercial CC-BY-NC: This article is distributed under the terms of the Creative Commons

Attribution-NonCommercial 3.0 License (<http://www.creativecommons.org/licenses/by-nc/3.0/>) which permits non-commercial use, reproduction and distribution of the work without further permission provided the original work is attributed as specified on the SAGE and Open Access pages (<https://us.sagepub.com/en-us/nam/open-access-at-sage>).

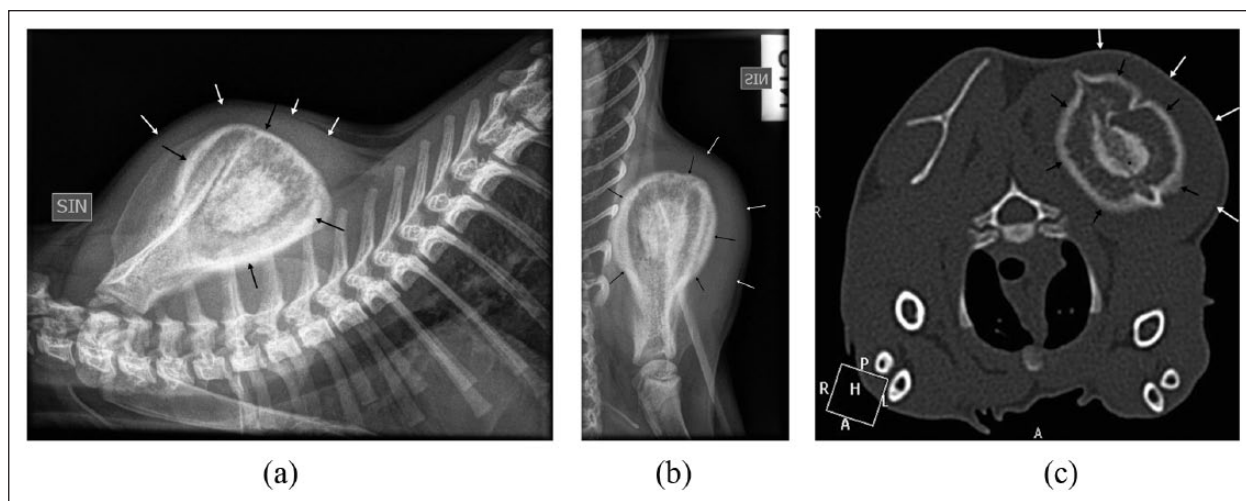


Figure 1 (a) Mediolateral projection of the left scapula showing the expansile lesion (black arrows) with adjacent soft tissue swelling (white arrows). (b) Caudocranial projection of the left scapula showing the marked expansion of the bone with aggressive periosteal reaction (black arrows), thickening of the cortex and surrounding soft tissue swelling (white arrows). (c) Transverse CT image (window level 500, window width 2000, slice thickness 1.0 mm) showing the expansile lesion (black arrows) with the central irregular heterogeneous mineral density. Surrounding soft tissue swelling (white arrows)

was one additional cat in the new household and both cats were strictly confined indoors with no physical contact with other animals.

Physical examination revealed a non-weight-bearing left thoracic limb lameness, mild muscle atrophy of the left thoracic limb and a large, firm swelling over the left scapula. No signs of skin wounds or trauma to the affected area were seen. The cat was otherwise bright, alert and responsive and no other abnormal clinical findings were noted.

Initial radiographic examination showed a monostotic spherical expansile bone lesion in the infraspinatus fossa of the left scapula with a central heterogeneous mineral opacity surrounded by a zone of radiolucency and an outer rim of sclerotic and markedly thickened cortex and periosteal new bone with thin perpendicular radiating brush border-like reactions. Swelling of the surrounding soft tissue was noted (Figure 1a,b).

CT (Philips Brilliance [40-slice]; Philips Medical Systems) was performed on the thoracic limbs. The expansile lesion had a central core of irregular mineral density with a heterogeneous lucent centre. The periosteum was thickened with a brush border-like reaction and there was marked surrounding soft tissue swelling (Figure 1c). CT of the abdomen and thorax, including lung parenchyma, was unremarkable.

The differential diagnoses for the monostotic expansile bone lesion were an aggressive disease process such as bacterial osteomyelitis with sequestrum formation, fungal osteomyelitis or bone abscess. Bone cyst or neoplasia, such as osteochondroma or osteoclastoma, were considered less likely.

It was decided to collect samples from the scapular lesion for histopathological and microbiological analyses. The cat was premedicated with medetomidine (Domitor; Orion Pharma Animal Health) 0.08 mg/kg SC, meloxicam (Metacam; Boehringer Ingelheim Vetmedica) 0.2 mg/kg SC and methadone (Metadon Recip; Meda) 0.3 mg/kg. Ketamine (Ketaminol; Intervet) 5 mg/kg was administered intramuscularly to maintain a dissociative anaesthesia. Oxygen was delivered by flow-by during the procedure. With the cat positioned in right lateral recumbency a skin incision was made centrally over the left scapula parallel to the scapular spine. Blunt dissection through subcutaneous tissue, the aponeurosis of the deltoid muscle and the infraspinatus muscle gave access to the scapular lesion. Wedge biopsies were taken with a number 11 scalpel blade from both the mineralised capsule and the softer inner core. Fresh material was placed on a sterile surgical sponge during surgery, then placed in a sterile plastic container and submitted for microbiological culture in the hospital's internal laboratory. Material fixed in 10% buffered neutral formalin was submitted for histopathological examination. The surgical site was lavaged with saline and closed routinely with 1.5 metric polyglactin 910 and nylon, and the cat recovered from anaesthesia. The cat received meloxicam 0.05 mg/kg administered orally q24h for 6 days after surgery.

Aerobic and anaerobic microbiological culture did not reveal bacterial growth.

The histopathological description of the lesion was a central acute suppurative osteomyelitis (Figure 2) with

reactive fibrosis and new bone formation in the periphery. Treatment with a first-generation cephalosporin cefadroxil (Cefadroxil; Mylan), oral suspension 20 mg/kg q12h, was initiated. The cat was re-evaluated after 3 weeks of antibiotic treatment. Physical examination revealed only a mild swelling over the left scapula and

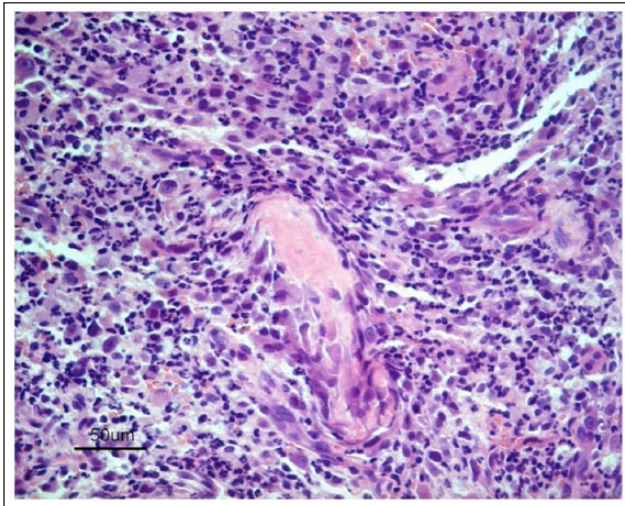


Figure 2 Light microscopic section of a decalcified biopsy from left scapula. Cell-rich inflammation with central eosinophilic acellular necrotic bone is seen. The cellular infiltrate comprises lymphocytes, plasma cells, macrophages and neutrophilic granulocytes, intermingled with nuclear debris. Haematoxylin and eosin

the lameness was completely resolved. Radiographic evaluation of the left scapula showed a markedly less aggressive lesion with a more normal trabecular pattern of the bone, thinning of the periost and decreased surrounding soft tissue swelling (Figure 3a, b).

Treatment with cefadroxil was continued to a total of 8 weeks, at which time the owners were interviewed by telephone and reported that the cat was acting completely normal, had no detectable swelling on the left scapula and no visible lameness.

The second follow-up, 20 weeks after treatment with antibiotics was initiated (12 weeks after completion of the treatment), revealed a clinically normal healthy cat with no scapular swelling and no lameness. Computed radiography and CT scan were performed which showed only mild expansion of the left infraspinatus fossa with near-normal thickness of the periosteum and no detectable periosteal reaction (Figure 4a,b). The previous central heterogeneous mineral opacity was no longer present. A telephone interview with the owner was made 8 months after completion of the treatment; the cat was described by the owner as a completely normal healthy cat with no signs of lameness or scapular swelling.

Discussion

This report describes the diagnosis, treatment and outcome of a severe deforming OM affecting the left scapula of an immature, male, domestic shorthair cat. This is the first known case of scapular OM presented to our clinic.

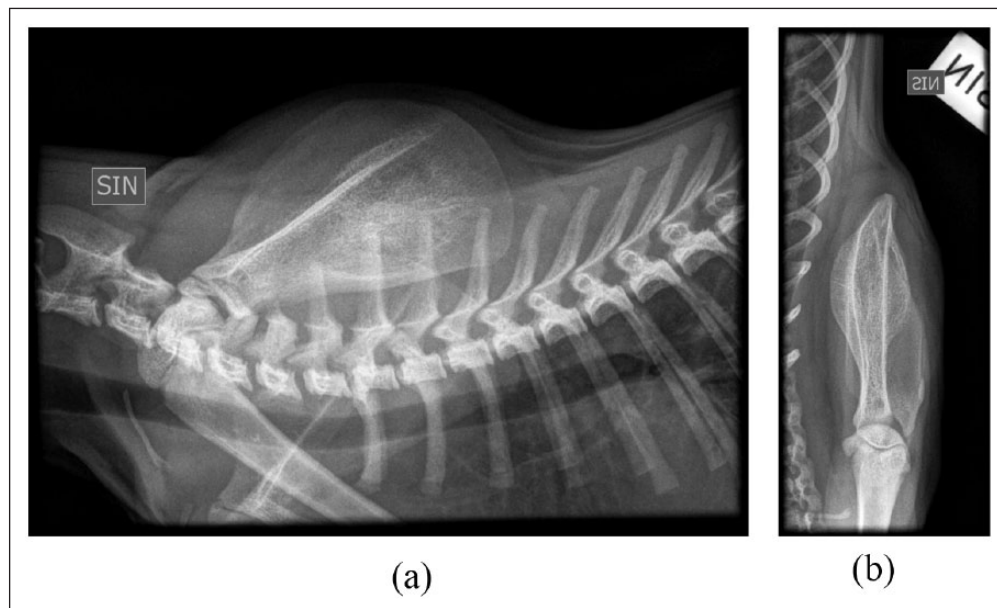


Figure 3 (a) Mediolateral projection of the left scapula at first follow-up 3 weeks after initiation of antibiotic treatment. The central lesion is less sclerotic with trabecular pattern of the bone. The periost has a smooth outline and decreased thickness with decreased surrounding soft tissue swelling. (b) Caudocranial projection of the left scapula at first follow-up 3 weeks after initiation of antibiotic treatment. The lesion appears less expansive and less active with a trabecular pattern of the bone, decreased thickness of the periost and decreased surrounding soft tissue swelling

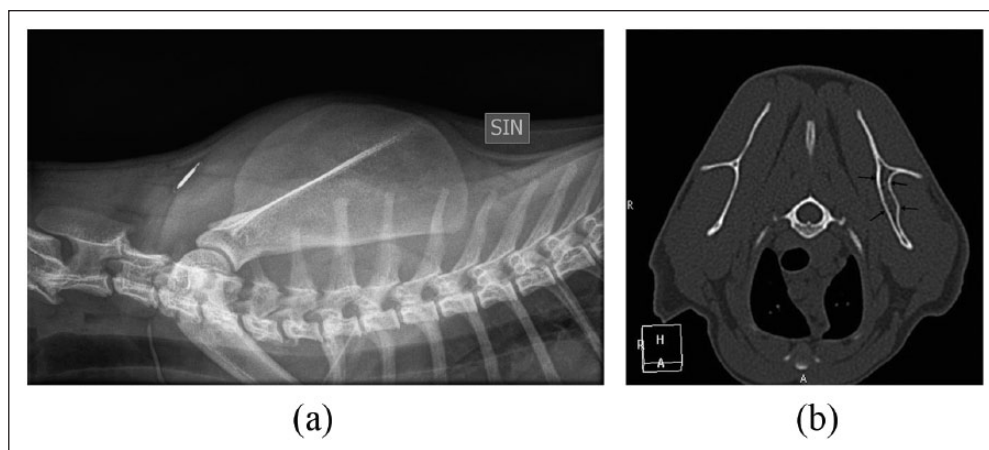


Figure 4 (a) Twenty-week follow-up mediolateral projection of the left scapula. The lesion is no longer detectable. A microchip has been implanted subcutaneously in the neck. (b) Follow-up transverse CT image (window level 500, window width 2000, slice thickness 1.0 mm). There is mild expansion of the left scapula with smoothly outlined cortex without periosteal reaction

The most common localisation of OM in small animals is within the long bones of the appendicular skeleton both for haematogenous and post-traumatic infections.^{1,6,10} Other skeletal involvement such as vertebral infections and discospondylitis are most often caused by a haematogenous spread from elsewhere in the body,¹² whereas OM of the jaw in cats is often associated with periodontal disease and caused by a broad range of bacteria, most of which are normal oral flora.¹³

There are only a few cases of scapular OM described in the veterinary literature, all of which are reported in dogs.^{6,11} This also reflects the situation in people, where only a few rare cases have been described in relatively young individuals,¹⁴ mostly haematogenous in origin, but post-traumatic cases have also been reported.¹⁵

The pathogenesis of the scapular OM in this cat could not be determined and both haematogenous as well as post-traumatic origins are possible. There was no evidence of trauma to the skin over the affected area at the initial clinical examination, but it is possible that the cat previously had a small wound or abscess that was not noticed by the owner, and by the time of presentation it had completely healed. There are reports where there is a delay of weeks between a primary soft tissue lesion and a subsequent osteomyelitis of underlying bone.⁷ Skin trauma could, in this case, potentially have occurred when the mother carried the kitten by the scruff, or from a bite or a scratch caused by littermates.

Despite culture for both aerobic and anaerobic microbes, no causative agent could be detected. There are other reports of OM where the aetiological agent could not be established but where the animals also responded well to antibiotic treatment and were successfully treated with antibiotics.^{8,16} Previous investigations on sample techniques and specimen handling have revealed the extreme importance of correct procedures to ensure optimal

laboratory results.^{2,17,18} In our case, it took approximately 15 mins before the specimen arrived in the laboratory for culture, and the specimen was, unfortunately, exposed to room air during this time. This suboptimal handling of the specimen may be a reason for the negative result of the anaerobic culturing.^{1,19} According to some authors, a suspicion of anaerobic infection should be raised in the case of a negative bacteriological culture.^{3,5}

Samples from the lesion were not cultured for fungi even though the osteomyelitis potentially could be of mycotic origin. In dogs and cats primary mycotic osteomyelitis are considered rare, it is most often haematogenous and the animals usually show signs of systemic disease.⁵ There was no histological evidence of fungal organisms within the biopsies. This cat did not show any signs of fever, lethargy or systemic disease, only local pain and lameness. The fact that treatment with antibiotics was highly effective also makes a mycotic aetiology less likely. Additional testing, with *in situ* hybridisation or PCR, may have provided further information regarding the underlying cause for the lesion seen. However, dehydration and decalcification could have altered the results according to correspondence with the laboratory involved.

For economic reasons, the owner declined urine analysis and blood analyses for complete blood counts, biochemistry, feline leukaemia virus/feline immunodeficiency virus and culture. An elevated white blood cell count together with an increased C-reactive protein could have supported an underlying infectious cause, despite the negative culture result. Other tests may have revealed signs of altered bone metabolism, immunodeficiency and/or infectious disease. However, the diagnostic value of blood tests when evaluating a localised OM is debated,²⁰ and the authors do not believe that the results of blood tests and urine analysis would have changed the treatment plan or the outcome in this case.

Conclusions

To our knowledge this is the first reported case of feline scapular osteomyelitis, and this report presents the clinical, diagnostic imaging and treatment characteristics for this rare condition. The present observations suggest that the prognosis appears to be favourable. There were no signs of recurrence during 8 months of follow-up.

Acknowledgements The authors thank Biovet Sweden for photography and histopathological interpretation.

Funding The authors received no financial support for the research, authorship, and/or publication of this article.

Conflict of interest The authors declared no potential conflicts of interest with respect to the research, authorship, and/or publication of this article.

References

- 1 Muir P and Johnson KA. **Anaerobic bacteria isolated from osteomyelitis in dogs and cats.** *Vet Surg* 1992; 21: 463–466.
- 2 Johnson KA. **Osteomyelitis in dogs and cats.** *J Am Vet Med Assoc* 1994; 205: 1882–1887.
- 3 Houlton JEF and Vannini R. **Complications of fracture treatment, osteomyelitis.** In: Johnson AL (ed). *AO principle of fracture management in the dog and cat.* Davos: AO Publishing Davos, 2005, p 416.
- 4 Caywood DD. **Osteomyelitis.** *Vet Clin North Am Small Anim Pract* 1983; 13: 43–53.
- 5 Bubenik LJ. **Infections of the skeletal system.** *Vet Clin North Am Small Anim Pract* 2005; 35: 1039–1109.
- 6 Caywood DD, Wallace LJ and Braden TD. **Osteomyelitis in the dog: a review of 67 cases.** *J Am Vet Med Assoc* 1978; 172: 943–946.
- 7 Johnson KA, Lomas GR and Wood AK. **Osteomyelitis in dogs and cats caused by anaerobic bacteria.** *Aust Vet J* 1984; 61: 57–61.
- 8 Bradley WA. **Metaphyseal osteomyelitis in an immature Abyssinian cat.** *Aust Vet J* 2003; 81: 472–475.
- 9 Read RA and Carlisle CH. **Generalized osteomyelitis in a dog: a case report.** *J Small Anim Pract* 1983; 24: 687–694.
- 10 Walker MA, Lewis RE, Kneller SK, et al. **Radiographic signs of bone infection in small animals.** *J Am Vet Med Assoc* 1975; 166: 908–910.
- 11 Stampley A. **What is your diagnosis?** *J Am Vet Med Assoc* 1989; 194: 567–568.
- 12 Thomas WB. **Diskospondylitis and other vertebral infections.** *Vet Clin North Am Small Anim Pract* 2000; 30: 169–182.
- 13 Bell CM and Soukup JW. **Histologic, clinical, and radiologic findings of alveolar bone expansion and osteomyelitis of the jaws in cats.** *Vet Pathol* 2015; 52: 910–918.
- 14 Koubaa M, Mnif H, Zrig M, et al. **Acute hematogenous osteomyelitis of the scapula in children.** *Orthop Traumatol Surg Res* 2009; 95: 632–635.
- 15 Buckley SL, Alexander AH and Barrack RL. **Scapular osteomyelitis. An unusual complication following subacromial corticosteroid injection.** *Orthop Rev* 1989; 18: 321–324.
- 16 Dunn JK, Dennis R and Houlton JEF. **Successful treatment of two cases of metaphyseal osteomyelitis in the dog.** *J Small Anim Pract* 1992; 33: 85–89.
- 17 Hindiyeh M, Acevedo V and Carroll KC. **Comparison of three transport systems (Starplex StarSwab II, the new Copan Vi-Pak Amies Agar Gel collection and transport swabs, and BBL Port-A-Cul) for maintenance of anaerobic and fastidious aerobic organisms.** *J Clin Microbiol* 2001; 39: 377–380.
- 18 Dow SW, Jones RL and Adney WS. **Anaerobic bacterial infections and response to treatment in dogs and cats: 36 cases (1983–1985).** *J Am Vet Med Assoc* 1986; 189: 930–934.
- 19 Walker RD, Richardson DC, Bryant MJ, et al. **Anaerobic bacteria associated with osteomyelitis in domestic animals.** *J Am Vet Med Assoc* 1983; 182: 814–816.
- 20 Braden TD. **Posttraumatic osteomyelitis.** *Vet Clin North Am Small Anim Pract* 1991; 21: 781–811.