



Marginal resection and adjuvant strontium plesiotherapy in the management of feline eyelid malignant peripheral nerve sheath tumours: two cases

Authors: Berlato, Davide, Serras, Ana Rita, Matas Riera, Marian, and Rasotto, Roberta

Source: Journal of Feline Medicine and Surgery Open Reports, 2(2)

Published By: SAGE Publishing

URL: <https://doi.org/10.1177/2055116916674863>

BioOne Complete (complete.BioOne.org) is a full-text database of 200 subscribed and open-access titles in the biological, ecological, and environmental sciences published by nonprofit societies, associations, museums, institutions, and presses.

Your use of this PDF, the BioOne Complete website, and all posted and associated content indicates your acceptance of BioOne's Terms of Use, available at www.bioone.org/terms-of-use.

Usage of BioOne Complete content is strictly limited to personal, educational, and non - commercial use. Commercial inquiries or rights and permissions requests should be directed to the individual publisher as copyright holder.

BioOne sees sustainable scholarly publishing as an inherently collaborative enterprise connecting authors, nonprofit publishers, academic institutions, research libraries, and research funders in the common goal of maximizing access to critical research.



Marginal resection and adjuvant strontium plesiotherapy in the management of feline eyelid malignant peripheral nerve sheath tumours: two cases

Journal of Feline Medicine and Surgery
Open Reports
 1–5

© The Author(s) 2016
 Reprints and permissions:
sagepub.co.uk/journalsPermissions.nav
 DOI: 10.1177/2055116916674863
jfmsopenreports.com

This paper was handled and processed by the European Editorial Office (ISFM) for publication in JFMS Open Reports



Daive Berlato¹, Ana Rita Serras^{1,*}, Marian Matas Riera^{2,†} and Roberta Rasotto^{3,‡}

Abstract

Case series summary Two cats with a marginally resected eyelid malignant peripheral nerve sheath tumour were treated with adjuvant strontium plesiotherapy a few weeks after surgery. The dose applied in both cases was 200 Gy to the surface, in five fractions, on a Monday–Wednesday–Friday basis. The treatment aimed to achieve a clinical margin of approximately 1 cm around the surgical scar and multiple application fields were required to cover such an area. Local recurrence was not seen in either case after 1330 and 645 days, respectively.

Relevance and novel information The majority of periocular malignant peripheral nerve sheath tumours reported in the literature recur after surgery. In the two cases described in this report the combination of surgery and adjuvant plesiotherapy has been able to provide good local control with minimal toxicity. This multimodal approach could be considered as an alternative to aggressive surgery such as enucleation or exenteration.

Accepted: 23 September 2016

Introduction

In people, peripheral nerve sheath tumours (PNSTs) are a group of neoplasms that arise from Schwann cells, perineurial cells and intraneuronal fibroblasts. Depending on their cell of origin, PNSTs can be further divided into schwannoma, neurofibroma and malignant PNSTs, respectively. According to the most recent edition of the World Health Organization's International Classification of Tumors of Domestic Animals, PNSTs are, in veterinary medicine, divided into only benign and malignant variants because of their uncertain histogenesis.¹ PNSTs can be difficult to differentiate histologically from other spindle-cell tumours such as perivascular wall tumours and fibrosarcomas, and immunohistochemistry is often required to substantiate the diagnosis. The most common immunohistochemical marker used to support the morphological diagnosis of PNSTs is S100, which is expressed in up to 100% of cases.²

A recent retrospective study described pathological and clinical characteristics of 59 PNSTs in 53 cats.² There were 43 benign PNSTs and 16 malignant PNSTs. The overall recurrence rate in the study was 23% (13/57).

The recurrence rate for benign PNSTs was 15% (6/41); none of the tumours removed with clear margins recurred (19/19), while recurrence was seen in 27% (6/22) of the incompletely removed tumours. Between benign PNSTs, only one involved the lower eyelid and the tumour recurred after incomplete excision; another three were completely removed from the periocular skin, and none of them

¹Oncology Unit, Animal Health Trust, Newmarket, UK

²Ophthalmology Unit, Animal Health Trust, Newmarket, UK

³Diagnostic Laboratory Services, Animal Health Trust, Newmarket, UK

*Current address: Hospital Veterinario de Berna, Lisbon, Portugal

†Current address: Royal Veterinary College, University of London, Hatfield, UK

‡Current address: Dick White Referrals, Six Mile Bottom, UK

Corresponding author:

Daive Berlato, Dip ECVIM-CA (Onc), MSc (Clin Onc), PhD, MRCVS, Animal Health Trust, Lanwades Park, Kentford, Newmarket CB8 7UU, UK

Email: davide.berlato@aht.org.uk



Creative Commons Non Commercial CC-BY-NC: This article is distributed under the terms of the Creative Commons

Attribution-NonCommercial 3.0 License (<http://www.creativecommons.org/licenses/by-nc/3.0/>) which permits non-commercial use, reproduction and distribution of the work without further permission provided the original work is attributed as specified on the SAGE and Open Access pages (<https://us.sagepub.com/en-us/nam/open-access-at-sage>).

recurred. The recurrence rate of malignant PNSTs was 44% (7/16); none of the tumours removed with clear margins recurred (6/6), while recurrence was seen in 70% (7/10) of the tumours removed with incomplete margin. Of the malignant PNSTs there was one tumour involving the upper eyelid and the tumour recurred after incomplete excision.

In another recent retrospective series describing 43 feline eyelid tumours submitted to a single pathology laboratory, there were three PNSTs involving the eyelid.³ In this study PNSTs were not classified as benign or malignant and margins of excision were not reported. All three eyelid PNSTs recurred after surgical excision.

A recent case series described presentation and outcome of cutaneous periocular PNSTs in six cats.⁴ As in the previous study, PNSTs were not divided into benign and malignant and margin of excision were not described. All six tumours recurred, on average, three times after conservative surgical excision. After multiple conservative surgeries, four of these cats underwent exenteration or enucleation as a curative-intent procedure; none of the cats undergoing aggressive surgery presented tumour recurrence.

Radical or wide surgical resection or debulking surgery followed by adjuvant radiotherapy is considered the treatment of choice for the management of soft tissue sarcomas in cats and dogs.⁵ However, adjuvant irradiation of the periocular area with external beam radiotherapy using curative-intent doses (>45 Gy) is limited by the risk of incurring in severe toxicity. Side effects reported in this location include dermatitis, conjunctivitis, keratitis, iritis or chronic complications such as chronic keratoconjunctivitis sicca, corneal ulceration, secondary uveitis, chronic conjunctivitis, cataract formation, radiation retinopathy and optic neuropathy.⁶⁻⁹

Strontium plesiotherapy consists of the direct application of the radioactive source to the tumour surface. Strontium 90 undergoes beta (β)-decay emitting β -particles, which are characterized by limited penetration ability into the irradiated tissue (2–3 mm). The shallow penetration is the main attraction of this treatment because it allows applying a large dose of radiation to the surface without affecting the deeper tissue. Strontium plesiotherapy has been successfully used in the treatment of various periocular tumours in cats and dogs; for example, feline mast cell tumours,^{10,11} canine limbal melanoma¹² and canine limbal hemangiosarcomas.¹³

Herein, we present the use of conservative surgery followed by adjuvant strontium plesiotherapy in the treatment of two cases of malignant feline PNSTs involving the eyelid. Histopathology and immunohistochemistry in both cases were reviewed by a board-certified pathologist (RR).

Case series description

Case 1

A 11-year-old, female, neutered, domestic longhair cat was presented to the Ophthalmology Unit with a 4 mm

mass on the left lower eyelid (Figure 1a). Cytology showed a spindle cell neoplastic population with severe nuclear atypia and occasional multinucleated cells. Staging including thoracic radiographs and abdominal ultrasound showed no evidence of metastatic disease.

Treatment options, including aggressive surgery or more conservative surgery followed by strontium plesiotherapy, were discussed with the owners and they elected for the more conservative approach. A wedge resection of the mass with double layer closure was performed, leaving a relatively tight lower eyelid (Figure 1b), but no functional problems.

Histology revealed a poorly demarcated neoplastic proliferation of spindle cells expanding the eyelid dermis and arranged in bundles with occasional nuclear palisading. These cells displayed moderate anisocytosis and marked anisokaryosis. Multinucleation was occasionally evident. Mitoses were 10 in 10 high-powered fields (HPFs). A histological diagnosis of soft tissue sarcoma, most likely a malignant PNST, was made. Immunohistochemistry showed that the neoplastic cells were positive for S100, confirming the diagnosis of malignant PNST. The margin of excision was narrow (2 mm).

Strontium plesiotherapy was started 20 days after surgery. The treatment was delivered on a Monday–Wednesday–Friday basis for five fractions to a total surface dose of 200 Gy. Each fraction consisted of five contiguous application fields to obtain a clinical margin of approximately 1 cm around the scar. The globe was protected from the radiation field using a Jaeger lid plate. No acute side effects developed during the treatment and the cat was discharged without any medication.

At re-examination 5 weeks later the owner reported no side effect apart from radiation-induced localized alopecia (Figure 1c). The left eye was comfortable, with no evidence of ophthalmic abnormalities. Eyelid function and tear production were normal. Alopecia was still present at the second re-examination 6 months later, but the remainder of the ophthalmological examination was unremarkable.

After collapsing, the cat was presented to the referring vet after 1330 days and the owner elected for euthanasia without any further investigations. At the time of the consultation there was no evidence of local recurrence. The owner did not allow a post-mortem examination.

Case 2

A 5-year-old, female, neutered, domestic shorthair cat was referred to the Oncology Unit after incomplete excision of a 7 mm mass from the lateral aspect of the left lower eyelid. A blepharoplasty had been performed to resect the mass, but information about the specific surgical technique used was not available upon referral.

Histology revealed a poorly demarcated spindle cell proliferation expanding the eyelid dermis with cells organized in bundles and admixed with oedematous

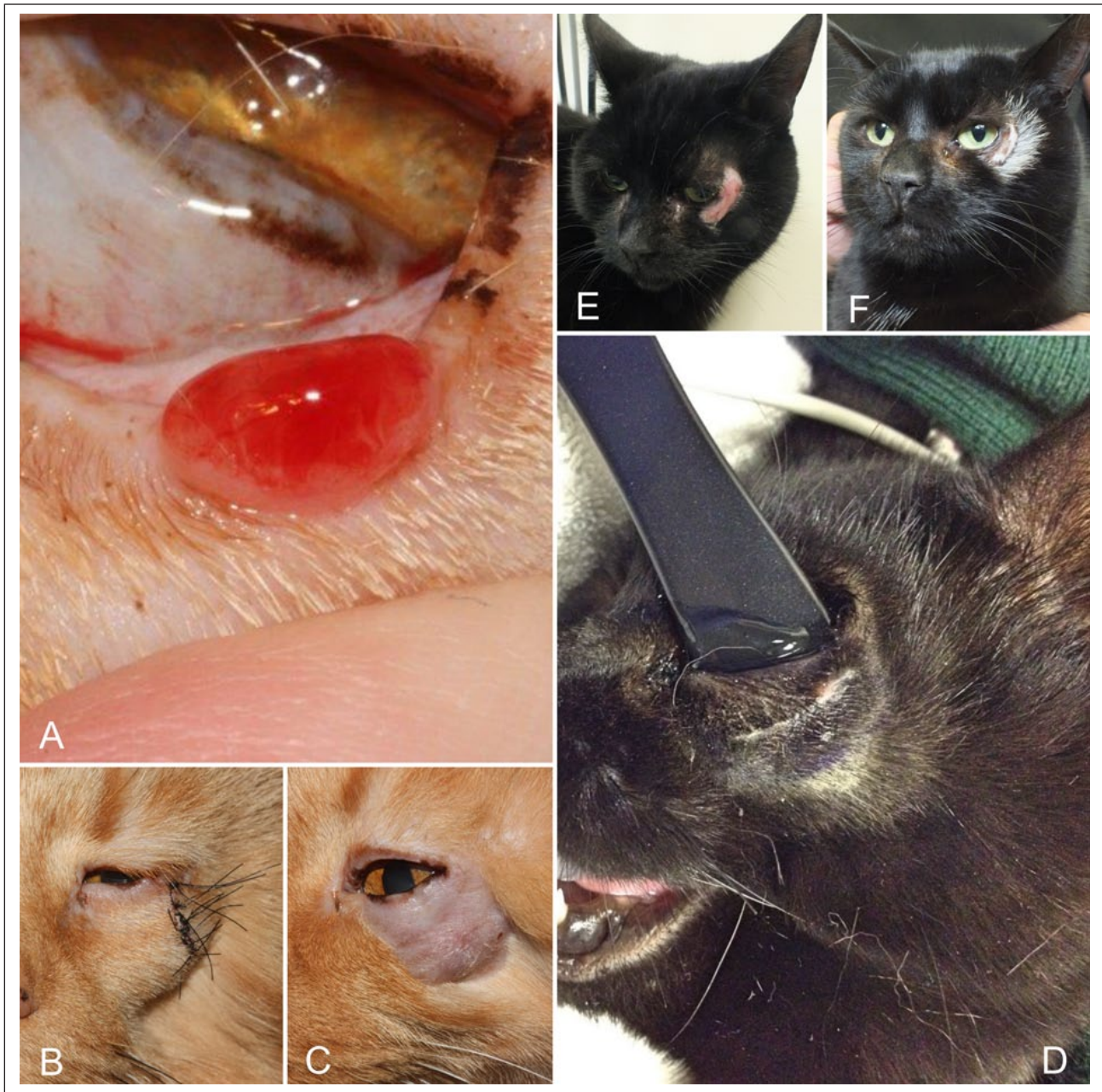


Figure 1 Case 1: malignant peripheral nerve sheath tumour of the left lower eyelid (a) before and (b) after surgery. (c) Alopecia 5 weeks after the end of strontium plesiotherapy. Case 2: (d) plastic Jaeger lid plate in place to protect the eye during strontium plesiotherapy. (e) Cutaneous acute moist dermatitis 2 weeks after treatment, (f) followed by leukotrichia after a few months.

fibrillar matrix. Anisocytosis and anisokaryosis were moderate and mitoses were 2 in 10 HPFs. Small areas of necrosis were noted scattered throughout the tumour. The tumour was initially diagnosed as incompletely excised soft tissue sarcoma and subsequent immunostaining for S-100 allowed a final diagnosis of malignant PNST.

Revision surgery using a more aggressive approach or adjuvant plesiotherapy was discussed with the

owners, and they elected for the more conservative approach.

Strontium plesiotherapy was started 33 days after surgery. The treatment was delivered on a Monday–Wednesday–Friday basis for five fractions to a total surface dose of 200 Gy. Each fraction consisted of six contiguous application fields providing a clinical margin of approximately 1 cm around the scar. During the treatment the globe was protected using a plastic Jaeger lid

plate (Figure 1d). At the end of the radiation course there was mild erythema in the irradiated area. Meloxicam was prescribed for 3 weeks as an anti-inflammatory and analgesic. A few days after the end of the radiotherapy moist desquamation developed (Veterinary Radiation Therapy Oncology Group grade 2 skin acute toxicity;⁹ Figure 1e).

At re-examination 3 weeks later, the dermatitis was completely resolved, but the irradiated area was completely alopecic. At re-examination after 6 months, the irradiated area presented diffuse leukotrichia (Figure 1f), but there was no evidence of chronic ocular toxicity.

At the time of writing, 645 days after the end of the radiotherapy, the cat is still well and there is no evidence of tumour recurrence.

Discussion

Marginal resection followed by strontium plesiotherapy was able to provide good local control in the two cases presented herein without performing aggressive surgery such as enucleation or exenteration. This was an extremely promising result considering that 11/14 periocular PNSTs reported in the literature recurred after surgical excision.²⁻⁴

The dose of radiation prescribed in these two cases was 200 Gy to the surface or 50 Gy at a depth of 2 mm,¹⁴ which is comparable with the total dose commonly prescribed as adjuvant treatment in cats with injection-site sarcoma treated with external beam radiotherapy.¹⁵

Compared with external beam radiotherapy, strontium plesiotherapy can be used to treat small areas (2–8 cm²) because only a limited number of contiguous fields can be successfully applied to an area. Both tumours presented in this report underwent surgery when their size was still small (4 and 7 mm, respectively), leaving a surgical scar smaller than 1 cm. A margin of approximately 1 cm around the scar was applied to define the treatment area, but this decision was driven by the practicality of the treatment, as specific data are not available in the literature. When planning external beam radiotherapy as adjuvant treatment of injection-site sarcomas a margin of 3 cm around the surgical scar is commonly applied because of their tendency to infiltrate along the fascial planes.^{15,16} In the two cases presented in this series, we applied a narrower margin because non-injection site sarcomas are less biologically aggressive and infiltrative than injection-site sarcomas.¹⁷

Acute and long-term side effects associated with the treatment were limited to the skin and very mild. At re-examination at 6 months there was no evidence of ocular toxicity such as cataract. In this sense we think that protecting the eye with a plastic Jaeger lid plate provided further attenuation to the already weak deep radiation dose.

Conclusions

Excisional globe-sparing surgery of small periocular PNSTs followed by adjuvant plesiotherapy may be a valid alternative to enucleation or exenteration. A larger number of cases would be necessary to further support the positive outcome seen in these cases.

Funding The authors received no financial support for the research, authorship, and/or publication of this article.

Conflict of interest The authors declared no potential conflicts of interest with respect to the research, authorship, and/or publication of this article.

References

- 1 Koestner A, Bilzer T, Fatzer R, et al. Tumors of the peripheral nervous system. In: *Histologic Classification of tumors of the nervous system of domestic animals*. Washington, DC: Armed Forces Institute of Pathology and American Registry of Pathology, 1999, pp 37–38.
- 2 Schulman FY, Johnson TO, Facemire PR, et al. **Feline peripheral nerve sheath tumors: histologic, immunohistochemical, and clinicopathologic correlation (59 tumors in 53 cats)**. *Vet Pathol* 2009; 46: 1166–1180.
- 3 Newkirk KM and Rohrbach BW. **A retrospective study of eyelid tumors from 43 cats**. *Vet Pathol* 2009; 46: 916–927.
- 4 Hoffman A, Blocker T, Dubielzig R, et al. **Feline periocular peripheral nerve sheath tumor: a case series**. *Vet Ophthalmol* 2005; 8: 153–158.
- 5 Liptak JM and Forrest LJ. **Soft tissue sarcomas**. In: *Withrow and MacEwen's small animal clinical oncology*. 5th ed. St Louis, MO: Elsevier Saunders, 2013, pp 356–380.
- 6 Ching SV, Gillette SM, Powers BE, et al. **Radiation-induced ocular injury in the dog: a histological study**. *Int J Radiat Oncol Biol Phys* 1990; 19: 321–328.
- 7 Jamieson VE, Davidson MG, Nasisse MP, et al. **Ocular complications following cobalt 60 radiotherapy of neoplasms in the canine head region**. *J Am Anim Hosp Assoc* 1992; 27: 51–55.
- 8 Roberts SM, Lavach JD, Severin GA, et al. **Ophthalmic complications following megavoltage irradiation of the nasal and paranasal cavities in dogs**. *J Am Vet Med Assoc* 1987; 190: 43–47.
- 9 LaDue TA, Klein MK and Veterinary Radiation Therapy Oncology Group. **Toxicity criteria of the veterinary radiation therapy oncology group**. *Vet Radiol Ultrasound* 2001; 42: 475–476.
- 10 Montgomery KW, van der Woerd A, Aquino SM, et al. **Periocular cutaneous mast cell tumors in cats: evaluation of surgical excision (33 cases)**. *Vet Ophthalmol* 2010; 13: 26–30.
- 11 Turrel JM, Farrelly J, Page RL, et al. **Evaluation of strontium 90 irradiation in treatment of cutaneous mast cell tumors in cats: 35 cases (1992–2002)**. *J Am Vet Med Assoc* 2006; 228: 898–901.
- 12 Donaldson D, Sansom J and Adams V. **Canine limbal melanoma: 30 cases (1992–2004). Part 2. Treatment with lamellar resection and adjunctive strontium-90 β plesiotherapy – efficacy and morbidity**. *Vet Ophthalmol* 2006; 9: 179–185.

- 13 Donaldson D, Sansom J, Murphy S, et al. **Multiple limbal haemangiosarcomas in a border collie dog: management by lamellar keratectomy/sclerectomy and strontium – 90 beta plesiotherapy.** *J Small Anim Pract* 2006; 47: 545–549.
- 14 Goodfellow MR, Hayes AM, Murphy S, et al. **A retrospective study of 90Strontium plesiotherapy for feline squamous cell carcinoma of the nasal planum.** *J Feline Med Surg* 2006; 8: 169–176.
- 15 Eckstein C, Guscetti F, Roos M, et al. **A retrospective analysis of radiation therapy for the treatment of feline vaccine-associated sarcoma.** *Vet Comp Oncol* 2009; 7: 54–68.
- 16 Hahn KA, Endicott MM, King GK, et al. **Evaluation of radiotherapy alone or in combination with doxorubicin chemotherapy for the treatment of cats with incompletely excised soft tissue sarcomas: 71 cases (1989–1999).** *J Am Vet Med Assoc* 2007; 231: 742–745.
- 17 Morrison WB, Robin MS and The Vaccine-Associated Feline Sarcoma Task Force. **Vaccine-associated feline sarcomas.** *J Am Vet Med Assoc* 2001; 218: 697–702.