



Tuberculosis joint infections in four domestic cats

Authors: Lalor, Stephanie M, Clarke, Stephen, Pink, Jonathan, Parry, Andrew, Scurrall, Emma, et al.

Source: Journal of Feline Medicine and Surgery Open Reports, 3(2)

Published By: SAGE Publishing

URL: <https://doi.org/10.1177/2055116917719401>

BioOne Complete (complete.BioOne.org) is a full-text database of 200 subscribed and open-access titles in the biological, ecological, and environmental sciences published by nonprofit societies, associations, museums, institutions, and presses.

Your use of this PDF, the BioOne Complete website, and all posted and associated content indicates your acceptance of BioOne's Terms of Use, available at www.bioone.org/terms-of-use.

Usage of BioOne Complete content is strictly limited to personal, educational, and non - commercial use. Commercial inquiries or rights and permissions requests should be directed to the individual publisher as copyright holder.

BioOne sees sustainable scholarly publishing as an inherently collaborative enterprise connecting authors, nonprofit publishers, academic institutions, research libraries, and research funders in the common goal of maximizing access to critical research.



Tuberculosis joint infections in four domestic cats

Stephanie M Lalor¹, Stephen Clarke¹, Jonathan Pink¹, Andrew Parry¹, Emma Scurrell², Noel Fitzpatrick³, Fraje Watson³, Conor O'Halloran⁴ and Danielle Gunn-Moore⁴

Journal of Feline Medicine and Surgery Open Reports
1–8

© The Author(s) 2017

Reprints and permissions:

sagepub.co.uk/journalsPermissions.nav

DOI: 10.1177/2055116917719401

journals.sagepub.com/home/jfmsopenreports

This paper was handled and processed by the European Editorial Office (ISFM) for publication in *JFMS Open Reports*



Abstract

Case series summary This paper describes the clinical presentation, diagnostic imaging findings and outcome in four cats with confirmed joint-associated tuberculosis. The cats were 2–6 years of age, and immune competent. Three cases had tuberculosis affecting only one joint, whereas one case had at least three joints affected. Two cases were caused by *Mycobacterium bovis*, and the other two were caused by *Mycobacterium microti*. Radiological findings included osteolysis, periosteal reaction and associated soft tissue swelling. Two cases were euthanased and two cases responded well to amputation and follow-on antibiotic therapy.

Relevance and novel information To our knowledge, this is the first publication of a series of cats with joint-associated tuberculosis. Although tuberculosis is not common, a high degree of suspicion is needed to avoid delayed diagnosis. This case series highlights the importance of considering mycobacterial disease as a differential for joint disease in cats.

Accepted: 13 June 2017

Introduction

Tuberculosis is a global health concern in humans and other animals.¹ A study of cats in the UK found that 34% of their mycobacterial infections are caused by members of the *Mycobacterium tuberculosis* complex (tuberculosis complex), with 19% of cases being caused by *Mycobacterium microti* (the vole bacillus) and 15% by *Mycobacterium bovis*.² While feline tuberculosis is not common, it occurs more frequently than most veterinary surgeons realise – a 2013 study found that histopathological changes consistent with mycobacterial infection were present in ~1% of all feline tissue samples submitted for histopathological examination in the UK.³

Unfortunately, diagnosis of tuberculosis can be difficult. It is based on the demonstration of typical acid-fast bacilli (eg, using Ziehl–Neelsen [ZN] staining) on cytology or histopathology,⁴ specialist culture^{2,5} or PCR testing of tissue biopsies,^{4,6} and/or the interferon gamma release assay (IGRA) run on whole blood.^{7,8} However, each of these methods has caveats: (1) ZN staining is often falsely negative in paucibacillary infections.⁹ (2) Specialist

culture can take many weeks to get a positive growth (especially when *M microti* is involved),⁵ such that ~50% of feline tissue samples with histopathology indicative of mycobacterial infections fail to grow any mycobacteria.² (3) PCR testing should ideally be performed on fresh rather than fixed tissue as fixation increases the risk of false negatives (PCR can give false negatives in paucibacillary infections as the assays are not particularly

¹Willows Veterinary Centre and Referral Service, Highlands Road, Solihull, UK

²CytoPath, Ledbury, UK

³Fitzpatrick Referrals, Eashing, Godalming, UK

⁴Royal (Dick) School of Veterinary Studies and the Roslin Institute, Easter Bush Veterinary Centre, Roslin, UK

Corresponding author:

Stephanie M Lalor BVetMed (Hons), MANZCVS, DipECVIM-CA, MRCVS, European and RCVS Specialist in Internal Medicine, RCVS Specialist in Feline Medicine, Willows Veterinary Centre, Highlands Road, Solihull B90 4NH, UK
Email: stephanie.lalor@willows.uk.net



Creative Commons Non Commercial CC BY-NC: This article is distributed under the terms of the Creative Commons

Attribution-NonCommercial 4.0 License (<http://www.creativecommons.org/licenses/by-nc/4.0/>) which permits non-commercial use, reproduction and distribution of the work without further permission provided the original work is attributed as specified on the SAGE and Open Access pages (<https://us.sagepub.com/en-us/nam/open-access-at-sage>).

sensitive [at least currently]);¹⁰ some laboratories do not differentiate between members of the tuberculosis complex; and the tests can be expensive.¹⁰ (4) While the IGRA has been found to have good predictive capacity for both *M bovis* and *M microti* infections in laboratory conditions,⁸ field data have yet to be published.

In the UK, three-quarters of cats with mycobacterial disease present with single or multiple cutaneous lesions, and half have local lymph node involvement, typically affecting the mandibular nodes.² Cutaneous lesions typically affect the 'fight and bite sites', such as the head and legs, and are believed to result most commonly from being bitten when playing with infected prey (both *M microti* and *M bovis* can infect small rodents).^{2,9,11,12} Pulmonary or systemic signs are seen less frequently, but can be seen, most typically, in chronic infections.^{2,9}

Mycobacterial joint involvement is thought to be uncommon. In a retrospective study describing radiographic findings in cats with mycobacterial infections, 11 cats had radiographs available for assessment of musculoskeletal changes;¹³ skeletal abnormalities were found in the distal antebrachium (three), pes (two), and maxilla, scapula, ventral spine, manus, femur and tarsus (one each). The most common changes were osteolytic lesions (73%; 8/11 cases), which were typically permeative osteolytic lesions (64%; 7/11). Osteoproliferative changes were seen in three cats and were characterised as smooth, irregular or 'sunburst-like' (one each).¹³ Soft tissue swelling was present in five cats, which was adjacent to the bony abnormality in four of them.¹³

A retrospective study describing the CT findings in feline mycobacterial infection found focal osteolytic lesions in 35% (7/20) of cats.¹⁴ These lesions affected the nasal bridge in three cats and the limbs in the remaining four, and were predominantly characterised by regions of cortical lysis (71%; 5/7) or erosive lesions at joint surfaces (29%; 2/7). An associated pathological long-bone fracture was present in one case. In all but one of these cases, osteoproliferative changes, either periosteal reactions or periarticular osteophytosis, were noted in the same location as the osteolytic change. The osteoproliferation was mild in three cases and severe in three cases. However, the degree of proliferative change did not necessarily correlate with the degree of lytic change in each case.¹⁴

There is a single case report of osteomyelitis of the coxofemoral joint due to an unidentified species of *Mycobacterium* in a feline renal transplant recipient.¹⁵ A femoral head and neck ostectomy was performed on the affected limb; however, the cat's clinical condition declined despite treatment and the owner elected for euthanasia.¹⁵

To our knowledge there are no case reports of spontaneous mycobacterial infection involving the joint in cats.

The aim of this paper was to describe the clinical presentation, findings and outcome in four cats with mycobacterial infection (specifically tuberculosis) of the joint(s).

Case series description

Case 1

A 6-year-old male neutered Maine Coon cat from Hereford, UK, was referred to the Willows Veterinary Centre (WVC) for further investigation of a 5 week history of a swollen left hock, which had been associated with variable lameness. There was no history of trauma or a bite wound. The cat was not known to be a hunter. The cat was fully vaccinated against feline calicivirus (FCV), feline herpesvirus (FHV)-1 and feline panleukopenia virus (FPV).

On presentation the cat was 1/10 lame on the left hindlimb. There was a marked periarticular swelling of the left hock. The cat was in good body condition and general physical examination was unremarkable. The referring veterinarian's radiographs of the left hock revealed a periarticular soft tissue swelling, with some distal tibial periosteal reaction. Neoplasia or inflammatory joint disease were considered as differential diagnoses at this stage. Cytology of the lesion revealed neutrophilic inflammation. The cat had a chronic history of FHV-1 infection (which resulted in intermittent mild episodes of conjunctivitis) and inflammatory bowel disease (IBD). Aspiration pneumonia associated with previous liquid paraffin administration had been diagnosed in 2012 when the IBD had been investigated. The IBD was being managed with Royal Canin Sensitivity Control diet.

Physical examination revealed mild left hindlimb lameness and mild associated muscle atrophy. The left hock was markedly thickened and discomfort was noted on manipulation. The left popliteal lymph node was moderately enlarged. No other obvious orthopaedic abnormalities were apparent. General physical examination revealed dull lung sounds ventrally on auscultation, but was otherwise unremarkable, and all vital parameters were within normal limits. Routine haematology, serum biochemistry and feline immunodeficiency virus (FIV) and feline leukaemia virus (FeLV) testing (in-house SNAP test) were unremarkable. Possible differential diagnoses included inflammatory arthropathy (infection or immune mediated), soft tissue neoplasia or, less likely, a synovial cyst.

CT was performed under general anaesthesia and revealed mild enlargement of the left medial iliac lymph node and moderate enlargement of the left popliteal lymph node. There was a moderate irregular periosteal reaction circumferentially affecting the left distal tibia, fibula, talus and calcaneus. Associated with this was a marked heterogeneously contrast-enhancing soft tissue-attenuating mass that was visible circumferentially

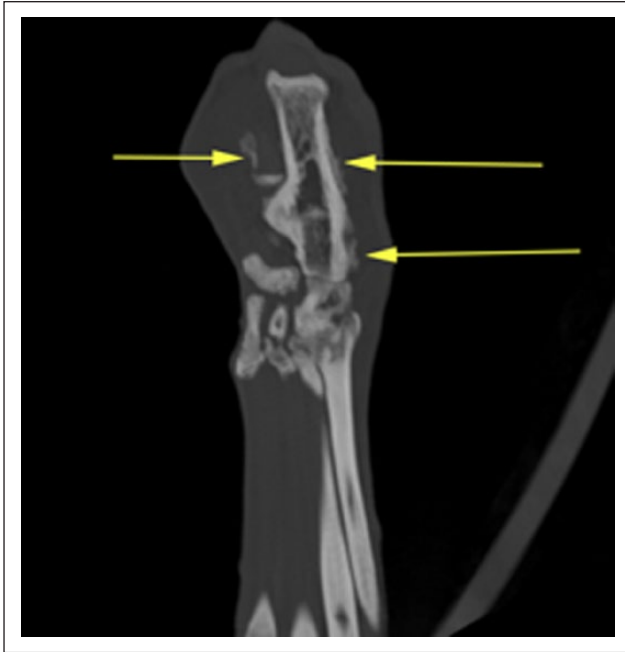

Figure 1 Dorsal multiplanar reformatted image of the left tarsus of case 1. A moderate periosteal reaction as described is identified (arrows)

around the talocrural joint (Figure 1). The lesion appeared intimately associated with the synovium. There were multiple pockets of non-contrast-enhancing soft tissue-attenuating material within the mass. CT of the chest revealed consolidation of the ventral aspect of all lung lobes. The consolidation occupied up to approximately two-thirds of each lung lobe. Air bronchograms were identified at the dorsal aspects of the regions of consolidation. The tip of the left cranial lung lobe was characterised by emphysematous changes. There was scant heterogeneous mineralisation of the lateral aspects of the right caudal lobe. There was also a mild tracheobronchial lymphadenopathy. These changes may have been consistent with previous severe liquid paraffin aspiration; however, concurrent disease (mycobacterial pneumonia) was also possible.

Fine-needle aspirates were collected from the left popliteal lymph node and biopsies were collected from the left hock mass. Samples were submitted for cytology, histopathology and aerobic/anaerobic culture. The cat was discharged with tramadol (25 mg PO q12h) and a 7 day course of potentiated amoxicillin (100 mg PO q12h) while awaiting the results.

Cytology of the popliteal lymph node was typical of a reactive lymphadenopathy. Rare clumps of macrophages were identified and these were thought to reflect either sinus histiocytosis (eg, chronic antigenic stimulation) or focal granulomatous inflammation. Histopathology of the left hock periarticular tissue revealed pyogranulomatous

inflammation. Based on this, there was a high index of suspicion for mycobacterial infection, but repeated ZN stains were negative for acid-fast bacilli, even on prolonged microscopy. Aerobic and anaerobic bacterial culture of the synovium was negative.

Blood IGRA results were consistent with infection by a member of the tuberculosis complex, and *M bovis* was considered to be most likely (PPDA+, PPDB++, ESAT6/CFP10+/-).⁸

The cat's owner elected for euthanasia as they felt the cat's quality of life was poor and they did not want leg amputation or medical management. A post-mortem examination was performed at the Animal Plant Health Agency (APHA), Weybridge, UK, and *M bovis* was confirmed on culture.

Case 2

A 6-year-old female neutered British Shorthair cat was referred to the WVC for further investigation of chronic left forelimb lameness. The cat had lived in Worcestershire, UK, for the past 18 months; however, it was a rescue cat so its previous history was unknown. The cat was fully vaccinated against FCV, FHV-1 and FPV, and was a known hunter. It had evidence of carpal discomfort and radiographs performed by the referring veterinary surgeon revealed an irregular area between the radius and ulna. The cat was treated for presumptive osteomyelitis with a 10 week course of cephalexin (175 mg PO q12h) and clindamycin (75 mg PO q12h), and intermittent meloxicam (0.25 mg PO q24h, as needed); there had been no improvement.

On presentation the cat was 4/10 lame on the left forelimb and had moderate-to-marked left forelimb muscle atrophy. There was a soft tissue swelling/effusion over the dorsal aspect of the antebrachium extending to the medial aspect. Discomfort was noted on extension of the left carpus and on firm palpation of the ulna styloid. General physical examination was unremarkable and all vital parameters were within normal limits. The cat was in good body condition at 5 kg. Routine haematology, serum biochemistry and FIV and FeLV testing (in-house SNAP test) were unremarkable.

CT of the carpi and thorax was performed under general anaesthesia. This revealed marked soft tissue swelling of the left carpus centred at the level of the antebrachiocarpal joint, particularly medially, and periosteal new bone formation on the dorsal aspect of the distal row of carpal bones, the intermedioradial carpal bones, the distal radius and the caudal aspect of the ulnar (the periosteal reaction here was smooth) (Figures 2 and 3). Post-contrast, there was marked enhancement of the soft tissues surrounding the carpus and, in particular, the soft tissue swelling dorsal to the carpus, which contained multiple ring-enhancing foci. There were well-defined and extensive areas of reduced attenuation

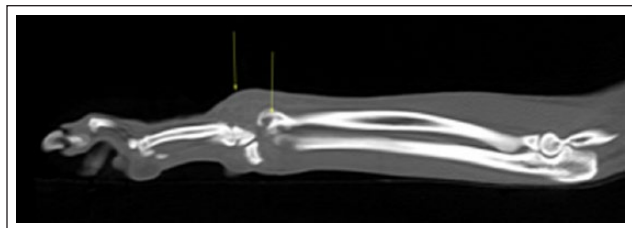

Figure 2 Sagittal multiplanar reformatted image of the left carpus of case 2. There is marked soft tissue swelling associated with the antebrachio-carpal joint. Osteolysis of the distal radius is also identified (arrows)

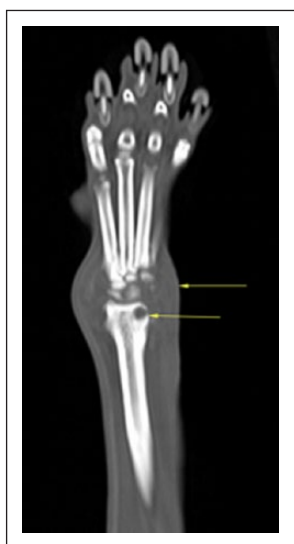

Figure 3 Dorsal multiplanar reformatted image of the left carpus of case 2. There is marked soft tissue swelling identified associated with the antebrachio-carpal joint (arrow). Smooth periosteal new bone is identified along the medial aspect of the distal radius. Marked osteolysis is identified, and particularly obvious in the lateral aspect of the distal radial epiphysis (arrow)

within the distolateral aspect of the radius and the inter-mediatoradial carpal bone consistent with osteolysis. Differential diagnoses included osteomyelitis/erosive arthritis (fungal, bacterial), atypical immune-mediated arthritis, mycobacterial infection and soft tissue neoplasia (eg, synovial cell sarcoma). CT of the right carpus was unremarkable. Enlargement of the left axillary lymph node was noted on CT, which was thought to be consistent with reactive or metastatic change. CT of the thorax revealed no abnormalities.

A fine-needle aspirate of the axillary lymph node was performed and this revealed a non-specific reactive lymphadenopathy. A fine-needle aspirate of the periarticular tissue of the distal antebrachium (carpus) was performed and biopsies were taken for histopathology. Both cytology and histopathology samples indicated pyogranulomatous inflammation. Based on this, there was a high

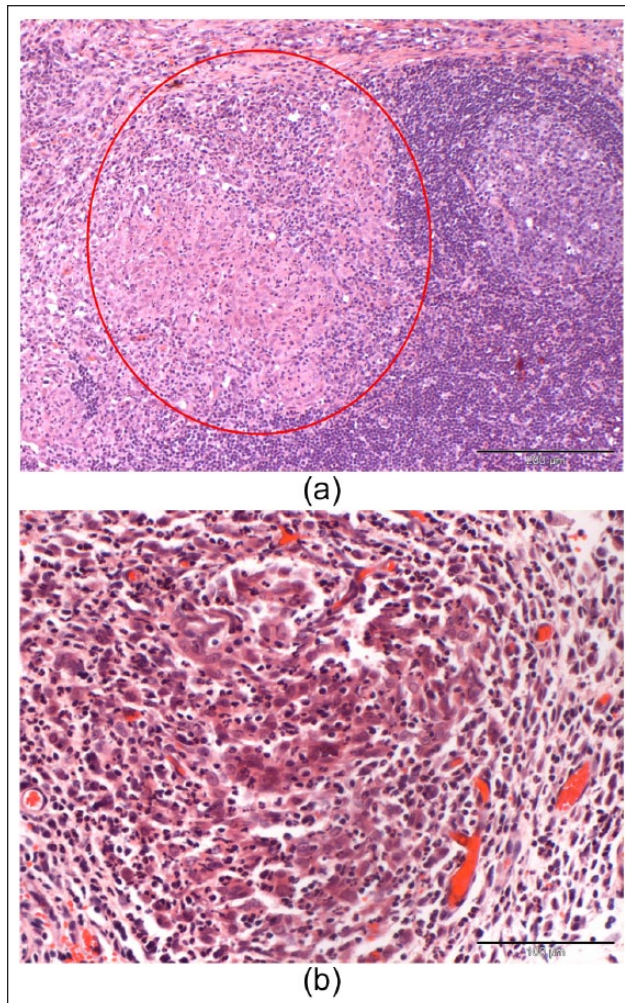


Figure 4 (a) The lymph node cortex is focally infiltrated by pyogranulomatous to granulomatous inflammation (red circle). (b) A lymphoid follicle lies to the right-hand side of the image (haematoxylin and eosin, $\times 200$)

index of suspicion for mycobacterial infection; ZN staining was performed on the histopathology and cytology samples, and was negative for acid-fast bacilli.

Amputation was advised to achieve local control of disease and to confirm the diagnosis. An excisional biopsy of the axillary lymph node was performed at this time. Histopathological examination of the axillary lymph node revealed multifocal pyogranulomatous-to-granulomatous lymphadenitis with reactive secondary lymphoid follicular hyperplasia (Figure 4a,b). ZN staining was performed on sections of the lymph node and was negative for acid-fast bacilli.

IGRA results were consistent with infection by a member of the tuberculosis complex, and *M bovis* was considered to be most likely (PPDA+/-, PPDB+, ESAT6/CFP10+/-). Tissue from the amputated carpus was sent to the APHA for culture, which confirmed *M bovis*.

The cat was started on pradofloxacin (25 mg PO q24h), rifampicin (50 mg PO q24h) and azithromycin (50 mg PO q24h), with all three drugs being given for 2 months, after which rifampicin and azithromycin were continued at the same doses for a further 4 months. A telephone update 10 months after presentation revealed that the cat was doing well and the owner had no concerns.

Case 3

A 5-year-old female neutered Persian crossbred cat from Edinburgh (that had moved there from Cornwall a year previously) was referred to the Royal (Dick) School of Veterinary Studies for further investigation of a 6 month history of suspected food allergic dermatitis (periorbital alopecia, pruritus and bilateral otitis externa), and more recent expiratory noise, with wheezes on respiration, and the cat was also lethargic. It had been treated with Nestlé Purina HA diet, prednisolone (1 mg PO q24h for 10 days) and Epiotic ear cleaner (administered fortnightly) and its dermatological signs had improved. The cat was fully vaccinated against FCV, FHV-1 and FPV, had outdoor access and was a known hunter.

On presentation the cat was quiet, alert and responsive, and had a crouched stance. It was in a poor body condition with a body weight of 3.4 kg and body condition score of 3/9. It was mildly pyrexic (39.1°C), tachycardic (208 beats per min) and tachypnoeic (48 respirations per min). It had moderate bilateral submandibular lymphadenopathy. On auscultation of the lung fields there was an expiratory wheeze. On dermatological examination it had symmetrical periaural alopecia, and mild seborrhoea, crusting of the nose and dry foot pads. The left prescapular lymph node was moderately enlarged. It had swollen and thickened elbows, hocks and carpi with a decreased range of motion, and was unable to extend its hips. Neurological examination was unremarkable. Its owners reported no lameness.

Investigations were performed. Haematology revealed a mild neutrophilia ($16 \times 10^9/l$, reference interval [RI] $2.5\text{--}12.8 \times 10^9/l$) and serum biochemistry revealed mild hypoalbuminaemia (25.8 g/l, RI 28–39 g/l). Clotting times were unremarkable. FIV and FeLV SNAP tests on serum were negative. PCR on whole blood was negative for *Bartonella*, *Anaplasma* and *Borellia* species; Antinuclear Antibodies (ANA) testing was also negative. *Toxoplasma gondii* serology was negative with a serum IgG of <50 and IgM of <20. Urine analysis was unremarkable, with a urine specific gravity of 1.050 and no proteinuria.

CT revealed mild bilateral otitis externa, cranial and thoracic lymphadenopathy, and diffuse pulmonary disease. There was a generalised increase in lung attenuation due to numerous tiny soft tissue-attenuating nodules (ie, a miliary nodular pattern). An irregular periosteal reaction with mild osteolytic changes was present on the articular surfaces of the elbows and tarsi.

This was associated with a soft tissue swelling around these joints. Arthrocentesis of the left elbow and left tarsus produced cytology consistent with a non-infective polyarthritides (up to 95% non-degenerative neutrophils). Bronchoscopy revealed an irregular mucosa in the ramifications of both principal bronchi and mucus in the right bronchus. Bronchoalveolar lavage was performed and the fluid was consistent with moderate chronic active inflammation as it contained 35% macrophages, 55% neutrophils and 10% small lymphocytes. Routine bacterial and fungal culture and *Mycoplasma* species PCR were negative. Skin biopsies were taken from the left ear, and histopathology revealed a diffuse moderate follicular atrophy with mild focal chronic folliculitis; periodic acid-Schiff staining was negative for fungal elements. ZN staining was not performed on any samples as mycobacterial infection was (unfortunately) not suspected.

The cat subsequently developed diarrhoea, alopecia and marked lameness. Full faecal analysis, including culture and parasitology, plus *Giardia* species and *Tritrichomonas foetus* PCR was unremarkable. Serum cobalamin, folate and feline trypsin-like immunoreactivity were unremarkable, but feline pancreatic lipase immunoreactivity was slightly raised at 4.9 µg/l (RI 0.1–3.5). The cat was treated with prednisolone (2.5 mg PO q12h) and chlorambucil (2 mg PO every 7 days) for the suspected immune-mediated polyarthritides and allergic skin disease; famotidine (5 mg PO q24h) and Fortiflora (one sachet PO q12h) for the diarrhoea; a 2 week course of doxycycline (40 mg PO q24h) for the pneumonia; and a transdermal fentanyl patch (25 µg/h patch) was applied to give analgesia for the painful joints.

The cat was re-assessed 2 weeks and then 4 weeks later and had clinically improved, with no evidence of lameness and good regrowth of hair. Over the following 6 months the cat retained good coat quality; however, it appeared to have mild intermittent abdominal pain, potentially associated with a slightly enlarged ileocaecocolic lymph node, it lost progressively more weight (reducing to 2.43 kg, with a body condition score of 2/9) and had a persistent neutrophilia (ranging from $15\text{--}28 \times 10^9/l$; RI 2.5–12.8). Its owner declined further investigations and ultimately elected for euthanasia owing to a poor quality of life.

Post-mortem examination revealed severe diffuse pyogranulomatous and necrotising arthritis and osteomyelitis of the right carpus, left carpus and right hock; ZN staining revealed numerous acid-fast bacilli within the cytoplasm of many macrophages. Moderate-to-marked multifocal pyogranulomatous nephritis was noted, with tubular necrosis, regeneration, atrophy and fibrosis; small numbers of acid-fast bacilli were present in the kidneys on acid-fast staining. Moderate-to-marked granulomatous interstitial pneumonia was noted, as was focally severe lymphoplasmocytic and histiocytic pancreatitis. PCR of a joint biopsy was

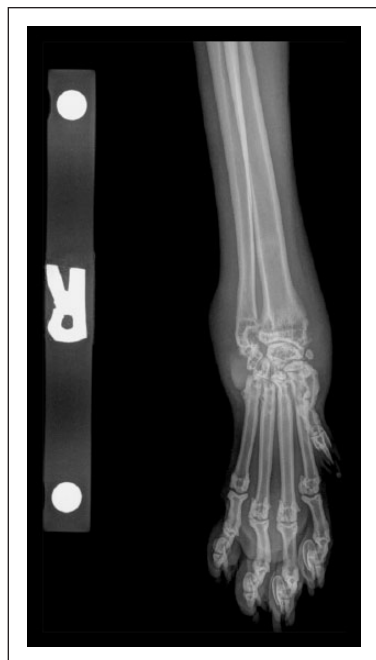

Figure 5 Dorsopalmar radiograph of the right antebrachiocarpal joint of case 4. There is marked soft tissue swelling associated with the antebrachiocarpal joint, as well as a smooth periosteal reaction along the distal radial metaphysis on the medial and lateral aspects. Focal regions of osteolysis are present within the medial aspect of the distal radial epiphysis

positive for *M tuberculosis* complex, confirmed to be *M microti* on GenoType MTBC assay (Leeds Teaching Hospitals Trust, Department of Microbiology).

Case 4

A 35-month-old male neutered Maine Coon cat from Kent, UK, presented to Fitzpatrick Referrals for assessment of right carpal swelling, which had been ongoing since November 2015. The cat was a known hunter. Lameness of the right thoracic limb had occurred suddenly. Initially pradofloxacin (18 mg PO q24h) and meloxicam (0.3 mg PO q24h) produced improvement, but the lameness subsequently continued. Arthrocentesis at the time suggested an infectious cause with a neutrophilic inflammatory response. Doxycycline (60 mg PO q24h) was given, in conjunction with meloxicam (0.3 mg PO q24h), but this failed to produce improvement. Radiography was inconclusive.

Physical examination on the day of presentation revealed pain and a firm soft tissue swelling associated with the right carpus, but was otherwise unremarkable. The cat was in good body condition with a weight of 6 kg. Radiography and CT examination of the right carpus was performed. Radiographs revealed a marked soft tissue swelling associated with the antebrachiocarpal joint,

a smooth periosteal reaction along the distal radial metaphysis and focal regions of osteolysis within the medial aspect of the distal radial epiphysis (Figure 5). CT revealed osteolysis affecting all of the carpal bones, the proximal metacarpal bones and the distal radius and ulna. A periarticular soft tissue mass was identified, with moderate-to-marked heterogeneous contrast enhancement. A sample of joint fluid was sent for analysis and an incisional biopsy was taken. CT examination of the thorax and abdomen was unremarkable. Routine haematology and serum biochemistry were unremarkable.

Amputation of the right forelimb was advised and then performed. Histopathology of the right carpus revealed a multifocal-to-coalescing, pyogranulomatous panniculitis and synovitis. Rare ZN-positive, intracytoplasmic bacterial rods were identified in the macrophages. Culture of the tissue was negative, but PCR confirmed the presence of *M tuberculosis* complex DNA and this was subsequently identified as *M microti*. IGRA testing revealed that *M microti* was most likely (PPDA+, PPDB++, ESAT6/CFP10-).

The cat was treated with rifampicin (90 mg PO q24h), azithromycin (90 mg PO q24h) and pradofloxacin (30 mg PO q24h) for 3 months. The cat recovered uneventfully. At follow-up 11 months later, the owners reported no concerns and the cat was back to its normal self with no signs of reoccurrence.

Discussion

This case series describes spontaneous joint-associated tuberculosis in four cats. The cats were 2–6 years of age and immune competent. This is in agreement with previous findings that the median age of cats with *M bovis* infection is 3 years of age and *M microti* is 8 years, and that cats with mycobacterial infections are no more likely to be infected with FeLV or FIV than the general cat population.² Cases 1, 2 and 4 had tuberculosis affecting only one joint, while case 3 had at least three joints affected. Three of the cats were known to hunt rodents, and rodents are known to be able to carry *M bovis* and *M microti*,^{11,12} so rodent bites are a likely source of infection in these cases. Mycobacterial disease in cats most often involves the face, extremities of the limbs, tail base or perineum, that is, 'fight and bite sites',⁹ and the distal limb joints (hock and carpi) were involved in all three cases. However, while cases 1, 2 and 4 probably resulted from an infected rodent bite close to or into the affected joint, case 3, which had at least three joints affected and had concurrent illness, is more likely to have developed polyarthrititis secondary to haematogenous spread of *M microti* from an unrecognised original bite or infected wound. It is interesting that in humans, weightbearing joints were the most commonly involved sites for tuberculous arthritis,¹⁶ and all four of these feline cases affected appendicular joints.

Tuberculous arthritis has been very infrequently reported in cats, a situation similar to that seen in people where tuberculosis of the musculoskeletal system accounts for only 1–3% of all cases of tuberculosis.¹⁷ Interestingly, the spine is the most common site of skeletal tuberculosis in people,¹⁷ while this appears very rare in cats – in nearly 25 years of investigating feline mycobacterial infections the senior author (DGM) has only seen one case of spinal mycobacteriosis, and that was caused by *Mycobacterium avium* (DGM, unpublished observations). This may be because spinal involvement in people is most commonly the result of haematogenous spread of *M tuberculosis* from a pulmonary focus,¹⁸ and primary pulmonary tuberculosis accounts for >90% of human tuberculosis,¹⁹ while cats rarely develop primary pulmonary tuberculosis, much more typically having cutaneous disease, and only developing pulmonary development late on in disease following haematogenous dissemination.^{9,11} In people, articular tuberculosis is even less common than spinal tuberculosis, and it is usually associated with bone disease and concomitant immunosuppression.²⁰

This case series clearly highlights the difficulties in making a diagnosis of articular tuberculosis, especially when there is only joint involvement, as collection of biopsy material is not trivial. Joint aspirates appear to be of little use in this diagnosis, so the collection of joint biopsies was necessary. Mycobacterial disease has relatively specific features on histopathology, showing (pyo) granulomatous inflammation, often with epithelioid macrophages, and lesions may have foci of necrosis. Acid-fast stains can be applied to cytology and histopathology samples to screen for acid-fast bacilli in the first instance; however, as many of these infections are paucibacillary,⁹ a negative result does not rule out mycobacterial infection, as seen in cases 1 and 2. When the cytology and/or histopathology indicates an index of suspicion for mycobacterial infection, it is necessary to send fresh (frozen) tissue for specialist mycobacterial culture,^{2,5} to have mycobacterial PCR tests run (ideally on fresh tissue, although they can still be performed on fixed tissue) and/or send blood for an IGRA, to try and confirm the diagnosis.⁸ This is what happened with cases 1 and 2, where histopathology was highly suggestive of mycobacterial infection, but no acid-fast bacteria were seen, so an IGRA was run. In both cases the IGRA was found to be consistent with *M bovis* infection, leading to euthanasia and limb amputation, respectively, and tissue could be sent for confirmation by specialist culture. Culture or PCR results can give a definitive result, but to run these tests it is important to divide the original biopsy when it is first removed from the cat, fix part of it and send it for histopathology, and freeze the rest of the biopsy (ideally in 2–3 separate pots) so that it is later available for culture and/or PCR testing.

Unfortunately, in case 3, mycobacterial infection was not considered as a potential differential diagnosis and the cat was given systemic immunosuppressive drugs in an attempt to treat the presumed immune-mediated disease(s). None of the cytology or histopathology samples revealed changes suggestive of mycobacterial infection. However, retrospectively, the pulmonary radiographic changes were suggestive, and if the IGRA had been available at that time, it would have been run, potentially leading to a very different outcome.

Cases 1 and 2 were both caused by *M bovis*, while cases 3 and 4 were caused by *M microti*. In the UK these infections tend to be geographically confined, such that *M bovis* is found in cats from the south-west of England and Wales (coincident with the areas where *M bovis* infects cattle and badgers), whereas *M microti* is found in cats south and east of London, in the north of England and in Scotland.² Cases 1 and 2 came from Hereford and Worcestershire, respectively, and case 3 originated from Cornwall, an area where *M bovis* infection is commonly seen, but then moved to Edinburgh a year before it developed clinical signs, which is a region where *M microti* is found. Case 4 came from Kent. Hence, all four cases were infected with the type of tuberculosis expected from their location in the UK.²

The prognosis for people with skeletal tuberculosis (caused by *M tuberculosis*) is reasonable; in a study of 26 patients, 69% had a favourable outcome (defined as no relapses or functional disability).¹⁵ In that study, 12 patients underwent surgery (mainly to obtain samples for culture), and medical management, which was given to 21/26, included isoniazid, rifampin, pyrazinamide and/or ethambutol. In human medicine, the diagnosis of skeletal tuberculosis is often delayed several months or years due to lack of recognition of the disease.¹⁷

In the present study, 2/4 cats (cases 2 and 4) underwent appropriate treatment, and they both did well. Amputation of the affected limb was performed in each case as the senior author (DGM) has previously had poor responses to therapy where significant tuberculous arthritis and/or osteomyelitis has been involved (DGM, unpublished observations). This was followed by medical therapy consisting of rifampicin (10–15 mg/kg PO q24h), azithromycin (5–15 mg/kg PO q24h) and pradofloxacin (3.5–5 mg/kg PO q24h) for 2 months in case 2 and 3 months in case 4, followed by rifampicin (5–15 mg/kg PO q24h) and pradofloxacin (3.5–5 mg/kg PO q24h) for 4 months in case 2. While these are the recommended doses for these drugs, following observations gathered over the past 25 years, the senior author (DGM) now recommends that all three of these drugs be given for 4–6 months, depending on the extent of disease, and always for at least 2 months following complete resolution of the lesions.²¹

Conclusions

Feline skeletal tuberculosis is uncommon; however, it can occur in cats, even without concurrent disease and/or apparent immunosuppression. A high degree of suspicion is needed in both human and veterinary medicine to avoid delayed diagnosis. This case series highlights the importance of considering mycobacterial disease as a differential for joint disease in cats.

Acknowledgements Thanks go to the referring veterinary surgeons, and all staff at Willows Veterinary Centre, the Royal (Dick) School of Veterinary Studies Hospital for Small Animals, and Fitzpatrick Referrals, who helped with these cases.

Conflict of interest The authors declared no potential conflicts of interest with respect to the research, authorship, and/or publication of this article.

Funding The authors received no financial support for the research, authorship, and/or publication of this article.

References

- Lobue PA, Enarson DA and Thoen CO. **Tuberculosis in humans and animals: an overview.** *Int J Tuberc Lung Dis* 2010; 14: 1075–1078.
- Gunn-Moore DA, McFarland SE, Brewer JI, et al. **Mycobacterial disease in cats in Great Britain: I. Culture results, geographical distribution and clinical presentation of 339 cases.** *J Feline Med Surg* 2011; 13: 934–944.
- Gunn-Moore DA, Gaunt C and Shaw DJ. **Incidence of mycobacterial infections in cats in Great Britain: estimate from feline tissue samples submitted to diagnostic laboratories.** *Transbound Emerg Dis* 2013; 60: 338–344.
- Malik R, Hunt GB, Goldsmid SE, et al. **Diagnosis and treatment of pyogranulomatous panniculitis due to *Mycobacterium smegmatis* in cats.** *J Small Anim Pract* 1994; 35: 524–530.
- Smith NH, Crawshaw T, Parry J, et al. ***Mycobacterium microti*, more diverse than previously thought.** *J Clin Microbiol* 2009; 47: 2551–2559.
- Reppas G, Fyfe J, Foster S, et al. **Detection and identification of mycobacteria in fixed stained smears and formalin-fixed paraffin-embedded tissues using PCR.** *J Small Anim Pract* 2013; 54: 638–646.
- Rhodes SG, Gruffydd-Jones TJ, Gunn-Moore DA, et al. **Adaptation of IFN-gamma ELISA and ELISPOT for the diagnosis of feline tuberculosis.** *Vet Immunol and Immunopathol* 2008; 124: 379–384.
- Rhodes SG, Gruffydd-Jones T, Gunn-Moore D, et al. **Interferon-gamma test for feline tuberculosis.** *Vet Rec* 2008; 162: 453–455.
- Gunn-Moore D. **Mycobacterial infections in cats and dogs.** In: Ettinger SJ (ed). *Textbook of veterinary internal medicine.* 7th ed. Philadelphia, PA: Saunders, 2010; 1: 871–875.
- Gunn-Moore D and Lalor S. **Tuberculosis in companion animal species.** In: *Many hosts of mycobacteria: tuberculosis, leprosy, and other mycobacterial disease of man and animals.* Wallingford: CABI International, 2015, pp 235–258.
- Burthe S, Bennett M, Kipar A, et al. **Tuberculosis (*Mycobacterium microti*) in wild field vole populations.** *Parasitology* 2008; 135: 309–317.
- Delahay RJ, Smith GC, Barlow AM, et al. **Bovine tuberculosis infection in wild mammals in the South-West region of England: a survey of prevalence and a semi-quantitative assessment of the relative risks to cattle.** *Vet J* 2007; 173: 287–301.
- Bennett AD, Lalor S, Schwarz T, et al. **Radiographic findings in cats with mycobacterial infections.** *J Feline Med Surg* 2011; 13: 718–724.
- Major A, Holmes A, Warren-Smith C, et al. **Computed tomographic findings in cats with mycobacterial infection.** *J Feline Med Surg* 2015; 18: 510–517.
- Lo AJ, Goldschmidt MH and Aronson LR. **Osteomyelitis of the coxofemoral joint due to *Mycobacterium* species in a feline renal transplant recipient.** *J Feline Med Surg* 2012; 14: 919–923.
- Ruiz G, Garcia Rodriguez J, Guerri ML, et al. **Osteoarticular tuberculosis in a general hospital during the last decade.** *Clin Microbiol Infect* 2003; 9: 919–923.
- Tuli SM. **Tuberculosis of the skeletal system (bones, joints, spine and bursal sheaths).** New Delhi: Jaypee Brothers Medical Publishers, 2010, pp 69–110.
- McLain RF and Isada C. **Spinal tuberculosis deserves a place on the radar screen.** *Cleve Clin J Med* 2004; 71: 537–539.
- Lawn SD and Zumla AI. **Tuberculosis.** *Lancet* 2011; 378: 57–72.
- Houshian S, Poulsen S and Riegels-Nielsen P. **Bone and joint tuberculosis in Denmark: increase due to immigration.** *Acta Orthop Scand* 2000; 71: 312–315.
- O'Brien C, O'Halloran C and Gunn-Moore DA. **Companion animal mycobacterial diseases.** In: Sykes J (ed). *Greene's infectious diseases of the dog and cat.* 5th ed.