



Mammary fibroadenomatous hyperplasia in a male cat

Authors: Mayayo, Saray Lorna, Bo, Stefano, and Pisu, Maria Carmela

Source: Journal of Feline Medicine and Surgery Open Reports, 4(1)

Published By: SAGE Publishing

URL: <https://doi.org/10.1177/2055116918760155>

BioOne Complete (complete.BioOne.org) is a full-text database of 200 subscribed and open-access titles in the biological, ecological, and environmental sciences published by nonprofit societies, associations, museums, institutions, and presses.

Your use of this PDF, the BioOne Complete website, and all posted and associated content indicates your acceptance of BioOne's Terms of Use, available at www.bioone.org/terms-of-use.

Usage of BioOne Complete content is strictly limited to personal, educational, and non - commercial use. Commercial inquiries or rights and permissions requests should be directed to the individual publisher as copyright holder.

BioOne sees sustainable scholarly publishing as an inherently collaborative enterprise connecting authors, nonprofit publishers, academic institutions, research libraries, and research funders in the common goal of maximizing access to critical research.



Mammary fibroadenomatous hyperplasia in a male cat

Saray Lorna Mayayo¹, Stefano Bo² and Maria Carmela Pisu³

Journal of Feline Medicine and Surgery Open Reports
1–5

© The Author(s) 2018

Reprints and permissions:

sagepub.co.uk/journalsPermissions.nav

DOI: 10.1177/2055116918760155

journals.sagepub.com/home/jfmsopenreports

This paper was handled and processed

by the European Editorial Office (ISFM)

for publication in *JFMS Open Reports*



Abstract

Case summary Mammary fibroadenomatous hyperplasia (MFH) is a benign pathology characterised by extensive proliferation of the ductal epithelium and mammary stroma. It typically occurs in young female cats, and seems to result from hypersensitivity to progesterone. A 2-year-old entire male European Shorthair cat presented to the veterinary clinic with enlargement of several mammary glands, which had developed within the previous 10 days. There was no prior administration of progestin in the cat's medical history. Diagnostic tests were performed to assess the basal progesterone concentration and the concentration after stimulation with gonadotropin-releasing hormone, which ruled out the presence of functional ovarian tissue. Histological examination of the testes excluded hormone-secreting testicular tumours. Histological examination of the mammary gland confirmed the diagnosis of MFH. Treatment was started with aglepristone, a selective competitor for progesterone receptors, administered subcutaneously at 15 mg/kg at days 1, 2, 8 and 15. A reduction in the size of the mammary glands was evident 6 days after the first administration, with complete remission observed after 4 weeks.

Relevance and novel information To the best of our knowledge, this is the first full report of MFH in a male cat. Although the origin of the progestins responsible for MFH in this case could not be confirmed, in the light of the diagnostic tests performed and the results obtained, accidental contact with hormone-like substances seems to be the only plausible explanation for the cat's clinical signs. Inhibitor therapy was successful.

Accepted: 12 January 2018

Introduction

Approximately 80% of feline mammary masses are neoplastic. The remaining 20% are benign and are predominantly mammary fibroadenomatous hyperplasia (MFH).¹ MFH, also known as fibroepithelial hyperplasia or feline mammary hyperplasia, was first described by Allen in 1973.²

This benign pathology is characterised by the uniform and rapid proliferation of the ductal epithelium and mammary stroma. The aetiology is suspected to be an exaggerated response to natural progesterone or synthetic progestins.^{1,3} Burstyn suggested that this condition may be the result of hypersensitivity to physiological concentrations of endogenous progesterone or from the administration of exogenous progestin.⁴ However, this disease has occasionally been described in sterilised males and females without any clinical signs of hormone ingestion.^{5,6}

MFH can affect all or most of the mammary glands, without involving the adjacent lymph nodes, and is not usually accompanied by milk secretion.³ The hyperplasia

can be severe, leading to tissue necrosis, ulceration and infection.⁷ A majority of the affected cats are young queens of reproductive age, queens during their first oestrous cycle, queens during pregnancy or pseudopregnancy, or males or females after treatment with progesterone or synthetic gestagens (megestrol acetate, medroxyprogesterone acetate or proligestone).^{8–10}

Another cause has been reported to be an increase in the secretion of growth hormone (GH), produced as a side effect of the presence of natural or synthetic progesterone. In cats, the target organ of GH is the breast tissue, and this

¹Cumiana, Turin, Italy

²Veterinary Association of Bo-Ferro Outpatient Clinic, Turin, Italy

³VRC-Centro di Referenza Veterinario, Turin, Italy

Corresponding author:

Stefano Bo DVM, PhD, Internal Medicine, Veterinary Association of Bo-Ferro Outpatient Clinic, 10123 Turin, Italy
stefano@veterinariassociati.it



Creative Commons Non Commercial CC BY-NC: This article is distributed under the terms of the Creative Commons

Attribution-NonCommercial 4.0 License (<http://www.creativecommons.org/licenses/by-nc/4.0/>) which permits non-commercial use, reproduction and distribution of the work without further permission provided the original work is attributed as specified on the SAGE and Open Access pages (<https://us.sagepub.com/en-us/nam/open-access-at-sage>).

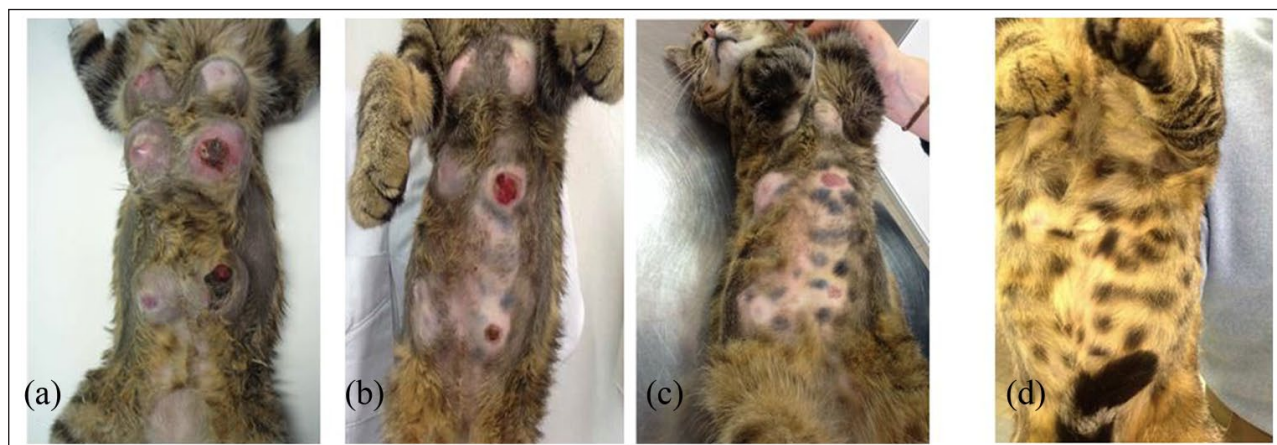

Figure 1 (a) Clinical manifestation of mammary fibroadenomatous hyperplasia. (b) Cat after 1 week of treatment with aglepristone. (c) Complete remission of clinical signs after 4 weeks of treatment. (d) Follow-up after 3 months

hormone induces the proliferation of epithelial and stromal glandular ducts until hyperplasia.^{11–13}

Case description

The patient was a 2-year-old entire male European short-hair cat. At the time of presentation its body condition score was 4/9 and it weighed 4 kg. The owner reported an increase in volume of the mammary glands from about 10 days prior, with a progressive increase in size until the day of the visit. It was an indoor cat and had no contact with other animals. The cat had been fed a commercial dry diet, was regularly vaccinated and was negative for retroviral diseases, including feline leukaemia virus and feline immunodeficiency virus. In the patient's medical history, no indication of any therapies was reported (steroids, antifungals, chemotherapy or progestins). There were no other clinical signs or behavioural changes.

All vital signs evaluated during the clinical examination were normal. Upon palpation, the axillary and abdominal breasts were warm and painful, and there was evidence of necrosis and ulceration of two of the mammary glands (Figure 1a). The testes were symmetrical and appeared normal, and moved freely into the scrotum. No additional checks had been performed during previous veterinary visits.

Diagnosis and interpretation of results

Owing to the extent and severity of injuries, mammary neoplasia was also considered when making the differential diagnosis, as reported in the classification of the main mammary masses in cats.¹⁴

The acute mastitis could be a secondary pathology of a form of mammary hyperplasia, considering that these diseases can occur simultaneously.⁴ Although rare in feline species, adrenal and hormone-secreting testicular tumours must be considered in the differential diagnosis,^{15,16} as well as the possible presence of functional ovarian tissue in the abdominal cavity.¹

General screening of the patient involved a complete haematological and biochemical profile, including electrolyte levels and complete urinalysis. Afterward, a series of specific tests aimed to evaluate the levels of reproductive hormones (progesterone, 17β -oestradiol and testosterone) were performed. A chest x-ray study was suggested to the owner, but this was postponed owing to the results of the other tests.

A stimulation test with human chorionic gonadotropin (hCG) was then performed, with the aim being to increase the endogenous secretion of testosterone by the Leydig cells, so to exclude possible presence of ovariectomized, or to induce ovulation if ovarian tissue was present, resulting in the production of 17β -oestradiol and progesterone.³ Several protocols using hCG have been published, with variable efficacy.^{3,16–21} For the stimulation test, 500 IU hCG (Gonasi HP, 1000 IU/ml; IBSA Farmaceutici Italia) was administered intramuscularly, and 2 h later a blood sample was taken to measure the levels of testosterone and 17β -oestradiol. After 2 weeks, a second blood test was performed to measure the progesterone levels, as recommended by the manufacturer (off-label).

At the same time, an abdominal ultrasound was performed to evaluate the testicular structure and the adrenal glands, and to identify the presence of any functional ovarian tissue. A breast ultrasound was then performed to complete the study. The ultrasound system used was the MyLab 30 Gold VET (Esaote) with a CA123 VET micro-convex probe (8–3 MHz; Esaote).

The haematological and biochemical profiles and results of the urinalysis were all unremarkable. The testosterone levels before stimulation were 0.65 ng/ml (reference interval [RI] 0.05–4 ng/ml) and 7.41 ng/ml (RI 4–9 ng/ml) after stimulation. These results are consistent with normal hormone secretion by the testes and normal function of the Leydig cells.^{1,3,22}

The 17β -oestradiol level before stimulation was 24.2 pmol/l (RI <73.4 pmol/l) and 26 pmol/l (RI <220.3

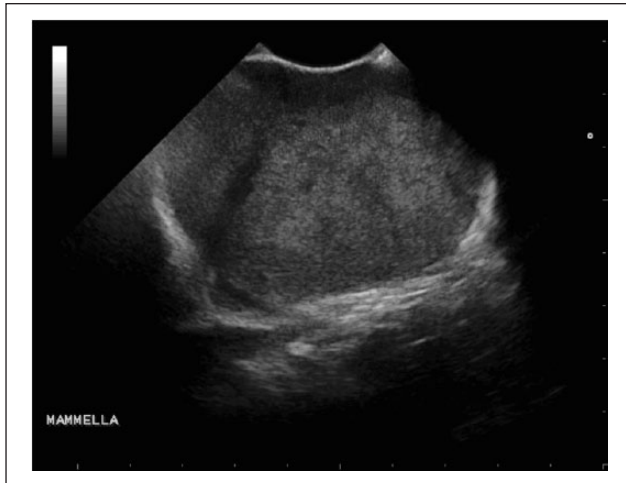

Figure 2 Ultrasonography of mammary glands with a homogeneous glandular structure and regular margins, characteristic of benign lesions

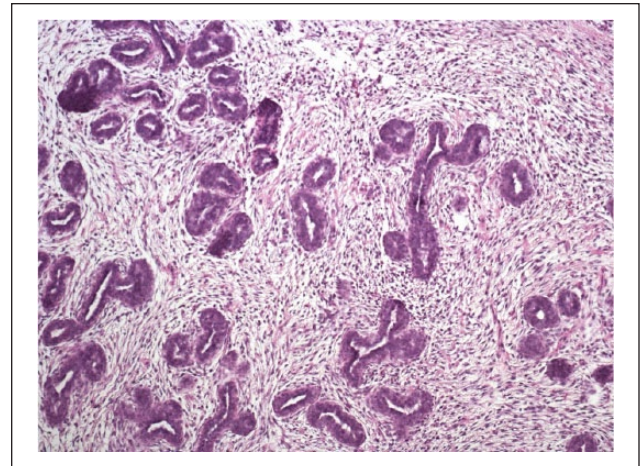


Figure 3 Histological image of fibroadenomatous hyperplasia. Stained with haematoxylin and eosin, $\times 10$ magnification

pmol/l) after stimulation. However, the lack of response to the stimulation test cannot exclude the presence of ovarian tissue or the presence of a hormone-secreting testicular tumour,^{1,16,23,24} especially in cats, where it is not proven that this is a useful test.

The progesterone concentrations were 1.5 and 1.7 nmol/l before and after stimulation, respectively. This result allowed us to exclude the presence of ovarian tissue, as the basal RI for a male cat is 1.3–5.4 nmol/l,²⁵ and the reported level post-stimulation is >6.3 nmol/l when ovarian tissue is present.^{1,16,18,20,24,26,27}

The ultrasound revealed testicular parenchyma of normal size and structure, and there was no presence of functional ovarian tissue in the abdominal cavity. The adrenal glands were normal in appearance and size (0.34 cm both right and left), which excluded a possible neoplasm that prevented them from producing sex hormones.^{16,28}

Ultrasonography of the mammary glands showed a homogeneous glandular structure with regular margins, characteristic of benign lesions,^{29–31} as shown in Figure 2.

A coagulation profile test was then performed as a preventive measure and normal results were obtained; a biopsy of the mammary gland was taken with the cat under anaesthesia. The cat was premedicated with 10 mg/ml methadone (Semfortan solution for injection; Eurovet Animal Health) at a dose of 0.2 mg/kg administered intramuscularly, and anaesthesia was induced with 10 mg/ml propofol (Proposure solution for injection; Merial Italia) at a dose 5 mg/kg administered intravenously. After tracheal intubation, anaesthesia was maintained with isoflurane (IsoFlo inhalational anaesthesia; Ecuphar Italia).

A breast incisional wedge biopsy was performed, and a sample measuring $0.5 \times 0.5 \times 0.5$ cm was taken. Two simple interrupted stitches with a non-absorbable thread (Daclon USP 3/0 EP2) were used to close the wound. The

sample was placed in 10% buffered formalin and stained with haematoxylin and eosin. The histological examination showed widespread fibroadenomatous hyperplasia with proliferation of the ductal epithelium of the mammary glands, which confirmed the diagnosis of MFH (Figure 3 and Appendix 1 in the supplementary material).¹⁰

In addition to the biopsy, an orchietomy was performed using a routine ‘open’ technique, with two incisions directly on the scrotum.³² Histological examination of the testes was normal, excluding the presence of a hormone-secreting testicular tumour.^{3,15,23}

The presence of functional ovarian tissue was excluded after the abdominal sonography, combined with the negative response to progesterone stimulation with hCG.^{1,16} Excluding all possible differential diagnoses, our remaining hypothesis was accidental contact with hormone-like substances; however, no voluntary administration was reported by the owner or found in the cat’s medical history.

An insulin-like growth factor-1 test was performed, and the value was 100 nmol/l (RI >6.5 and <131 nmol/l; acromegaly >131 nmol/l), thereby excluding the pathology.

Treatment for MFH began with subcutaneous administration of a progesterone receptor inhibitor, aglepristone (Alizin; Virbac), at 15 mg/kg on days 1, 2, 8 and 15. The affinity of this molecule for the progesterone receptor displaces natural or synthetic progesterones without activating the receptors.^{6,29,33–35}

A broad-spectrum antibiotic was also prescribed to treat incidental infections related to the presence of necrosis and ulceration in two of the breasts. For this, amoxicillin-clavulanic acid (Synulox, palatable tablets; Pfizer Italy) was orally administered at a dose of 20 mg/kg twice daily (morning and evening) for 2 weeks. A painkiller, tramadol HCl (Ultram Altadol, soluble tablets;

Formevet), was also orally administered at a dose of 2 mg/kg twice daily (morning and evening) for 1 week.

The cat was monitored weekly for 5 weeks to assess healing of the ulcerated breasts, control the clinical course and confirm the regression of hyperplasia. Six days after beginning the therapy, a reduction in size and change in the consistency of all mammary glands was already evident (Figure 1b).

Complete remission of clinical signs was observed approximately 4 weeks later, similar to that reported in the literature (Figure 1c).¹ Another follow-up was performed 3 months later, with no visible signs of disease recurrence observed (Figure 1d).

Discussion

The clinical signs, patient signalment and history, together with the biopsy of the mammary gland, confirmed the diagnosis of MFH in the cat. It was unlikely that the lesions were a malignant neoplasm form owing to the young age and sex of the patient. Although male cats are significantly less affected by this disease, the observed clinical manifestation appeared characteristic.⁷

Only a few published articles have reported the physiological levels of progesterone and 17 β -oestradiol in male cats, probably because the disease is not common in these patients.²⁵ Occasionally, MFH will resolve spontaneously,⁵ as reported in the case of a castrated 1.5-year-old male treated with megestrol acetate.⁹ This disease is only occasionally described in males or females with no history of progestogen administration.^{1,5,6} To the best of our knowledge, this is the first full report of MFH in a male cat.

The role of progesterone in the development of MFH seems obvious owing to the full remission of hyperplasia observed in the cat after 4 weeks of beginning aglepristone therapy. Aglepristone is a synthetic steroid that binds to progesterone (P4) receptors, thereby inhibiting the biological effects of progesterone.^{6,34}

Conclusions

Understanding the pathogenesis requires further investigation, especially in the rare cases where the role of these compounds is not easily correlated with the appearance of clinical signs.⁶ In the clinical case described here, no voluntary administration of progesterone was reported by the owner, and there was no detectable increase in progesterone detected in the cat's serum. It is important to note that some exogenous progestin may be evaluated with the tests usually performed to measure progesterone, which may result in a false increase in this hormone, whereas other compounds (medroxyprogesterone acetate, megestrol, proligestone, norethindrone) are not measured by normal tests.^{6,36,37} Therefore, in these cases the cat might have come in contact with one of these compounds but the serum progesterone assay would still be in the normal range. Progestin is a component of

contraceptive pills, and is also found in some creams and lotions and in different types of plants found in the environment. The time interval between ingestion of progestins and the appearance of MFH can be longer than 6 months,³⁶ but if the accidental contact was with human progestogens, the effect may be different and may have a shorter response time. In the light of the diagnostic tests performed and the results obtained, accidental contact with hormone-like substances seems to be the only plausible explanation for the cat's clinical signs.

Conflict of interest The authors declared no potential conflicts of interest with respect to the research, authorship, and/or publication of this article.

Funding This research received no specific grant from any funding agency in the public, commercial, or not-for-profit sectors

Supplementary material Appendix 1: histology report for the mammary gland.

References

- 1 Little S. **Feline reproduction: problems and clinical challenges.** *J Feline Med Surg* 2011; 13: 508–515.
- 2 Allen HL. **Feline mammary hypertrophy.** *Vet Pathol* 1973; 10: 501–508.
- 3 Marti JA and Fernandez S. **Approccio clinico alle patologie mammarie.** In: *ev Edizioni Veterinarie (ed). Riproduzione e neonatologia del cane e del gatto.* 2nd ed. Turin: Pisu MC, 2013, pp 161–162.
- 4 Burstyn U. **Management of mastitis and abscessation of mammary glands secondary to fibroadenomatous hyperplasia in a primiparient cat.** *J Am Vet Med Assoc* 2010; 236: 326–329.
- 5 Mandel M. **Spontaneous remission of feline benign mammary hypertrophy.** *Vet Med Small Anim Clin* 1975; 70: 846–847.
- 6 Görlinger S, Kooistra HS, van den Broek A, et al. **Treatment of fibroadenomatous hyperplasia in cats with aglepristone.** *J Vet Intern Med* 2002; 16: 710–713.
- 7 Little S. **Management of reproduction and related disorders.** In: Harvey A and Tasker S (eds). *BSAVA manual of feline practice.* Gloucester: British Small Animal Veterinary Association, 2013, pp 399–412.
- 8 Hayden DW, Barnes DM and Johnson KH. **Morphologic changes in the mammary gland of megestrol acetate-treated and untreated cats: a retrospective study.** *Vet Pathol* 1989; 26: 104–113.
- 9 MacDougall LD. **Mammary fibroadenomatous hyperplasia in a young cat attributed to treatment with megestrol acetate.** *Can Vet J* 2003; 44: 227–229.
- 10 Loretta AP, Ilha MR, Ordás J, et al. **Clinical, pathological and immunohistochemical study of feline mammary fibroepithelial hyperplasia following a single injection of depot medroxyprogesterone acetate.** *J Feline Med Surg* 2005; 7: 43–52.
- 11 Mol JA, Henzen-Logmans SC, Hageman P, et al. **Expression of the gene encoding growth hormone in the human mammary gland.** *J Clin Endocrinol Metab* 1995; 80: 3094–3096.

- 12 Mol JA, Lantinga-van Leeuwen I, et al. **Progesterin induced mammary growth hormone (GH) production.** *Adv Exp Med Biol* 2000; 480: 71–76.
- 13 Mol JA, Van Garderen E, Rutteman GR, et al. **New insights in the molecular mechanism of progesterin-induced proliferation of mammary epithelium: induction of the local biosynthesis of growth hormone (GH) in the mammary glands of dogs, cats and humans.** *J Steroid Biochem Mol Biol* 1996; 57: 67–71.
- 14 Buracco P. **Mammary glands.** In: Landley-Hobbs SJ, Demetriou JL and Ladlow JF (eds). *Feline soft tissue and general surgery.* Elsevier, 2014, pp 220–221.
- 15 Miller MA, Hartnett SE and Ramos-Vara JA. **Interstitial cell tumor and sertoli cell tumor in the testis of a cat.** *Vet Pathol* 2007; 44: 394–397.
- 16 Meler EN, Scott-Moncrieff JC, Peter AT, et al. **Cyclic estrous-like behavior in a spayed cat associated with excessive sex-hormone production by an adrenocortical carcinoma.** *J Feline Med Surg* 2011; 13: 473–478.
- 17 Memon MA, Ganjam VK, Pavletic MM, et al. **Use of human chorionic gonadotropin stimulation test to detect a retained testis in a cat.** *J Am Vet Med Assoc* 1992; 201: 1602.
- 18 England GC. **Confirmation of ovarian remnant syndrome in the queen using hCG administration.** *Vet Rec* 1997; 141: 309–310.
- 19 Kutzler MA. **Estrus induction and synchronization in canids and felids.** *Theriogenology* 2007; 68: 354–374.
- 20 Axné E, Gustavsson T and Ström Holst B. **Estradiol measurement after GnRH-stimulation as a method to diagnose the presence of ovaries in the female domestic cat.** *Theriogenology* 2008; 70: 186–191.
- 21 Goericke-Pesch S. **Reproduction control in cats. New developments in non-surgical methods.** *J Feline Med Surg* 2010; 12: 539–546.
- 22 Schlafer DH, Valentine B, Fahnestock G, et al. **A case of SRY-positive 38,XY true hermaphroditism (XY sex reversal) in a cat.** *Vet Pathol* 2011; 48: 817–822.
- 23 Benazzi C, Sarli G and Brunetti B. **Sertoli cell tumour in a cat.** *J Vet Med A Physiol Pathol Clin Med* 2004; 51: 124–126.
- 24 Ball R, Birchard S, May R, et al. **Ovarian remnant syndrome in dogs and cats: 21 cases (2000–2007).** *J Am Vet Med Assoc* 2010; 236: 548–553.
- 25 Hofmann-Lehmann R, Holznagel E and Lutz H. **Female cats have lower rates of apoptosis in peripheral blood lymphocytes than male cats: correlation with estradiol-17beta, but not with progesterone blood levels.** *Vet Immunol Immunopathol* 1998; 65: 151–160.
- 26 Wallace MS. **The ovarian remnant syndrome in the bitch and queen.** *Vet Clinics North Am Small Anim Pract* 1991; 21: 501–507.
- 27 Giménez F, Hecht S, Craig LE, et al. **Early detection, aggressive therapy: optimizing the management of feline mammary masses.** *J Feline Med Surg* 2010; 12: 214–224.
- 28 Zatelli A, D'Ippolito P, Fiore I, et al. **Ultrasonographic evaluation of the size of the adrenal glands of 24 diseased cats without endocrinopathies.** *Vet Rec* 2007; 160: 658–660.
- 29 Wehrend A, Hospes R and Gruber AD. **Treatment of feline mammary fibroadenomatous hyperplasia with a progesterone-antagonist.** *Vet Rec* 2001; 148: 346–347.
- 30 Sontas BH, Turna O, Ucmak M, et al. **What is your diagnosis? Feline mammary fibroepithelial hyperplasia.** *J Small Anim Pract* 2008; 49: 545–547.
- 31 Payan-Carreira R and Martins-Bessa AC. **Ultrasonographic assessment of the feline mammary gland.** *J Feline Med Surg* 2008; 10: 466–471.
- 32 Friend EJ. **Male genital tract.** In: Landley-Hobbs SJ, Demetriou JL and Ladlow JF (eds). *Feline soft tissue and general surgery.* Elsevier, 2014, pp 452–453.
- 33 Meisl D, Hubler M and Arnold S. **Treatment of fibroepithelial hyperplasia (FEH) of the mammary gland in the cat with the progesterone antagonist Aglepristone (Alizine).** *Schweiz Arch Tierheilkd* 2003; 145: 130–136.
- 34 Nak D, Nak Y, Seyrek-Intas K, et al. **Treatment of feline mammary fibroadenomatous hyperplasia with aglepristone.** *Aust Vet Pract* 2004; 34: 161–162.
- 35 Jurka P and Max A. **Treatment of fibroadenomatosis in 14 cats with aglepristone - changes in blood parameters and follow-up.** *Vet Rec* 2009; 165: 657–660.
- 36 Hayden DW, Johnston SD, Kiang DT, et al. **Feline mammary hypertrophy/fibroadenoma complex: clinical and hormonal aspects.** *Am J Vet Res* 1981; 42: 1699–1703.
- 37 Leidinger E, Hooijberg E, Sick K, et al. **Fibroepithelial hyperplasia in an entire male cat: cytologic and histopathological features.** *Tierarztl Prax Ausg K Kleintiere Heimtiere* 2011; 39: 198–202.