



## **Novel treatment using topical malachite green for nasal phaeohyphomycosis caused by a new *Cladophialophora* species in a cat**

Authors: Brooks, Ian J, Walton, Stuart A, Shmalberg, Justin, and Harris, Autumn

Source: Journal of Feline Medicine and Surgery Open Reports, 4(1)

Published By: SAGE Publishing

URL: <https://doi.org/10.1177/2055116918771767>

---

BioOne Complete ([complete.BioOne.org](https://complete.BioOne.org)) is a full-text database of 200 subscribed and open-access titles in the biological, ecological, and environmental sciences published by nonprofit societies, associations, museums, institutions, and presses.

Your use of this PDF, the BioOne Complete website, and all posted and associated content indicates your acceptance of BioOne's Terms of Use, available at [www.bioone.org/terms-of-use](https://www.bioone.org/terms-of-use).

Usage of BioOne Complete content is strictly limited to personal, educational, and non - commercial use. Commercial inquiries or rights and permissions requests should be directed to the individual publisher as copyright holder.

---

BioOne sees sustainable scholarly publishing as an inherently collaborative enterprise connecting authors, nonprofit publishers, academic institutions, research libraries, and research funders in the common goal of maximizing access to critical research.



# Novel treatment using topical malachite green for nasal phaeohyphomycosis caused by a new *Cladophialophora* species in a cat

*Journal of Feline Medicine and Surgery Open Reports*  
1–7

© The Author(s) 2018

Reprints and permissions:

sagepub.co.uk/journalsPermissions.nav

DOI: 10.1177/2055116918771767

journals.sagepub.com/home/jfmsopenreports

This paper was handled and processed by the American Editorial Office (AAFP) for publication in *JFMS Open Reports*



Ian J Brooks<sup>1</sup>, Stuart A Walton<sup>1</sup>, Justin Shmalberg<sup>2</sup> and Autumn Harris<sup>3</sup>

## Abstract

**Case summary** A 1.5-year-old castrated male domestic shorthair cat presented with a 2 month history of progressive nasal swelling and hypoxemia. Minimal improvement prior to referral was achieved with a course of antibiotics and glucocorticoids. Cytology of an ulcerative lesion on the dorsal aspect of the nose was consistent with a diagnosis of phaeohyphomycosis. The cat achieved static disease for 6 weeks following initiation of itraconazole but developed epistaxis at 9 weeks. CT of the head demonstrated nasal and frontal sinus involvement. Nasal biopsy and culture identified infection with a *Cladophialophora* species not previously reported to cause disease. Initial response to a combination of itraconazole and terbinafine was noted, but owing to severe thrombocytopenia this combination was discontinued. Voriconazole was used but discontinued because of adverse side effects. Posaconazole treatment was offered throughout the clinical course but rejected owing to financial constraints and an uncertain response to medical therapy. Rhinotomy with debulking of diseased tissue and topical malachite green treatment was performed. Following the procedure itraconazole was continued and the cat has had no recurrence for over 1 year.

**Relevance and novel information** Infections by *Cladophialophora* species have been reported in veterinary species, including cats. The specific fungal organism isolated from this cat has not been previously reported to cause disease in humans or animals and has only been described in the mangroves of Brazil. Furthermore, this is the first report to describe the use of topical malachite green as a treatment for refractory phaeohyphomycosis.

**Accepted:** 16 March 2018

## Introduction

Phaeohyphomycosis are cutaneous, subcutaneous or systemic fungal infections caused by ubiquitous saprophytic agents with a worldwide distribution and represent an emerging cause of opportunistic fungal infections. Eight species of *Cladophialophora* have been identified, with natural occurrence in soil and vegetation.<sup>1,2</sup> *Cladophialophora bantiana* is the most frequently reported in human and veterinary medicine, with infections reported in dogs, cats and other species.<sup>3–8</sup> Infections are often refractory to antifungal treatment and relapses common.<sup>5,8,9</sup> Currently recommended treatment includes aggressive surgical resection of affected

<sup>1</sup>Department of Small Animal Clinical Sciences, University of Florida, College of Veterinary Medicine, Gainesville, FL, USA

<sup>2</sup>Department of Comparative, Diagnostic, and Population Medicine, University of Florida, College of Veterinary Medicine, Gainesville, FL, USA

<sup>3</sup>Division of Nephrology, Hypertension and Renal Transplantation, Gainesville, FL, USA

### Corresponding author:

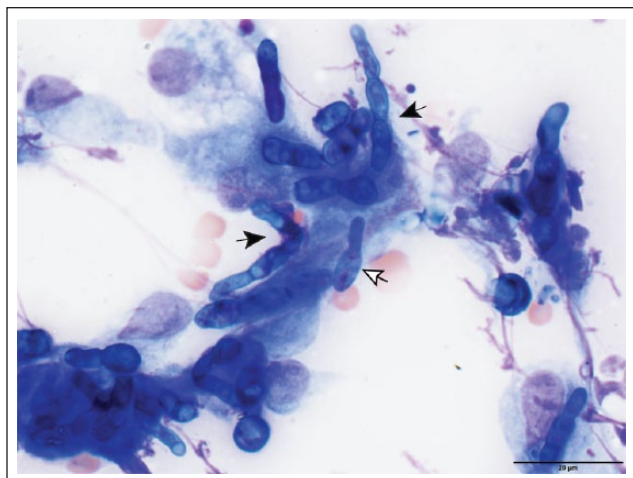
Stuart A Walton BVSc(Hons), BScAgr(Hons), MANZCVS (Small Animal Internal Medicine), Department of Small Animal Clinical Sciences, University of Florida, College of Veterinary Medicine, 2015 SW 16th Avenue, PO Box 100116, Gainesville, FL 32611-0880, USA

Email: stuartawalton@ufl.edu



Creative Commons Non Commercial CC BY-NC: This article is distributed under the terms of the Creative Commons

Attribution-NonCommercial 4.0 License (<http://www.creativecommons.org/licenses/by-nc/4.0/>) which permits non-commercial use, reproduction and distribution of the work without further permission provided the original work is attributed as specified on the SAGE and Open Access pages (<https://us.sagepub.com/en-us/nam/open-access-at-sage>).



**Figure 1** Cytologic sample obtained via fine-needle aspiration of the ulcerative nasal lesion containing septated fungal elements (~3  $\mu\text{m}$ ), moderately basophilic to green, of varying length with occasional acute angular branching found within macrophages (black arrows) and free in the background. Some fungal elements demonstrate ballooning of internal and/or terminal segments (white arrow). Wright-Giemsa stain at x 100 objective

tissue with long-term azole antifungal therapy post-surgery owing to local recurrence of disease.<sup>4,5</sup>

This case report describes an infection caused by a novel species of *Cladophialophora* involving the nasal cavity and frontal sinus, as well as treatment incorporating surgery with a single local infusion of malachite green for disease management.

### Case description

A 1.5-year-old male, neutered, domestic shorthair, indoor-only cat presented to University of Florida Small Animal Hospital (UFSAH) with a 2 month history of progressive nasal swelling, noted initially as crusting over the bridge of the nose, and hyporexia. Fine-needle aspirate cytology of the swelling had been inconclusive, with scant cocci identified. Partial lesion remission was achieved with empiric oral enrofloxacin (3.5 mg/kg PO q24h [Baytril; Pfizer]). Owing to persistent disease, a tapering course of prednisone (0.75 mg/kg PO q24h for 7 days then 0.75 mg/kg q48h) was administered with no visible improvement.

On physical examination (day 1), a firm soft-tissue swelling (1 cm  $\times$  1 cm  $\times$  0.5 cm) was noted on the dorsum of the nose. No nasal discharge was present. Diminished right nasal airflow was appreciated, through a negative slide condensation test. Complete blood count and serum biochemistry were unremarkable. Serological tests for feline immunodeficiency virus antibody, feline leukemia virus antigen (SNAP FIV/FelV Combo Test; IDEXX Laboratories) and *Cryptococcus*

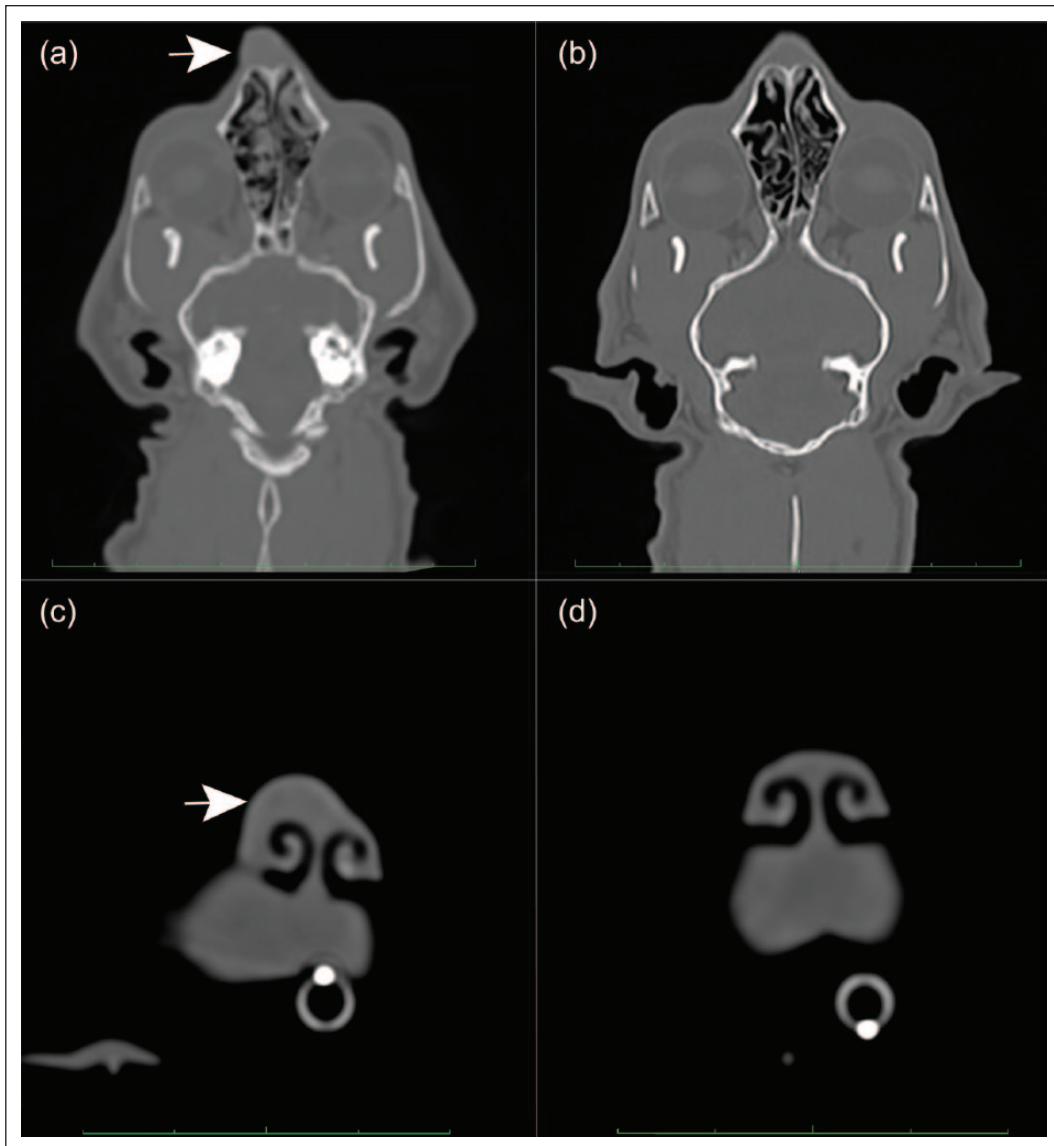
antigen (Remel *Cryptococcus* Antigen Latex Test; Thermo Fisher Scientific) were negative.

A presumptive diagnosis of pyogranulomatous inflammation secondary to phaeohyphomycosis was made based on the identification of moderately basophilic to green fungal elements of varying length within macrophages, existing as fungal mats within clusters of macrophages, and free in the background on cytology. Hyphae (~3  $\mu\text{m}$  diameter) had roughly parallel walls, frequent ballooning of internal and/or terminal segments and less frequent acute angular branching (Figure 1). Biopsy and cultures were declined and empiric antifungal therapy consisting of compounded itraconazole (4.9 mg/kg PO q 12h) was instituted.

At day 42 the nasal swelling was unchanged. Repeat serum biochemistry was unremarkable. On day 63 the cat developed intermittent epistaxis. Contrast-enhanced CT of the head and antegrade blind nasal biopsies using pituitary cup graspers were performed. Findings included a soft-tissue-attenuating nodule (9 mm  $\times$  4 mm  $\times$  9 mm) with moderate contrast enhancement on the dorsal aspect of the right nasal planum. Soft tissue-attenuating, non-contrast-enhancing material was present in the right nasal cavity with accompanying multifocal turbinate lysis (Figure 2). The frontal sinuses contained non-contrast-enhancing, soft tissue-attenuating material without lysis. Biopsy samples were submitted for histopathology and fungal culture and sensitivity. Itraconazole was continued and terbinafine (28.9 mg/kg PO q 24h) was initiated pending results. Histopathology identified multifocal-to-coalescing, moderate-to-marked chronic neutrophilic and lymphohistiocytic rhinitis with fibrosis and bony resorption of the nasal turbinates. Large numbers of Grocott-Gomori methenamine silver stain (GMS)-positive fungal hyphae (2–6  $\mu\text{m}$  diameter) with septate, variable parallel to non-parallel walls that exhibited occasional acute angle branching. Within the intraluminal exudate, there were small numbers of 6–9  $\mu\text{m}$  diameter GMS-positive piriform yeasts, or pseudohyphal structures, exhibiting broad-based budding (Figure 3).

Fungal isolate identification was performed by combined phenotypic characterization and DNA sequencing of the internal transcribed spacer (ITS) region on a pure isolate (Fungus Testing Laboratory, Department of Pathology, University of Texas Health Science Center at San Antonio, Department of Pathology, San Antonio, TX, USA). A previously described *Cladophialophora* species was identified.<sup>10</sup> Susceptibility testing was performed (Table 1). There are no established breakpoints available in veterinary species for these organisms.<sup>11</sup> The cat's clinical signs improved with initiation of terbinafine.

On day 168 the cat developed generalized pruritus, which was managed by the referring veterinarian and a board-certified dermatologist with cefovecin (8 mg/kg



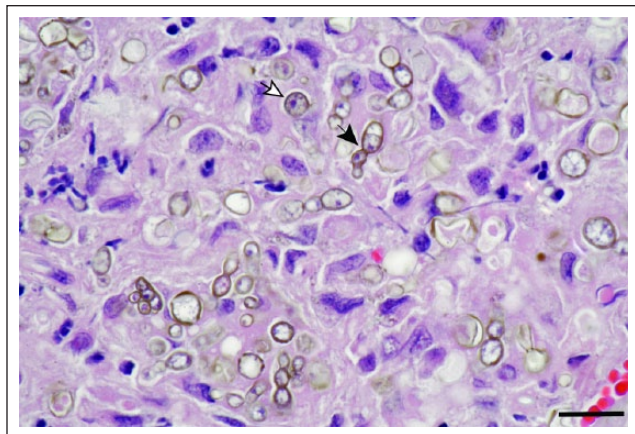
**Figure 2** (a,b) CT images of dorsal plane, post-contrast (window level [WL] 350, window width [WW] 2700) and (c,d) transverse plane post-contrast (WL 350, WW 1500). (a) Multiplanar reformat (MPR) of available post-contrast data; (b–d) MPRs of the volume data. (a,c) Contrast-enhancing swelling is shown on the dorsum of the nose (white arrows). (b,d) Six month postoperative images revealing resolution of the previous swelling

SC [Convenia; Zoetis]), a novel-protein diet (Royal Canin Feline Selected Protein Rabbit and Pea Diet; Royal Canin), topical moxidectin (1%)/imidacloprid (10% [Advantage Multi; Bayer]), lime sulfur dips, topical oatmeal product, topical neem oil and pentoxifylline (14.5 mg/kg PO q12h).

On day 175, the cat presented to UFSAH for progressive lethargy, hyporexia and acute diarrhea. Small areas of hypopigmentation and alopecia were present at the ear base and multiple areas of excoriation present on the face (left commissure, lateral canthi, chin and ear base). Hematologic abnormalities included marked thrombocytopenia (6 K/ $\mu$ l; reference interval [RI] 160–502 K/ $\mu$ l)

with mild anemia (packed cell volume 28.9% [RI 34–51%]). Serum biochemistry was unremarkable. A drug reaction was suspected and itraconazole, terbinafine and pentoxifylline discontinued. Mirtazapine (0.63 mg/kg PO q48h) was started. Clinical improvement of the acute signs was noted within 48 h. Two weeks later (day 189), the thrombocytopenia and anemia had resolved. However, recurrent nasal swelling was noted and itraconazole restarted at the previous dose. Terbinafine, considered as the likely cause of thrombocytopenia, due to recent initiation, concurrent development of thrombocytopenia and because no prior thrombocytopenia was noted with itraconazole, was not restarted. Additional





**Figure 3** Histopathology of nasal biopsy. Large numbers of tan-to-brown hyphae (~2–6 µm) septate, parallel to non-parallel walls with occasional acute angle branching (black arrow), pseudohyphae and yeast-like structures (white arrow) scattered throughout the tissue, composed of moderate fibrovascular stroma. Hematoxylin and eosin stained section at x 580 magnification. The black bar measures 15.5 µm

therapeutic options were discussed, including other antifungal drugs (posaconazole, amphotericin B), intranasal clotrimazole infusions and aggressive surgical debridement. The owners refused to change from itraconazole to posaconazole because of the cost of prolonged therapy and they were fearful of additional adverse reactions. They eventually agreed to surgical debridement in the face of progressive disease.

The cat was anesthetized and underwent rhinotomy and fungal debulking 9 months (252 days) after initial presentation due to progressive disease. Abdominal ultrasound, serum biochemistry, urinalysis and urine culture and sensitivity performed before the procedure revealed mild renal azotemia (urine specific gravity 1.025, creatinine 2.3 mg/dl [RI 1.0–2.1 mg/dl]) with a negative urine culture. Abdominal ultrasound identified enlarged colic lymph nodes. Cytology of fine-needle aspirates of the nodes demonstrated a heterogeneous lymphoid population without fungal hyphae. During surgery, the left and right dorsal nasal cavities were exposed and necrotic tissue debrided. Following debridement, umbilical tape soaked in 100 ppm malachite green solution was packed into each nasal cavity and left in place for 12 mins. Postoperatively, itraconazole was discontinued and voriconazole (4.2 mg/kg PO q24h) started. Histopathology was consistent with previous biopsies.

Two weeks after surgery (day 266), the cat presented for lethargy and hyporexia. A moderate thrombocytopenia (42 K/µl [RI 160–502 K/µl]) and persistent mild azotemia (creatinine 2.6 mg/dl [RI 1.0–2.1 mg/dl]) were identified. Voriconazole was discontinued and supportive care, consisting of mirtazapine (0.63 mg/kg PO q48h) and intravenous fluids (lactated Ringer's solution

**Table 1** Fungal susceptibility testing of isolated *Cladophialophora* species

Drug	Inhibitory concentration (µg/ml)
Fluconazole	16
Itraconazole	0.5
Posaconazole	0.25
Voriconazole	0.5

11 ml/h) was initiated. The cat was discharged after 24 h. Voriconazole was discontinued and itraconazole (4.9 mg/kg PO q12h) was restarted. No further adverse effects were observed.

At day 420 (6 months post-surgical debridement and topical malachite green), follow-up CT of the head was performed. The cat was asymptomatic and oral itraconazole continued to be well tolerated. There were no hematological or biochemical abnormalities. The previously identified soft-tissue-attenuating material in the left nasal cavity and focal mass on the nasal planum were absent (see Figure 2). Moderate lysis of the nasal turbinates persisted with the nasal septum remaining deviated toward the left within the mid-nasal cavity. Static soft tissue-attenuating material was present throughout the right nasal cavity and right frontal sinus. Approximately 13 months (day 616) after surgical debridement, topical malachite green and continued itraconazole the cat remains free of clinical signs.

## Discussion

At the time of writing this case report, the cat was clinically well with stable/static disease. Varied and temporally spaced treatments make interpretation of the cat's disease status (stable disease vs remission with persistent inflammation) difficult and the efficacy of each intervention unclear. Given the incomplete response to itraconazole, it appears reasonable that surgical debridement and malachite green treatment were responsible for clinical improvement and lack of disease progression. While a definitive cure was not confirmed with histopathology, culture or PCR, the clinical sign-free interval of more than 12 months following the last major intervention should be considered a positive outcome. Owing to a lack of information in the literature concerning therapy, little comparative information on survival times is available. In general, patients receiving immunosuppressive therapy or those that have non-invasive lesions, have a better response to therapy and a more desirable outcome than cerebral and/or invasive phaeohyphomycosis, which has a worse prognosis, with most cats being euthanized at or around the time of diagnosis, or within several months of treatment initiation.<sup>4,7,8,12–14</sup>

The *Cladophialophora* species infection in this cat was isolated to the skin and the nasal cavity. The nature of

exposure in this cat is unclear; although inhalation is possible, a dermal wound or trauma is considered the most likely route of infection given the initial cutaneous involvement. The fungal organism isolated from this cat was identified using standard PCR techniques of the ITS1 and ITS2 regions and shared perfect sequence homology with a *Cladophialophora* species identified as an environmental isolate from the Brazilian mangroves (Fungus Testing Laboratory, Department of Pathology, University of Texas Health, TX, USA; Zoo Medicine Infectious Disease Testing, University of Florida, College of Veterinary Medicine, Gainesville, FL, USA).<sup>10</sup> The isolate is related to, but genetically separate from, *C bantiana*, the most recognized species causing mammalian disease, generally affecting the central nervous system.

Current treatment recommendations for phaeohyphomycosis are based upon human literature and veterinary case reports.<sup>3-5,7,15-19</sup> Refractory disease is related to the organism's inherent features enabling evasion of the host's immune system. Melanin is the characteristic feature, reducing the organism's susceptibility to the host's immune response through scavenging free radicals released by phagocytic cells and by blocking the effects of acid hydrolases on fungal cell walls.<sup>12</sup> Other features include thick cell walls, meristematic growth, presence of a combination of forms/phases within tissue (ie, septate hyphae, yeast-like cells and pseudohyphae), thermo- and osmotolerance, and the production of extracellular polysaccharides, siderophores, and acidic or alkaline secondary metabolites.<sup>12,18</sup> The greatest impact on long-term survival is associated with aggressive surgical resection if possible, with prolonged adjunctive antifungal therapy.<sup>3,5-7,12,14,15,19-21</sup>

There are no established breakpoints for itraconazole and specific fungal organisms in cats.<sup>22</sup> Itraconazole was chosen as initial treatment for this cat because, although in vitro studies have varied, they have generally shown similar minimum inhibitory concentrations for itraconazole, posaconazole,  $\pm$  terbinafine and voriconazole against a variety of species and strains of *Cladophialophora*.<sup>23-26</sup> Additionally, itraconazole has been recommended as an adjunct to surgical excision of cutaneous phaeohyphomycosis in veterinary patients, with the use of posaconazole or voriconazole being recommended for recurrent infections.<sup>21</sup> In retrospect, however, the use of compounded itraconazole was a poor choice as recent data showed that a compounded formulation of itraconazole produced very low plasma concentrations in dogs.<sup>27</sup> Additionally, a more recent publication has shown that a compounded capsule and a compounded suspension also demonstrated poor absorption in cats.<sup>28</sup> As a result of these studies, use of compounded itraconazole is not recommended for treatment of fungal disease in dogs or cats. Poor disease control in this cat may also have been due to poor

owner compliance with administration and/or prolonged time needed to achieve steady-state serum concentrations.<sup>22,27,29,30</sup>

When progressive disease was noted after discontinuing antifungal treatment because of suspected drug-induced thrombocytopenia, other treatment options, including other medications (posaconazole, voriconazole, amphotericin B, intranasal clotrimazole) with or without surgical debridement, were recommended. Despite repeated recommendations, the owners initially refused to allow treatment with other antifungal agents because of the concern for adverse effects. Even in the face of progressive disease, it took almost 2 months for them to consent to surgical debridement, topical malachite green and changing from itraconazole to voriconazole. The decision to use voriconazole instead of posaconazole was largely owing to cost savings, as voriconazole is about one-third the cost of posaconazole. Unfortunately, the cat developed hyporexia and thrombocytopenia, which only served to reinforce the owner's reluctance to consider other antifungal medications.

The literature concerning phaeohyphomycosis in most veterinary species is limited to individual case reports, so there is little to strongly support one antifungal medication over another. A murine model of *Cladophialophora* species infection showed longer survival of mice treated with combination posaconazole therapy vs monotherapy, but long-term survival was poor for all treatment groups.<sup>17</sup> Although there is a single case report of a cat with subcutaneous nasal *Mucor* species infection that responded to oral posaconazole alone, there are no such reports in cats with *Cladophialophora* species infection.<sup>31</sup> A cat with a pulmonary granuloma containing *Cladophialophora* species was treated with posaconazole for 7 months after surgical removal of the granuloma but relapsed within 4 weeks after the drug was discontinued.<sup>7</sup>

Malachite green is a triphenylmethane chemical dye used in the fish and dye industries that possesses antifungal, antiparasitic and antibacterial activity.<sup>32-35</sup> Antifungal activity is attributed to transposition toward fermentative metabolism, depletion of intracellular iron stores and generation of reactive oxygen species leading to cellular necrosis.<sup>36</sup> Historically, in vitro studies demonstrated concentrations as low as 1 ppm are able to reduce the growth of *Candida albicans*, *Aspergillus parasiticus*, *Aspergillus flavus*, *Penicillium verrucosum* and *Fusarium oxysporum*.<sup>34,36</sup> Data related to adverse effects associated with the use of malachite green are limited. Upon ingestion and intestinal absorption, malachite green is reduced to leucomalachite green.<sup>32,33,35</sup> Residues of malachite and leucomalachite green can persist in tissue. Reported side effects based on murine models involving ingestion of the compound include apoptosis

of transitional epithelium of the urinary bladder and thyroid follicles, dose-dependent hepatocellular damage and hepatocellular adenoma.<sup>32,33,36,35</sup> In vitro data on oomycetes and other fungal organisms treated with malachite green, at our teaching hospital, have demonstrated promising results, with reduced disease burden, based on external lesion size, and static disease being elicited for variable periods of time. Malachite green has been used topically, as a pluronic gel, orally and parenterally (IV and SC). Side effects have been acceptable with transient local irritation, cellulitis and vasculitis being noted when the drug is used parenterally, but this route has generally been reserved for cases with an extremely poor prognosis. Povidone iodine is another attractive, readily available, cheap, topical alternative that may be considered with its efficacy being proven in the management of otomycosis in people and fungal resistance yet to be reported.<sup>37</sup>

This case highlights the difficulty in making evidence-based recommendations for treatment of patients with rare fungal infections. It could be argued that a prolonged course of posaconazole, if successful as a monotherapy, might have been of equal or lesser cost than surgery and topical malachite green therapy. However, given the uncertain outcome with prolonged medical therapy, limitations in antifungal options imposed by the owner, and progressive clinical signs despite antifungal therapy, surgical debridement and topical malachite green therapy were elected.

## Conclusions

The fungal organism isolated from this case is consistent with an unnamed *Cladophialophora* species not previously found to cause disease in humans, or other animals. This is the first reported use of topical malachite green for refractory phaeoophomycosis. Treatment was well tolerated, and the cat experienced no adverse side effects with static/stable disease being present for more than 16 months following malachite green treatment. Additional in vitro and in vivo studies are needed to assess the utility and safety of topical malachite green for fungal diseases in veterinary medicine.

**Acknowledgements** The authors would like to thank Dr Mary Leissing for the cytology interpretation, Dr Kirsten Cooke for her constructive reviews of this paper and Dr Philip 'PJ' Hamel for the CT interpretation.

**Conflict of interest** The authors declared no potential conflicts of interest with respect to the research, authorship, and/or publication of this article.

**Funding** The authors received no financial support for the research, authorship, and/or publication of this article.

## References

- 1 Abliz P, Fukushima K, Takizawa K, et al. **Specific oligonucleotide primers for identification of *Cladophialophora carrionii*, a causative agent of chromoblastomycosis.** *J Clin Microbiol* 2004; 42: 404–407.
- 2 Badali H, Carvalho VO, Vicente V, et al. ***Cladophialophora saturnica* sp. nov., a new opportunistic species of *Chaetothyriales* revealed using molecular data.** *Med Mycol* 2009; 47: 51–66.
- 3 Coldrick O, Brannon CL, Kydd DM, et al. **Fungal pyelonephritis due to *Cladophialophora bantiana* in a cat.** *Vet Rec* 2007; 161: 724–728.
- 4 Lloret A, Hartmann K, Pennisi MG, et al. **Rare opportunistic mycoses in cats: phaeoophomycosis and hyalophomycosis. ABCD guidelines on prevention and management.** *J Feline Med Surg* 2013; 15: 628–630.
- 5 Abramo F, Bastelli F, Nardoni S, et al. **Feline cutaneous phaeoophomycosis due to *Cladophialophora bantiana*.** *J Feline Med Surg* 2002; 4: 157–163.
- 6 Elies L, Balandraud V, Boulouha L, et al. **Fatal systemic phaeoophomycosis in a cat due to *Cladophialophora bantiana*.** *J Vet Med* 2003; 50: 50–53.
- 7 Evans N, Gunew M, Marshall R, et al. **Focal pulmonary granuloma caused by *Cladophialophora bantiana* in a domestic short haired cat.** *Med Mycol* 2011; 49: 194–197.
- 8 Russell EB, Gunew MN, Dennis MM, et al. **Cerebral pyogranulomatous encephalitis caused by *Cladophialophora bantiana* in a 15-week-old domestic shorthair kitten.** *JFMS Open Rep* 2016; 2: DOI: 10.1177/2055116916677935.
- 9 Zambelli AB and Griffiths CA. **South African report of first case of chromoblastomycosis caused by *Cladosporium* (syn *Cladophialophora*) *carrionii* infection in a cat with feline immunodeficiency virus and lymphosarcoma.** *J Feline Med Surg* 2015; 17: 375–380.
- 10 Guerra RS, Nascimento MMFD, Miesch S, et al. **Black yeast bioata in the mangrove, in search of the origin of the lethargic crab disease (LCD).** *Mycopathologia* 2013; 174: 421–430.
- 11 Clinical and Laboratory Standards Institute. Reference method for broth dilution antifungal susceptibility testing of filamentous fungi: approved standard. 2nd ed. Wayne, PA: Clinical and Laboratory Standards Institute, 2008.
- 12 Revankar SG, Sutton DA and Rinaldi MG. **Primary central nervous system phaeoophomycosis: a review of 101 cases.** *Clin Infect Dis* 2004; 38: 206–216.
- 13 Mariani CL, Platt SR, Scase TJ, et al. **Cerebral phaeoophomycosis caused by *Cladosporium* spp. in two domestic shorthair cats.** *J Am Anim Hosp Assoc* 2002; 38: 225–230.
- 14 Grooters AM and Foil CS. **Miscellaneous fungal infections.** In: Greene CE (ed). *Infectious diseases of the dog and cat*. 4th ed. St Louis, MO: Elsevier Saunders, 2011, pp 675–688.
- 15 Añor S, Sturges BK, Lafranco L, et al. **Systemic phaeoophomycosis (*Cladophialophora bantiana*) in a dog – clinical diagnosis with stereotactic computed tomographic-guided brain biopsy.** *J Vet Intern Med* 2001; 15: 257–261.
- 16 Bouljihad M, Lindeman CJ and Hayden DW. **Pyogranulomatous meningoencephalitis associated with dematiaceous fungal (*Cladophialophora bantiana*) infection in a domestic cat.** *J Vet Diagn Invest* 2002; 14: 70–72.



- 17 Marine M, Pastor FJ and Guarro J. **Combined antifungal therapy in a murine model of disseminated infection by *Cladophialophora bantiana*.** *Med Mycol* 2009; 47: 45–49.
- 18 Seyedmousavi S, Guillot J and Hoog GSD. **Phaeohyphomycoses, emerging opportunistic diseases in animals.** *Clin Microbiol Rev* 2013; 26: 19–35.
- 19 Garzoni C, Markham L, Bijlenga P, et al. ***Cladophialophora bantiana*: a rare cause of fungal brain abscess. Clinical aspects and new therapeutic options.** *Med Mycol* 2008; 46: 481–486.
- 20 Guillot J, Garcia-Hermoso D, Degorce F, et al. **Eumycetoma caused by *Cladophialophora bantiana* in a dog.** *J Clin Microbiol* 2004; 42: 4901–4903.
- 21 Gooters AM. **Miscellaneous fungal diseases.** In: Sykes JE (ed). *Canine and feline infectious diseases*. St Louis, MO: Elsevier Saunders, 2014, pp 660–667.
- 22 Middleton SM, Kubier A, Dirikolu L, et al. **Alternate-day dosing of itraconazole in healthy adult cats.** *J Vet Pharmacol Ther* 2015; 39: 27–31.
- 23 Baldali H, Hoog GSD, Curfs-Breuker I, et al. **Use of amplified fragment length polymorphism to identify 42 *Cladophialophora* strains related to cerebral phaeohyphomycosis with in vitro antifungal susceptibility.** *J Clin Microbiol* 2010; 48: 2350–2356.
- 24 Chakrabarti A, Kaur H, Rudramurthy SM, et al. **Brain abscess due to *Cladophialophora bantiana*: a review of 124 cases.** *Med Mycol* 2016; 54: 111–119.
- 25 Deng S, de Hoog GS, Badali H, et al. **In vitro antifungal susceptibility of *Cladophialophora carrionii*, an agent of human chromoblastomycosis.** *Antimicrob Agents Chemother* 2013; 57: 1974–1977.
- 26 Vitale RG, Perez-Blanco M and Hoog GSD. **In vitro activity of antifungal drugs against *Cladophialophora* species associated with human chromoblastomycosis.** *Med Mycol* 2009; 47: 35–40.
- 27 Mawby DI, Whittemore JC, Genger S, et al. **Bioequivalence of orally administered generic, compounded, and innovator-formulated itraconazole in healthy dogs.** *J Vet Intern Med* 2014; 28: 72–77.
- 28 Mawby DI, Whittemore JC, Fowler LE, et al. **Comparison of absorption characteristics of oral reference and compounded itraconazole formulations in healthy cats.** *J Am Vet Med Assoc* 2018; 252: 195–200.
- 29 Boothe DM, Herring I, Calvin J, et al. **Itraconazole disposition after single oral and intravenous and multiple oral dosing in healthy cats.** *Am J Vet Res* 1997; 58: 872–877.
- 30 Liang C, Shan Q, Zhong J, et al. **Pharmacokinetics and bioavailability of itraconazole oral solution in cats.** *J Feline Med Surg* 2016; 18: 310–314.
- 31 Wray JD, Sparkes AH and Johnson EM. **Infection of the subcutis of the nose in a cat caused by *Mucor* species: successful treatment using posaconazole.** *J Feline Med Surg* 2008; 10: 523–527.
- 32 Culp SJ, Mellick PW, Trotter RW, et al. **Carcinogenicity of malachite green chloride and leucomalachite green in B6C3F<sub>1</sub> mice and F344 rats.** *Food Chem Toxicol* 2006; 44: 1204–1212.
- 33 Culp SJ, Blankenship LR, Kusewitt DF, et al. **Toxicity and metabolism of malachite green and leucomalachite green during short-term feeding to Fischer 344 rats and B6C3F<sub>1</sub> mice.** *Chem Biol Interact* 1999; 122: 153–170.
- 34 Bragulat MR, Abarca ML, Bruguera MT, et al. **Dyes as fungal inhibitors: effect on colony diameter.** *Appl Environ Microbiol* 1991; 57: 2777–2780.
- 35 Donya SM, Farghaly AA, Abo-zeid MA, et al. **Malachite green induces genotoxic effect and biochemical disturbances in mice.** *Eur Rev Med Pharmacol Sci* 2012; 16: 469–482.
- 36 Dhamgaye S, Devaux F, Manoharlal R, et al. **In vitro effect of malachite green on *Candida albicans* involves multiple pathways and transcriptional regulators *UIC2* and *STP2*.** *Antimicrob Agents Chemother* 2011; 56: 495–506.
- 37 Philip A, Thomas R, Job A, et al. **Effectiveness of 7.5 percent povidone iodine in comparison to 1% clotrimazole with lignocaine in the treatment of otomycosis.** *ISRN Otolaryngol* 2013; 2013: 239730.