



Feline gastric pneumatosis

Authors: Silveira, Carla, Benigni, Livia, Gugich, Kaye, and McClaran, Janet Kovak

Source: Journal of Feline Medicine and Surgery Open Reports, 4(2)

Published By: SAGE Publishing

URL: <https://doi.org/10.1177/2055116918782779>

BioOne Complete (complete.BioOne.org) is a full-text database of 200 subscribed and open-access titles in the biological, ecological, and environmental sciences published by nonprofit societies, associations, museums, institutions, and presses.

Your use of this PDF, the BioOne Complete website, and all posted and associated content indicates your acceptance of BioOne's Terms of Use, available at www.bioone.org/terms-of-use.

Usage of BioOne Complete content is strictly limited to personal, educational, and non - commercial use. Commercial inquiries or rights and permissions requests should be directed to the individual publisher as copyright holder.

BioOne sees sustainable scholarly publishing as an inherently collaborative enterprise connecting authors, nonprofit publishers, academic institutions, research libraries, and research funders in the common goal of maximizing access to critical research.



Feline gastric pneumatosis

Carla Silveira¹, Livia Benigni^{1,2}, Kaye Gugich¹
and Janet Kovak McClaran¹

Journal of Feline Medicine and Surgery Open Reports
1–5

© The Author(s) 2018

Reprints and permissions:

sagepub.co.uk/journalsPermissions.nav

DOI: 10.1177/2055116918782779

journals.sagepub.com/home/jfmsopenreports

This paper was handled and processed

by the European Editorial Office (ISFM)

for publication in *JFMS Open Reports*



Abstract

Case summary A 9-year-old male neutered domestic shorthair cat was presented with a 2 day history of anorexia and vomiting. A minimum database, including a complete blood count, serum biochemistry profile and urinalysis were unremarkable apart from a toxic neutrophilic left shift and borderline proteinuria. Abdominal ultrasound revealed intramural gas entrapment with thinning of the gastric wall, a hypoechoic pancreas, peritoneal fluid and a small volume of peritoneal gas along with a hyperechoic mesentery. CT was performed and demonstrated gas within the gastric submucosa and gas in the peritoneal cavity. Generalised gastric erythema was present at surgery and histopathology of excised abnormal areas reported gastric erosion with no obvious causative agents; however, pretreatment with dexamethasone may have been a contributing factor. Culture from biopsied gastric tissue was sterile. Clinical signs resolved after partial gastrectomy and medical management.

Relevance and novel information Feline gastric pneumatosis is a rare clinical finding. Imaging is essential for diagnosis and to decide on the appropriate treatment; this is often medical but in cases where there is suspicion or evidence of gastric perforation, surgery is indicated. To our knowledge, this is the first case of feline gastric pneumatosis secondary to gastric ulceration, diagnosed via CT and where dexamethasone may have been a contributing factor.

Keywords: Pneumatosis, computed tomography, imaging, novelty

Accepted: 18 May 2018

Introduction

Pneumatosis is the presence of air in an abnormal location in the body. Gastric pneumatosis is the term used to describe air in the wall of the stomach. It is a rare condition in humans, and to our knowledge only a few cases of canine gastrointestinal pneumatosis have been reported,^{1–6} and one case of feline gastric pneumatosis.⁷

Possible causes of gastric pneumatosis in dogs and cats include gastric ulceration (eg, secondary to steroid medication), foreign bodies, surgery, necrosis of the gastric wall (eg, gastric dilatation and volvulus), invasion of gastric mucosa by gas-producing bacteria, trauma and secondary to pancreatitis.^{4,5,7} Aetiologies described in humans include ischaemia, necrosis, inflammation, mucosal disruption, increased mucosal permeability, trauma and pulmonary disease.^{8–11}

The clinical signs include non-specific gastrointestinal signs such as regurgitation, abdominal pain and vomiting.⁷

CT is the preferred method of diagnosing the condition in humans, but radiography and ultrasonography can also play an important role.^{10,12,13} Depending on the underlying cause and severity of the condition, medical or surgical treatment is indicated.^{3,5,6}

Case description

A 9-year-old male neutered domestic shorthair cat was presented to the first-opinion practice with a 2 day history of anorexia and vomiting. Physical examination was unremarkable; therefore, the cat was treated

¹London Veterinary Specialists, London, UK

²Amwell Veterinary Practice, London, UK

Corresponding author:

Carla Silveira DVM, MRCVS, certAVP (SAM), London Veterinary Specialists, 56 Belsize Lane, London NW3 5AR, UK

Email: ca.silveira@hotmail.com



Creative Commons Non Commercial CC BY-NC: This article is distributed under the terms of the Creative Commons

Attribution-NonCommercial 4.0 License (<http://www.creativecommons.org/licenses/by-nc/4.0/>) which permits non-commercial use, reproduction and distribution of the work without further permission provided the original work is attributed as specified on the SAGE and Open Access pages (<https://us.sagepub.com/en-us/nam/open-access-at-sage>).

Table 1 Haematology

	Result	Reference interval
RBCs ($\times 10^{12}/l$)*	5.58	5.5–10.0
Hb (g/dl)	9.8	9.0–17.0
HCT (%)	32	27.0–50.0
MCV (fl)	46.8	40.0–55.0
MCH (pg)	14.5	13.0–21.0
MCHC (g/dl)	31.0	28.0–36.0
RDW (%)	16.0	18–23
Platelets (n) [†]	81	151–600
WBCs ($\times 10^9/l$)	8.15	4.0–15.0
Neutrophils ($\times 10^9/l$) [‡]	6.44	2.5–12.5
Bands ($\times 10^9/l$)	0.65	0–0.3
Lymphocytes ($\times 10^9/l$)	1.6	1.5–7.0
Monocytes ($\times 10^9/l$)	0.00	0–0.8
Eosinophils ($\times 10^9/l$)	0.00	0–1.5
Reticulocyte (%)	0.3	
Reticulocyte count ($\times 10^9/l$)	16.14	

*Scanty polychromatic cells, slight anisocytosis, poikilocytes +

[†]Giant platelets and platelet clumps. Actual platelet count appeared normal

[‡]Dohle bodies present

RBCs = red blood cells; Hb = haemoglobin; HCT = haematocrit; MCV = mean cell volume; MCHC = mean cell haemoglobin content; RDW = red cell distribution width; WBCs = white blood cells

Table 2 Biochemistry

	Result	Reference interval
Albumin (g/l)	43	22–44
ALP (U/l)	22	10–90
ALT (U/l)	84	20–100
Amylase (U/l)	664	300–1100
Total bilirubin ($\mu\text{mol/l}$)	4	2–10
Urea (mmol/l)	7.9	3.8–10.7
Total calcium (mmol/l)	2.37	2.0–2.95
Phosphorus (mmol/l)	1.33	1.10–2.74
Creatinine $\mu\text{mol/l}$	158	27–188
Glucose (mmol/l)	7.8	3.9–8.3
Sodium (mmol/l)	147	142–184
Potassium (mmol/l)	4.4	3.7–5.8
Total protein (g/l)	78	54–82
Globulins (g/l)	33	15–57

ALP = alkaline phosphatase; ALT = alanine transaminase

symptomatically with 1 mg/kg maropitant SC (Cerenia; Zoetis), 0.2 mg/kg dexamethasone SC (Dexadreson; MSD) and Hill's Prescription Diet i/d. The following day the cat's clinical signs had not improved – it developed abdominal pain and pyrexia, prompting its admission to the hospital.

Routine haematology (Table 1) showed a toxic neutrophilic left shift and Dohle bodies. Serum biochemistry (Table 2) was normal. Urinalysis, including multistick, specific gravity, culture and urine protein:creatinine ratio,

showed borderline proteinuria (Table 3). An abdominal-focused assessment using sonography for trauma was performed showing no effusion. Supportive treatment was initiated with intravenous fluid therapy (Vetiflex 11 [Hartmann's]; Dechra), 1 mg/kg maropitant IV, 1 mg/kg omeprazole IV (Losec; AstraZeneca) and 0.2 mg/kg methadone IV (Physeptone; Martindale Pharma).

The following day the cat was referred for an abdominal ultrasound with a board-certified radiologist, which revealed peritoneal effusion in the cranial abdomen and hyperechoic mesentery. The pancreas was enlarged and hypoechoic. There were foci of hyperechogenicity in the cranial abdomen adjacent to the pylorus and possibly within the pancreas. There was thinning of the gastric wall with hyperechoic material within the gastric wall layers. At the level of the pylorus there was an area where hyperechoic material seemed to cross the entire gastric wall thickness. The suspicion of pancreatitis, peritonitis, gastric ulceration and gastric perforation with free gas in the abdomen was raised on the basis of the ultrasonography findings.

Serosanguinous fluid was retrieved via ultrasound-guided abdominocentesis. In-house cytology showed erythrocytes and occasional free bacteria; however, no intracellular bacteria were identified. The free bacteria were therefore judged to be of questionable clinical significance, and likely related to contamination of the staining solutions.

The cat was prepared for further imaging with a pre-medication of 0.2 mg/kg of methadone IV, 2 $\mu\text{g}/\text{kg}$ of

Table 3 Urinalysis

	Results
Urine protein (mg/dl)	0.10
Urine creatinine (mmol/l)	3.45
Urine protein:creatinine	0.29
	(reference <0.5)
Specific gravity	1.038
pH	6
Protein	Negative
Glucose	+
Ketones	Negative
Urobilinogen	Negative
Bilirubin	Negative
Haemoglobin	Negative
Urine sediment	
RBCs	<6/hpf
WBCs	<3/hpf
Epithelial cells	None seen
Bacteria	None seen
Crystals	++triple phosphate
Casts	None seen
Urine culture	No growth

RBCs = red blood cells; hpf = high-power field; WBCs = white blood cells

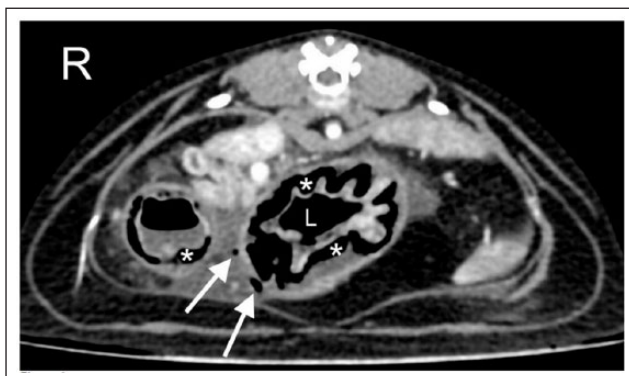


Figure 1 Abdominal CT. There are a few small gas bubbles within the peritoneal cavity and adjacent to the lesser curvature of the stomach at the level of the body/pylorus (arrows). There is gas within the gastric wall, within the submucosa (asterisks). There is a small amount of fluid in the stomach. L = lumen

medetomidine hydrochloride IV (Dorbene; Zoetis) and 0.2 mg/kg of midazolam IV (Hypnovel; Roche). Induction of anaesthesia was performed with alfaxalone IV (Alfaxan; Jurox), and the cat was intubated and maintained with isoflurane in oxygen.

CT of the thorax and abdomen was performed. The thoracic images were considered normal. The abdominal images showed a small amount of peritoneal fluid and a few small gas bubbles within the peritoneum located

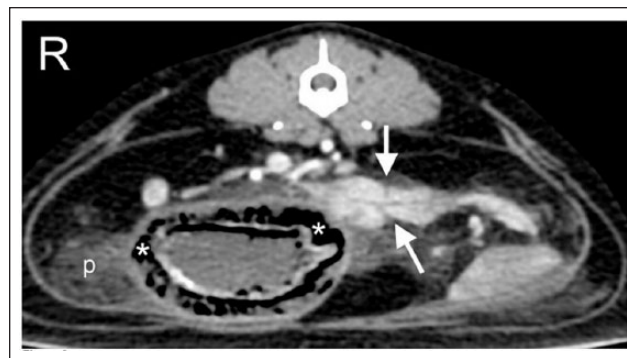

Figure 2 Abdominal CT. There are a few linear hypodense lines crossing the pancreas (arrows) and a small amount of peritoneal fluid (p). The asterisks represent gas within the gastric wall, within the submucosa

adjacent to the lesser curvature of the stomach, at the level of the gastric body/pylorus (Figure 1). There was gas within the submucosal layer of the gastric wall (Figure 2) and stripy areas of hypoattenuation were seen within the pancreas.

The findings were considered to be consistent with gastric wall ulceration, gastric pneumatosis, pneumoabdomen and peritonitis. Necrosis of the gastric wall was raised as a possibility. The pancreatic appearance was compatible with pancreatic oedema and/or pancreatitis.

The cat was administered 20 mg/kg cefuroxime IV (Zinacef; GlaxoSmithKline) and an exploratory laparotomy was performed. A sample of the abdominal effusion was collected for culture. Evidence of a diffusely abnormal gastric wall with generalized erythema and distension was found. A 2 cm × 2 cm focal area of thinned gastric wall was palpated along the lesser curvature of the pyloric antrum at the level identified on the CT scan. However, no evidence of a full-thickness perforated ulcer was found, and a partial gastrectomy was performed of this abnormal region identified at the junction of the cardia and pyloric antrum. An enlarged gastric lymph node was also excised. All samples were sent for histopathology and culture. An esophagostomy tube (14 Fr Mila) was placed at the time of surgery. Anaesthesia, as well as recovery, were routine.

The cat remained in hospital with the following treatment: 10 mg/kg metronidazole IV (q12h [Metronidazole; Braun]), 20mg/kg cefuroxime IV (q8h), 1mg/kg maropitant IV (q24h), 1mg/kg omeprazole IV (q24h). Analgesia with 0.2 mg/kg methadone IV was administered and adjusted based on Colorado Pain Score Composite, every 4 h. Enteral nutrition was provided with Royal Canin Recovery Liquid until the cat was voluntarily eating 100% of its resting energy requirements.

Histology of the stomach revealed multifocal areas of marked erosion of the gastric mucosa. The lamina propria was effaced and replaced by a layer of eosinophils

and basophilic debris containing large quantities of erythrocytes and degenerate neutrophils. The muscularis layer had smooth muscle degeneration. No *Helicobacter* species were seen. No neoplastic process was identified.

The lymph node histology was consistent with neutrophilic lymphadenitis. Aerobic and anaerobic culture of the gastric tissue was negative. Extended aerobic and anaerobic culture, as well as fungal culture from the abdominal effusion, was also negative.

At the time of writing (12 months following surgery) the cat remains clinically well with no recurrence of gastrointestinal clinical signs and with no ongoing treatment.

Discussion

Pneumatosis is the accumulation of gas within a tissue, and in humans is most commonly described in the colon and less commonly described in the stomach.¹⁴ Gastric pneumatosis is a rare condition with multiple aetiologies reported in humans,¹¹ dogs⁴ and cats.⁷

A few theories have been proposed to explain the pathogenesis of gastric pneumatosis in humans: (1) the mechanical theory, involving proximal gastrointestinal obstruction, which leads to chronically elevated gastric pressure with emesis and subsequent gastric mucosal tears, resulting in infiltration of air into the submucosal space;¹¹ (2) the bacterial theory, in which bacteria enter the gastric wall and produce gas;¹² (3) the pulmonary theory, hypothesising that diffusion of air occurs from alveolar rupture, through the blood vessels and the gastrointestinal wall; and (4) the mucosal damage theory, in which luminal gas under pressure is forced into the gastrointestinal wall either through an intact or injured mucosa (eg, ulceration).¹⁵ Cases of gastric pneumatosis induced by chemotherapy drugs (eg, vincristine) and dexamethasone have also been described.^{12,16} Finally, iatrogenic pneumatosis has been described after endoscopic procedures and nasogastric tube placement.¹⁷

Anything that compromises gastric wall integrity can cause pneumatosis. In this cat we speculate that the use of a high dose of steroids, possibly combined with pre-existing gastritis of unknown aetiology, may have led to gastric ulceration, secondary pneumatosis and gastric perforation.

To our knowledge, there is only one previous report of feline gastric pneumatosis, diagnosed with a combination of radiology and ultrasonography.⁷

In humans the imaging modality of choice for diagnosing pneumatosis is CT, owing to its high sensitivity in detecting small volumes of air within soft tissue, followed by radiography and ultrasonography.⁹ The typical CT findings include gas density that follows the lineal or curve fringe orientation of the gastric wall lining,¹² occasionally accompanied by pneumoperitoneum,

as was seen in this cat's case. Imaging findings are not indicative of severity of disease, underlying cause or associated prognosis.¹²

Common radiographic findings of gastric pneumatosis include a distended stomach outlined by linear, curvilinear or mottled gas lucency within often thinned gastric walls, parallel to the border of the stomach. These lucencies remain constant with positional change of the patient.⁸ Fat within the submucosal layer can mimic pneumatosis as both produce a lucent line parallel to the stomach wall.¹⁸ Contrast radiography has been used in humans to demonstrate intramural penetration of contrast.¹²

Ultrasonography can be used to diagnose gastric pneumatosis and may help with identifying smaller volumes of air compared with radiography.¹³ The characteristic findings include hyper-reflective hyperechoic foci within the gastrointestinal wall. These must be differentiated from intraluminal air and intramural fat.^{3,7} Intramural gas stays stationary within the wall, even with compression, as opposed to intraluminal gas. This could help with distinguishing both conditions. Some authors have described the ultrasonographic appearance of gastric pneumatosis as a 'gastric corona sign' in humans, which implies a diffuse involvement of the entire circumferential wall of the stomach.¹³

There are two conditions that can be associated with the presence of gas within the gastric wall, which are indistinguishable on imaging: gastric pneumatosis (or gastric emphysema), thought to be caused by air dissecting the wall through the various mechanisms mentioned above, whereas emphysematous gastritis is postulated to be related to gas-producing bacteria.¹⁹ Humans with gastric emphysema are often asymptomatic or may show mild gastric symptoms, such as vomiting. There is no standard treatment and in most cases the condition has a benign course, resolving within a few days.²⁰ In the case of this cat, although no macroscopic evidence of perforation of the gastric wall was found, this was thought to be due to spontaneous resealing of the original tear, or the presence of a microscopic tear leading to passage of air into the abdomen. The presence of peritonitis may have exacerbated the clinical signs and prompted the need for laparotomy and excision of abnormal gastric tissue, which has resulted in a complete recovery. Human patients affected by emphysematous gastritis have a much more acute presentation, often showing severe abdominal pain, shock and septicaemia. Despite recommended treatment with broad-spectrum antibiotics, fluids and nutritional support, the mortality rate is high.²¹

Conclusions

Gastric pneumatosis is a rare condition in cats, which is readily diagnosed with CT. This case describes radiographic, ultrasonographic and CT findings in a case

of feline gastric pneumatosis associated with gastric ulceration. Often, medical management is recommended in humans, but in this case surgical excision of a suspected perforated gastric ulcer was indicated.

Conflict of interest The authors declared no potential conflicts of interest with respect to the research, authorship, and/or publication of this article.

Funding The authors received no financial support for the research, authorship, and/or publication of this article.

References

- Russell NJ, Tyrrell D, Irwin PJ, et al. **Pneumatosis coli in a dog.** *J Am Anim Hosp Assoc* 2008; 44: 32–35.
- Morris ME. **Pneumatosis coli in a dog.** *Vet Radiol Ultrasound* 1992; 33: 154–157.
- Choi JH, Kim TE, Kim HW, et al. **Ultrasonographic findings of pneumatosis intestinalis in a dog.** *J Vet Clin* 2013; 30: 138–141.
- Fischetti AJ, Saunders HM, Kenneth MS, et al. **Pneumatosis in canine gastric dilatation-volvulus syndrome.** *Vet Radiol Ultrasound* 2004; 45: 205–209.
- Aste G, Boari A, Guglielmini C, et al. **What is your diagnosis? Pneumatosis coli.** *J Am Vet Med Assoc* 2005; 227: 1407–1408.
- Degner AD. **Pneumatosis coli in a dog.** *Canadian Vet J* 1992; 33: 609–611.
- Lang LG, Greatting HH and Spaulding KA. **Imaging diagnosis – gastric pneumatosis in a cat.** *Vet Radiol Ultrasound* 2011; 52: 658–660.
- Pear BL. **Pneumatosis intestinalis: a review.** *Radiology* 1998; 207: 13–19.
- Ho LM, Paulson EK and Thompson WM. **Pneumatosis intestinalis in the adult: benign to life-threatening causes.** *Am J Roentgenol* 2007; 188: 1604–1613.
- Kernagis LY, Levine MS and Jacobs JE. **Pneumatosis intestinalis in patients with ischemia: correlation of CT findings with viability of bowel.** *Am J Roentgenol* 2003; 180: 733–736.
- D’Cruz R and Emil S. **Gastroduodenal emphysema.** *J Pediatr Surg* 2008; 43: 2121–2123.
- Lopez-Medina G, Leon RCD, Heredia-Salazar AC, et al. **Gastric emphysema a spectrum of pneumatosis intestinalis: a case report and literature review.** *Case Rep Gastrointest Med* 2014; 2014: 1–5.
- Chang Y, Wang H, Huang G, et al. **Sonographic ‘gastric corona sign’: diagnosis of gastric pneumatosis caused by a penetrating gastric ulcer.** *J Clin Ultrasound* 1999; 27: 409–412.
- Hawn MT, Canon CL, Lockhard ME, et al. **Serum lactic acid determines the outcomes of CT diagnosis of pneumatosis of the gastrointestinal tract.** *Am Surg* 2004; 70: 19–23.
- St Peter SD, Abbas MA and Kelly KA. **The spectrum of pneumatosis intestinalis.** *Arch Surg* 2003; 138: 68–75.
- Zander T, Briner V, Buck F, et al. **Gastric pneumatosis following polychemotherapy.** *Eur J Intern Med* 2007; 18: 251–252.
- Ting YJ, Chang K, Wong SM, et al. **Gastric pneumatosis in a premature neonate.** *Am J Perinatol Rep* 2011; 1: 11–13.
- Ranger AL. and Approach to abdominal radiographs. In: Schaer M and Gaschen F (eds). *Clinical medicine of the dog and cat.* 3rd ed. Boca Raton, FL: CRC Press, 2016, p 538.
- Pauli EM, Tomasko JM, Jain V, et al. **Multiple recurrent episodes of gastric emphysema.** *Case Rep Surg* 2011; 2011: DOI: 10.1155/2011/587198.
- Khan SA, Boko E, Khookhar HA, et al. **Acute gastric dilatation resulting in gastric emphysema following postpartum hemorrhage.** *Case Rep Surg* 2012; 2012: DOI: 10.1155/2012/230629.
- Szuchmacher M, Bedford T, Sukharamwala P, et al. **Is surgical intervention avoidable in cases of emphysematous gastritis? A case presentation and literature review.** *Int J Surg Case Rep* 2013; 4: 456–459.