



Caudal mandibular fracture repair using three-dimensional printing, presurgical plate contouring and a preformed template to aid anatomical fracture reduction

Authors: Southerden, Peter, and Barnes, Duncan M

Source: Journal of Feline Medicine and Surgery Open Reports, 4(2)

Published By: SAGE Publishing

URL: <https://doi.org/10.1177/2055116918798875>

BioOne Complete (complete.BioOne.org) is a full-text database of 200 subscribed and open-access titles in the biological, ecological, and environmental sciences published by nonprofit societies, associations, museums, institutions, and presses.

Your use of this PDF, the BioOne Complete website, and all posted and associated content indicates your acceptance of BioOne's Terms of Use, available at www.bioone.org/terms-of-use.

Usage of BioOne Complete content is strictly limited to personal, educational, and non - commercial use. Commercial inquiries or rights and permissions requests should be directed to the individual publisher as copyright holder.

BioOne sees sustainable scholarly publishing as an inherently collaborative enterprise connecting authors, nonprofit publishers, academic institutions, research libraries, and research funders in the common goal of maximizing access to critical research.



Caudal mandibular fracture repair using three-dimensional printing, presurgical plate contouring and a preformed template to aid anatomical fracture reduction

Journal of Feline Medicine and Surgery Open Reports
1–6

© The Author(s) 2018

Reprints and permissions:

sagepub.co.uk/journalsPermissions.nav

DOI: 10.1177/2055116918798875

journals.sagepub.com/home/jfmsopenreports

This paper was handled and processed

by the European Editorial Office (ISFM)

for publication in *JFMS Open Reports*



Peter Southerden ¹ and Duncan M Barnes ²

Abstract

Case summary Two cats were presented with mandibular fractures following head trauma. Following a CT scan, both were diagnosed with fractures of the ramus. The CT scans were used to print three-dimensional (3D) models of the mandibular fractures, which were used to pre-contour stainless steel mini-plates. These were fixed to the models and the screw positions used to produce a stainless steel template. The template was used as a pattern during surgery to drill holes in the ramus so that the pre-contoured mini-plates could be fixed in the exact same position as they had been on the 3D model. The fractures healed in both cats achieving normal jaw function and occlusion.

Relevance and novel information Conventional techniques used to treat caudal mandibular fractures in cats, such as maxillomandibular fixation and bignathic encircling and retaining device (BEARD), are associated with significant patient morbidity and postoperative complications. Internal rigid fixation is difficult because of small bone size, requirement for considerable plate contouring and difficulty in achieving accurate anatomical reduction of caudal mandibular fractures. These are the first reported cases of mini-plate fixation of caudal mandibular fractures in cats using 3D models, pre-contouring of bone plates and the use of a template to facilitate accurate plate positioning, which may provide an alternative technique suitable for fixing caudal mandibular fractures in cats.

Keywords: Fracture; mandible; ramus; fixation; plate

Accepted: 6 July 2018

Introduction

Mandibular fractures are common in cats, representing 14.5% of fractures identified.¹ Symphyseal fractures are reportedly the most common mandibular fracture,¹ but these are frequently accompanied by caudal fractures affecting the ramus and body of the mandible.

Fractures of the caudal part of the mandible are often associated with malocclusion (Figure 1), and stabilisation of these fractures is difficult.² Access to the fracture site is challenging and the bone of the ramus is thin, ranging from about 1.5 mm in its central part to 3.5 mm at its leading rostral edge.

Various techniques have been reported for repair of mandibular fractures including circummandibular cerclage wiring, intraoral wire and acrylic splints, maxillo-mandibular fixation (MMF), interfragmentary wire,

external fixators, bignathic encircling and retaining device (BEARD), and internal rigid fixation (IRF) using mini-plates and screws.^{2–5}

Caudal mandibular fractures affect the mandibular body, ramus and condyle caudal to the mandibular first

¹Department of Dentistry and Oral Surgery, Eastcott Veterinary Referrals, Swindon, UK

²Department of Orthopaedic Surgery, Eastcott Veterinary Referrals, Swindon, UK

Corresponding author:

Peter Southerden BVSc, MBA, DipEVDC, MRCVS, Department of Dentistry and Oral surgery, Eastcott Referrals, Edison Park, Dorcan Way, Swindon SN3 3FR, UK
Email: Southerdenp@gmail.com



Creative Commons Non Commercial CC BY-NC: This article is distributed under the terms of the Creative Commons

Attribution-NonCommercial 4.0 License (<http://www.creativecommons.org/licenses/by-nc/4.0/>) which permits non-commercial use, reproduction and distribution of the work without further permission provided the original work is attributed as specified on the SAGE and Open Access pages (<https://us.sagepub.com/en-us/nam/open-access-at-sage>).

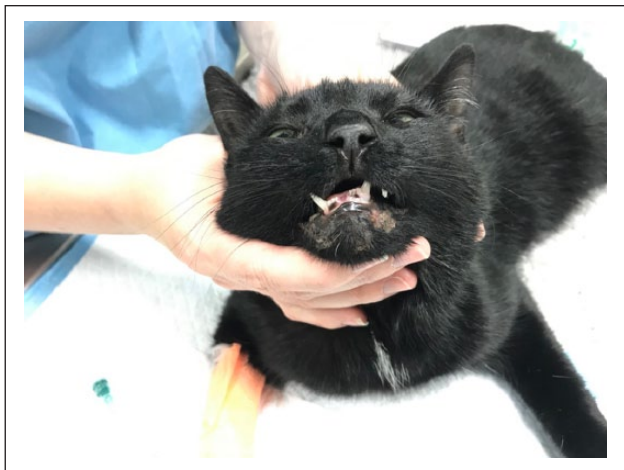


Figure 1 Cat with right-sided caudal mandibular fracture demonstrating lateral deviation of the mandibles towards the side of the fracture

molar. Application of an intraoral splint is not possible as there are no teeth caudal to the fracture to allow fixation. Circummandibular cerclage wiring is only suitable for the fixation of symphyseal or parasymphyseal fractures. MMF and BEARD are both techniques advocated for caudal fractures and can be used successfully. However, both techniques are associated with a high degree of patient morbidity during the period of inter-arcade fixation. Problems include: difficulty with thermoregulation, long duration of hospitalisation and assisted feeding, and increased risk of aspiration of food or regurgitated stomach contents.^{3,5-8} As BEARD does not involve fracture reduction and rigid fixation there is greater potential for post-fixation malocclusion than for rigid MMF.² Rigid MMF requires breaking of the fixation for intubation following induction for follow-up imaging, which carries risks of tooth fracture and requires reapplication of the fixation if the fracture healing is inadequate.³ Inter-fragmentary wiring is not suited to the thin, fragile bone of the feline ramus. Similarly, much of the bone of the ramus is unsuitable for the use of external fixators owing to the poor pin bone interface, leading to premature pin loosening and pull-out.³

In humans and larger dogs the ramus has a relatively large, slightly curved surface that is accessible surgically and which lends itself to stabilisation using IRF with plates and screws. This provides accurate fracture reduction and construct stability.^{3,9} In cats, plate fixation is more difficult owing to small bone size, the need for greater contouring of implants and the difficulty in achieving accurate anatomical reduction during implant application, because of the small fragment size and small surface area of the fracture surfaces.

The advantages of IRF in the treatment of mandibular fractures are the accurate restoration of normal anatomy and occlusion and rapid return to normal function. The aim of this paper is to evaluate a new, previously

unreported technique, utilising three-dimensional (3D) printing, presurgical plate contouring and a preformed template to aid screw placement.

Case description

The medical records of two cats that presented to the Dentistry and Oral Surgery Department of Eastcott Referrals, Swindon, UK, in July and August 2017 were reviewed.

Diagnosis of caudal mandibular fracture was based on clinical examination and CT scan. Transverse 0.625 mm collimated CT images using a Lightspeed 4 (GE Healthcare) CT scanner with kVp of 120 and auto-mA were obtained for both cats before surgery, immediately postoperatively and then 36 weeks (cat 1) and 6 weeks (cat 2) postoperatively to assess the progression of bone healing. Both cases had fractures extending from the rostral margin of the ramus, close to its junction with the mandibular body, to the caudal extent of the ramus either immediately dorsal or ventral to the neck of the condyle (Figure 2a,b).

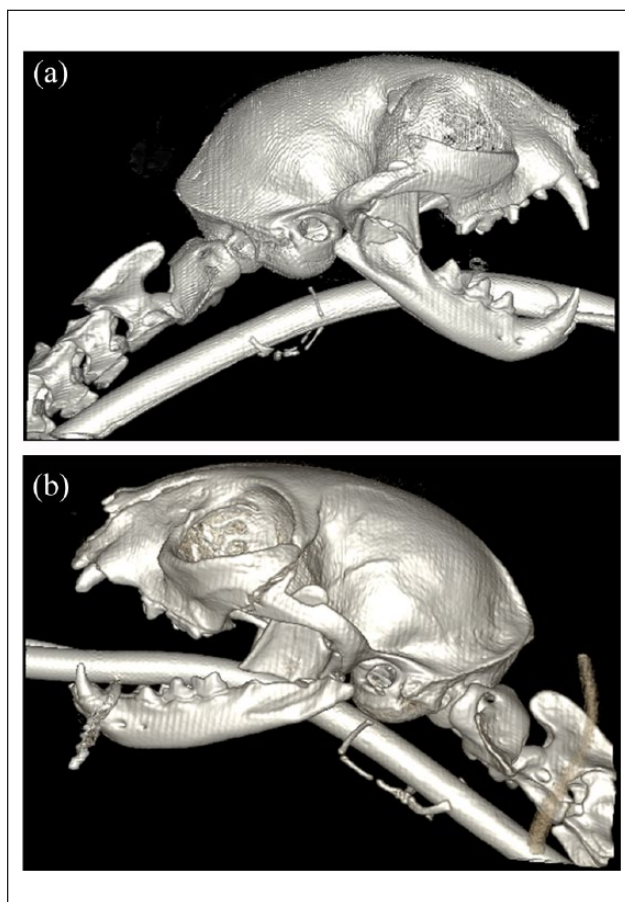


Figure 2 (a) Three-dimensional reconstruction of CT scan of cat 1 with an horizontal comminuted fracture of the mandibular ramus. (b) Three-dimensional reconstruction of CT scan of cat 2 showing fracture of the zygomatic arch and horizontal fracture of the mandibular ramus

Prior to fracture fixation, both cats were treated in a similar manner. Nutritional requirements were calculated and given using a high-energy convalescence support diet (Convalescence Support; Royal Canin) via an oesophageal feeding tube.

A preoperative CT scan of each cat was used as a template to print a 3D model of the complete lower jaw using a nylon selective laser sintering EOS P1 printer (Figure 3). The model of the caudal mandibular fracture was then disassembled to separate the fracture fragments. The mandible model was then reconstructed and the fracture

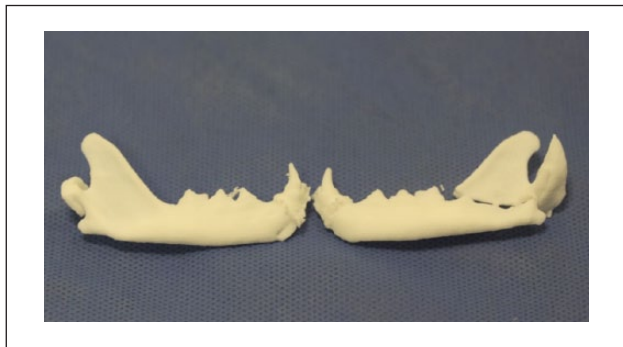


Figure 3 Three-dimensional printed models of the right and left mandibles of a cat with a caudal jaw fracture

fragments fixed in position using a light-cured dental composite (Figure 4a). A seven-hole 1.0 mm stainless steel reconstruction bone plate was contoured to conform to the ramus at its rostral edge and extend to the ventral margin of the caudal mandibular body. The plate was fixed to the model using 1.0 mm stainless steel screws with a 0.25 mm pitch. A second shorter plate (in cat 1 a three-hole 1.0 mm stainless-steel plate and in cat 2 a four-hole 1.0 mm stainless steel T-plate) was also contoured to conform to the fracture caudal to the first plate and fixed to the model (Figure 4b).

The plates and screws were removed from the reconstructed 3D model leaving the screw positions marked by the screw holes. A stainless-steel template was then made to fit exactly over the dorsal fracture fragment and the position of the screw holes was marked (Figure 4c,d). The contoured plates, screws and stainless steel template were autoclaved ready for surgery.

Pre- and postoperative analgesia was achieved with buprenorphine (Buprenodale; Dechra) 0.02 mg/kg IV q6h and meloxicam (Metacam; Boehringer Ingelheim) 0.05 mg/kg IV q24h. Premedication was with fentanyl (Fentadol; Dechra) 0.002 mg/kg IV and ketamine (Narketan; Vetoquinol) 0.5mg/kg IV. Both patients were induced with alfaxalone (Alfaxan; Jurox) 3 mg/kg IV and maintained on isoflurane (Isoflo; Zoetis) delivered

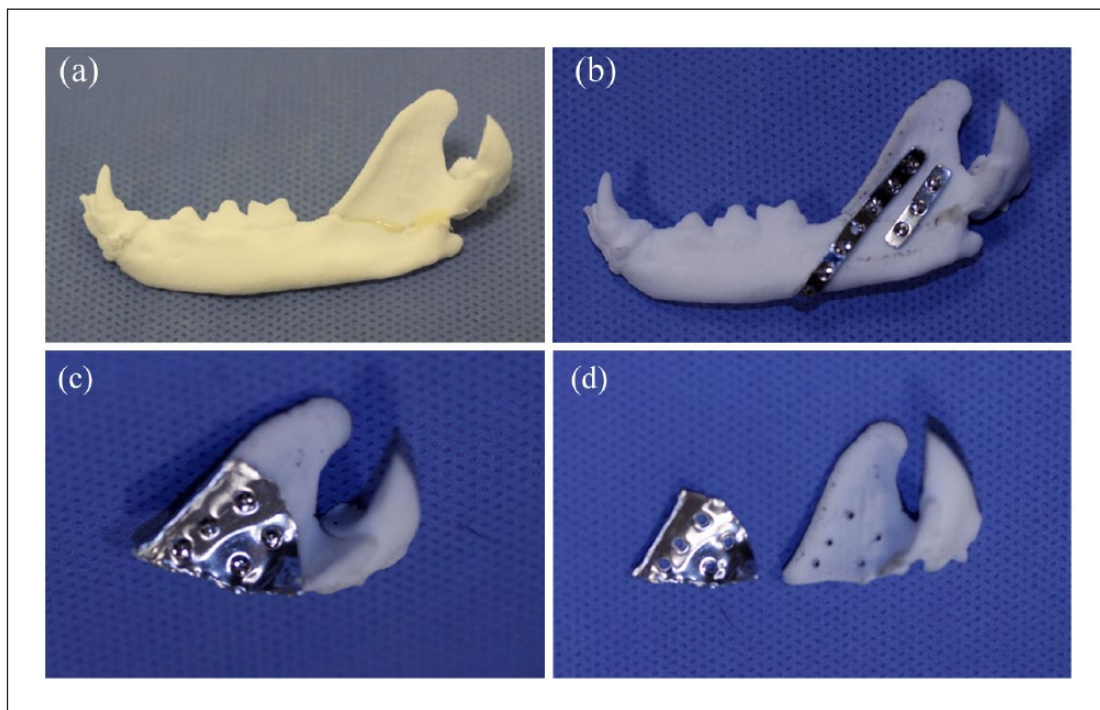


Figure 4 (a) Three-dimensional (3D) printed model of the left mandible of a cat with a caudal jaw fracture following reduction and fixation of the fracture using dental composite. (b) 3D printed model of the left mandible of a cat with a caudal jaw fracture following application of two 1 mm stainless steel plates. (c) 3D model of the dorsal fracture fragment with stainless steel template attached in position. (d) 3D model of dorsal fragment and stainless steel template with screw holes marked

in oxygen by a modified Ayre's T-Piece circuit. A constant rate infusion of ketamine 1 mg/kg/h and fentanyl 0.0025 mg/kg/h was given intraoperatively.

Both cats were prepared for surgery in lateral recumbency and a standard surgical approach made to the ramus. The masseter muscle was elevated from its lateral aspect to allow application of the plate. The pre-contoured stainless steel template was placed precisely over the dorsal mandibular fragment (Figure 5) and stabilised in position using Allis tissue forceps. Four drill holes were made in the dorsal fragment in the position marked on the template.

A seven-hole 1.0 mm pre-contoured stainless steel plate was then fixed to the dorsal fragment using 1.0 mm cortical screws.

The plate was used to manipulate the dorsal fragment and anatomically reduce the fracture so that the contour of the plate adapted perfectly to the ventral fragment. The plate was held in position with bone-holding forceps and screw holes drilled and screws placed in the ventral part of the ramus to complete attachment of the plate. The second pre-contoured plate was then positioned and secured with screws (Figure 6). The surgical site was closed routinely.

A postoperative CT scan was performed to assess the accuracy of the reduction (Figure 7a,b) and the occlusion checked prior to recovery from anaesthesia.

Postoperative CT scans showed excellent anatomical fracture reduction in both cases. This resulted in excellent postoperative occlusion in both cats.

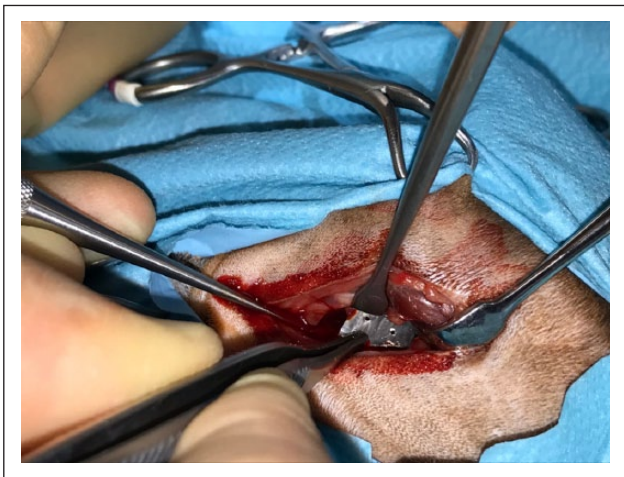

Figure 5 Placement of the stainless steel template over the dorsal mandibular fragment during caudal mandibular fracture repair

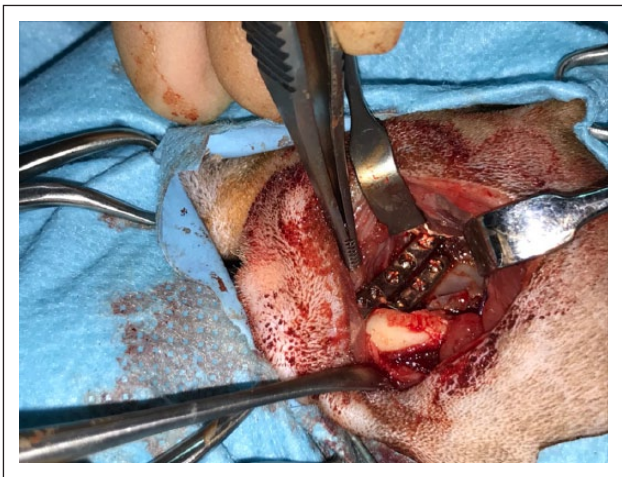


Figure 6 Surgical site with two 1 mm stainless steel plates attached to the lateral aspect of the mandibular ramus

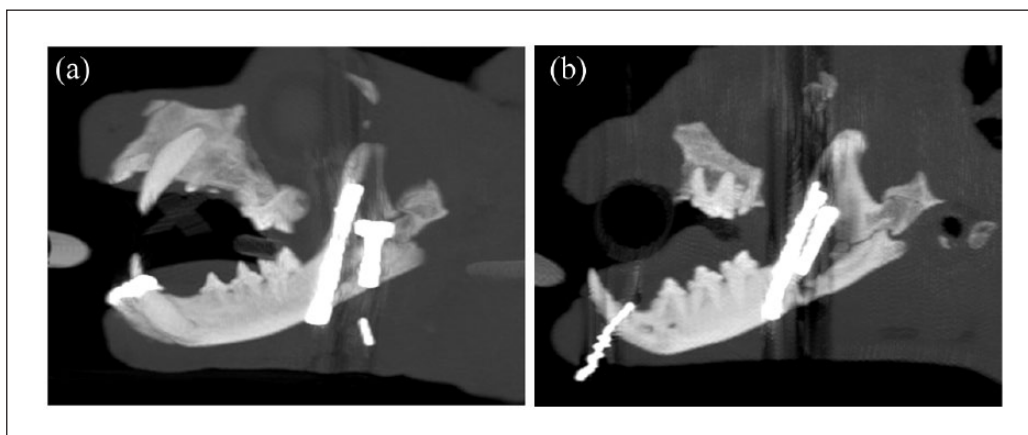


Figure 7 (a) Sagittal CT view of left mandible of cat 1 showing anatomical reduction of the caudal mandibular fracture using two 1 mm stainless steel plates. (b) Sagittal CT view of left mandible of cat 2 showing anatomical reduction of the caudal mandibular fracture using two 1 mm stainless steel plates

Cat 2 started eating within 24 h of the surgery. Cat 1 appeared to have normal jaw function and movement and allowed palpation and movement of its jaws postoperatively, but was reluctant to eat. Further investigation (blood profiles, abdominal ultrasound scan and liver aspirate) confirmed a diagnosis of hepatic lipidosis. This cat was fed via an oesophageal feeding tube until it ate voluntarily 59 days after the surgical procedure.

Discussion

These cases document a technique that was used to successfully treat caudal mandibular fractures in two cats.

CT scanning helps the clinician to gain excellent understanding of the configuration of caudal mandibular fractures. However, there are limitations associated with rendering 3D anatomy into a two-dimensional representation, which affects the understanding of the spatial relationships of fracture fragments.¹⁰ A significant part of the decision-making regarding the placement and contouring of implants has to be performed intraoperatively. Final decisions about implant placement and contouring are time-consuming and subjective. When using non-locking neutralisation plates, poor plate contouring and consequent poor adaption of the plate to the underlying bone increases the risk of plate failure.¹¹

Production of 3D models to facilitate fracture fixation is an established technique that offers surgeons a precise, custom model facilitating a better surgical plan and preoperative plate contouring. This reduces surgical time and plate handling.^{10,12} To our knowledge, these are the first documented cases where 3D modelling has been used to facilitate the fixation of caudal mandibular fractures in cats. Both surgical planning and preoperative plate contouring were beneficial in these cases reducing surgical time and improving the accuracy of the anatomical reduction of the fractures.

One of the challenges in anatomical reduction of caudal jaw fractures in cats is the manipulation of small, thin, fragile bone fragments and maintaining them in reduction while a plate is being applied. This technique allowed the application of the plate to the dorsal fracture fragment prior to fracture reduction and then use of the pre-contoured plate itself to reduce the fracture correctly. The use of a template ensured the plate was attached to the dorsal fracture fragment in the same position as on the 3D model, which facilitated very accurate anatomical reduction of the fracture. This is important, as failure to achieve accurate anatomical fracture reduction may cause malocclusion.⁹

The rostral edge of the ramus is around 3.5 mm thick, reducing to about 1.5 mm thick in its central part. Screw

performance is strongly correlated with bone quality.¹³ It is suggested that at least 1–2 mm of bone thickness is required to place screws for a neutralisation plate,^{2,9,14} and that the thickness of the bone should be at least twice the thread pitch distance of the screw.¹¹ This technique allowed accurate screw placement to ensure screws were placed into the best quality bone. The rostral border of the ramus has been shown to be subject to tensile stress patterns and compressive stress patterns exist on the caudal border. This suggests the rostral border of the ramus is the best bone surface for plate placement to obtain 3D stability.^{9,11}

A second plate was used in both cats. This was placed parallel to the rostral plate in the central part of the ramus and ensured excellent 3D reduction and better support. There is evidence in human jaw surgery that application of a second plate helps to neutralise bending, shearing and torsional forces in mandibular fractures, especially when the mandible is loaded.^{9,15}

Cat 2 started eating very soon after surgery. Cat 1 had a prolonged period of anorexia associated with hepatic lipidosis. In both cats the range of jaw movement and jaw function appeared to be normal following recovery from surgery. Hepatic lipidosis is a rare sequel a to jaw fracture in cats and this is the only instance seen by the authors. It is likely that it was associated with a short period of anorexia following the initial trauma, and highlights the importance of maintaining adequate nutrition in these patients.

In a study of 75 mandibular fractures complications occurred in approximately 60% of cats with mandibular body and condylar fractures and the most common complications were malocclusion and soft tissue infection.¹ Along with fracture healing and analgesia, restoring normal occlusion is a prime objective of jaw fracture repair. Failure to accurately reduce caudal mandibular fractures can result in significant deviation of the rostral segment, which can prevent full closure of the mouth because of malocclusion.¹⁶ The technique reported in these cases allowed accurate anatomical fracture reduction and restoration of normal occlusion (Figure 8a,b).

Conclusions

The use of 3D printed models, presurgical plate contouring and a patient-specific preformed template to aid screw placement and fracture reduction in two cats enabled accurate fracture reduction and the restoration of normal occlusion. This technique facilitated a rapid return to normal function and provides an alternative technique for the fixation of caudal mandibular fractures in cats.

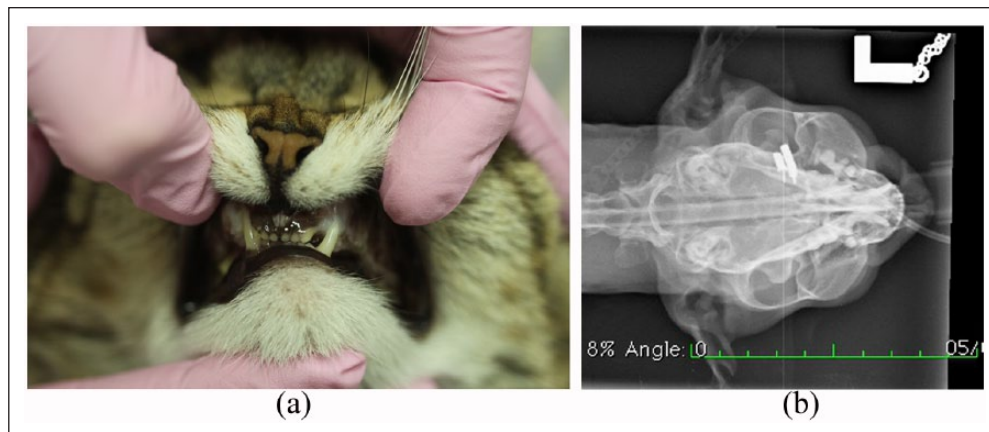



Figure 8 (a) Postoperative picture of cat 1 showing occlusion. (b) Postoperative dorsoventral view of cat 1, showing mandibular symmetry and occlusion

Conflict of interest The authors declared no potential conflicts of interest with respect to the research, authorship, and/or publication of this article.

Funding The authors received no financial support for the research, authorship, and/or publication of this article.

ORCID iD Peter Southerden  <https://orcid.org/0000-0002-1975-2742>

Duncan M Barnes  <https://orcid.org/0000-0002-1562-9472>

References

- Umphlet RC and Johnson AL. **Mandibular fractures in the cat. A retrospective study.** *Vet Surg* 1988; 17: 333–337.
- Woodbridge N and Owen M. **Feline mandibular fractures.** *J Feline Med Surg* 2013; 15: 211–218.
- Bennett JW, Kapatkin AS and Marretta SM. **Dental composite for the fixation of mandibular fractures and luxations in 11 cats and 6 dogs.** *Vet Surg* 1994; 23: 190–194.
- Bilgili H and Kurum B. **Treatment of fractures of the mandible and maxilla by mini titanium plate fixation systems in dogs and cats.** *Aust Vet J* 2003; 81: 671–673.
- Nicholson I, Wyatt J, Radke H, et al. **Treatment of caudal mandibular fracture and temporomandibular joint fracture-luxation using a bi-gnathic encircling and retaining device.** *Vet Comp Ortho Traumatol* 2010; 23: 102–108.
- Hoffer M, Marretta SM, Kurath P, et al. **Evaluation of composite resin materials for maxillomandibular fixation in cats for treatment of jaw fractures and temporomandibular joint luxations.** *Vet Surg* 2010; 40: 357–368.
- Somrak AJ and Marretta SM. **Management of temporomandibular joint luxation in a cat using a custom-made tape muzzle.** *J Vet Dent* 2015; 32: 239–246.
- Zacher AM and Marretta SM. **Oral and maxillofacial surgery in dogs and cats.** *Vet Clin North Am* 2013; 43: 609–649.
- Boudrieau RJ and Kudisch M. **Miniplate fixation for repair of mandibular and maxillary fractures in 15 dogs and 3 cats.** *Vet Surg* 1996; 25: 277–291.
- Winer JN, Verstraete FJM, Cissell DD, et al. **The application of 3-dimensional printing for preoperative planning in oral and maxillofacial surgery in dogs and cats.** *Vet Surg* 2016; 46: 942–951.
- Wong R, Tideman H, Kin L, et al. **Biomechanics of mandibular reconstruction: a review.** *Int J Oral Maxillofac Surg* 2010; 39: 313–319.
- Arzi B, Cissell DD, Pollard RE, et al. **Regenerative approach to bilateral rostral mandibular reconstruction in a case series of dogs.** *Front Vet Sci* 2015; 2: 4. DOI: 10.3389/fvets.2015.00004
- Fernandes D, Elias C and Ruellas A. **Influence of screw length and bone thickness on the stability of temporary implants.** *Materials* 2015; 8: 6558–6569.
- El Khairy S and Mahaini L. **Determination of buccal cortical bone thickness for mini-screws placement in horizontal growth type patients by cone beam computed tomography.** *J Dent Health Oral Disord Ther* 2015; 2: 00073. DOI 10.15406/jdhodt.2015.02.00073
- Ji B, Wang C, Song F, et al. **A new biomechanical model for evaluation of fixation systems of maxillofacial fractures.** *J Craniomaxillofac Surg* 2012; 40: 405–408.
- Milella L. **Occlusion and malocclusion in the cat.** *J Feline Med Surg* 2015; 17: 5–20.