



## **Acquired arteriovenous fistula formation following cephalic vein intravenous catheterisation in a cat**

Authors: Graziano, Lisa, Di Paco, Stefania, Avallone, Giancarlo, and Roccabanca, Paola

Source: Journal of Feline Medicine and Surgery Open Reports, 5(1)

Published By: SAGE Publishing

URL: <https://doi.org/10.1177/2055116919831857>

---

BioOne Complete ([complete.BioOne.org](https://complete.BioOne.org)) is a full-text database of 200 subscribed and open-access titles in the biological, ecological, and environmental sciences published by nonprofit societies, associations, museums, institutions, and presses.

Your use of this PDF, the BioOne Complete website, and all posted and associated content indicates your acceptance of BioOne's Terms of Use, available at [www.bioone.org/terms-of-use](https://www.bioone.org/terms-of-use).

Usage of BioOne Complete content is strictly limited to personal, educational, and non - commercial use. Commercial inquiries or rights and permissions requests should be directed to the individual publisher as copyright holder.

---

BioOne sees sustainable scholarly publishing as an inherently collaborative enterprise connecting authors, nonprofit publishers, academic institutions, research libraries, and research funders in the common goal of maximizing access to critical research.



# Acquired arteriovenous fistula formation following cephalic vein intravenous catheterisation in a cat

Lisa Graziano<sup>1</sup> , Stefania Di Paco<sup>2</sup>, Giancarlo Avallone<sup>3</sup> and Paola Roccabanca<sup>4</sup>

*Journal of Feline Medicine and Surgery Open Reports*  
1–6

© The Author(s) 2019

Article reuse guidelines:

sagepub.com/journals-permissions

DOI: 10.1177/2055116919831857

journals.sagepub.com/home/jfmsopenreports

This paper was handled and processed by the European Editorial Office (ISFM) for publication in *JFMS Open Reports*



## Abstract

**Case summary** A 10-year-old male neutered domestic shorthair cat was presented with a 4 month history of slow, progressive swelling and intermittent multifocal bleeding of the distal right forepaw that progressively developed after cephalic vein catheterisation for anaesthesia. The procedure was performed for dental calculus removal. Initial clinical and biopsy (superficial biopsy) findings matched two differential diagnoses: progressive angiomas and acquired peripheral arteriovenous fistula (AVF). AVF was suspected based on Doppler ultrasound examination that identified multiple abnormal sinusoidal neofomed branching vessels with turbulent high-velocity flow spectrum at the confluence of the artery and vein, and high-velocity arterialised flow in the vein. Owing to rapid and severe progression of lesions after biopsy, the owner requested amputation of the cat's limb. A definitive diagnosis of acquired iatrogenic peripheral AVF was based on deep-tissue microscopical evaluation. High numbers of arterioles and venules in superficial and deep dermis embedded in oedematous stroma were connected to dilated and tortuous vessels with irregularly thickened walls in deep dermis and panniculus. Vasculitis and vascular thrombosis and thickening (attributed to local hypertension) were common findings. No bone or muscular invasion were observed. The cat was doing well 3 years after surgery.

**Relevance and novel information** This report describes a case of iatrogenic acquired peripheral AVF following venous catheterisation in a cat, fully documented for the first time by a combination of clinical findings, ultrasound imaging, complete histopathology and follow-up history.

**Keywords:** Arteriovenous fistula; ultrasound examination; histopathology; surgical treatment

**Accepted:** 28 January 2019

## Case description

A 10-year-old male neutered domestic shorthair cat presented with a 4 month history of slow, progressive swelling of the distal right (mostly dorsolateral) forepaw. Skin lesions evolved to erosions with intermittent multifocal bleeding. Occasional chewing of the lesions was reported. There was no previous history of traumatic injuries. The owner reported that lesions started to develop 3 weeks after cephalic vein catheterisation for anaesthesia and dental calculus removal.

Bacterial infection was initially suspected; thus, a 15 day course of clindamycin (10 mg/kg q24h PO [Clindacyn; Farmaceutici Gellini]) and a 3 day course of prednisolone (0.5 mg/kg q24h PO [Vetsolone; Bayer])

were administered by the referring veterinarian. No improvement was seen. Antibiotic therapy was discontinued 2 days before referral to the dermatologists. Upon

<sup>1</sup>Veterinary Clinic of Meda, Meda, Italy

<sup>2</sup>Milan, Italy

<sup>3</sup>Department of Veterinary Medical Sciences, University of Bologna, Bologna, Italy

<sup>4</sup>Department of Veterinary Medical Sciences, University of Milan, Milan, Italy

### Corresponding author:

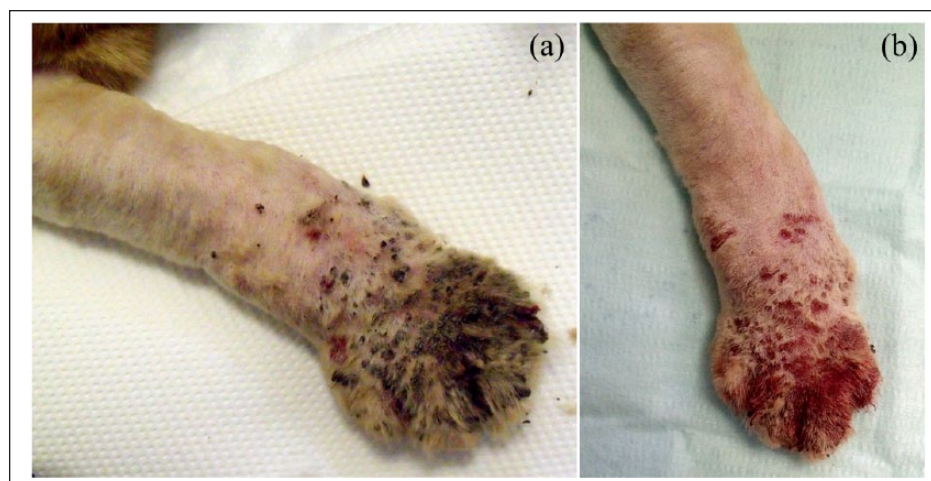
Lisa Graziano DVM, Veterinary Clinic of Meda, via Libertà 76, Meda, 20821, Italy

Email: lisagraziano.vet@gmail.com



Creative Commons Non Commercial CC BY-NC: This article is distributed under the terms of the Creative Commons

Attribution-NonCommercial 4.0 License (<http://www.creativecommons.org/licenses/by-nc/4.0/>) which permits non-commercial use, reproduction and distribution of the work without further permission provided the original work is attributed as specified on the SAGE and Open Access pages (<https://us.sagepub.com/en-us/nam/open-access-at-sage>).



**Figure 1** Clinical pictures of the cat. (a) At presentation the distal limb was swollen, with thick, adherent black-to-red crusts and multifocal round ulcers. (b) Following cleaning of the leg, swelling was more evident, there were multiple ulcers and haemorrhage was more severe in the dorsal distal carpopometacarpal area

referral, the cat was in general good health, no systemic signs were observed and general physical examination was unremarkable with the exception of skin lesions that consisted of moderate soft tissue swelling of distal right dorsal carpus and foot. The skin had adherent black crusts on the dorsum of the right paw and interdigital spaces (Figure 1). There were no lesions on the ventral aspect of the limb. Bleeding was easily provoked by crust removal. Upon palpation, the affected area was manifestly colder than the corresponding surface on the contralateral limb. No pain, pruritus or lameness were elicited.

Based on clinical history, presentation and lack of response to prior therapy, the list of differential diagnoses included vasculitis/vasculopathy, angiomas, a vascular tumour (angioma-angiosarcoma) or an arteriovenous fistula (AVF). Microscopic examination of hair shafts was unremarkable. No parasites or fungal elements were observed, nor were hair shape or cuticular anomalies. Skin scrapings were negative for aetiological agents. Wood's lamp and fungal culture were negative for dermatophytes.

Cytological samples obtained from swollen soft tissues by fine-needle aspiration air dried and stained with May Grünwald-Giemsa stain were characterised by blood contamination and rare plump spindle cells (<10 cells per sample), interpreted as reactive fibroblasts.

Complete blood cell count and biochemical profiles were unremarkable. Four 4 mm punch biopsies were taken under general anaesthesia (pre-anaesthetic medication: 0.2 mg/kg butorphanol and 3 µg/kg dexmedetomidine IM; anaesthesia: 3 mg/kg propofol IV followed by maintenance with isoflurane) from the distal forelimb at the level of the paw and were immediately fixed in 10% neutral buffered formalin.

Microscopic lesions were similar in all biopsies. Lesions were diffuse, severe and characterised by severe diffuse serocellular crusting. Crusts contained keratin scales, degenerated (karyolytic) neutrophils, serum and erythrocytes. Severe diffuse orthokeratotic hyperkeratosis was present in conjunction with severe diffuse epidermal irregular hyperplasia and multifocal erosions and dermal haemorrhages underneath multifocal epidermal ulcers. Variably severe spongiosis, intercellular oedema and mild neutrophilic exocytosis were visible.

Capillaries in the superficial and mid-dermis were multifocally occluded by fibrin thrombi or were highly reactive with plump endothelial cells with prominent nuclei and thickened walls. Angiogenesis and fibroplasia were diffusely present and variably severe in the superficial and mid-dermis. Fibrinoid and necrotising leukocytoclastic vasculitis was multifocally observed.

In the deep dermis at the limit of one of the four biopsies an increased number of vessels, grouped reactive proliferating capillaries and extensive large irregular vessels were locally present.

Microscopic findings were limited owing to the lack of sufficient deep tissue. Clinical signs at presentation, and gross and microscopic lesions were still compatible either with progressive angiomas (PA) or an acquired peripheral AVF and a definitive diagnosis was not considered feasible at this time on microscopic grounds.

Additional clinical evaluations were granted. Ultrasound examination of the forelimb revealed irregular dilation of the cephalic vein with multiple abnormal sinusoidal neofomed branching vessels. Doppler ultrasound revealed a turbulent high-velocity flow spectrum at the confluence of the artery and vein, and high-velocity arterialised flow in the vein.

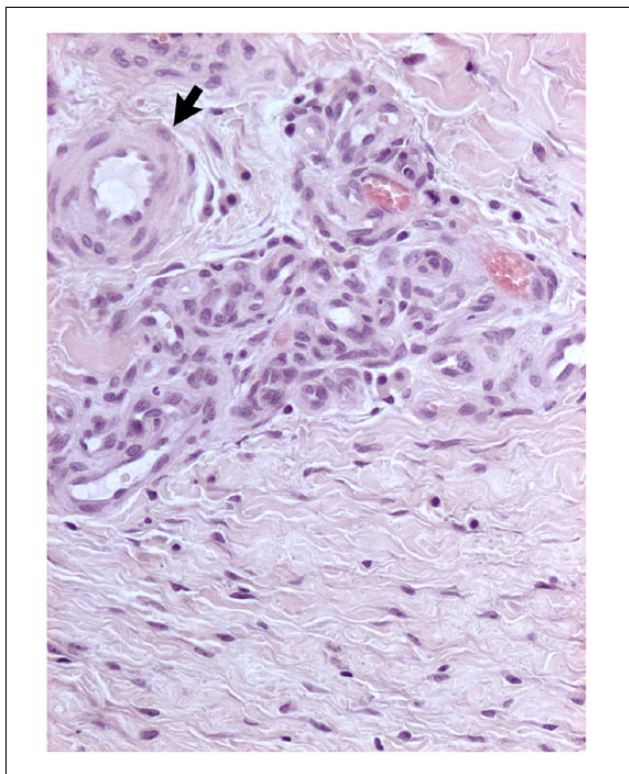
Following biopsy, the cat worsened rapidly over 2–3 weeks, developing pain and lameness that was

unresponsive to anti-inflammatory therapy (meloxicam 0.05 mg/kg PO). There was rapid progression of the lesion proximally, with intense swelling spreading from the right carpus into the antebrachium with intensification of soft tissue swelling.

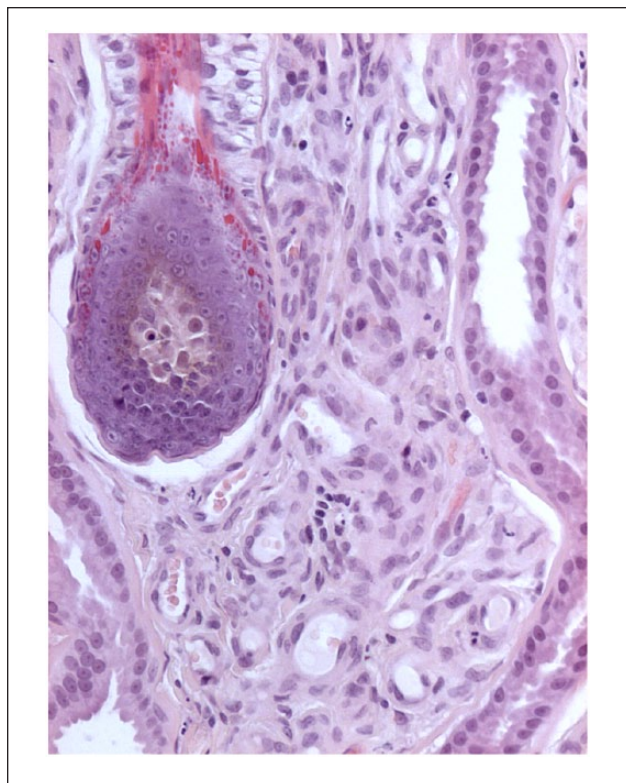Local excision was not feasible at this point, thus the owner opted for amputation of the affected limb under general anaesthesia (pre-anaesthetic medication: 0.2 mg/kg methadone and 3 µg/kg dexmedetomidine IM; anaesthesia: 3 mg/kg propofol IV followed by maintenance with isoflurane and infusion of 10 µg/kg/h fentanyl).

Following surgery, the entire leg was fixed in 10% neutral buffered formalin and lesional tissues were sampled. The residual leg was then demineralised in a solution of 10% hydrochloric acid and formic acid for 1 week. Skin and deep tissues were routinely processed and evaluated microscopically.

Microscopic findings were characterised by surface changes similar to those of the initial biopsies. The mid- and deep dermis and panniculus contained abnormally elevated numbers of vessels of various calibre (Figure 2), with dilated and tortuous profiles and with irregularly thickened walls (Figure 3) and multifocally occluded by fibrin thrombi (Figure 4). Vessel calibre and the occasional



**Figure 2** Cat, haired skin: deep dermis. Group of newly formed vessels with predominance of capillaries lined by one layer of plump reactive endothelial cells admixed with one arteriole (arrow). Haematoxylin and eosin stain



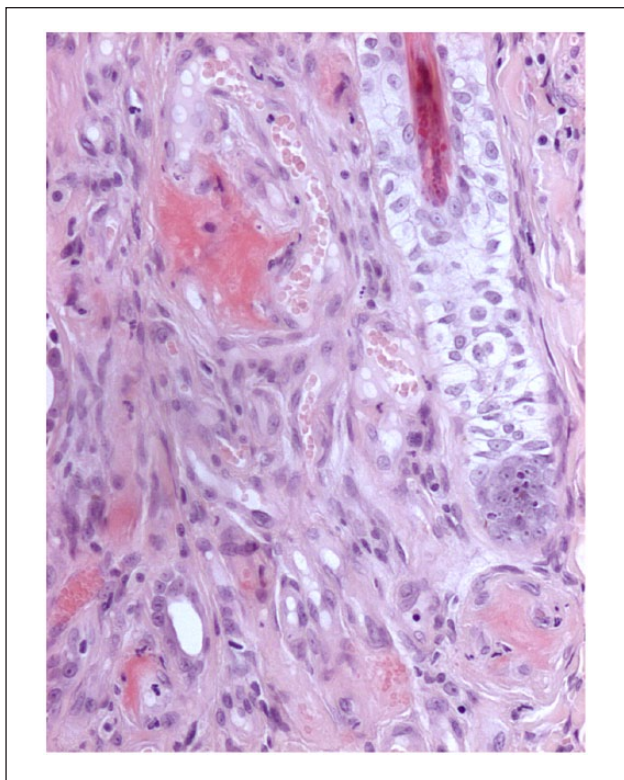
**Figure 3** Cat, haired skin: mid-dermis. Abnormally elevated numbers of capillaries lined by one layer of plump reactive endothelial cells expanding interfollicular areas and surrounding hair follicles and adnexa. Haematoxylin and eosin stain

presence of lamina elastica allowed the identification of arterioles and venules among the proliferation. Deep vessels were also characterised by transmural thickening of the vasculature due to spindle-cell proliferation and collagen deposition (lamination).

The wall of some vessels was characterised by inter- and intracellular oedema and multifocal vascular lumen occlusion. These changes were interpreted as the consequence of hypertension. In adjacent dermis and panniculus, elevated numbers of plump reactive fibroblasts and oedema were diffusely evident. The deep tissues, and tibial and carpal bones were all evaluated at different levels and no lesions were observed.

Follow-up was performed via email with the owner. The cat was clinically normal 3 years after the amputation, with no recurrence of the original lesion or incidence of metastatic disease.

A diagnosis of acquired iatrogenic peripheral AVF was supported by: (1) a history of intravenous cephalic vein catheterisation 15 days prior to the development of a cutaneous and vascular lesion in the same geographical area; (2) ultrasound evidence of abnormal sinusoidal branching vessels with turbulent high-velocity flow spectrum at the confluence of the artery and vein, and



**Figure 4** Cat, haired skin: mid-to-deep dermis. Abnormal increase of vessels characterised by multifocal mural necrosis, micro-haemorrhage, fibrinoid-to-leukocytoclastic vasculitis and variably occluded by fibrin thrombi. Haematoxylin and eosin stain

high-velocity arterialisated flow in the vein in the affected limb; (3) histological findings of the lesion pre- and post-limb amputation; and (4) complete resolution of disease following excision.

## Discussion

AVF is an uncommon vascular proliferation derived from the abnormal direct connection between an artery and an adjacent vein circumventing the terminal capillary circulation. In humans, AVFs are generally classified as either congenital or acquired according to their origin, and as either cardiac or extracardiac (peripheral) according to their site of development.<sup>1,2</sup>

Congenital AVFs result from the persistence of the embryological communication between arteries and veins, while acquired AVFs are not present at birth and are due to pathological events (eg, trauma, vascular inflammation, aneurysm rupture) or iatrogenic procedures (eg, haemodialysis). Cardiac congenital AVFs are linked to a defect of atrial and ventricular septa. Extracardiac congenital AVFs at several anatomical sites, including hepatic, ocular, auricular, spinal and peripheral vascular tissues systems, have been described in humans and animals.<sup>1–25</sup>

In veterinary medicine, most cases of AVF described are extracardiac and acquired, and have been described in dogs, cats and horses. Acquired AVFs are more frequently reported in the portal and peripheral circulation.<sup>1–8,12–24,26</sup>

Peripheral AVF of skin and subcutaneous tissues has been most commonly described following trauma (bites, blunt trauma, wounds) or tumour development.<sup>1,2,18–21</sup> The most frequent iatrogenic cause of AVF in human patients is the surgical anastomosis between an artery and a vein created as vascular access for haemodialysis. In veterinary medicine, underlying factors in AVF formation include venepuncture, catheterisation, injection of irritant medications, repeated blood collection in canine blood donors and surgery (eg, feline declawing).<sup>1,2,14,22</sup>

In the present case, AVF was classified as acquired and peripheral. The AVF developed 3 weeks after an iatrogenic procedure consisting of cephalic vein cannulation for general anaesthesia, and affected the dorsum of the right paw and interdigital spaces. This case closely resembles reports of AVF developing in human dialysis patients and, to our knowledge, is the first description of an AVF developing after venous catheterisation in a cat.

Acquired AVFs cause localised hypertension, volume overload and turbulent blood flow associated with the direct connection of arterial and venous flows. Shear stress activates vascular remodelling with development of a collateral circulation characterised by progressive increase of the number and size of anastomotic vessels.<sup>1,2,27</sup> The newly formed vessel network often provides an inadequate blood supply with additional abnormalities, including oedema, misshapen vessels and haemorrhage, with swelling of tissues distal to the AVF. Clinical signs are variable depending on location and severity of lesions.

Most common skin lesions in AVF-affected limbs are moderate-to-severe oedema, cyanosis and hypothermia of the area distal to the vascular abnormality. Often, crusts and ulcers are present, provoking lameness and pain. Sometimes a pulsating thrill associated with a continuous murmur can be detected in the AVF area. Furthermore, compression of the proximal artery may induce bradycardia (Nicoladoni–Israel–Branham sign).<sup>1,2,13,14,18</sup>

In the present case, the cat had no systemic signs and blood tests were unremarkable. Skin lesions, including swelling, non-healing ulcers and thick crusts on the dorsal aspect of the right paw and interdigital spaces, were highly suggestive of AVF. No lesions were observed on the ventral surface. Murmur was not detected at auscultation over the vascular anomaly and Nicoladoni–Israel–Branham sign was negative.

Diagnosis of AVF is based on traditional angiography with contrast media, fluoroscopic angiography, Doppler ultrasound, contrast-enhanced CT and MRI, and, recently, continuous-wave acoustic Doppler examination.<sup>12–14,17,21,23,24,27,28</sup>

In this cat, Doppler evaluation was preferred to invasive procedures (angiography/fluoroscopy) or to more expensive ones (CT and MRI) requiring general anaesthesia, to avoid additional catheterisation and owing to the owner's financial constraints. Ultrasound examination of the forelimb revealed irregular dilation of the cephalic vein with multiple abnormal sinusoidal neofomed branching vessels. Doppler ultrasound revealed a turbulent high-velocity flow spectrum at the confluence of the artery and vein, and high-velocity arterialised flow in the vein.

The differential diagnoses of AVF include vascular aberrations (angiomas, venous thrombosis, embolism, aneurysm), vascular tumours (angiosarcoma, haemangioma/haemangiosarcoma, lymphangioma/lymphangiosarcoma), inflammatory or infectious diseases (eg, crushing or penetrating wounds), lymphoedema, and Klippel-Trenaunay-like syndrome (vascular proliferation secondary to deep lymphatic hypoplasia). The only major differential diagnosis following gross clinical and microscopical findings was PA. PA is aggressive with progressive growth resulting in soft tissue destruction and phalangeal bone lysis. Histopathology is characterised by a central cavernous vessel surrounded by small, capillary-type vascular structures. In some cases, large- or medium-sized vessels invade dermis and subcutaneous tissue. Vessels may resemble capillaries or may be accompanied by smooth muscle and fibrous tissue, creating vascular structures that resemble small arterioles and veins. These latter lesions are referred to as arteriovenous angiomas.<sup>29</sup>

AVFs, as seen in our case, do not progress rapidly, do not invade deep tissues and are characterised by increased numbers of thin-walled and grouped, small vascular structures resembling venules and arterioles in superficial-to-deep dermis. Proliferation is associated with acute vessel injury (fibrinoid hyaline deposits, pyknotic nuclear fragments, vascular necrosis, haemorrhage, luminal thrombosis) but lack hard-tissue invasion.<sup>1,2</sup> The most common form of treatment of AVF in human medicine is endovascular embolisation, and only one case has been treated similarly in a cat. A catheter is inserted into an artery and guided by imaging towards the AVF site. Here, an embolic agent (eg, coils, glues, balloons) is injected to close the abnormal vascular connection. Embolisation can be unsuccessful owing to incomplete occlusion or complications (eg, bleeding, infection, allergic reactions). Another option, most common in veterinary medicine, is the surgical resection of AVF with or without vessel reconstruction. The type of surgery depends on the extension and location of AVF.<sup>12-18,20-24,30,31</sup>

Prognosis of AVF depends on the size and location of vessels involved. In the present case amputation was considered the optimal and resolute treatment option because of the location and the extent of the vascular damage, and the systemic signs (pain and lameness)

unresponsive to medical treatment. AVF excision with angioplasty or embolisation were considered not possible owing to the extensive vascular network.

## Conclusions

This case report describes an iatrogenic acquired peripheral AVF in a middle-aged cat following cephalic vein intravenous catheterisation. The diagnosis of AVF was well characterised by clinical findings, ultrasound imaging and histopathology. Treatment via amputation of the affected limb was curative.

**Conflict of interest** The authors declared no potential conflicts of interest with respect to the research, authorship, and/or publication of this article.

**Funding** The authors received no financial support for the research, authorship, and/or publication of this article.

**ORCID iD** Lisa Graziano  <https://orcid.org/0000-0001-7553-5120>

## References

- Ettinger SJ and Feldman EC. **Peripheral vascular diseases.** In: Textbook of veterinary internal medicine: diseases of the dog and cat. St Louis, MO: Elsevier Saunders, 2005, pp 1145–1165.
- Hosgood G. **Arteriovenous fistulas: pathophysiology, diagnosis, and treatment.** *Compend Contin Educ Pract Vet* 1989; 11: 625–636.
- Zwingenberger AL, McLear RC and Weisse C. **Diagnosis of arterioportal fistulae in four dogs using computed tomographic angiography.** *Vet Radiol Ultrasound* 2005; 46: 472–477.
- McConnell JF, Sparkes AH, Ladlow J, et al. **Ultrasonographic diagnosis of unusual portal vascular abnormalities in two cats.** *J Small Anim Pract* 2006; 47: 338–343.
- Legendre AM, Krahwinkel DJ, Carrig CB, et al. **Ascites associated with intrahepatic arteriovenous fistula in a cat.** *J Am Vet Med Assoc* 1976; 168: 589–591.
- Landers EA and Mitten RW. **Intrahepatic arteriovenous fistula with portosystemic communications: a case report.** *J Am Vet Radiol Soc* 1978; 19: 70. DOI: 10.1111/j.1740-8261.1978.tb01143.x.
- Easley JC and Carpenter JL. **Hepatic arteriovenous fistula in two Saint Bernard pups.** *J Am Vet Med Assoc* 1975; 66: 167–171.
- Rogers WA, Suter PF, Breznock EM, et al. **Intrahepatic arteriovenous fistulae in a dog resulting in portal hypertension, portocaval shunts and reversal of portal blood flow.** *J Am Anim Hosp Assoc* 1977; 13: 470–475.
- Rubin LF and Patterson DF. **Arteriovenous fistula of the orbit in a dog.** *Cornell Vet* 1965; 55: 471–481.
- Kealy JK, Lucey M and Rhodes WH. **Arteriovenous fistula in the ear of a dog: a case report.** *J Am Vet Radiol Soc* 1970; 11: 15–20.
- Morabito S, Auriemma E, Zagarella P, et al. **Computed tomographic and angiographic assessment of spinal extradural arteriovenous fistulas in a dog.** *Can Vet J* 2017; 58: 275–279.

- 12 Ettinger S, Campbell L, Suter PF, et al. **Peripheral arteriovenous fistula in a dog.** *J Am Vet Med Assoc* 1968; 153: 1055–1058.
- 13 Slocum B, Colgrove D, Carrig CB, et al. **Acquired arteriovenous fistula in two cats.** *J Am Vet Med Assoc* 1973; 162: 271–275.
- 14 Furneaux RW, Pharr JW and McManus JL. **Arteriovenous fistulation following dewclaw removal in a cat.** *J Am Anim Hosp Assoc* 1974; 10: 569–573.
- 15 Butterfield AB, Hix WR, Pickler JC, et al. **Acquired peripheral arteriovenous fistula in a dog.** *J Am Vet Med Assoc* 1980; 176: 445–448.
- 16 Jones DGC, Allen WE and Webbon PM. **Arteriovenous fistula in the metatarsal pad of a dog: case report.** *J Small Anim Pract* 1981; 22: 635–639.
- 17 Harari J, MacCoy DM, Johnson AL, et al. **Recurrent peripheral arteriovenous fistula and hyperthyroidism in a cat.** *J Am Anim Hosp Assoc* 1984; 20: 759–754.
- 18 Bouayard H, Feeney DA, Lipowitz AJ, et al. **Peripheral acquired arteriovenous fistula: a report of four cases and literature review.** *J Am Anim Hosp Assoc* 1987; 23: 205–211.
- 19 Parks AH, Guy BL, Rawlings CA, et al. **Lameness in a mare with signs of arteriovenous fistula.** *J Am Vet Med Assoc* 1989; 194: 379–380.
- 20 Welch RD, Dean PW and Miller MW. **Pulsed spectral Doppler evaluation of a peripheral arteriovenous fistula in a horse.** *J Am Vet Med Assoc* 1992; 200: 1360–1362.
- 21 Lewis DC and Harari J. **Peripheral arteriovenous fistula associated with a subcutaneous hemangiosarcoma/hemangioma in a cat.** *Feline Pract* 1992; 20: 27–29.
- 22 Aiken SW, Jakovljevic S, Lantz GC, et al. **Acquired arteriovenous fistula secondary to castration in a dog.** *J Am Vet Med Assoc* 1993; 202: 965–967.
- 23 Tobias KM, Cambridge A and Gavin P. **Cyanoacrylate occlusion and resection of an arteriovenous fistula in a cat.** *J Am Vet Med Assoc* 2001; 219: 785–788.
- 24 Santoro D, Pease A, Linder KE, et al. **Post-traumatic peripheral arteriovenous fistula manifesting as digital haemorrhages in a cat: diagnosis with contrast-enhanced 3D CT imaging.** *Vet Dermatol* 2009; 20: 206–213.
- 25 Allon M, Imrey PB, Cheung AK, et al. **Relationships between clinical processes and arteriovenous fistula cannulation and maturation: a multicenter prospective cohort study.** *Am J Kidney Dis* 2018; 71: 677–689.
- 26 Oliver NB. **Pathophysiology or arteriovenous fistulae.** In: Slatter DH (ed). *Textbook of small animal surgery*. Philadelphia, PA: WB Saunders, 1985, pp 1051–1054.
- 27 Hernandez J. **Successful diagnosis and treatment of a pelvic limb arteriovenous fistula in a cat.** *Rev Med Vet* 2018; 169: 24–29.
- 28 Miller-Thomas MM, West OC and Cohen AM. **Diagnosing traumatic arterial injury in the extremities with CT angiography: pearls and pitfalls.** *Radiographics* 2005; 25: S133–S142.
- 29 Gross TL, Ihrke PJ, Walder EJ, et al. **Vascular tumours.** In: *Skin diseases of the dog and cat: clinical and histopathologic diagnosis*. 2nd ed. Oxford: Blackwell Publishing, 2005, pp 735–758.
- 30 Ford EG, Stanley P, Tolo V, et al. **Peripheral congenital arteriovenous fistulae: observe, operate, or obturate?** *J Pediatr Surg* 1992; 27: 714–719.
- 31 White RL, Pollak J, Persing J, et al. **Long-term outcome of embolotherapy and surgery for high-flow extremity arteriovenous malformations.** *J Vasc Interv Radiol* 2000; 11: 1285–1295.