



## **Colonic malignant peripheral nerve sheath tumour in a cat**

Authors: Boland, Lara, Setyo, Laura, Sangster, Cheryl, Brunel, Laurencie, Foo, Timothy, et al.

Source: Journal of Feline Medicine and Surgery Open Reports, 5(1)

Published By: SAGE Publishing

URL: <https://doi.org/10.1177/2055116919849979>

---

BioOne Complete ([complete.BioOne.org](https://complete.BioOne.org)) is a full-text database of 200 subscribed and open-access titles in the biological, ecological, and environmental sciences published by nonprofit societies, associations, museums, institutions, and presses.

Your use of this PDF, the BioOne Complete website, and all posted and associated content indicates your acceptance of BioOne's Terms of Use, available at [www.bioone.org/terms-of-use](https://www.bioone.org/terms-of-use).

Usage of BioOne Complete content is strictly limited to personal, educational, and non - commercial use. Commercial inquiries or rights and permissions requests should be directed to the individual publisher as copyright holder.

---

BioOne sees sustainable scholarly publishing as an inherently collaborative enterprise connecting authors, nonprofit publishers, academic institutions, research libraries, and research funders in the common goal of maximizing access to critical research.



# Colonic malignant peripheral nerve sheath tumour in a cat

Lara Boland<sup>1</sup>, Laura Setyo<sup>2</sup>, Cheryl Sangster<sup>2</sup>,  
Laurencie Brunel<sup>1</sup>, Timothy Foo<sup>1</sup> and Peter Bennett<sup>1</sup>

*Journal of Feline Medicine and Surgery Open Reports*  
1–8

© The Author(s) 2019

Article reuse guidelines:

sagepub.com/journals-permissions

DOI: 10.1177/2055116919849979

journals.sagepub.com/home/jfmsopenreports

This paper was handled and processed by the European Editorial Office (ISFM) for publication in *JFMS Open Reports*



## Abstract

**Case summary** A 14-year-old male neutered domestic mediumhair cat presented with a 4 month history of inappetence and weight loss. Pertinent abnormalities on haematology and biochemistry included a mild microcytic regenerative anaemia (packed cell volume [PCV] 24% [reference interval (RI) 30–45%], mean cell volume 30.8 fl [RI 40–45 fl], absolute reticulocyte count  $326.8 \times 10^{12}$ ) and increased alkaline phosphatase activity (76 IU/l; RI <50 IU/l). Abdominal ultrasound and CT scan revealed masses in the transverse colon (2.0 cm × 1.2 cm) and right medial liver lobe (5.0 cm diameter). Thoracic radiographs were unremarkable. Right medial liver lobe resection and colectomy were performed. Immunohistochemistry was positive for S-100 protein, vimentin and glial fibrillary acidic protein, very weakly positive for c-kit and negative for muscle-specific actin and CD18, consistent with a colonic malignant peripheral nerve sheath tumour (MPNST) with a hepatic metastasis. Postoperative treatment with metronomic cyclophosphamide was well tolerated. Eighteen months postoperatively the cat re-presented after 3 days of progressive lethargy and inappetence. Haematology revealed a marked non- or pre-regenerative anaemia (PCV 10%). Coagulation times were prolonged (prothrombin time 39 s [RI 15–22 s] and activated partial thromboplastin time >300 s [RI 65–119 s]). Abdominal ultrasound identified multiple renal and hepatic nodules. Euthanasia was performed and post-mortem examination confirmed metastasis of the MPNST.

**Relevance and novel information** This report describes the treatment of a metastatic colonic peripheral nerve sheath tumour in a cat. Feline visceral MPNSTs are rare and little is known about prognosis or optimal treatment.

**Keywords:** Peripheral nerve sheath tumour; metastasis; metronomic chemotherapy; cyclophosphamide

**Accepted:** 11 April 2019

## Introduction

Peripheral nerve sheath tumours (PNSTs) are neoplasms originating from Schwann cells, perineural cells and intraneural fibroblasts. Sub-classifications are used in human medicine (eg, Schwannoma, neurofibroma); however, owing to unclear histogenesis, in veterinary medicine they are usually divided into benign or malignant (MPNST).<sup>1–3</sup> Feline PNSTs are uncommonly reported, usually occur in older cats, are mostly benign and usually involve the skin/subcutis of the head, neck and limbs.<sup>1,4–11</sup> MPNSTs involving the spinal cord/canal are uncommonly reported and rarely reported sites include the gingiva, eye, small intestine and bladder, or are perirenal.<sup>12–20</sup> Approximately 15% of benign and 30% of malignant feline dermal/subcutaneous PNSTs recur locally.<sup>1</sup> Metastatic disease is rarely reported.<sup>17</sup> Surgical

resection may be curative; however, there are few reports of postoperative follow-up or treatment of incompletely resected or metastatic feline MPNSTs.<sup>1,12–14,17,21</sup> Strontium plesiotherapy following marginal resection of feline eyelid MPNSTs has been described.<sup>21</sup>

<sup>1</sup>Valentine Charlton Cat Centre, Sydney School of Veterinary Science, Faculty of Science, University of Sydney, NSW, Australia

<sup>2</sup>Veterinary Pathology Diagnostic Services, Sydney School of Veterinary Science, Faculty of Science, University of Sydney, NSW, Australia

### Corresponding author:

Lara Boland BVSc, DipECVIM-CA, FANZCVS (feline medicine), Valentine Charlton Cat Centre, Faculty of Science, Sydney School of Veterinary Science, University of Sydney, Evelyn Williams Building B10, NSW 2006, Australia  
Email: lara.boland@sydney.edu.au



Creative Commons Non Commercial CC BY-NC: This article is distributed under the terms of the Creative Commons

Attribution-NonCommercial 4.0 License (<http://www.creativecommons.org/licenses/by-nc/4.0/>) which permits non-commercial use, reproduction and distribution of the work without further permission provided the original work is attributed as specified on the SAGE and Open Access pages (<https://us.sagepub.com/en-us/nam/open-access-at-sage>).

This report describes the presentation, diagnosis, treatment and outcome of a colonic MPNST with hepatic metastasis in a cat. To our knowledge, this is the second case report of an intestinal MPNST and the second of PNST metastases in a cat.<sup>12,17</sup>

### Case description

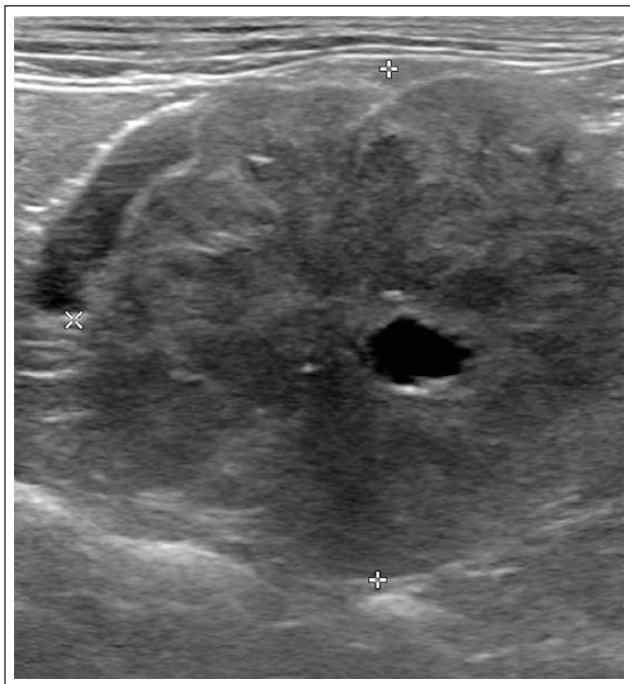
A 14-year-old male neutered domestic mediumhair cat was referred for investigation of 4 months of inappetence and 1.2 kg weight loss. Diabetes mellitus

had been diagnosed 2 years earlier and was well managed with insulin glargine (Lantus; Sanofi) with doses up to 4 IU subcutaneously (SC) q12h and a high-protein/low-carbohydrate diet (Hill's m/d; Hill's Pet Nutrition). In the month prior to referral the insulin dose had been reduced to 2 IU SC q12h based on blood glucose curves.

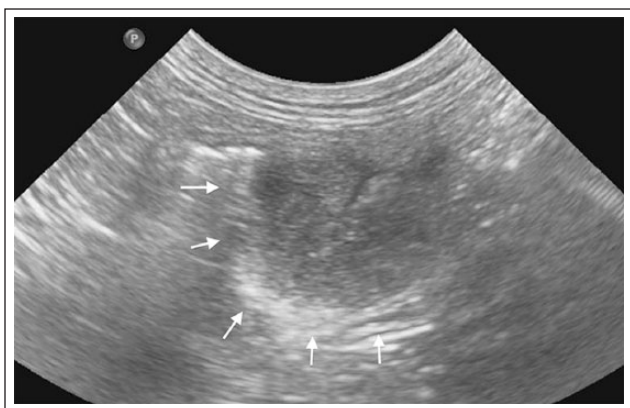
Physical examination revealed a low body condition score (3/9) and a grade II/VI left systolic cardiac murmur. Pertinent abnormalities on haematology and biochemistry included a mild microcytic regenerative anaemia (packed cell volume [PCV] 24% [reference interval (RI) 30–45%], mean cell volume 30.8 fl [RI 40–45 fl], absolute reticulocyte count  $326.8 \times 10^{12}$ ), mild neutrophilia ( $15.35 \times 10^9/l$ ; RI  $3.76\text{--}10.08 \times 10^9/l$ ) and increased alkaline phosphatase activity (76 IU/l; RI <50 IU/l). Urinalysis was unremarkable.

Abnormalities identified on abdominal ultrasound included a 5.0 cm diameter, large, heterogeneous and poorly vascularised mass within the right medial lobe of the liver, which was fluid-filled centrally (Figure 1), and an eccentrically located, intramural (2.0 cm  $\times$  1.4 cm) hypoechoic mass within the distal portion of the transverse colon with loss of normal wall layering (Figure 2). Thoracic radiographs were unremarkable.

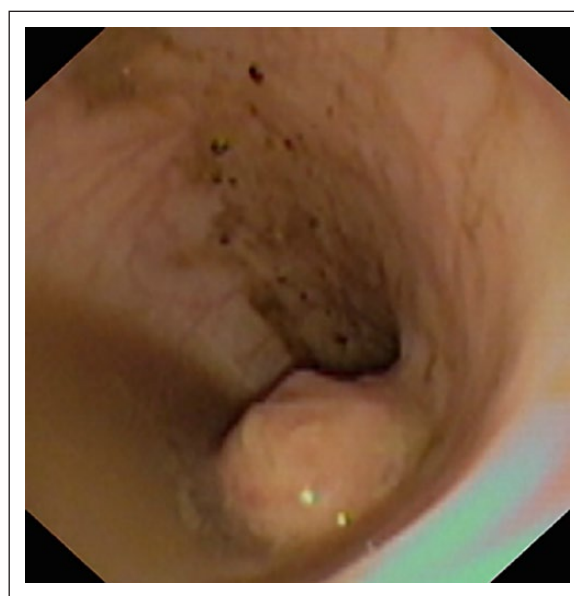
Fine-needle aspirate cytology of the masses was non-diagnostic. Coagulation times were within the RIs. The cardiac murmur was not investigated owing to financial constraints. Colonoscopy revealed a smooth, raised mass in the transverse colon and biopsies were collected (Figure 3). An ultrasound-guided liver mass biopsy (Vet-Core biopsy needle 16 G 9 cm; Smiths Medical USA) was performed and an oesophageal feeding tube was placed.



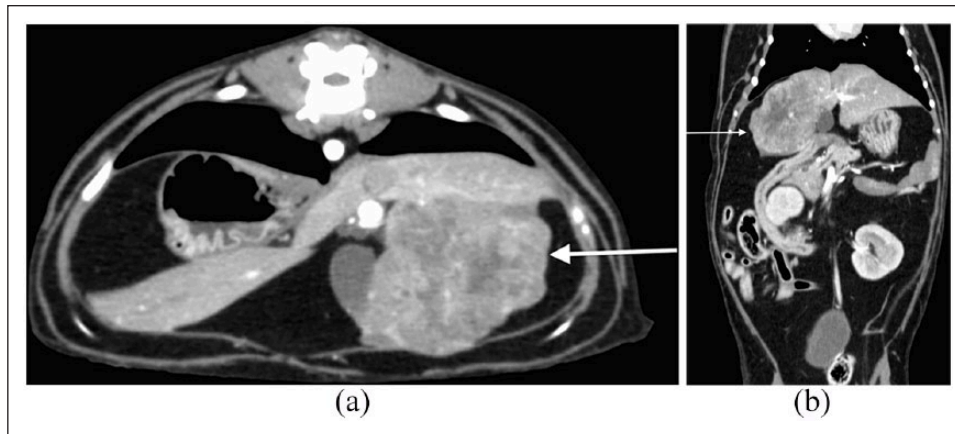
**Figure 1** Transverse sonogram (Phillips EPIQ5; Phillips Medical Systems) of the right medial liver lobe. There was a large, heterogeneous mass (outlined by callipers) containing a central fluid-filled component



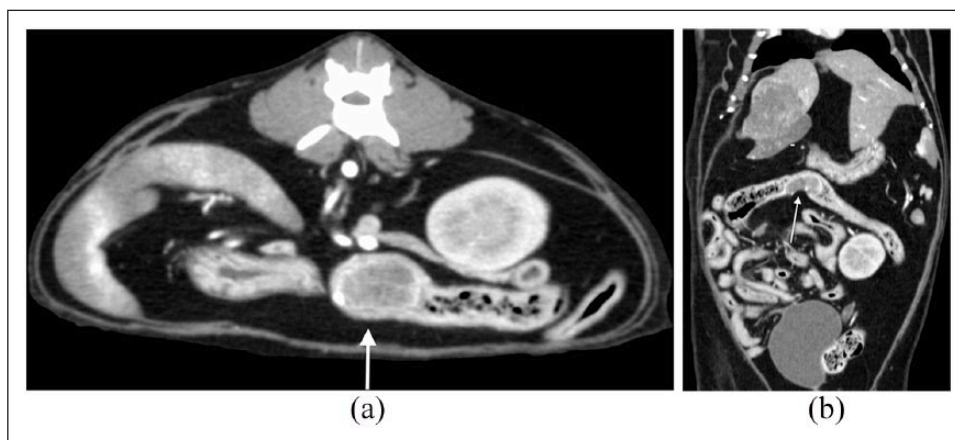
**Figure 2** Longitudinal sonogram of the transverse colon. There was an eccentric, intramural hypoechoic mass within the distal portion of the transverse colon. Note the displacement of the intraluminal gas interface by this lesion (arrows)



**Figure 3** Colonoscopy revealed a smooth, raised mass in the transverse colon



**Figure 4** CT images of the (a) transverse and (b) dorsal planes of the abdomen displayed in a soft tissue window. The patient's right is to the left. There was a large heterogeneous hepatic mass within the right medial lobe (arrows). Note the heterogeneous post-contrast enhancement of the mass with multiple coalescing non-enhancing regions suggestive of necrosis. Images obtained with a 16-detector row CT scanner (Phillips 16-slice Brilliance CT V2.3; Phillips Medical Systems [120 kVp, 100 mAs, 1.5 mm slice thickness])



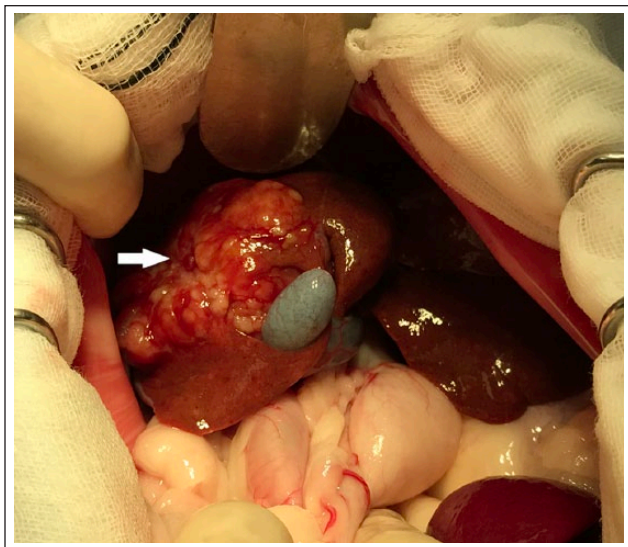
**Figure 5** CT images of the (a) transverse and (b) dorsal planes of the abdomen displayed in a soft tissue window. The patient's right is to the left. There is an intramural hypoechoic mass within the transverse colon (arrows). Note the heterogeneous, predominantly peripheral contrast enhancement of the mass.

Histopathology of the colonic and hepatic masses revealed disorganised large pale pleomorphic spindle cells with prominent nucleoli. The colonic mass was suspected to be a primary spindle cell sarcoma with the liver mass representing a metastasis.

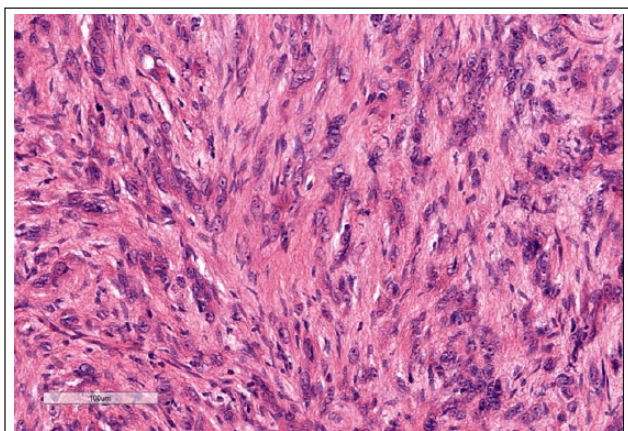
Pre- and post-contrast enhanced CT of the abdomen was performed for tumour staging and surgical planning. A heterogeneous soft tissue-attenuating 4.3 cm mass was noted within the right medial lobe of the liver (Figure 4). This mass was heterogeneously enhancing post-contrast administration with multiple, coalescing non-contrast-enhancing areas suggestive of necrosis. Within the transverse colon, there was a hypoattenuating mass (2.4 cm × 1.4 cm × 0.6 cm) with heterogeneous, predominantly peripheral enhancement post-contrast administration (Figure 5).

Laparotomy was performed under general anaesthesia. The hepatic mass was separated from the gall bladder by blunt dissection and right medial and quadrate liver lobe resection performed because of shared vasculature (Figure 6). The rest of the liver had a diffusely mottled appearance and a 6 mm punch biopsy was collected from the left medial lobe. The colonic mass was identified at the hepatic flexure of the colon and removed by colectomy and anastomosis. Postoperative analgesia was provided by a fentanyl continuous rate infusion (5 µg/kg/h for 48 h) followed by buprenorphine (0.015 mg/kg IV q8h for 24h) and then 0.02 mg/kg sublingually for another 48 h.

The feeding tube was removed after 2 weeks. Postoperative medications included: amoxicillin-clavulanate (Augmentin; GlaxoSmithKline) 20 mg/kg



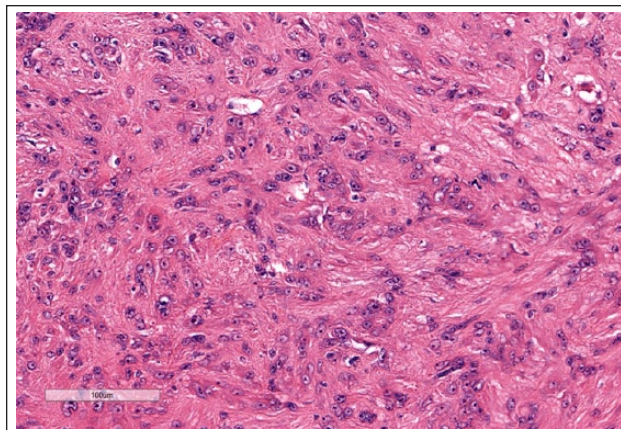
**Figure 6** Intraoperative image of the right medial liver lobe mass (arrow) adjacent to the gall bladder



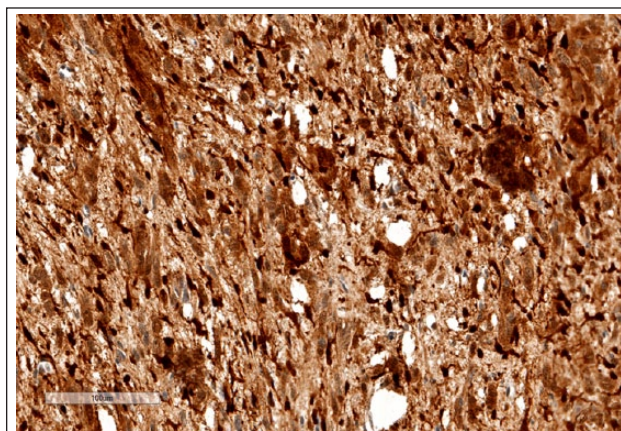
**Figure 7** Colonic mass. Neoplastic cells are arranged in interlacing streams and bundles. Haematoxylin and eosin ( $\times 400$ )

intravenously (IV) q8h for 48 h then orally (PO) for 7 days; metronidazole (Metronidazole Sandoz IV; Sandoz) 10 mg/kg IV q12h for 48 h then PO for 7 days; enrofloxacin (Baytril; Bayer) 2.5 mg/kg SC q12h for 48 h then PO for 7 days; maropitant (Cerenia; Zoetis) 1 mg/kg SC q24h for 48 h then PO for 5 days; and insulin glargine 1 IU SC q12h.

Histopathology of the colonic mass (Figure 7) revealed a poorly circumscribed, unencapsulated, well-demarcated, densely cellular, infiltrative neoplasm composed of spindle cells arranged in interlacing streams and bundles separated by a scant eosinophilic fibrillary matrix that was transmurally infiltrating and effacing the mucosa, lamina propria, submucosa, tunica muscularis and serosa, and extending into the colonic lumen. Neoplastic cells had variably distinct cell borders,




**Figure 8** Hepatic mass. Neoplastic cells demonstrate similar behaviour to the colonic mass (Figure 7). Note the marked anisocytosis and anisokaryosis. Haematoxylin and eosin ( $\times 400$ )



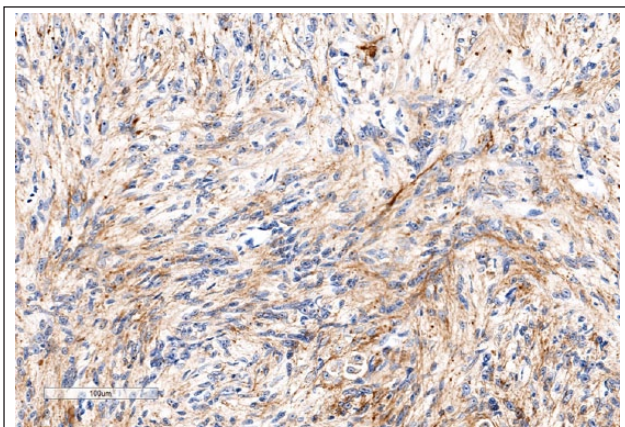
**Figure 9** Colonic mass. Neoplastic cells demonstrate diffuse marked nuclear and cytoplasmic labelling for S-100. Peroxidase immunohistochemistry and haematoxylin and eosin ( $\times 400$ )

moderate-to-abundant eosinophilic fibrillar cytoplasm, oval-to-elongated nuclei containing finely stippled chromatin and generally one distinct nucleolus. The mitotic rate averaged one per 10 high-powered fields. There was marked anisocytosis and anisokaryosis. In addition, there was scattered necrosis and lymphoplasmacytic aggregates. The mass appeared to have been completely excised. Similar neoplastic infiltrates admixed with scattered single-cell necrosis infiltrated and replaced the architecture of the right medial liver lobe (Figure 8).

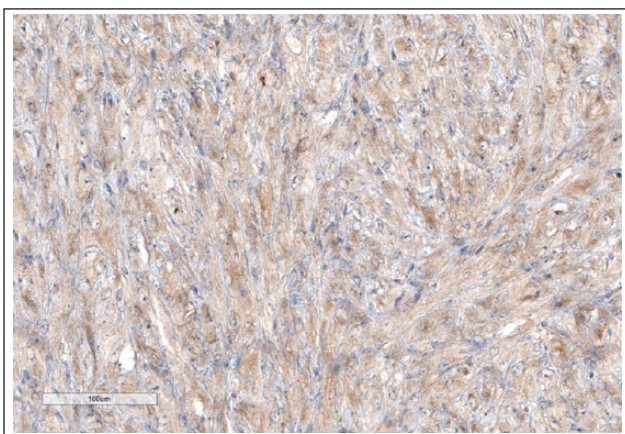
The cat was diagnosed with a colonic malignant spindle-cell neoplasm with hepatic metastasis. Immunohistochemistry revealed that both masses stained positive for S-100 protein, vimentin and glial fibrillary acidic protein, very weakly positive for c-kit and negative for muscle-specific actin and CD18, consistent with a diagnosis of a MPNST (Figures 9–12).<sup>1,8,22–24</sup>



**Figure 10** Colonic mass. Neoplastic cells demonstrate diffuse marked cytoplasmic labelling for vimentin. Peroxidase immunohistochemistry and haematoxylin and eosin ( $\times 400$ )



**Figure 11** Hepatic mass. Neoplastic cells demonstrate diffuse marked cytoplasmic labelling for glial fibrillary acidic protein. Peroxidase immunohistochemistry and haematoxylin and eosin ( $\times 400$ )



**Figure 12** Colonic mass. Neoplastic cells demonstrate scattered faintly positive cytoplasmic labelling for c-kit. Peroxidase immunohistochemistry and haematoxylin and eosin ( $\times 400$ )

Metronomic chemotherapy was commenced 2 weeks postoperatively with cyclophosphamide 15.5 mg/m<sup>2</sup> PO q24h. Cyclophosphamide was well tolerated long term. Intermittent vomiting occurred and was treated with maropitant 1.5 mg/kg PO q24h and omeprazole (Losec; AstraZeneca) 1.5 mg/kg PO q24h as required. Haematology performed at 1, 2, 3 and 5 months revealed microcytosis for 3 months before resolution. Insulin glargine was increased to 3 IU SC q12h by 5 months postoperatively, based on blood glucose curves performed every 1–2 months. The cat gained 200 g following surgery and maintained a stable body weight.

Sixteen months postoperatively, the cat was re-presented to the referring veterinarian for polyuria and polydipsia. Fructosamine indicated over-control of diabetes mellitus (203  $\mu$ mol/l; RI 221–340  $\mu$ mol/l), hyperthyroidism was diagnosed (total thyroxine 92 nmol/l; RI 10–60 nmol/l), and pertinent abnormalities on haematology and biochemistry included a mild anaemia (haematocrit 24%; RI 30–52%) and increased alanine aminotransferase activity (138 IU/l; RI 12–130 IU/l). The insulin dose was reduced to 2 IU SC q12h and methimazole transdermal gel 5 mg q12h was commenced.

Eighteen months postoperatively the cat re-presented following 3 days of progressive lethargy and inappetence. Physical examination revealed 100 g of weight loss, marked lethargy, pallor, a right-sided goitre and a grade II/VI left systolic cardiac murmur. Haematology revealed a marked non- or pre-regenerative anaemia (PCV 10%). Coagulation times were prolonged (prothrombin time 39 s [RI 15–22 s] and activated partial thromboplastin time >300 s [RI 65–119 s]). Abdominal ultrasound identified multiple renal and hepatic nodules (Figure 13 in the supplementary material). Thoracic radiographs were unremarkable. Retroviral testing was negative (Witness FIV-FelV; Zoetis). The owner elected euthanasia. Post-mortem examination, including renal immunohistochemistry, confirmed the presence of an MPNST within the kidneys and liver (Figures 14–21 in the supplementary material). Additional findings of note observed incidentally on gross and microscopic post-mortem examination included thyroid cystic follicular adenomas, cardiac fibrosis and islet amyloidosis.

## Discussion

Ribas et al reported a small intestinal MPNST, without metastasis, in a cat that was treated with surgical resection and that was clinically well 6 months postoperatively.<sup>12</sup> Buza et al reported a partially resected gingival MPNST in a cat that developed local recurrence and post-mortem examination identified nodal and pulmonary metastases after an 8.5 month survival time.<sup>17</sup> Pavia et al described a urinary bladder MPNST in a cat that died several weeks after partial cystectomy.<sup>13</sup> The case reported here is unique in that the cat was treated with

surgical resection of the primary tumour and hepatic metastasis, received postoperative metronomic chemotherapy and had a prolonged survival time.

MPNSTs in humans are rare and half occur in people with neurofibromatosis type 1, an autosomal dominant disorder.<sup>2,25,26</sup> Treatment focuses on surgical resection with the role of postoperative radiation and chemotherapy less well defined.<sup>25</sup>

Most MPNST in dogs arise from spinal nerves and nerve roots of the brachial plexus or, less commonly, from the trigeminal nerve or skin.<sup>21,27,28</sup> Rarely reported sites of origin include the lung, spleen, liver, diaphragm, vagus nerve, tongue, omentum, ocular origin, heart, brain, adrenal gland and testis.<sup>22,29–50</sup> Incomplete surgical resection leads to recurrence and metastatic disease is rarely reported.<sup>22,24,39,43,44,46,47,49–52</sup> Stereotactic radiation therapy for canine trigeminal and brachial plexus MPNSTs may prolong survival times when surgical resection is not possible.<sup>28,53</sup> Metronomic cyclophosphamide and piroxicam treatment delays recurrence in dogs with incompletely resected MPNST.<sup>49,54</sup> Cryosurgery of small canine dermal MPNSTs has been reported.<sup>55</sup> Immunotherapy with interleukin-2 following marginal surgical resection did not prolong survival times in dogs.<sup>52</sup>

The major initial differential diagnoses in the case reported here were a leiomyosarcoma or gastrointestinal stromal cell tumour (GIST), which are uncommon to rare in cats, respectively.<sup>56,57</sup> The immunohistochemistry was consistent with a PNST, which are usually S-100 protein and vimentin positive, muscle-specific actin negative and most are glial fibrillary acidic protein positive.<sup>1</sup> The neoplasm also stained weakly positive for c-kit; however, a GIST was excluded given the positive S-100 protein and the unconvincing nature of the c-kit staining.<sup>57</sup>

The colonic mass was presumed to be the primary tumour with hepatic metastasis. Given that surgical resection was unlikely to be curative, metronomic cyclophosphamide was used. Conventional chemotherapy for feline MPNSTs has not been reported. Metronomic cyclophosphamide rather than intravenous doxorubicin was chosen owing to financial constraints, potential side effects and stress to the cat, along with a lack of information on efficacy for either doxorubicin or metronomic chemotherapy. Use of metronomic cyclophosphamide for various feline tumour types, including soft tissue sarcomas, has been reported and well tolerated; however, there is scarce information about tumour response rates.<sup>58</sup> Conclusions cannot be drawn about what impact metronomic chemotherapy had on the survival time of this cat.

The prognostic significance of distant metastases at the time of diagnosis is unclear for cats with MPNSTs owing to limited publications. Resection of both GIST and non-GIST sarcoma hepatic metastases in selected

human patients is associated with improved survival times.<sup>59,60</sup> Similar data are not available for companion animals and conclusions cannot be drawn about what impact the hepatic mass resection had on the survival time of this cat.

## Conclusions

Visceral MPNSTs are rarely reported in cats and little is known about prognosis or optimal treatment. This report describes a colonic MPNST with hepatic metastasis that was treated with surgical resection and metronomic cyclophosphamide. An 18 month survival time was achieved before the development of clinically significant disease secondary to tumour recurrence.

**Acknowledgements** The authors would like to thank the cat's owner, staff and students of the Valentine Charlton Cat Centre, and Summer Hill Village Vet for provision of follow-up information.

## Supplementary material

The following files are available:

Figure 13: Longitudinal sonogram of the right kidney 18 months postoperatively showing a rounded (7.3 mm long × 7.7 mm thick), heterogeneously hypoechoic nodule present in the caudal cortex of the right kidney.

Figure 14: Photograph of the right kidney upon post-mortem examination, with an off-white multilobulated irregular mass protruding from the kidney that extends through the cortex on section.

Figure 15: Photograph of the left kidney upon post-mortem examination, with a loss of reniform appearance, and blunting of the left cranial aspect by a smooth pale-tan focus.

Figure 16: Photograph of the liver upon post-mortem examination, with numerous pale-tan firm nodules peppered across the hepatic serosa.

Figure 17: Histopathology of the renal mass upon post-mortem examination, with neoplastic cells demonstrating similar behaviour to the colonic mass (Figure 7), and marked anisocytosis and anisokaryosis.

Figure 18: Immunohistochemistry of the renal mass upon post-mortem examination, with neoplastic cells demonstrating diffuse marked nuclear and cytoplasmic labelling for S-100.

Figure 19: Immunohistochemistry of the renal mass upon post-mortem examination, with neoplastic cells demonstrating diffuse marked cytoplasmic labelling for vimentin.

Figure 20: Immunohistochemistry of the renal mass upon post-mortem examination, with neoplastic cells demonstrating scattered faintly positive cytoplasmic labelling for c-kit.

Figure 21: Immunohistochemistry of the renal mass upon post-mortem examination, with neoplastic cells demonstrating diffuse marked cytoplasmic labelling for glial fibrillary acidic protein.

**Conflict of interest** The authors declared no potential conflicts of interest with respect to the research, authorship, and/or publication of this article.

**Funding** The authors received no financial support for the research, authorship, and/or publication of this article.

**ORCID iD** Peter Bennett  <https://orcid.org/0000-0002-7209-4996>

## References

- Schulman FY, Johnson TO, Facemire PR, et al. **Feline peripheral nerve sheath tumors: histologic, immunohistochemical, and clinicopathologic correlation (59 tumors in 53 cats).** *Vet Pathol* 2009; 46: 1166–1180.
- Rodriguez FJ, Folpe AL, Giannini C, et al. **Pathology of peripheral nerve sheath tumors: diagnostic overview and update on selected diagnostic problems.** *Acta Neuropathol* 2012; 123: 295–319.
- Stoll A, Suárez-Bonnet A, Summers B, et al. **Malignant cutaneous peripheral nerve sheath tumour with rhabdomyosarcomatous differentiation (Triton tumour) in a domestic cat.** *J Comp Pathol* 2018; 165: 1–5.
- Hoffman A, Blocker T, Dubielzig R, et al. **Feline periocular peripheral nerve sheath tumor: a case series.** *Vet Ophthalmol* 2005; 8: 153–158.
- Newkirk KM and Rohrbach BW. **A retrospective study of eyelid tumors from 43 cats.** *Vet Pathol* 2009; 46: 916–927.
- Watrous BJ, Lipscomb TP, Heidel JR, et al. **Malignant peripheral nerve sheath tumor in a cat.** *Vet Radiol Ultrasound* 1999; 40: 638–640.
- Jones B, Alley M, Johnstone A, et al. **Nerve sheath tumours in the dog and cat.** *N Z Vet J* 1995; 43: 190–196.
- Mandara MT, Fabriani E, Pavone S, et al. **Feline cutaneous nerve sheath tumours: histological features and immunohistochemical evaluations.** *Res Vet Sci* 2013; 95: 548–555.
- de Cecco BS, da Silva TM, Felin DV, et al. **Malignant peripheral nerve sheath tumor in a cat: cytological, histopathological, and immunohistochemical aspects.** *Comp Clin Pathol* 2018; 27: 803–806.
- Tremblay N, Lanevski A, Doré M, et al. **Of all the nerve! A subcutaneous forelimb mass on a cat.** *Vet Clin Pathol* 2005; 34: 417–420.
- Dillon CJ, Mauldin GN and Baer KE. **Outcome following surgical removal of nonvisceral soft tissue sarcomas in cats: 42 cases (1992–2000).** *J Am Vet Med Assoc* 2005; 227: 1955–1957.
- Ribas A, Miller R and Rasotto R. **Small intestinal peripheral nerve sheath tumour in a cat.** *JFMS Open Rep* 2017; 3. DOI: 10.1177/2055116917710394.
- Pavia P, Havig M, Donovan T, et al. **Malignant peripheral nerve sheath tumour of the urinary bladder in a cat.** *J Small Anim Pract* 2012; 53: 245–248.
- Okada M, Kitagawa M, Shibuya H, et al. **Malignant peripheral nerve sheath tumor arising from the spinal canal in a cat.** *J Vet Med Sci* 2007; 69: 683–686.
- Stoica G, Tasca S and Kim H-T. **Point mutation of neu oncogene in animal peripheral nerve sheath tumors.** *Vet Pathol* 2001; 38: 679–688.
- Boonsriroj H, Kimitsuki K, Akagi T, et al. **Malignant epithelioid schwannoma of the oral cavity in a cat.** *J Vet Med Sci* 2014; 76: 927–930.
- Buza EL, Menzies RA, Goldschmidt MH, et al. **Malignant peripheral nerve sheath tumor in a cat with nodal and pulmonary metastases.** *J Vet Diagn Invest* 2012; 24: 781–784.
- Evans PM, Lynch GL and Dubielzig RR. **Anterior uveal spindle cell tumor in a cat.** *Vet Ophthalmol* 2010; 13: 387–390.
- Marioni-Henry K, Van Winkle TJ, Smith SH, et al. **Tumors affecting the spinal cord of cats: 85 cases (1980–2005).** *J Am Vet Med Assoc* 2008; 232: 237–243.
- Rossmesl JH, Jr, Lanz O, Waldron D, et al. **Surgical cytoreduction for the treatment of non-lymphoid vertebral and spinal cord neoplasms in cats: retrospective evaluation of 26 cases (1990–2005).** *Vet Comp Oncol* 2006; 4: 41–50.
- Berlato D, Serras AR, Riera MM, et al. **Marginal resection and adjuvant strontium plesiotherapy in the management of feline eyelid malignant peripheral nerve sheath tumours: two cases.** *JFMS Open Rep* 2016; 2. DOI: 10.1177/2055116916674863.
- Suzuki S, Uchida K and Nakayama H. **The effects of tumor location on diagnostic criteria for canine malignant peripheral nerve sheath tumors (MPNSTs) and the markers for distinction between canine MPNSTs and canine perivascular wall tumors.** *Vet Pathol* 2014; 51: 722–736.
- Sirri R, Sabattini S, Bettini G, et al. **Reclassification of 21 presumptive canine peripheral nerve sheath tumors (PNST) using a literature-based immunohistochemical panel.** *Acta Vet* 2016; 66: 455–465.
- Chijiwa K, Uchida K and Tateyama S. **Immunohistochemical evaluation of canine peripheral nerve sheath tumors and other soft tissue sarcomas.** *Vet Pathol* 2004; 41: 307–318.
- Kim A, Stewart DR, Reilly KM, et al. **Malignant peripheral nerve sheath tumors state of the science: leveraging clinical and biological insights into effective therapies.** *Sarcoma* 2017; 2017. DOI: 10.1155/2017/7429697.
- Agaimy A, Märkl B, Kitz J, et al. **Peripheral nerve sheath tumors of the gastrointestinal tract: a multicenter study of 58 patients including NF1-associated gastric schwannoma and unusual morphologic variants.** *Virchows Arch* 2010; 456: 411–422.
- Ko S-B, Song K-O, Kang S-C, et al. **Cutaneous peripheral nerve sheath tumors in 15 dogs.** *Korean J Vet Res* 2014; 54: 7–12.
- Swift KE, McGrath S, Nolan MW, et al. **Clinical and imaging findings, treatments, and outcomes in 27 dogs with imaging diagnosed trigeminal nerve sheath tumors: a multi-center study.** *Vet Radiol Ultrasound* 2017; 58: 679–689.
- Silva E, Goiozo P, Pereira L, et al. **Concomitant malignant pulmonary peripheral nerve sheath tumour and benign cutaneous peripheral nerve sheath tumour in a dog.** *J Comp Pathol* 2017; 157: 46–50.
- Bergmann W, Burgener I, Roccabianca P, et al. **Primary splenic peripheral nerve sheath tumour in a dog.** *J Comp Pathol* 2009; 141: 195–198.
- Park J-W, Woo G-H, Jee H, et al. **Malignant peripheral nerve sheath tumour in the liver of a dog.** *J Comp Pathol* 2011; 144: 223–226.
- Patterson CC, Perry RL and Steficek B. **Malignant peripheral nerve sheath tumor of the diaphragm in a dog.** *J Am Anim Hosp Assoc* 2008; 44: 36–40.



- 33 Anderson GM, Dallaire A, Miller LM, et al. **Peripheral nerve sheath tumor of the diaphragm with osseous differentiation in a one-year-old dog.** *J Am Anim Hosp Assoc* 1999; 35: 319–322.
- 34 Akdesir E. **Malignant peripheral nerve sheath tumour in the tongue of a dog.** *J Comp Pathol* 2012; 69: 243–246.
- 35 Baratt RM, Rawlinson J, Roth-Johnson L, et al. **Lingual malignant peripheral nerve sheath tumor in a Chinese pug dog.** *J Vet Dent* 2015; 32: 165–172.
- 36 Yap F and Pratschke K. **Peripheral nerve sheath tumor of the vagus nerve in a dog.** *J Am Anim Hosp Assoc* 2016; 52: 57–62.
- 37 Hara Y, Tagawa M, Ejima H, et al. **Regression of hypertrophic osteopathy following removal of intrathoracic neoplasia derived from vagus nerve in a dog.** *J Vet Med Sci* 1995; 57: 133–135.
- 38 Ruppert C, Hartmann K, Fischer A, et al. **Cervical neoplasia originating from the vagus nerve in a dog.** *J Small Anim Pract* 2000; 41: 119–122.
- 39 So B, Jung J, Jung J, et al. **Omental malignant peripheral nerve sheath tumour with pulmonary and hepatic metastasis in a dog.** *J Comp Pathol* 2016; 1: 104.
- 40 Leis ML, Salpeter ME, Bauer BS, et al. **Primary bilateral corneal nerve sheath neoplasm in a dog.** *Vet Ophthalmol* 2017; 20: 365–371.
- 41 Sugiyama A, Morita T, Shimada A, et al. **Primary malignant peripheral nerve sheath tumor with eosinophilic cytoplasmic globules arising from the greater omentum in a dog.** *J Vet Med Sci* 2008; 70: 739–742.
- 42 Sato T, Yamamoto A, Shibuya H, et al. **Intraocular peripheral nerve sheath tumor in a dog.** *Vet Ophthalmol* 2005; 8: 283–286.
- 43 Duke FD, Brudenall DK, Scott EM, et al. **Metastatic uveal schwannoma of blue-eyed dogs.** *Vet Ophthalmol* 2013; 16: 141–144.
- 44 Zarfoss M, Klauss G, Newkirk K, et al. **Uveal spindle cell tumor of blue-eyed dogs: an immunohistochemical study.** *Vet Pathol* 2007; 44: 276–284.
- 45 Wohlsein P, Cichowski S and Baumgärtner W. **Primary endocardial malignant spindle-cell sarcoma in the right atrium of a dog resembling a malignant peripheral nerve sheath tumour.** *J Comp Pathol* 2005; 132: 340–345.
- 46 Shihab N, Summers BA, Benigni L, et al. **Imaging diagnosis – malignant peripheral nerve sheath tumor presenting as an intra-axial brain mass in a young dog.** *Vet Radiol Ultrasound* 2013; 54: 278–282.
- 47 vom Hagen F, Romkes G, Kershaw O, et al. **Malignant peripheral nerve sheath tumor of the third eyelid in a 3-year-old Rhodesian Ridgeback.** *Clin Case Rep* 2015; 3: 50–56.
- 48 Rothwell T, Papadimitriou J, Xu F-N, et al. **Schwannoma in the testis of a dog.** *Vet Pathol* 1986; 23: 629–631.
- 49 Briffod C, Hélie P, De Lasalle J, et al. **Case report.** *Can Vet J* 2018; 59: 379–384.
- 50 Ichikawa M, Suzuki S, Tei M, et al. **Malignant peripheral nerve sheath tumor originating from the adrenal gland in a dog.** *J Vet Med Sci* 2018; 80: 1572–1575.
- 51 García P, Sanchez B, Sanchez M, et al. **Epithelioid malignant peripheral nerve sheath tumour in a dog.** *J Comp Pathol* 2004; 131: 87–91.
- 52 Haagsman AN, Witkamp AC, Sjollem BE, et al. **The effect of interleukin-2 on canine peripheral nerve sheath tumours after marginal surgical excision. A double-blind randomized study.** *BMC Vet Res* 2014; 9: 155. DOI: 10.1186/1746-6148-9-155.
- 53 Dolera M, Malfassi L, Bianchi C, et al. **Frameless stereotactic volumetric modulated arc radiotherapy of brachial plexus tumours in dogs: 10 cases.** *Br J Radiol* 2016; 90. DOI: 10.1259/bjr.20160617.
- 54 Elmslie R, Glawe P and Dow S. **Metronomic therapy with cyclophosphamide and piroxicam effectively delays tumor recurrence in dogs with incompletely resected soft tissue sarcomas.** *J Vet Intern Med* 2008; 22: 1373–1379.
- 55 De Queiroz GF, Matera JM and Zaidan Dagli ML. **Clinical study of cryosurgery efficacy in the treatment of skin and subcutaneous tumors in dogs and cats.** *Vet Surg* 2008; 37: 438–443.
- 56 Risetto K, Villamil JA, Selting KA, et al. **Recent trends in feline intestinal neoplasia: an epidemiologic study of 1,129 cases in the veterinary medical database from 1964 to 2004.** *J Am Anim Hosp Assoc* 2011; 47: 28–36.
- 57 Morini M, Gentilini F, Pietra M, et al. **Cytological, immunohistochemical and mutational analysis of a gastric gastrointestinal stromal tumour in a cat.** *J Comp Pathol* 2011; 145: 152–157.
- 58 Leo C, Stell A, Borrego J, et al. **Evaluation of low-dose metronomic (LDM) cyclophosphamide toxicity in cats with malignant neoplasia.** *J Feline Med Surg* 2014; 16: 671–678.
- 59 Goumard C, Marcal LP, Wang W-L, et al. **Long-term survival according to histology and radiologic response to preoperative chemotherapy in 126 patients undergoing resection of non-GIST sarcoma liver metastases.** *Ann Surg Oncol* 2018; 25: 107–116.
- 60 DeMatteo RP, Shah A, Fong Y, et al. **Results of hepatic resection for sarcoma metastatic to liver.** *Ann Surg* 2001; 234: 540–547.